

# Preservation of Glanular Cleft in the Configuration of a Vertical Slit NeoMeatus in Modified Mathieu Hypospadias Repair

Khizer Mansoor, Thomas Tsang<sup>1</sup>, Philemon E. Okoro<sup>2</sup>

Departments of Neonatal & Paediatric Surgery and <sup>1</sup>Paediatric Surgery, Norfolk and Norwich University Hospital, Norwich, UK, <sup>2</sup>Department of Neonatal & Paediatric Surgery, University of Port Harcourt Teaching Hospital, Port Harcourt, Nigeria

## Abstract

**Background:** The aim of this study is to review the results of modified Mathieu's repair in a single surgeon's series. The technique involved preserving the apical part of the glanular cleft including the lips, part of the un-formed glanular meatus in the reconstruction of a vertical slit neomeatus. The achievement of a vertical slit neomeatus was critically assessed. **Materials and Methods:** A retrospective analysis was carried out for all cases of Mathieu's repair done by a single surgeon over the past 22 years (1995–2017). Inclusion criteria included all cases of coronal, subcoronal and distal penile hypospadias. Cases done as redo secondary Mathieu's procedure were also included irrespective of the type of primary procedure. **Results:** A total of 97 cases fulfilled the inclusion criteria. 91 patients had a primary Mathieu's procedure. Six patients had a Mathieu's repair as a secondary operation. The complications included 4 fistulas (4.12%), 3 meatal retractions (3.09%) and 2 mild stenosis (2.06%). There were no breakdowns of the repair. Ninety-four patients (96.90%) had a glanular vertical slit neomeatus. This included patients with a fistula and both patients with mild stenosis. All fistulas were successfully closed in a single attempt. Four patients (4.12%) had a slight splaying of the lower end of the meatus and three circular neomeatus (3.09%). Both cases of stenosis responded well to dilatation. **Conclusion:** Mathieu's repair is an old and time-tested technique used in surgery of distal hypospadias. With modification aiming to preserve the apical part of the glanular cleft adopted, a vertical slit neomeatus can be achieved readily as shown by our series and major complications appear rather uncommon.

**Keywords:** Hypospadias, Mathieu's repair, meatal-based flap

## INTRODUCTION

Hypospadias is one of the most common urological procedures being performed in the paediatric age group. The generally accepted incidence of hypospadias is 0.82–8.2/1000 live male births.<sup>[1]</sup> Approximately 70% of the cases are of distal hypospadias. Many techniques have been reported for correction of this anomaly. Mathieu described his single-stage meatal-based flap technique over 80 years ago,<sup>[2]</sup> and it has been commonly used since.<sup>[3]</sup> A fish-mouth meatus following the classical Mathieu's repair is often considered as a major deficiency, and various modifications have been described to overcome it.<sup>[4-7]</sup>

In this series, the modified Mathieu's repair used preserved the apical part of the glanular cleft including the lips, part of the unformed glanular meatus in the reconstruction of a vertical slit neomeatus. Our results are presented.

## MATERIALS AND METHODS

A retrospective analysis of all cases of Mathieu's repair done by a single surgeon over the last 22 years (1995–2017) was carried out. Operation theatre database and the personal record were used to identify patients.

The demographic data, description of the defect, age at surgery, follow-up progress at 3 months, 15 months and 4 years and any associated complications were noted.

All cases of coronal, sub-coronal and distal penile hypospadias were included in the study. Cases done as secondary Mathieu's procedure were also included irrespective of the primary procedure.

**Address for correspondence:** Mr. Thomas Tsang,  
Department of Paediatric Surgery, Norfolk and Norwich University Hospital,  
Colney Lane, Norwich NR4 7SE, UK.  
E-mail: thomas.tsang@nnuh.nhs.uk

Received: 18-07-2017 Accepted: 04-03-2018 Available Online: 16-09-2020

### Access this article online

Quick Response Code:



Website:  
www.afrijpaedsurg.org

DOI:  
10.4103/ajps.AJPS\_67\_17

This is an open access journal, and articles are distributed under the terms of the Creative Commons Attribution-NonCommercial-ShareAlike 4.0 License, which allows others to remix, tweak, and build upon the work non-commercially, as long as appropriate credit is given and the new creations are licensed under the identical terms.

**For reprints contact:** WKHLRPMedknow\_reprints@wolterskluwer.com

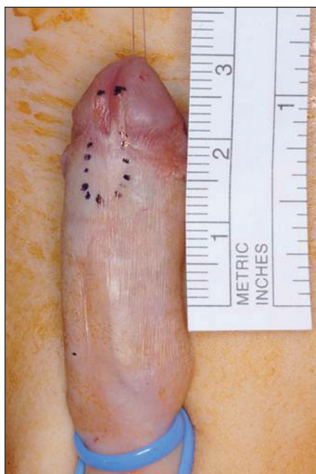**How to cite this article:** Mansoor K, Tsang T, Okoro PE. Preservation of glanular cleft in the configuration of a vertical slit neomeatus in modified Mathieu hypospadias repair. Afr J Paediatr Surg 2019;16:10-13.

## Surgical technique

All cases have been performed by a single surgeon using a standardised technique.

The patients received a general anaesthetic and caudal block. Horton's test was performed to assess chordee. A Denis Browne Ring Retractor was used to station the penile shaft on the full stretch to facilitate the surgery.<sup>[8]</sup>

The Mathieu's meatal-based flap was marked as shown in Figure 1. The length of the flap required was measured from the inferior edge of the hypospadiac meatus to the lip, a prominence along each side ('hillock') of glanular cleft. The width of the flap was 6–7 mm normally. The flap with the convex apex was raised from the ventral penile skin, 7/0 polydioxanone suture (PDS) was placed at the two corners of the free-end to provide traction avoiding any unnecessary grasping and tissue trauma of the flap during mobilisation. Distal incision followed on from the flap was made straight across the coronal sulcus along a line joining the lip of glanular cleft on each side. The glanular part of incision was deepened to give a loose adequate glans wing on each side. The neourethra was formed following a side-to-side anastomosis using subcuticular, continuous and inverting 7/0 PDS (polydioxanone, Ethicon) sutures of the Mathieu flap and the isolated distal urethral plate and part of the glanular cleft. The apical part of the glanular cleft and the apex of the flap bridging across the lips of the cleft formed the neomeatus [Figure 2]. A volume of 3 ml of the lateral part of the 2 glans wings were brought together and fixed to the neomeatus at the 6'0 clock position using 6/0 PDS. The rest of the glans wings were sutured together using interrupted, buried 6/0 PDS along the midline buttressing the neourethra and forming the ventral glans penis. As there was no overlap of the suture lines between the neourethra and the glans repair, no second waterproof layer was used. Excision of the hooded foreskin was done routinely unless parents had expressed their preference for a reconstruction of the foreskin. The ventral penile skin defect left by the flap was closed with the lateral skin mobilised and brought together in the midline using interrupted 6/0 PDS.



**Figure 1:** Marking of Mathieu's flap showing lips of un-formed meatus, points of glans closure and glans wings at neo-meatus level

A Foley catheter was inserted for urinary diversion. Trilaminare Allevyn (Smith and Nephew, UK and Ireland) non-adherent dressing was used<sup>[9]</sup> due to the ease of application and removal. This replaced the conformable foam (Cavi-care, Smith and Nephew, UK and Ireland) dressing used in early cases. The catheter and dressing were removed after 48 h postoperatively.<sup>[10]</sup> Parents were given the choice of the child staying only the first night and returning for removal of dressing and catheter or the full 48 h.<sup>[11]</sup>

Prophylactic trimethoprim was given to the patient while the urinary catheter was *in situ*. The catheter and dressing were taken off with the child sedated using oral midazolam. All patients are followed up at 3 months, 15 months and 4 years after the operation.

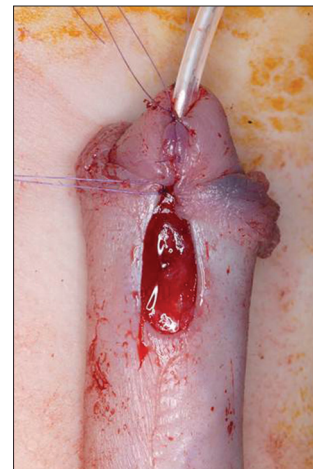
## RESULTS

A total of 97 cases fulfilled the inclusion criteria of this study.

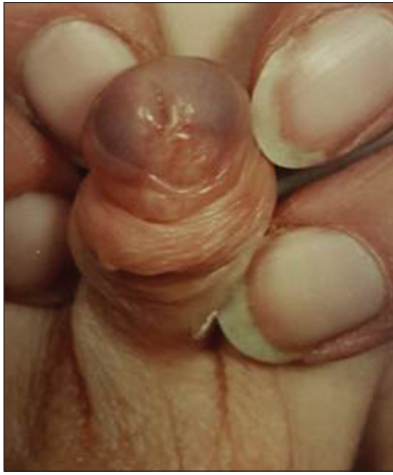
A total of 91 patients had a primary Mathieu's procedure. Six patients had a secondary Mathieu procedure, with the previous repair being Snodgrass in 1, Duckett onlay in 2, Meatal Advancement Glanuloplasty in 2 and a previous Mathieu in 1. Age of patients ranged from 8 months to 5 years at the time of surgery, with a mean age of 20 months. Level of distal hypospadias was coronal in 72 patients, subcoronal in 17 patients and distal penile hypospadias in 8 patients. 18 patients had a mild chordee.

Follow-up ranged from 15 months to 4 years with a mean of 2.5 years. Complications were noted in 9 patients: fistula in 4 (4.12%), meatal retraction in 3 (3.09%) and 2 had mild stenosis (2.06%).

Ninety-four patients (96.90%) had a vertical slit neomeatus [Figure 3]. This included the 4 patients with fistula and both patients with mild stenosis. All fistulae were closed operatively at 6–12 months from the initial repair. Both cases of stenosis responded well to dilatation. In 4 patients (4.12%), the lower end of the neomeatus was splayed giving it a slight



**Figure 2:** A completed modified Mathieu repair with urinary catheter *in situ*



**Figure 3:** Postoperative appearance of vertical slit neo-meatus at 3 months

triangular appearance compared to a natural slit, but the maximal dimension was still vertical. Three patients (3.09%) had a roundish neomeatus.

## DISCUSSION

The ‘fish-mouth’ appearance of the neomeatus following Mathieu’s repair has been seen as a common deficiency of the technique. With reference to the lips along the ridge of the glanular cleft, an easily recognisable part the unformed glanular meatus, augmented by the meatal-based flap allows a final configuration of the vertical slit neomeatus. The incision raising the glans wing was placed precisely along the ridge of the cleft, in line with the lips, instead of a straight paramedian one as in the original Mathieu’s technique. Preserving the lips and rest of apical cleft is essential in the final vertical slit appearance. The Mathieu flap has been considered rather robust with good vascularity, and our incidence of retraction of neomeatus is of 3.09% and total dehiscence of the repair has not been seen in our series. This agrees well with the report of a 100% success rate by Retik *et al.*, using the Mathieu’s repair in over 200 consecutive cases.<sup>[3]</sup>

Modifications of Mathieu’s repair aiming to achieve a vertical slit neomeatus have been reported. Barcat described the ‘balanic groove technique’ in 1969.<sup>[4]</sup> It involves a midline incision made into the glans allowing the neourethra buried deep into the glans tissue to create a more vertical meatus. Their results showed a significant complication rate of 20% involving breakdown and fistula formation in a series of 267 patients. In 1989, Rich *et al.*, described ‘hinging of the urethral plate’ in combination with the Mathieu flap.<sup>[5]</sup> Boddy and Samuel described a new modification for Mathieu’s repair called Mathieu and ‘V’ incision sutured (MAVIS) in 2000.<sup>[6]</sup> They excised a triangle from the apex of the para-meatal flap to create a more slit-like effect and a good cosmetic result without any fistula or stenosis was reported in 32 patients. Their complication rate was only 3%. The latest modification

has been described by Hadidi. This is called slit-like adjusted Mathieu’s technique with adjustment of the meatal edge of the flap similar to MAVIS, for distal hypospadias.<sup>[7]</sup> According to the authors, the main modifications were based on the design of a converging incision and the technique of suturing. They have reported a satisfactory result in 97%. Their fistula rate was 1.60%. They reported a stenosis rate of 0.45% and a repair breakdown rate of 0.68%.

Our technique deviates from the classical Mathieu’s repair in the position of the balanic incisions and preservation of the glanular cleft including the lips. In situation with a shallow glanular cleft or small and short glans, the success rate to recreate a vertical slit neomeatus will probably be lower. A postrepair roundish neomeatus which we attributed to the shallow glanular cleft has been seen in 3 of our patients

Among our series of 97 patients, a glanular vertical slit neomeatus was achieved in almost 97% of them. This compares favourably to 92.3% reported by Hamid *et al.*, in their experience in the use of Snodgrass technique.<sup>[12]</sup> Our experience with this technique is that of a reliable result of an adequate functioning neomeatus with good cosmesis. Our overall success rate is comparable to other reported series, in the use of Mathieu’s technique in the repair of distal hypospadias.<sup>[12]</sup>

## CONCLUSION

Mathieu’s repair is an old and time-tested technique used in surgery of distal hypospadias. With modification aiming to preserve the apical part of the glanular cleft adopted, a vertical slit neomeatus can be achieved readily as shown by our series and major complications appear rather uncommon. We can recommend favourably this approach as one of the options for distal hypospadias repair.

## Financial support and sponsorship

Nil.

## Conflicts of interest

There are no conflicts of interest.

## REFERENCES

1. Murphy JP. Hypospadias. In: Holcomb GW 3<sup>rd</sup>, Murphy PJ, Ostle DJ, editors. Philadelphia, PA: Ashcraft’s Pediatric Surgery. 6<sup>th</sup> ed. Saunders Elsevier; 2014. p. 794-807.
2. Mathieu P. Traitment en un temps de l’hypospadias balanique et juxta balanique. *J Chir* 1932;39:481-4.
3. Retik AB, Mandell J, Bauer SB, Atala A. Meatal based hypospadias repair with the use of a dorsal subcutaneous flap to prevent Urethrocutaneous fistula. *J Urol* 1994;152:1229-31.
4. Barcat J. Symposium sur l’hypospadias. *Ann Chir Infant* 1969;10:287.
5. Rich MA, Keating MA, Snyder HM, Duckett JW. Hinging the urethral plate in hypospadias meatoplasty. *J Urol* 1989;142:1551-3.
6. Boddy S, Samuel M. A natural glanular meatus after ‘mathieu and a V incision sutured’: MAVIS. *BJU Int* 2000;86:394-7.
7. Hadidi AT. The slit-like adjusted Mathieu technique for distal hypospadias. *J Pediatr Surg* 2012;47:617-23.
8. Tsang TM, Stewart RJ. Denis Browne ring retractor in hypospadias surgery. *Br J Urol* 1995;76:510.

9. Fathi K, Tsang T. A technique for applying a non-adherent, tri-laminate dressing for hypospadias repair. *Ann R Coll Surg Engl* 2009;91:164-5.
10. Gough DC, Dickson AP, Tsang T. Mathieu hypospadias repair: The postoperative care. In: Thuroff JW, Hohenfellner M, editors. *Reconstructive Surgery of the Lower Urinary Tract in Children*. Oxford: Isis Medical Media Ltd; 1995. p. 55-8.
11. Okoro PE, Tsang T. Short hospital stay versus day-care mathieu hypospadias repair. *Afr J Paediatr Surg* 2008;5:29-31.
12. Hamid R, Baba AA, Shera AH. Comparative study of snodgrass and mathieu's procedure for primary hypospadias repair. *ISRN Urol* 2014;2014:249765.