

Received: 2018.01.24
Accepted: 2018.02.11
Published: 2018.02.27

Efficacy of Laminoplasty in Patients with Cervical Kyphosis

Authors' Contribution:
Study Design A
Data Collection B
Statistical Analysis C
Data Interpretation D
Manuscript Preparation E
Literature Search F
Funds Collection G

ABDEFG **Shengjun Qian**
CDE **Zhan Wang**
BCD **Guangyao Jiang**
EF **Zhengkuan Xu**
ACEF **Weishan Chen**

Centre for Orthopedic Research, Orthopedics Research Institute of Zhejiang University, Department of Orthopedics, The Second Affiliated Hospital, School of Medicine, Zhejiang University, Hangzhou, Zhejiang, P.R. China

Corresponding Author: Weishan Chen, e-mail: chenweishan@zju.edu.cn

Source of support: This work was supported by the Zhejiang Provincial Natural Science Foundation (Grant no. LQ17H060003)

Background: The efficacy of laminoplasty in patients with cervical kyphosis is controversial. The purpose of this study was to investigate the impact of the initial pathogenesis on the clinical outcomes of laminoplasty in patients with cervical kyphosis.





Material/Methods: A total of 137 patients with cervical spondylotic myelopathy (CSM) or ossification of the posterior longitudinal ligament (OPLL) underwent laminoplasty from April 2013 to May 2015. The patients were divided into the following 4 groups: lordosis with CSM (LC), kyphosis with CSM (KC), lordosis with OPLL (LO), and kyphosis with OPLL (KO). The clinical outcome measures included the visual analogue scale (VAS) and modified Japanese Orthopedic Association (mJOA) scores, the range of motion (ROM), and the cervical global angle (CGA).

Results: The mean VAS and mJOA scores improved significantly in all groups after surgery. The changes in VAS and mJOA scores were significantly smaller, and the JOA recovery rate was significantly lower, in the KC group than in the LC and KO groups. The mean change in the CGA was greatest in the KC group (>8° towards kyphosis). The preoperative ROM was negatively correlated with the change in CGA and the JOA recovery rate in the KO and KC groups.

Conclusions: We found that laminoplasty is suitable for patients with cervical lordosis and those with mild cervical kyphosis and OPLL, but is not recommended for patients with kyphosis and CSM, particularly those with a large ROM preoperatively.

MeSH Keywords: **Kyphosis • Lordosis • Ossification of Posterior Longitudinal Ligament • Range of Motion, Articular**

Full-text PDF: <https://www.medscimonit.com/abstract/index/idArt/909140>

 1996  6  4  33



Background

Laminoplasty is effective in patients with multi-level cervical spinal canal stenosis, as first reported by Hattori et al. [1-4]. Laminoplasty alleviates cervical spinal cord compression by exerting a direct posterior local decompression effect, as well as an indirect anterior decompression effect due to posterior migration of the spinal cord [5,6]. Previous studies showed that cervical sagittal alignment plays an important role in the clinical outcomes of laminoplasty [7-9]. As laminoplasty is a posterior indirect decompression method, it is strongly recommended for patients with preoperative cervical lordotic alignment but is not suitable for patients with preoperative cervical neutral or kyphotic alignment [10-12]. However, some recent studies reported that preoperative cervical sagittal alignment did not have a consistent effect in the clinical outcomes of laminoplasty [13,14]. Moreover, other studies showed that laminoplasty was also suitable for patients with mild cervical kyphosis [15-17].

Although laminoplasty can be performed in patients with cervical kyphosis, the required angle of cervical kyphosis remains controversial [18]. Cervical spondylotic myelopathy (CSM) and ossification of the posterior longitudinal ligament (OPLL) are the major pathogenetic mechanisms of multi-level cervical spinal canal stenosis, and the former always has more dynamic factors while the latter mainly has more static factors [19-22]. Compared with patients with CSM, patients with OPLL always have smaller preoperative ROM. As cervical segmental stability is a key factor for the indication of laminoplasty, the preoperative ROM may play a crucial role in the process of aggravated kyphosis after surgery [23-27]. To the best of our knowledge, previous studies have not assessed the impact of the pathogenetic mechanism on the clinical outcomes of laminoplasty in patients with mild cervical kyphosis. Therefore, in the present study we compared the clinical outcomes of patients with and without cervical kyphosis, and assessed the impact of the pathogenetic mechanism on this process.

Material and Methods

Study population

From April 2013 to May 2015, we retrospectively analyzed 158 patients diagnosed with multi-level cervical spinal canal stenosis who underwent unilateral open-door laminoplasty. All of these patients were treated by the same senior surgeon. Twenty-one patients who had cervical segmental instability, local kyphosis, prominent anterior compression, spinal injury, infection, tumor and inflammatory arthritis were excluded (Figure 1). Eighty-eight men and 49 women with an average age of 55.3 years (range 33 to 77 years) were enrolled in this

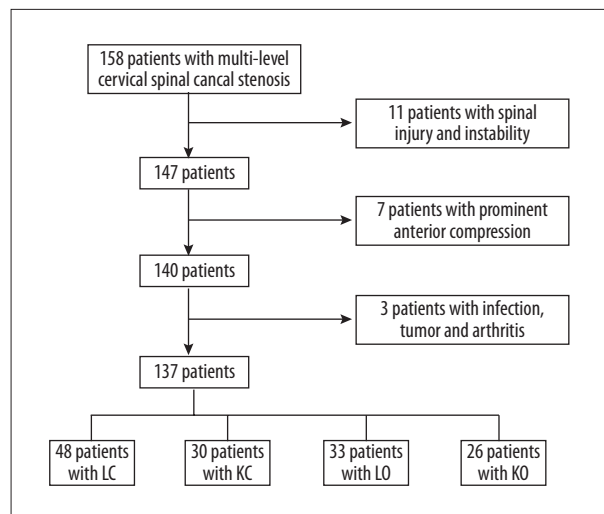


Figure 1. Flowchart of the collection of the study population.

study. Sixty-two patients had 3 levels of cervical canal stenosis and 75 patients had 4 or 5 levels of cervical canal stenosis. Eighty-one patients had cervical lordosis (cervical global angle (CGA) $>0^\circ$) and 56 patients had cervical kyphosis (CGA $<0^\circ$) (Figure 2A, 2B). Fifty-nine patients had OPLL and 78 patients had CSM (Figure 2C, 2D). The patients were divided into the following 4 groups: lordosis with CSM (LC group, $n=48$), kyphosis with CSM (KC group, $n=30$), lordosis with OPLL (LO group, $n=33$), and kyphosis with OPLL (KO group, $n=26$). The average follow-up duration was 30.6 months (range 24 to 38 months) (Table 1).

Operative techniques

All patients underwent unilateral open-door laminoplasty with fixation using titanium miniplates. The paravertebral muscle was detached from each lamina while preserving the muscles attached to the C2 spinous process as much as possible. A high-speed air drill was used to open the hemilamina on the dominant symptomatic side. A shallow gutter was scored on the contralateral hemilamina and used as a hinge to open the lamina. Next, the hinged, open-door lamina was fixed using a preshaped titanium miniplate, and small screws were twisted through the plate holes into the lateral mass on the dominant symptomatic side and the opened lamina on the contralateral side. A cervical collar was used for 2 to 4 weeks after the operation.

Data collection

Clinical efficacy was assessed using visual analogue scale (VAS) and modified Japanese Orthopedic Association (mJOA) score. The VAS score was used to measure pain on a scale of 0 to 10, on which the higher the score, the greater the level of pain. The mJOA score was a 17-point instrument based on

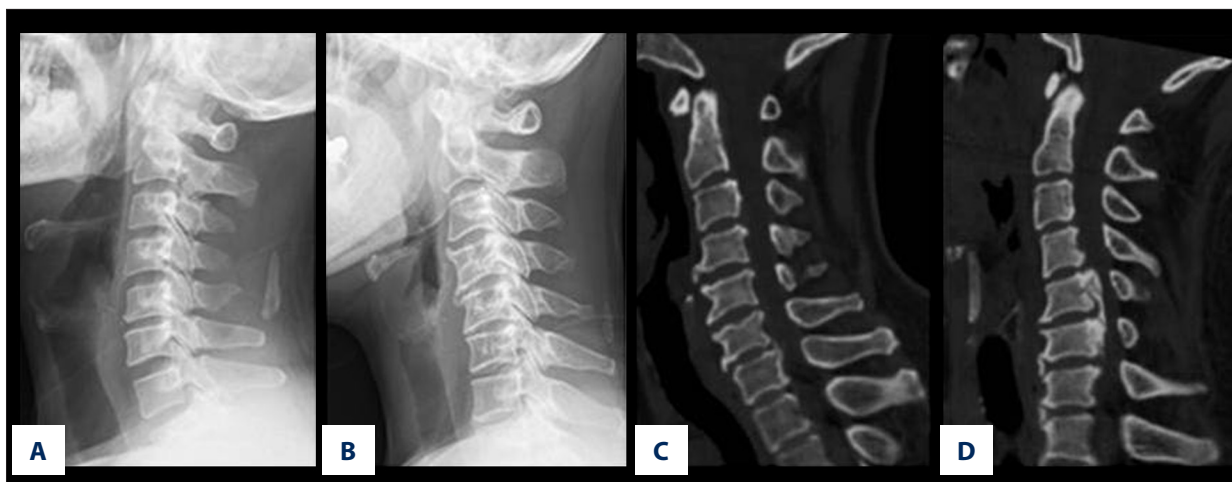


Figure 2. The schematic of lordosis, kyphosis, CSM and OPLL. (A) lordosis in lateral radiograph. (B) kyphosis in lateral radiograph. (C) CSM in sagittal computed tomography scan. (D) OPLL in sagittal computed tomography scan.

Table 1. Clinical summary of 137 patients with multi-level cervical spondylosis.

Variable	Data
Gender	
Male	88
Female	49
Mean age (y, mean ±SD)	55.3±22.1
Cervical canal stenosis segments	
3 levels	62
4–5 levels	75
Pathogenesis	
OPLL	59
CSM	78
Type	
Cervical lordosis	81
Cervical kyphosis	56
Subgroup	
LC group	48
KC group	30
LO group	33
KO group	26
Mean follow-up time (mo, mean ±SD)	30.6±7.1

ratings of sensory function (upper extremity, lower extremity, and trunk), motor function (upper and lower extremities), and urinary bladder function. The JOA recovery rate was calculated as follows: JOA recovery rate (%)=(postoperative

JOA–preoperative mJOA)÷(17–preoperative mJOA)×100%. A JOA recovery rate of >50% was considered indicative of a satisfactory clinical outcome.

Cervical standing neutral radiographs and lateral dynamic radiographs (extension and flexion) were taken before and after surgery, and at the final follow-up. As the inferior border of the C7 vertebra was indefinite in lateral radiographs, the Cobb angle method was unsuitable. Instead, the cervical sagittal alignment was represented by the cervical global angle (CGA), which was measured between the posterior border of the C2 and C7 vertebral bodies [28]. The C2–7 ROM was calculated as the difference between the cervical lordotic and kyphotic angles measured on lateral dynamic radiographs taken during maximal extension and flexion, respectively. Measurements were performed at least 3 times by one of the authors and an independent experienced musculoskeletal radiologist.

Statistical analysis

The statistical significance of differences between groups was determined by *t* tests in SPSS version 20.0. A *p*-value <0.05 was considered indicative of statistical significance. Linear regression analysis was performed in KO and KC groups to evaluate the relationship of preoperative ROM with the CGA change and JOA recovery rate.

Ethics statement

All procedures were performed at our institution with the approval of the Institutional Ethics Committee. Written informed consent was obtained from the patients for publication of this study and any accompanying images. Procedures were carried out in accordance with the appropriate guidelines.

Table 2. Assessment of VAS score and JOA score before and after surgery in each subgroup.

	LO		LC		KO		KC	
	Pre	Post	Pre	Post	Pre	Post	Pre	Post
VAS (mean ±SD)	5.4±1.6	3.0±1.5	5.1±1.6	2.2±1.1	5.8±1.8	2.8±1.3	5.4±1.9	3.3±1.3
<i>p</i> Value	<0.001		<0.001		<0.001		<0.001	
JOA (mean ±SD)	9.2±1.9	13.5±2.2	9.4±2.0	13.6±2.3	8.3±2.0	12.7±2.4	7.6±1.8	10.9±2.9
<i>p</i> Value	<0.001		<0.001		<0.001		<0.001	

T-test – statistically significant at $p < 0.05$.

Table 3. Comparison of the changes in VAS score, JOA score and JOA recovery rate between subgroups.

	OPLL		CSM		Lordosis		Kyphosis	
	LO	KO	LC	KC	LO	LC	KO	KC
VAS change (mean ±SD)	-2.4±1.1	-3.0±1.5	-2.9±1.1	-2.2±1.4	-2.4±1.1	-2.9±1.1	-3.0±1.5	-2.2±1.4
<i>p</i> Value	0.066		0.016		0.044		0.037	
JOA change (mean ±SD)	4.4±1.7	4.3±1.4	4.2±1.9	3.3±1.9	4.4±1.7	4.2±1.9	4.3±1.4	3.3±1.9
<i>p</i> Value	0.966		0.046		0.665		0.024	
JOA recovery rate (%) (mean ±SD)	58±20	50±18	57±22	38±19	58±20	57±22	50±18	38±19
<i>p</i> Value	0.080		<0.001		0.846		<0.001	

T-test – statistically significant at $p < 0.05$.

Table 4. CGA and ROM before and after surgery in each subgroup.

	LO		LC		KO		KC	
	Pre	Post	Pre	Post	Pre	Post	Pre	Post
CGA (mean ±SD)	15.1±8.3	11.8±8.6	16.5±9.9	12.5±8.1	-5.6±7.0	-8.2±7.9	-5.4±7.5	-13.8±10.6
<i>p</i> Value	<0.001		0.005		<0.001		<0.001	
ROM (mean ±SD)	41.4±13.2	30.0±14.2	41.5±15.9	34.5±14.3	37.0±13.5	25.3±14.6	47.7±16.6	39.7±15.3
<i>p</i> Value	<0.001		<0.001		<0.001		<0.001	

T-test – statistically significant at $p < 0.05$.

Results

VAS, mJOA scores, and JOA recovery rate

The mean VAS and mJOA scores were significantly improved in all groups after surgery ($p < 0.001$, Table 2). At the final follow-up, the changes in VAS and mJOA scores in the KC group were significantly lower than those in the LC and KO groups ($p < 0.05$). The changes in mJOA scores were not significantly different among the other groups. The JOA recovery rates in the LO, LC, KO, and KC groups were (58±20)%, (57±22)%, (50±18)%, and (38±19)%, respectively. The JOA recovery rate in the KC group was significantly lower than those in the LC and KO groups ($p < 0.001$). No significant difference in the JOA

recovery rate was observed between the LO and LC groups (Table 3).

Changes in CGA and ROM

The mean CGA and ROM decreased significantly after surgery in all of the groups ($p < 0.05$, Table 4). In terms of CGA, all groups showed a trend towards a lordotic decrease or kyphotic increase. The change in CGA in the KC group was significantly greater ($> 8^\circ$ towards kyphosis) than those in the LC and KO groups ($p < 0.05$). No significant difference in the change in CGA was observed among the other groups. All groups showed a decreased ROM after surgery. The change in ROM in the LC group was significantly smaller than that in the LO group ($p < 0.05$).

Table 5. Comparison of the changes in CGA and ROM between subgroups.

	OPLL		CSM		Lordosis		Kyphosis	
	LO	KO	LC	KC	LO	LC	KO	KC
CGA change (mean ±SD)	-3.3±6.8	-2.6±6.3	-4.0±7.5	-8.4±7.4	-3.3±6.8	-4.0±7.5	-2.6±6.3	-8.4±7.4
p Value	0.493		0.004		0.648		<0.001	
ROM change (mean ±SD)	-11.4±13.0	-11.7±12.5	-7.0±17.3	-8.0±14.6	-11.4±13.0	-7.0±17.3	-11.7±12.5	-8.0±14.6
p Value	0.677		0.473		<0.001		0.001	

T-test – statistically significant at $p < 0.05$.

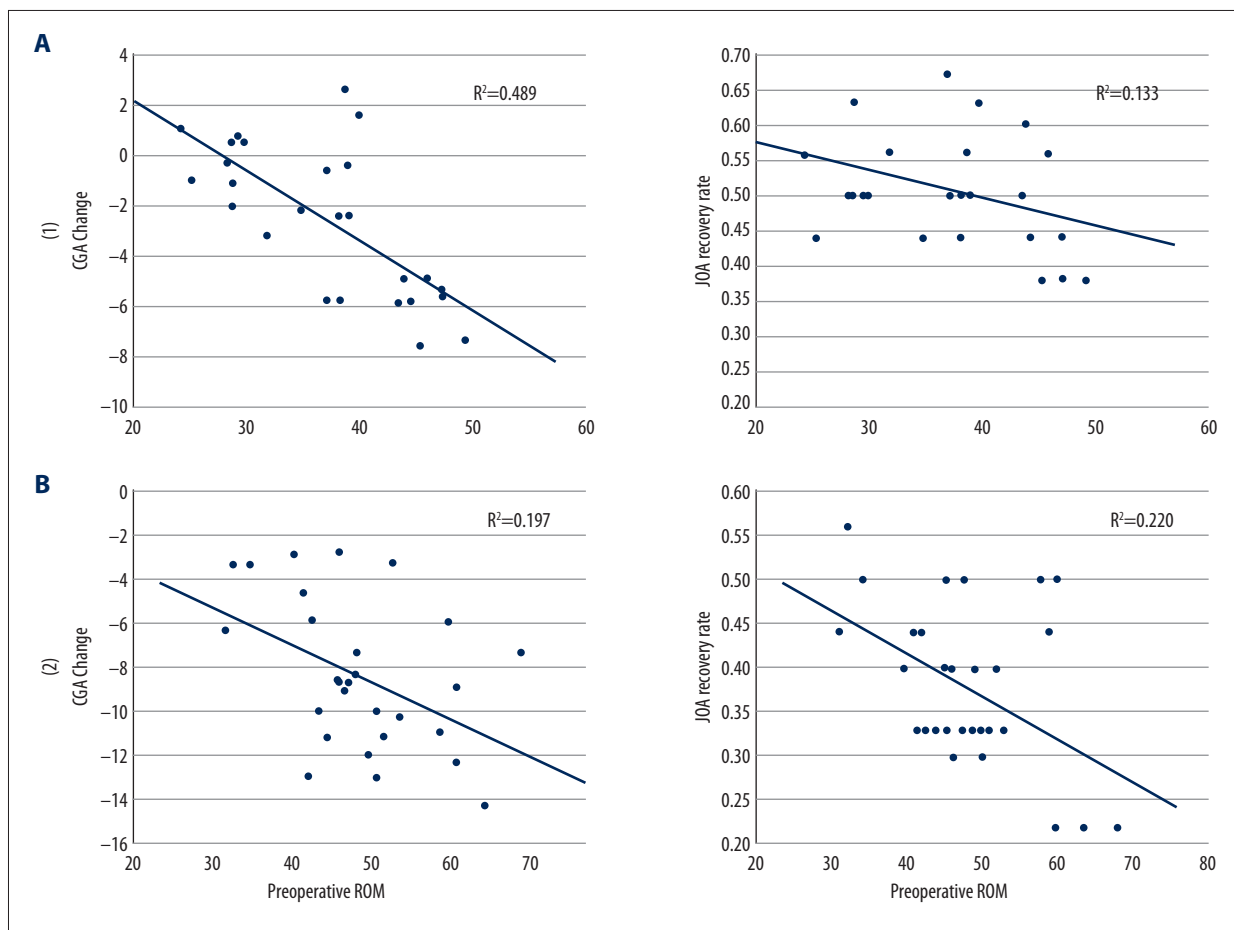


Figure 3. Linear regression analysis of preoperative ROM with CGA change and JOA recovery rate in KO (A) and KC (B) groups. Scatterplot showing preoperative ROM was negatively correlated with CGA change and JOA recovery rate in the KO and KC groups.

The change in ROM in the KC group was significantly smaller than that in the KO group ($p < 0.05$). The change in ROM did not differ significantly among the other groups (Table 5).

Relationships of preoperative ROM with CGA change and JOA recovery rate

Linear regression analysis showed that preoperative ROM was negatively correlated with CGA change and JOA recovery rate in the KO and KC groups (Figure 3).

Table 6. Postoperative complication rates in each subgroup.

	Persistent axial pain	C5 paresis	Progressive kyphosis
LO	3/33 (9%)	2/33 (6%)	2/33 (6%)
LC	6/48 (13%)	3/48 (6%)	4/48 (8%)
KO	4/26 (15%)	1/26 (4%)	3/26 (12%)
KC	8/30 (26%)	1/30 (3%)	10/30 (33%)

Complications

The incidence rates of persistent axial pain were 9%, 13%, 15%, and 26% in LO, LC, KO, and KC groups, respectively, meaning over one-fourth of the patients in the KC group had persistent axial pain after laminoplasty. The incidences of C5 paresis (cervical nerve root 5 palsy) were 6%, 6%, 4%, and 3% in the LO, LC, KO, and KC groups, respectively, which did not differ significantly among the groups. The incidences of progressive kyphosis (kyphosis aggravated with sagittal imbalance) were 6%, 8%, 12%, and 33% in the LO, LC, KO, and KC groups, respectively, meaning that over one-third of patients in the KC group had progressive kyphosis after laminoplasty (Table 6).

Discussion

Patients with OPLL have less ROM preoperatively and show a greater decrease in ROM postoperatively than those with CSM, which may influence their cervical sagittal alignment [29,30]. Moreover, patients with CSM are more likely to experience cervical instability after laminoplasty, suggesting that laminoplasty is more suitable for patients with OPLL [31–33]. In our study, the ROM decreased postoperatively in all groups. The change in ROM in the LC group was significantly smaller than that in the LO group, and the change in ROM in the KC group was significantly smaller than that in the KO group. These results suggest that patients with OPLL had stronger osteogenesis and cervical stability, and experienced a greater decrease in ROM than patients with CSM. Therefore, stability protection was not emphasized during laminoplasty for inpatients with OPLL. The JOA recovery rate in the KC group was 38%, which was significantly lower than that in the other groups ($p < 0.001$), suggesting that laminoplasty did not yield satisfactory results in kyphotic patients with CSM.

In terms of the change in CGA, all groups showed a trend towards a lordotic decrease or kyphotic increase postoperatively. The mean change in CGA was largest in the KC group ($> 8^\circ$ towards kyphosis), suggesting that the cervical sagittal alignment balance was fragile, and this kyphotic deformity may lead to serious anterior compression in the long term. Therefore, laminoplasty was not recommended for patients with CSM and

kyphosis. Interestingly, although the JOA recovery rate in the KO group was lower than that in the LO group, the changes in the VAS and mJOA scores, as well as those in CGA and ROM, did not differ significantly between the 2 groups after laminoplasty. Therefore, we consider that laminoplasty was suitable for patients with mild kyphosis and OPLL.

The preoperative ROM was negatively correlated with the CGA change and JOA recovery rate in the KO and KC groups, meaning that in the KO and KC groups, the postoperative likelihood of cervical kyphosis increased, and the JOA recovery rate decreased, with increasing preoperative ROM. Thus, preoperative ROM was related to the clinical outcomes of laminoplasty in patients with mild cervical kyphosis. For example, 1 patient in the KO group who had a large preoperative ROM (45.9°) showed a -7.6° change in CGA and unsatisfactory JOA recovery rate (38%) after laminoplasty (Figure 4A–4D), and 1 patient in the KC group who had a large preoperative ROM (63.6°) exhibited a -14.3° change in CGA and the lowest JOA recovery rate (22%) (Figure 4E–4H). Although laminoplasty protected the posterior cervical soft tissue, it still destroyed the posterior ligament and paravertebral muscle. Patients with a smaller preoperative ROM may have superior cervical balance and stronger posterior ligament and paravertebral muscle, which are important for avoiding the development of kyphotic deformity and cervical spine cord compression in the long term. The preoperative ROM can be regarded as an indicator of the anterior-posterior cervical soft tissue balance and be used to screen for the suitability for laminoplasty of patients with mild kyphosis. Additionally, the incidences of persistent axial pain and progressive kyphosis were 15% and 12%, respectively, in the KO group after laminoplasty, but in the KC group the incidences of persistent axial pain and progressive kyphosis had increased to 26% and 33%, respectively, after laminoplasty. Therefore, laminoplasty was more suitable for patients with mild kyphosis and OPLL than for those with mild kyphosis and CSM.

This study has several limitations. First, it was a retrospective study. Second, it was limited to a single institution. Third, a relatively small number of patients were involved, and the follow-up duration was short. Therefore, we plan to conduct a further study involving a larger number of patients and a longer follow-up.

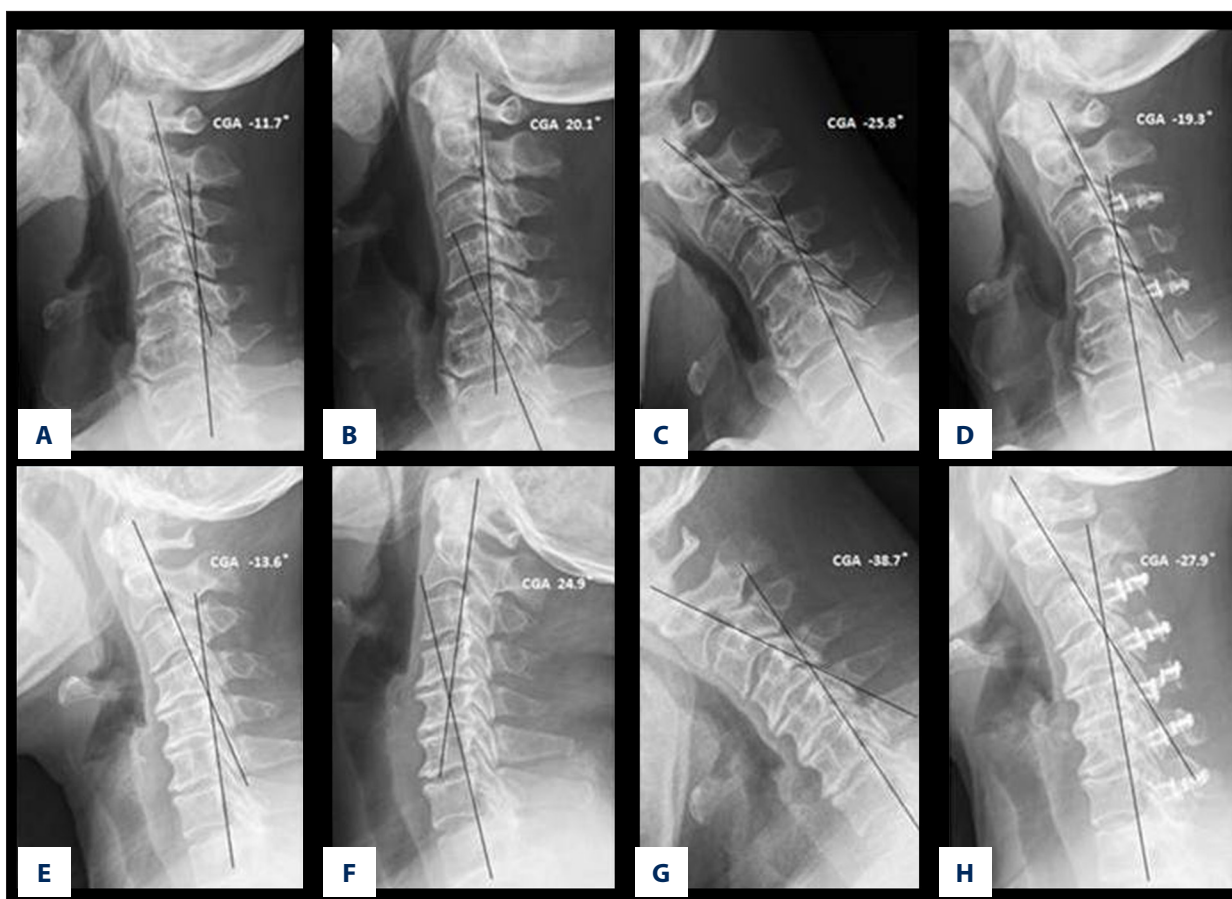


Figure 4. (A–D) A 70-year-old male patient in the KO group. (A) Preoperative lateral radiograph showed that the CGA was -11.7° . (B, C) Preoperative maximal flexion and extension lateral dynamic radiographs showed that the ROM was 45.9° . (D) Postoperative lateral radiograph showed that the CGA was -19.3° . (E–H) A 54-year-old female patient in the KC group. (E) Preoperative lateral radiograph showed that the CGA was -13.6° . (F, G) Preoperative maximal flexion and extension lateral dynamic radiographs showed that the ROM was 63.6° . (H) Postoperative lateral radiograph showed that the CGA was -27.9° .

Conclusions

In conclusion, laminoplasty is suitable for patients with cervical lordosis and those with mild cervical kyphosis and OPLL. The pathogenetic mechanism influences the clinical outcomes. Thus, laminoplasty is not recommended for patients with kyphosis and CSM, particularly those with a large ROM preoperatively.

References:

- Hale JJ, Gruson KI, Spivak JM: Laminoplasty: A review of its role in compressive cervical myelopathy. *Spine J*, 2006; 2895–985
- Satomi K, Ogawa J, Ishii Y et al: Short-term complications and long-term results of expansive open-door laminoplasty for cervical stenotic myelopathy. *Spine J*, 2001; 1: 26–30
- Jy Jia, Chen W, Xu L et al: A Modified laminoplasty technique to treat cervical myelopathy secondary to ossification of the posterior longitudinal ligament (OPLL). *Med Sci Monit*, 2017; 23: 4855–64
- Seichi A: Long-term results of double-door laminoplasty for cervical stenotic myelopathy. *Spine*, 2001; 26: 479–87
- Machino M: Cervical alignment and range of motion after laminoplasty: Radiographical data from more than 500 cases with cervical spondylotic myelopathy and a review of the literature. *Spine*, 2012; 37: E1243–50
- Liu G: Revision surgery following cervical laminoplasty: Etiology and treatment strategies. *Spine*, 2009; 34: 2760–68
- Sakai K: Impact of the surgical treatment for degenerative cervical myelopathy on the preoperative cervical sagittal balance: A review of prospective comparative cohort between anterior decompression with fusion and laminoplasty. *Eur Spine J*, 2007; 26: 104–12

Conflict of interest

None.

8. Lee CH, Jahng TA, Hyun SJ et al: Expansive laminoplasty versus laminectomy alone versus laminectomy and fusion for cervical ossification of the posterior longitudinal ligament: Is there a difference in the clinical outcome and sagittal alignment? *Clin Spine Surg*, 2016; 29: E9–15
9. Sakaura H: Preservation of the nuchal ligament plays an important role in preventing unfavorable radiologic changes after laminoplasty. *J Spinal Disord Tech*, 2008; 21: 338–43
10. Baba H, Maezawa Y, Furusawa N et al: Flexibility and alignment of the cervical spine after laminoplasty for spondylotic myelopathy. A radiographic study. *Int Orthop*, 1995; 19: 116–21
11. Kawaguchi Y: Minimum 10-year followup after en bloc cervical laminoplasty. *Clin Orthop Relat Res*, 2003; 411: 129–39
12. Miyamoto H: Outcomes of surgical intervention for cervical spondylotic myelopathy accompanying local kyphosis (comparison between laminoplasty alone and posterior reconstruction surgery using the screw-rod system). *Eur Spine J*, 2014; 23: 341–46
13. Lee SE, Chung CK, Jahng TA et al: Long-term outcome of laminectomy for cervical ossification of the posterior longitudinal ligament. *J Neurosurg Spine*, 2013; 18: 465–71
14. Kaptain GJ, Simmons NE, Replogle RE et al: Incidence and outcome of kyphotic deformity following laminectomy for cervical spondylotic myelopathy. *J Neurosurg*, 2000; 93: 199–204
15. Uchida K: Cervical spondylotic myelopathy associated with kyphosis or sagittal sigmoid alignment: outcome after anterior or posterior decompression. *J Neurosurg Spine*, 2009; 11: 521–28
16. Chiba K: Impact of longitudinal distance of the cervical spine on the results of expansive open-door laminoplasty. *Spine*, 2000; 25: 2893–98
17. Yeh KT, Lee RP, Chen IH et al: Laminoplasty instead of laminectomy as a decompression method in posterior instrumented fusion for degenerative cervical kyphosis with stenosis. *J OrthopSurg Res*, 2005; 10: 138
18. Suda K: Local kyphosis reduces surgical outcomes of expansive open-door laminoplasty for cervical spondylotic myelopathy. *Spine*, 2003; 28: 1258–62
19. Motosuneya T, Maruyama T, Yamada H et al: Long-term results of tension-band laminoplasty for cervical stenotic myelopathy: A ten-year follow-up. *J Bone Joint Surg Br*, 2011; 93: 68–72
20. Tetreault L, Ibrahim A, Cote P et al: A systematic review of clinical and surgical predictors of complications following surgery for degenerative cervical myelopathy. *J Neurosurg Spine*, 2016; 24: 77–99
21. Kawaguchi Y: Serum biomarkers in patients with ossification of the posterior longitudinal ligament (OPLL): Inflammation in OPLL. *PLoS One*, 2017; 12: e0174881
22. Wilson JR: Frequency, timing, and predictors of neurological dysfunction in the nonmyelopathic patient with cervical spinal cord compression, canal stenosis, and/or ossification of the posterior longitudinal ligament. *Spine*, 2013; 38: S37–54
23. Shigematsu H: Increased segmental range of motion is correlated with spondylolisthesis in the cervical spine after laminoplasty. *Spine*, 2017; 42: E385–91
24. Shin JW: Predictors of outcome in patients with cervical spondylotic myelopathy undergoing unilateral open-door laminoplasty. *Korean J Spine*, 2015; 12: 261–66
25. Katsumi K: Posterior instrumented fusion suppresses the progression of ossification of the posterior longitudinal ligament: A comparison of laminoplasty with and without instrumented fusion by three-dimensional analysis. *Eur Spine J*, 2016; 25: 1634–40
26. Ota M: Addition of instrumented fusion after posterior decompression surgery suppresses thickening of ossification of the posterior longitudinal ligament of the cervical spine. *J ClinNeurosci*, 2016; 34: 162–65
27. Yeh KT: Laminoplasty with adjunct anterior short segment fusion for multi-level cervical myelopathy associated with local kyphosis. *J Chin Med Assoc*, 2015; 78: 364–69
28. Grob D, Frauenfelder H, Mannion AF: The association between cervical spine curvature and neck pain. *Eur Spine J*, 2007; 16: 669–78
29. Hyun SJ, Rhim SC, Roh SW et al: The time course of range of motion loss after cervical laminoplasty: A prospective study with minimum two-year follow-up. *Spine*, 2009; 34: 1134–39
30. Fujimori T, Le H, Ziewacz JE et al: Is there a difference in range of motion, neck pain, and outcomes in patients with ossification of posterior longitudinal ligament versus those with cervical spondylosis, treated with plated laminoplasty? *Neurosurg Focus*, 2013; 35: E9
31. Maruo K: The impact of dynamic factors on surgical outcomes after double-door laminoplasty for ossification of the posterior longitudinal ligament of the cervical spine. *J NeurosurgSpine*, 2014; 21: 938–43
32. Matsumoto M, Chiba K, Toyama Y: Surgical treatment of ossification of the posterior longitudinal ligament and its outcomes: Posterior surgery by laminoplasty. *Spine*, 2012; 37: E303–8
33. Sakai K: Cervical sagittal imbalance is a predictor of kyphotic deformity after laminoplasty in cervical spondylotic myelopathy patients without pre-operative kyphotic alignment. *Spine*, 2016; 41: 299–305.