

Endoscopic Resection of Gastrointestinal Neuroendocrine Tumors: Long-Term Outcomes and Comparison of Endoscopic Techniques

Pedro Pimentel-Nunes^{a, b, c} Raquel Ortigão^a Luís Pedro Afonso^d
Rui Pedro Bastos^a Diogo Libânio^{a, c} Mário Dinis-Ribeiro^{a, c}

^aDepartment of Gastroenterology, Portuguese Oncology Institute – Porto, Porto, Portugal; ^bDepartment of Surgery and Physiology, Porto Faculty of Medicine, Porto, Portugal; ^cCINTESIS/Biostatistics and Medical Informatics, Porto Faculty of Medicine, Porto, Portugal; ^dDepartment of Pathology, Portuguese Oncology Institute – Porto, Porto, Portugal

Keywords

Neuroendocrine tumours · Survival · Endoscopic mucosal resection · Endoscopic submucosal dissection

Abstract

Introduction: Gastrointestinal neuroendocrine tumors (GI-NETs) are being more frequently diagnosed and treated by endoscopic resection (ER) techniques. However, comparison studies of the different ER techniques or long-term outcomes are rarely reported. **Methods:** This was a single-center retrospective study analyzing short and long-term outcomes after ER of gastric, duodenum, and rectal GI-NETs. Comparison between standard EMR (sEMR), EMR with a cap (EMRc), and endoscopic submucosal dissection (ESD) was made. **Results:** Fifty-three patients with GI-NET (25 gastric, 15 duodenal, and 13 rectal; sEMR = 21; EMRc = 19; ESD = 13) were included in the analysis. Median tumor size was 11 mm (range 4–20), significantly larger in the ESD and EMRc groups compared to the sEMR group ($p < 0.05$). Complete ER was possible in all cases with 68% histological complete resection (no difference between the groups). Complication rate was significantly higher in the EMRc group (EMRc 32%, ESD 8%, and EMRs 0%, $p = 0.01$). Local recurrence occurred in only one

patient, and systemic recurrence in 6%, with size ≥ 12 mm being a risk factor for systemic recurrence ($p = 0.05$). Specific disease-free survival after ER was 98%. **Conclusion:** ER is a safe and highly effective treatment particularly for less than 12 mm luminal GI-NETs. EMRc is associated with a high complication rate and should be avoided. sEMR is an easy and safe technique that is associated with long-term curability, and it is probably the best therapeutic option for most luminal GI-NETs. ESD appears to be the best option for lesions that cannot be resected en bloc with sEMR. Multicenter, prospective randomized trials should confirm these results.

© 2022 The Author(s).
Published by S. Karger AG, Basel

Exérese endoscópica de tumores neuroendócrinos gastrointestinais: resultados a longo prazo e comparação de técnicas endoscópicas

Palavras Chave

Tumores neuroendócrinos · Sobrevida · Ressecção endoscópica da mucosa · Dissecção endoscópica da submucosa

Resumo

Introdução: Os tumores neuroendócrinos gastrointestinais (GI-NET) são frequentemente diagnosticados e tratados por técnicas de ressecção endoscópica (ER). Contudo, estudos comparativos das diferentes técnicas de ER ou resultados a longo prazo são raramente descritos. **Métodos:** Estudo unicêntrico retrospectivo que analisa resultados a curto e longo prazo após ER de NETs gástricos, duodenais e retais. Realizou-se uma análise comparativa entre as técnicas de mucosectomia convencional (sEMR), mucosectomia com cap (EMRc) e disseção endoscópica da submucosa (ESD). **Resultados:** Foram incluídos 53 doentes com GI-NET (25 gástricos, 15 duodenais e 13 retais; sEMR=21; EMRc=19; ESD=13). A mediana do tamanho da lesão foi 11 mm (âmbito 4-20), sendo significativamente maiores nos grupos ESD e EMRc quando comparado com sEMR ($p < 0.05$). A ER completa foi possível em todos os casos com taxa de ressecção histológica completa de 68% (sem diferença entre os grupos). A taxa de complicações foi significativamente superior no grupo EMRc (EMRc 32%, ESD 8% e EMRs 0%, $p = 0.01$). Recorrência local apenas ocorreu em 1 doente e recorrência sistémica em 6%, com o tamanho da lesão ≥ 12 mm a ser um factor de risco para recorrência sistémica ($p = 0.05$). Sobrevida específica de doença após ER de 98%. **Conclusão:** ER é segura e altamente eficaz para o tratamento de GI-NETs principalmente com tamanho inferior a 12 mm. EMRc está associada a uma taxa de complicações elevada e deve ser evitada. sEMR é uma técnica segura e eficaz que se associa a curabilidade a longo prazo, sendo provavelmente a melhor opção terapêutica para a maioria dos GI-NETs luminiais. ESD parece ser a melhor opção para as lesões que não podem ser removidas em bloco pela técnica de sEMR. Estudos randomizados, prospectivos e multicêntricos devem confirmar estes resultados.

© 2022 The Author(s).
Published by S. Karger AG, Basel

Introduction

Neuroendocrine tumors (NET) are relatively uncommon gastrointestinal (GI) tract neoplasias, with a global annual age-adjusted incidence rate of 2/100,000 people per year [1]. However, the widespread use of endoscopy has led to increased detection of luminal GI, often at initial stages of disease. Not surprisingly, the majority of these initial stage GI-NETs are from the stomach, duodenum, and rectum, the most accessible areas to endoscopic exploration [2].

GI-NETs are classified as NET G1, NET G2 (both considered well-differentiated), and neuroendocrine carcinoma (NEC) G3 (poorly differentiated) based on the mitotic count and Ki-67 index [3]. Even though tumor grade is one of the most important prognostic factors (that is only correctly defined after resection), the size of the tumor is also an independent prognostic factor, increasing the risk of lymph node metastasis [4]. For this reason, most guidelines only recommend endoscopic resection (ER) as a treatment for small GI-NET, usually with less than 10–15 mm depending on the location, with every GI-NET larger than 2 cm being considered for surgery [4, 5].

Several studies and meta-analyses confirm the safety and effectiveness of ER for small GI-NETs. However, these studies include a small number of patients, and rarely long-term outcomes are reported [6–9]. Moreover, to our knowledge, no single study compared short- or long-term outcomes of the standard inject-and-cut endoscopic mucosal resection (sEMR) with more complex techniques such as EMR with a cap (EMRc) or endoscopic submucosal dissection (ESD).

In this retrospective study, we analyze long-term outcomes after ER of GI-NETs in the stomach, duodenum, and rectum. Moreover, we compare the short and long-term outcomes of the different ER methods.

Materials and Methods

Patients and Lesions

A retrospective observational study was performed. Pathological database of the Portuguese Oncology Institute of Porto was searched for GI-NETs diagnosed between 2010 and 2020. After evaluation of the pathological report, patients with non-GI NET, pancreatic, small bowel (with the exception of duodenum), appendix, or colonic (with the exception of rectum) NET were excluded from the analysis. The clinical records of all the other patients were analyzed. At this stage, additional exclusion criteria were non-endoscopic initial treatment (surgery or somatostatin analogs), GI-NET only present in biopsies, endoscopic diagnosis/treatment only with cold or hot-snare resection (without submucosal injection), endoscopic treatment at other hospital, or less than 12-month follow-up. At the end, only patients with GI-NET from stomach, duodenum, or rectum treated in our institute by sEMR, EMRc, or ESD with at least 1 year of follow-up were included in the analysis. In Figure 1, we can see the flowchart for patient enrolment.

ER Procedures

Standard EMR (EMRs) was defined as the conventional technique of tumor resection with hot snare technique after submucosal injection with normal saline and diluted adrenaline (1:10,000 to 1:50,000 dilution) (Fig. 2). EMRc was performed with a transparent cap (Olympus, reusable oblique cap) at the tip of conven-

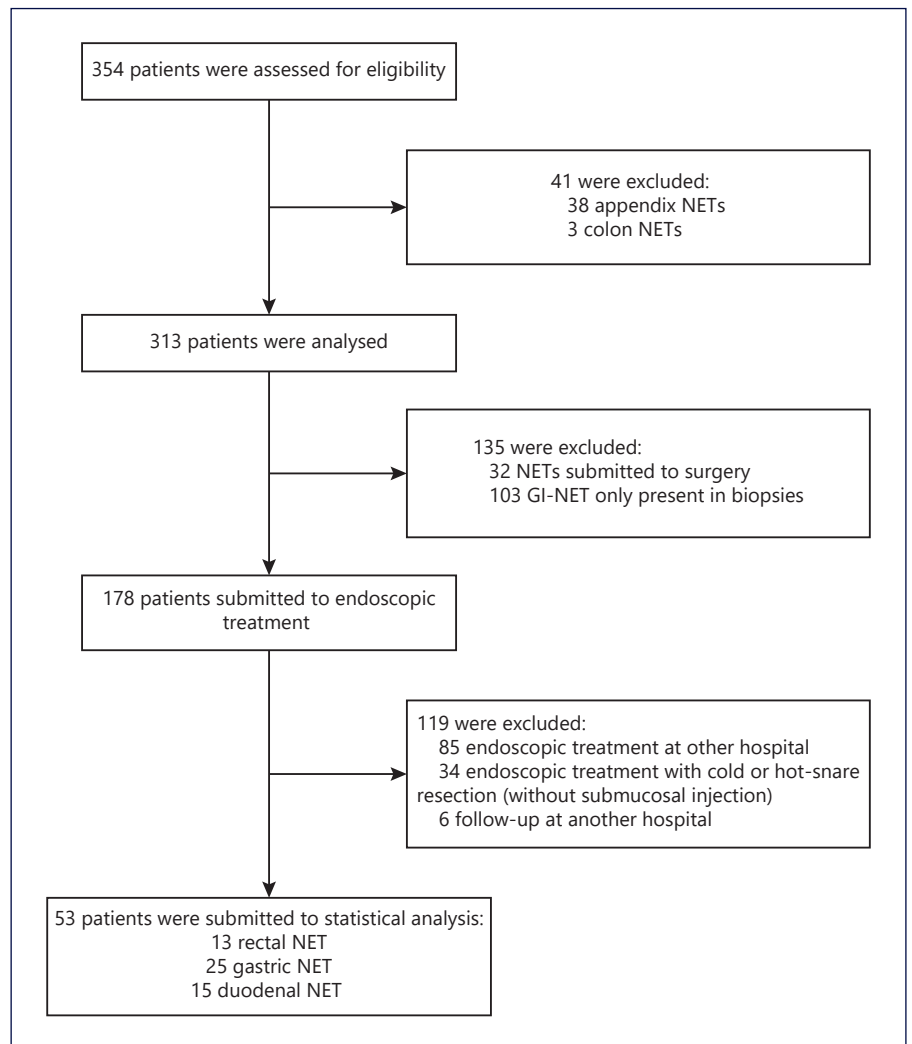


Fig. 1. Patient selection flowchart. NET, neuroendocrine tumor; GI-NET, gastrointestinal neuroendocrine tumor.

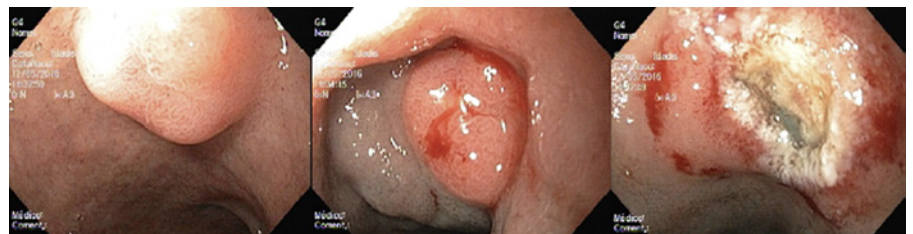

Fig. 2. Endoscopic mucosal resection of a 12-mm subepithelial lesion of the duodenal bulb.

tional upper GI endoscope and a crescent-type snare (EMR snare, Olympus). Hot-snare resection was done after submucosal injection with normal saline and diluted adrenaline (1:10,000 to 1:50,000 dilution) and suction of the lesion into the cap. ESD was performed as previously described (Fig. 3). Briefly, small coagulation marks were made around the lesion and then submucosal injection was performed with saline, diluted epinephrine (1:50-100,000), and methylene blue. After elevation, 3-4 incisions were made with a needle knife (Olympus®) to get access to the submucosal layer, and an insulated-tip knife (mainly IT-Knife™; Olympus®) was used to perform circumferential dissection using the Endo Cut mode

(Olympus electrosurgical unit, 80/60 W). Complete dissection was then performed in the Endo Cut or swift coagulation mode, with additional submucosal injection whenever necessary. The procedures were performed mainly under general anesthesia (with orotracheal intubation); deep sedation was restricted to a minority of procedures.

Definitions and Follow-Up

En bloc ER was defined as ER in one single fragment versus piecemeal resection defined as two or more fragments ER. Complete ER was defined as no evidence of macroscopic disease after

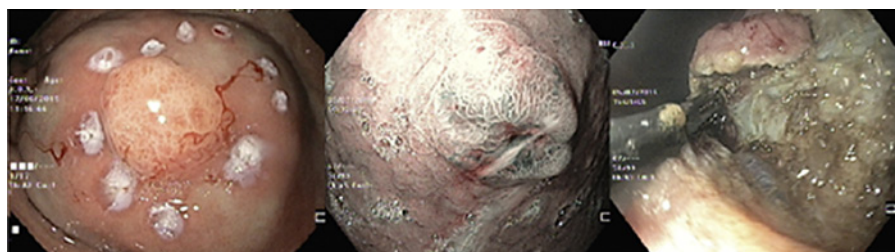


Fig. 3. Endoscopic submucosal dissection of a 12-mm gastric lesion.

Table 1. Patient characteristics

	Gastric lesions (n = 25)	Duodenal lesions (n = 15)	Rectal lesions (n = 13)	p	Total (n = 53)
Male, n (%)	12 (48)	9 (60)	5 (38)	ns	26 (49)
Age, median (range), years	60 (38-77)	58 (42-75)	55 (47-66)	ns	59 (38-77)
Tumor size, median (range), mm	12 (5-22)	10 (4-18)	9 (4-15)	0.1	11 (4-20)
<i>WHO TNE type (after ER)</i>				0.03	
Grade 1	12 (48)	12 (80)	11 (85)		35 (66)
Grade 2	13 (52)	3 (20)	2 (15)		18 (34)
Grade 3	0	0	0		0
<i>Gastric TNE</i>					
Type 1	21 (84)	–	–	–	21 (84)
Type 2	0				0
Type 3	4 (16)				4 (16)
<i>ER procedure</i>				0.005	
EMRs	5 (20)	5 (33)	11 (84)		21 (40)
EMRc	11 (44)	7 (47)	1 (7)		19 (36)
ESD	9 (36)	3 (20)	1 (7)		13 (24)

ER, independent of the type of ER (en bloc or piecemeal). Adverse events were defined as immediate (during procedure) or delayed complications (not apparent during the procedure). Bleeding as a complication was defined as intra-procedural bleeding requiring non-planned hemostasis (immediate bleeding) or as melena or hematochezia after the procedure (delayed bleeding), independently if additional interventions were required or not. Perforation was defined as a bowel wall penetration identified during the procedure (immediate perforation) or as symptoms compatible with perforation with imagiological (CT) confirmation of that (delayed perforation). Endoscopic size was defined as the estimated macroscopic size attributed by the gastroenterologist in the endoscopy report.

All the histological findings were evaluated by two pathologists, with at least one of them being experienced in GI-NET evaluation, with each specimen being graded according to the WHO classification [3]. Histological complete resection was defined as margins free of tumor, both lateral and vertical margins. Histological maximum size of the lesion was considered as the maximum diameter from one side to the other.

All patients were followed-up with periodic endoscopy (at least one per year), serum chromogranin A (at least one per year) and

imagiological methods, generally PET-CT with somatostatin receptors markers (as needed). Local recurrence was defined as histologically confirmed disease at the site of ER, and systemic recurrence as histologically confirmed ganglion, liver and/or another organ NET metastasis.

Statistical Analyses

Data were expressed as mean + standard deviation or as median and interquartile range (according to the dispersion) for continuous variables and as frequencies and/or proportions for categorical variables. Differences in outcomes were compared using independent *t* tests for numerical variables and χ^2 tests for categorical variables (p values were considered significant if they were <0.05). Multivariable logistic regression model was constructed to identify risk factors for systemic recurrence (including age, sex and variables with *p* < 0.20 at univariable analysis). All statistical analyses were performed using the Statistical Package for the Social Sciences (SPSS) software (version 27.0; IBM Corp., Armonk, NY, USA).

Table 2. Clinical outcomes of the different ER procedures

	EMRs (n = 21)	EMRc (n = 19)	ESD (n = 13)	p	Total (n = 53)
Endoscopic tumor size, mm	8.7 (3.9)	11.1 (3.7)	12.3 (3.2)	0.06 (EMRs vs. EMRc) 0.008 (EMRs vs. ESD) 0.3 (EMRc vs. ESD)	10.5 (3.9)
ER specimen, mm	9.7 (4.8)	15.2 (3.4)	21.9 (8.3)	<0.001 (all comparisons)	14.6 (6.7)
Complete ER	21 (100)	19 (100)	13 (100)	0.4	53 (100)
En bloc	21 (100)	18 (95)	13 (100)		52 (98)
Piecemeal	0 (0)	1 (5)	0 (0)		1 (2)
Histological complete resection*	15 (71)	12 (63)	9 (69)	0.15	36 (68)
Vertical margins +	4 (19)	7 (37)	4 (31)	0.4	15 (28)
Horizontal margins +	4 (19)	1 (5)	1 (8)	0.3	6 (11)
Procedure time, min	7.8 (3)	21 (16)	57 (21.3)	<0.001 (all comparisons)	24.7 (24.1)
Complications	0 (0)	6 (32)	1 (8)	0.01	7 (13)
Bleeding	0 (0)	3 (16)	0 (0)	0.03	3 (6)
Perforation	0 (0)	3 (16)	1 (8)	0.04	4 (8)
Surgery (because of)	0 (0)	0 (0)	1 (8)	0.4	1 (2)
<i>TNE location</i>				0.003	
Gastric	5 (24)	11 (58)	9 (69)		25 (47)
Duodenum	5 (24)	7 (37)	3 (23)		15 (28)
Rectal	11 (52)	1 (5)	1 (7)		13 (25)

Data presented as N (%) or as mean (SEM). * Histological complete resection implies both V and H margins negative – the number of V+ plus H+ might be higher than incomplete histological resection since some specimens may be both V+ and H+.

Table 3. Distant recurrence cases

	Location (and type if gastric)	Endoscopic/ histological size, mm	NET grade	Vertical margin	Lymphovascular invasion
Case 1	Gastric type 1	12/25	G2	V1	LV1
Case 2	Gastric type 3	20/30	G1	V0	LV0
Case 3	Duodenum	12/20	G2	V0	LV0

Results

Patient and Lesion Baseline Characteristics

A total of 53 patients were included in the analysis (Table 1). The median age was 58 years old and 49% were male, with no differences between the groups. The median size of the lesions was 11 mm (4 minimum, 20 maximum) with a non-significant trend for larger lesions in the stomach group. Only NETs grade 1 on biopsies were considered for ER (with a histological upgrade in the resection specimen to grade 2 lesions in 34% of the lesions). Twenty per cent of gastric NETs were type 3 and both this feature and size translated into more advanced lesions in

the stomach group (52% grade 2 lesions vs. 20% and 15% in the duodenum and rectum, respectively, $p = 0.003$). Endoscopic ultrasound (EUS) was performed in 51% of the patients, generally for lesions bigger than 10 mm.

Clinical Outcomes

The clinical outcomes of the different ER methods are summarized in Table 2. In general, EMRs was used for smaller lesions. There were no differences between the techniques regarding complete endoscopic and histological resection, with only one lesion being resected in piecemeal in the EMRc group. Even though complete ER was always achieved, histological complete resection rate was only of

Table 4. Risk factors for distant recurrence

	No recurrence (n = 50)	Recurrence (n = 3)	p	Multivariate
Age, mean (SD)	55.3 (12.9)	55.3 (12.8)	0.60	
Endoscopic size, median (range), mm	10.0 (4 – 20)	12 (12-20)	0.05	
Procedural time, min (mean, SD)	23.4 (24.1)	46.7 (15.3)	0.11	0.662
Maximum histological size, median (range), mm	14.5 (4.0-25.0)	25 (20-30)	0.004	
<i>Sex</i>			0.61*	
Male	24 (92.3%)	2 (7.7%)		
Female	26 (96.3%)	1 (3.7%)		
<i>Technique</i>			0.17 [#]	0.852
EMR-std	21 (100%)	0 (0%)		
EMR-cap	18 (94.7%)	1 (5.3%)		
ESD	11 (84.6%)	2 (15.4%)		
<i>Maximum histological size</i>			0.004	0.997
<20 mm	39 (100%)	0 (0%)		
≥20 mm	11 (78.6%)	3 (21.4%)		
<i>Location</i>			0.56 [#]	
Stomach	23 (92%)	2 (8%)		
Duodenum	14 (93.3%)	1 (6.7%)		
Rectum	13 (100%)	0 (0%)		
<i>NET type (gastric)</i>			0.31*	
Type I	19 (95%)	1 (5%)		
Type III	3 (75%)	1 (25%)		
<i>Ulcer</i>			0.51*	
No	40 (95.2%)	2 (4.8%)		
Yes	10 (90.9%)	1 (9.1%)		
<i>En bloc</i>			0.80	
No	1 (100%)	0 (0%)		
Yes	49 (94.2%)	3 (5.9%)		
<i>Grade</i>			0.26*	0.386
G1	34 (97.1%)	1 (2.9%)		
G2	16 (88.9%)	2 (11.8%)		
<i>Invasion depth</i>			0.785 [#]	
Mucosa	4 (100%)	0 (0%)		
Submucosa	43 (93.5%)	3 (6.5%)		
Muscularis propria	3 (100%)	0 (0%)		
<i>Horizontal margin</i>			0.816 [#]	
HM0	44 (93.6%)	3 (6.4%)		
HM1	3 (100%)	0		
HMx	3 (100%)	0		
<i>Vertical margins</i>			0.938 [#]	
VM0	36 (94.7%)	2 (5.3%)		
VM1	13 (92.9%)	1 (7.1%)		
VMx	1 (100%)	0 (0%)		
<i>Lymphovascular invasion</i>			0.51*	0.826
LV0	40 (95.2%)	2 (4.8%)		
LV1	10 (90.9%)	1 (9.1%)		
<i>R</i>			0.89 [#]	0.775
R0	34 (94.4%)	2 (5.6%)		
R1	13 (92.9%)	1 (7.1%)		
Rx	3 (100%)	0		

SD, standard deviation; EMR, endoscopic mucosal resection; ESD, endoscopic submucosal dissection; std, standard/lift-and-cut; NET, neuroendocrine tumor. * Fisher's exact test. [#] χ^2 test.

68% (no differences between the groups). ESD was significantly longer than EMRc and EMRc significantly longer than EMRs (57, 21, and 8 min, respectively, $p < 0.001$). The complication rate was significantly higher in the EMRc group (2 duodenal and 1 gastric perforation) when compared to the other two groups (EMRc 32%, ESD 8% and EMRs 0%, $p = 0.01$). However, surgery because of complication was only needed in one patient, after duodenal ESD.

Follow-Up

The mean follow-up was 44.6 months (range 12-102 months, no differences between the ER groups), and in this period there was only one local recurrence (2%), which was treated by another ER. There were 6 new lesions identified and treated by ER, all type 1 lesions in the stomach. Systemic recurrence occurred in 3 patients (1 only nodal and 2 liver and nodal disease, one of this with carcinoid syndrome), one case of type 1 gastric, other case type 3 gastric, and one duodenal NET. The mean time between diagnosis and systemic recurrence was 9 months (range 6-12 months). Only the duodenal NET patient with systemic recurrence died because of NET (after surgical treatment). Three additional patients died during follow-up due to NET-unrelated causes (specific disease-free survival 98%, global survival 92%).

Risk Factors for Recurrence

There was only one local recurrence, a 4-mm recurrence 3 years after R1 resection of type 1 gastric TNE that was treated effectively by hot snare technique. There was no statistically significant risk factor for local recurrence. Only one out of 17 (6%) R1 resections locally recurred.

Distant recurrence occurred in 3 patients (Table 3). The only identified risk factors for distant recurrence (Table 4) were the ones related to the size of lesion. Median endoscopic size of the lesions that recurred was 12 mm ($p = 0.05$) with all the recurrent lesions having a maximum histological size larger or equal to 20 mm ($p = 0.004$). Histological maximum size was the strongest risk factor for distant recurrence ($p = 0.004$).

For metachronous lesions, the only risk factor was type 1 gastric NET ($p < 0.001$).

Discussion

GI-NETs are being more frequently diagnosed and treated by ER methods. Even though several studies show the effectiveness and safety of different ER methods for the treatment of GI NETs, long-term outcomes are rarely

described. To our knowledge this is the first study that focuses on long-term outcomes after several ER methods for the treatment of luminal GI NETs. Our results confirm that ER should be a first-line therapy for small GI NETs providing curability in most cases.

There are some limitations to our study. First, we have a relatively small sample size of 53 patients. Secondly, by including all the organs we should be careful to interpret and generalize our results. Thirdly, even though similar, follow-up was not standardized between patients and so recurrence data should be interpreted with caution. Fourthly, band-EMR was not applied in any case, and so no conclusion can be made about this technique. Finally, the retrospective nature of the study should limit our conclusions regarding comparison of the several ER methods since selection bias is highly likely. Nevertheless, our study has several strengths. To our knowledge, it is the first study to focus on long-term outcomes after ER of luminal GI-NETs. We show that, independently of the organ, ER is a safe and highly effective therapy for small luminal GI-NETs. Moreover, we provide comparative data of 3 different ER methods that were rarely addressed in the literature. Our results show that EMRc should be avoided for the treatment of GI-NET since the risk of complications appears too high to justify this technique. Even though most complications can be handled endoscopically, they prolong hospitalization of our patients with greater costs, and if safer techniques are available, they should be preferred. Our results also demonstrate that, independently of the technique and margins, if ER is complete, local and distant recurrence is highly unlikely and does not seem to affect the global prognosis of these patients.

In a per-organ analysis for gastric NET, there are only few comparative studies of ER methods, all of them with a limited number of cases. Kim et al. [10] compared EMR and ESD in type I g-NETs and showed a higher complete resection and higher complication rate for ESD (both non-significant). Based on this, they concluded that ESD might be a better option for the treatment of gastric NET. However, no clinical advantage was seen in this study. In fact, other studies found no tumor recurrence after ER (EMR and ESD) during the follow-up of gastric NET G1/G2, even in patients with positive margins [11, 12]. This is in accordance with our results that showed that the importance of positive margins after complete ER regarding clinical and long-term outcomes is probably minimal since there was only one local recurrence after R1 resection (6% risk), and a small easily to treat recurrence. Regarding type 3

(sporadic) gastric NETs most guidelines still consider surgery as the best approach [3, 4]. However, Kwon et al. [13] suggested that ER can be safely performed in type 3 gastric NETs if <20 mm, G1 grading, confined to SM, and without lymphovascular invasion. In accordance, we were able to treat efficaciously 3 out of 4 type 3 gastric NET, with the only type 3 tumor that recurred systemically being a >15-mm tumor (the other 3 were 10- to 13-mm lesions). Even though these results should be interpreted cautiously, these 2 studies suggest that at least for <15-mm type 3 lesions, ER (particularly by ESD) may be a safe option.

For duodenal NETs, there are only some series, and they all include a small number of patients and a short long-term follow-up. Even though complete resection rates are high for both EMR and ESD, ESD perforation rates in the duodenum appear exceedingly high (>20%) [14–16]. In fact, our ESD duodenal perforation rate in our study was 1 in 3 (33%), and we now favor EMR-based techniques for duodenal NET ER.

For ER of rectal NET, the number of studies is considerable with evidence gathered in some meta-analyses (even though substantiated mostly on single-center studies with small groups of patients) [7, 8]. Based on significantly higher complete pathological rates both with modified EMR techniques and ESD compared to sEMR, with a similar safety profile, the authors concluded that modified EMR techniques and ESD should be preferred over sEMR. Despite this conclusion, long-term clinical outcomes were not different between the groups, with local recurrences being exceedingly rare (0.89%) even after incomplete pathological resection [7]. In fact, in our study most rectal NETs were treated by sEMR, and despite only 70% complete pathological resection rate, all patients were cured with no long-time local or systemic recurrence.

Taking all together, regarding short-term outcomes, all ER methods were highly efficacious in treating small luminal GI-NETs. Even though we did not find higher complete pathological rates, EMRc and ESD were selected for bigger and depressed lesions, particularly ESD, as they are associated with a significantly bigger specimen size. EMRc was associated with a significantly higher complication rate and, in our opinion, should be avoided in the treatment of luminal GI-NET. So, for most gastric, duodenal, and rectal lesions <10–12 mm in size, sEMR probably should be favored over ESD if lesion characteristics suggest that en bloc complete ER is feasible. If the lesion size is >12 mm or if the lesion shows depressed morphology, then ESD, even though more cumbersome, should be preferred over sEMR at least in the stomach

and rectum, since in the duodenum the high perforation rates make it prohibitive.

Regarding long-term outcomes, our study suggests high curative rates after successful ER of small luminal GI-NETs. Local or systemic recurrences are an exception even after R1 resections. Thus, in our opinion, positive margins after a complete ER should not guide further treatments or significantly influence further management. However, lesion size >12 mm significantly increases the risk of systemic recurrence. So, in these cases, before considering ER, multidisciplinary evaluation is advised. Nevertheless, even for these lesions, ER should be an option, particularly if the location of the tumor may imply a more aggressive surgery and/or when the patient is not fit for surgery. Furthermore, since maximum histological size is the strongest risk factor for recurrence, if after ER maximum histological size is at least 20 mm, consideration should be given to additional treatments in a multidisciplinary discussion. If ER is decided for these lesions, frequent (annual/bi-annual or as clinical needed) imagiological (e.g., PET-CT) follow-up is advised since the risk of systemic recurrence is high. Regarding endoscopic surveillance, our results suggest that besides type 1 gastric NETs, there is no need for a strict endoscopic follow-up, since local recurrence or new lesions are exceedingly rare. We recommend endoscopy 1 year after ER and, if there is no evidence of local recurrence, there is probably no need for further endoscopic surveillance (if positive margins are present, endoscopy 3–5 years after resection might be considered).

In conclusion, ER is a safe and highly effective treatment particularly for <12-mm luminal GI-NETs and when the maximum histological size post-ER is <20 mm. sEMR is an easy and safe technique that is associated with long-term curability, even if there are positive margins, and it is probably the best therapeutic option for most luminal GI-NETs. ESD appears to be the best option for lesions that cannot be removed en bloc with sEMR. Multi-center, prospective randomized trials evaluating long-term outcomes should confirm these results before strict recommendations can be made.

Statement of Ethics

This study was approved by the ethical committee of the Portuguese Oncology Institute of Porto in 2020 (CES 44/021).

Conflict of Interest Statement

The authors have no conflicts of interest to declare.

Funding Sources

None.

Author Contributions

P.P.-N. is the guarantor of the article and participated in all aspects of the work; L.P.A. performed the pathological evaluation of all lesions and wrote the paper; R.O., R.P.B., D.L., and M.D.-R. designed and performed the research and wrote the paper

Data Availability Statement

Data available upon request.

References

- 1 Niederle MB, Hackl M, Kaserer K, Niederle B. Gastroenteropancreatic neuroendocrine tumours: the current incidence and staging based on the WHO and European Neuroendocrine Tumour Society classification: an analysis based on prospectively collected parameters. *Endocr Relat Cancer*. 2010 Dec; 17(4):909–18.
- 2 Dasari A, Shen C, Halperin D, Zhao B, Zhou S, Xu Y, et al. Trends in the incidence, prevalence, and survival outcomes in patients with neuroendocrine tumors in the United States. *JAMA Oncol*. 2017 Oct 1;3(10):1335–42.
- 3 Clark OH, Benson AB 3rd, Berlin JD, Choti MA, Doherty GM, Engstrom PF, et al. NCCN clinical practice guidelines in oncology: neuroendocrine tumors. *J Natl Compr Canc Netw*. 2009 Jul;7(7):712–47.
- 4 Delle Fave G, Kwekkeboom DJ, Van Cutsem E, Rindi G, Kos-Kudla B, Knigge U, et al. ENETS consensus guidelines for the management of patients with gastroduodenal neoplasms. *Neuroendocrinology*. 2012;95(2):74–87.
- 5 Oberg K, Knigge U, Kwekkeboom D, Perren A, Group EGW. Neuroendocrine gastro-entero-pancreatic tumors: ESMO clinical practice guidelines for diagnosis, treatment and follow-up. *Ann Oncol*. 2012 Oct;23 Suppl 7: vii124–30.
- 6 Bang CS, Baik GH, Shin IS, Suk KT, Yoon JH, Kim DJ. Endoscopic submucosal dissection of gastric subepithelial tumors: a systematic review and meta-analysis. *Korean J Intern Med*. 2016 Sep;31(5):860–71.
- 7 Zhang HP, Wu W, Yang S, Lin J. Endoscopic treatments for rectal neuroendocrine tumors smaller than 16 mm: a meta-analysis. *Scand J Gastroenterol*. 2016 Nov;51(11):1345–53.
- 8 Pan J, Zhang X, Shi Y, Pei Q. Endoscopic mucosal resection with suction vs. endoscopic submucosal dissection for small rectal neuroendocrine tumors: a meta-analysis. *Scand J Gastroenterol*. 2018 Sep;53(9):1139–45.
- 9 Zheng JC, Zheng K, Zhao S, Wang ZN, Xu HM, Jiang CG. Efficacy and safety of modified endoscopic mucosal resection for rectal neuroendocrine tumors: a meta-analysis. *Z Gastroenterol*. 2020 Feb;58(2):137–45.
- 10 Kim HH, Kim GH, Kim JH, Choi MG, Song GA, Kim SE. The efficacy of endoscopic submucosal dissection of type I gastric carcinoid tumors compared with conventional endoscopic mucosal resection. *Gastroenterol Res Pract*. 2014;2014:253860.
- 11 Uygun A, Kadayifci A, Polat Z, Yilmaz K, Gunal A, Demir H, et al. Long-term results of endoscopic resection for type I gastric neuroendocrine tumors. *J Surg Oncol*. 2014 Feb; 109(2):71–4.
- 12 Jung HJ, Hong SJ, Han JP, Kim HS, Jeong GA, Cho GS, et al. Long-term outcome of endoscopic and surgical resection for foregut neuroendocrine tumors. *J Dig Dis*. 2015 Oct; 16(10):595–600.
- 13 Kwon YH, Jeon SW, Kim GH, Kim JI, Chung IK, Jee SR, et al. Long-term follow up of endoscopic resection for type 3 gastric NET. *World J Gastroenterol*. 2013 Dec 14;19(46):8703–8.
- 14 Matsumoto S, Miyatani H, Yoshida Y, Nokubi M. Duodenal carcinoid tumors: 5 cases treated by endoscopic submucosal dissection. *Gastrointest Endosc*. 2011 Nov;74(5):1152–6.
- 15 Suzuki S, Ishii N, Uemura M, Deshpande GA, Matsuda M, Iizuka Y, et al. Endoscopic submucosal dissection (ESD) for gastrointestinal carcinoid tumors. *Surg Endosc*. 2012 Mar; 26(3):759–63.
- 16 Kim GH, Kim JI, Jeon SW, Moon JS, Chung IK, Jee SR, et al. Endoscopic resection for duodenal carcinoid tumors: a multicenter, retrospective study. *J Gastroenterol Hepatol*. 2014 Feb;29(2):318–24.