




Lower urinary tract transitional cell carcinoma in cats: Clinical findings, treatments, and outcomes in 118 cases

Maureen A. Griffin¹ | William T. N. Culp¹  | Michelle A. Giuffrida¹ | Peter Ellis¹ | Joanne Tuohy² | James A. Perry³ | Allison Gedney³ | Cassie N. Lux⁴ | Milan Milovancev⁵ | Mandy L. Wallace⁶ | Jonathan Hash⁷ | Kyle Mathews⁷  | Julius M. Liptak⁸ | Laura E. Selmic⁹ | Ameet Singh¹⁰ | Carrie A. Palm¹  | Ingrid M. Balsa¹ | Philipp D. Mayhew¹ | Michele A. Steffey¹ | Robert B. Rebhun¹ | Jenna H. Burton¹ | Michael S. Kent¹

¹School of Veterinary Medicine, University of California-Davis, Davis, California

²College of Veterinary Medicine, Colorado State University, Fort Collins, Colorado

³School of Veterinary Medicine, University of Pennsylvania, Philadelphia, Pennsylvania

⁴College of Veterinary Medicine, University of Tennessee, Knoxville, Tennessee

⁵Carlson College of Veterinary Medicine, Oregon State University, Corvallis, Oregon

⁶College of Veterinary Medicine, University of Georgia, Athens, Georgia

⁷College of Veterinary Medicine, North Carolina State University, Raleigh, North Carolina

⁸VCA Canada—Alta Vista Animal Hospital, Ottawa, Ontario, Canada

⁹College of Veterinary Medicine, University of Illinois, Urbana, Illinois

¹⁰Ontario Veterinary College, University of Guelph, Guelph, Ontario, Canada

Correspondence

William T. N. Culp, University of California-Davis, School of Veterinary Medicine, One Garrod Drive, Davis, CA 95616.
 Email: wculp@ucdavis.edu

Present address

Laura E. Selmic, Department of Veterinary Clinical Sciences, The Ohio State University, College of Veterinary Medicine, Columbus, OH 43210.

Abstract

Background: Lower urinary tract transitional cell carcinoma (TCC) is an important but rarely described disease of cats.

Objectives: To report the clinical characteristics, treatments, and outcomes in a cohort of cats with lower urinary tract TCC and to test identified variables for prognostic relevance.

Animals: One-hundred eighteen client-owned cats with lower urinary tract carcinoma.

Methods: Medical records were retrospectively reviewed to obtain information regarding clinical characteristics, treatments, and outcomes. Recorded variables were analyzed statistically.

Results: Median age of affected cats was 15 years (range, 5.0–20.8 years) and median duration of clinical signs was 30 days (range, 0–730 days). The trigone was the most common tumor location (32/118; 27.1%) as assessed by ultrasound examination, cystoscopy, or both. Treatment was carried out in 73 of 118 (61.9%) cats. Metastatic disease was documented in 25 of 118 (21.2%) cats. Median progression-free survival

Abbreviations: BUN, blood urea nitrogen; CI, confidence interval; COX, cyclooxygenase; FNA, fine-needle aspirate; HR, hazard ratio; IQR, interquartile range; NSAIDs, nonsteroidal anti-inflammatory drugs; OR, odds ratio; TCC, transitional cell carcinoma.

This is an open access article under the terms of the Creative Commons Attribution-NonCommercial-NoDerivs License, which permits use and distribution in any medium, provided the original work is properly cited, the use is non-commercial and no modifications or adaptations are made.

© 2019 The Authors. *Journal of Veterinary Internal Medicine* published by Wiley Periodicals, Inc. on behalf of the American College of Veterinary Internal Medicine.

and survival time for all cats were 113 days (95% confidence interval [CI], 69-153) and 155 days (95% CI, 110-222), respectively. Survival increased significantly ($P < .001$) when comparing cats across the ordered treatment groups: no treatment, treatment without partial cystectomy, and treatment with partial cystectomy. Partial cystectomy (hazard ratio [HR], 0.31; 95% CI, 0.17-0.87) and treatment with nonsteroidal anti-inflammatory drugs (HR, 0.55; 95% CI, 0.33-0.93) were significantly associated with longer survival times.

Conclusions and Clinical Importance: The results support treatment using partial cystectomy and NSAIDs in cats with TCC.

KEYWORDS

bladder, cat, cystectomy, neoplasia, urethra

1 | INTRODUCTION

The urinary bladder is the most common site of urinary tract neoplasia in dogs and the second most common site of urinary tract neoplasia in cats (after renal lymphoma).^{1,2} Transitional cell carcinoma (TCC) is the most prevalent lower urinary tract cancer in dogs, and considerable information regarding TCC is available for dogs, including common anatomical locations of the tumor, risk factors, treatment, and prognosis.³⁻⁹ Many treatment modalities have been described for dogs with TCC.^{3,10-12} When surgery is performed as part of treatment, complete excision of lower urinary tract TCC lesions frequently is not achieved in dogs because of trigonal or urethral location of the tumor or both, “field effect” in which the entire urothelium undergoes malignant transformation and metastatic disease.³ Systemic medical treatment is considered to be a mainstay of treatment in dogs with TCC and typically involves chemotherapy and cyclooxygenase (COX) inhibitors.^{3,10} Radiation therapy (with multiple protocols described) has been utilized to treat TCC in dogs, but results still are reported uncommonly.^{3,11,12} Prognosis for dogs with TCC is strongly associated with the tumor-node-metastasis (TNM) stage at the time of diagnosis.³

In contrast to TCC in dogs, the incidence of TCC in cats is very low and few studies have been published.¹³ The largest retrospective study on TCC in cats to date documented 20 cases.¹⁴ Four of the 20 cats had evidence of metastasis at the time of diagnosis, and treatments pursued included piroxicam administration, chemotherapy, and surgical excision.¹⁴ The median survival time for all cats was 261 days, and 25% of cats were lost to follow-up.¹⁴ Because of an insufficient number of cats that received any given treatment protocol, it was not possible to determine a survival advantage for any specific treatment or combinations of treatments.¹⁴ In addition, risk factors and prognostic indicators could not be identified because of the small sample size of the study.¹⁴

Our objectives were to report the clinical characteristics, treatments, and outcomes in a cohort of cats with TCC of the lower urinary tract and to test identified variables for prognostic relevance. We hypothesized that cats undergoing partial cystectomy as part of the treatment regimen would have an improved prognosis compared to cats that did not undergo partial cystectomy.

2 | MATERIALS AND METHODS

2.1 | Case selection criteria

A retrospective study was performed. The medical record databases of 11 referral veterinary clinics (9 academic teaching hospitals and 2 private practice hospitals) were searched to identify cats with lower urinary tract carcinoma that were presented to clinicians of various specialty disciplines. To be included, cats were required to have cytological or histopathological confirmation of carcinoma from a mass in either the bladder or urethra.

2.2 | Medical records review

Variables obtained from the medical records included signalment, history of lower urinary tract disease, clinical signs and duration of clinical signs, physical examination findings, clinical pathology and urine culture results, diagnostic imaging results, treatments pursued (surgery, nonsteroidal anti-inflammatory drugs (NSAIDs), chemotherapy, radiation therapy, and urethral or ureteral stent placement), documented complications and adverse events, cytology and histopathology results, progression (ie, growth of primary tumor or recurrence) of disease, documentation of metastatic disease, and timing and cause of death. Complications were considered major if they required intensive care, revision surgery, or both; all other complications were considered minor.

2.3 | Statistical analysis

Descriptive statistics were calculated, using tests of skewness and kurtosis to evaluate normal distribution for continuous variables. Multivariable logistic regression was used to model risk factors associated with receiving no treatment. Univariable analyses were performed first and variables with $P < .2$ were tested in the final model. Variables were retained in the multivariable model if $P < .05$ or if incorporation changed odds ratios (OR) by $>15\%$. The Kaplan-Meier product limit method was used to estimate median progression-free survival (time

from initial presentation to the study institution until the first instance of documented progression, regional or distant metastasis, or death) and overall survival (time from initial presentation to the study institution until death). Cats that did not reach these endpoints or were lost to follow-up were censored in the respective analyses. Log rank test for trend across ordered groups was used to compare unadjusted survival across the following treatment groups: no treatment, treatment that did not include partial cystectomy, and treatment that included partial cystectomy. Multivariable COX regression was used to model risk factors associated with overall survival time as measured from the date of initial presentation to the contributing hospital. Similarly, univariable analyses were performed first and variables with $P < .2$ were tested in the final model. Variables were retained in the multivariable model if $P < .05$ or if incorporation changed hazard ratios (HR) by $>15\%$. Statistical software (Stata version 14.2, College Station, Texas) was used for all analyses, and $P < .05$ was considered statistically significant.

3 | RESULTS

3.1 | Cats

Between 1991 and 2018, 118 cats from 11 institutions met inclusion criteria. The contributing veterinary clinics were as follows: University of California-Davis, School of Veterinary Medicine; Colorado State University, College of Veterinary Medicine; University of Pennsylvania, School of Veterinary Medicine; University of Tennessee, College of Veterinary Medicine; Oregon State University, Carlson College of Veterinary Medicine; University of Georgia, College of Veterinary Medicine; North Carolina State University, College of Veterinary Medicine; VCA Canada—Alta Vista Animal Hospital; University of Illinois, College of Veterinary Medicine; University of Guelph, Ontario Veterinary College; and, Blue Pearl, Seattle Veterinary Specialists. The median age of included cats was 15.0 years (interquartile range [IQR], 13.0-17.0; range, 5.0-20.8 years). Cat breeds included 74 of 118 (62.7%) domestic shorthair, 18 of 118 (15.3%) domestic longhair, 10 of 118 (8.5%) domestic medium hair, 5 of 118 (4.2%) Siamese or Siamese Cross, and 2 of 118 (1.7%) each of Abyssinian, Persian, and Himalayan; 5 of 118 (4.2%) cats were other breeds. Sex included 62 of 117 (53.0%) spayed females, 54 of 117 (46.2%) castrated males, and 1 of 117 (0.9%) intact female; sex data was not provided for 1 cat.

3.2 | Lower urinary tract disease history and clinical signs

A history of urinary tract infection was present in 28 of 118 (23.7%) cats, feline idiopathic cystitis in 17 of 118 (14.4%) cats, and urolithiasis in 12 of 118 (10.2%) cats. The majority of cats (92/118; 78.0%) had previously been presented to a veterinarian for signs of urinary tract disease. At least 1 clinical sign was noted in 111 of 118 (94.1%) cats, and the median duration of clinical signs was 30 days (IQR, 9-105; range, 0-730 days). For the remaining 7 of 118 (5.9%) cats, TCC was found incidentally during diagnostic imaging for assessment of other disease

processes. Clinical signs included hematuria in 74 of 118 (62.7%), pollakiuria in 59 of 118 (50.0%), stranguria in 57 of 118 (48.3%), anorexia in 26 of 118 (22.0%), lethargy in 26 of 118 (22.0%), vomiting in 23 of 118 (19.5%), and abdominal pain in 12 of 118 (10.2%) cats. Of cats with these clinical signs, 27 of 111 (24.3%) had 1 sign, 31 of 111 (27.9%) had 2 signs, 36 of 111 (32.4%) had 3 signs, 11 of 111 (9.9%) had 4 signs, 2 of 111 (1.8%) had 5 signs, 2 of 111 (1.8%) had 6 signs, and 2 of 111 (1.8%) had 7 signs. Urethral obstruction at presentation was noted in 12 of 118 (10.2%) cats.

3.3 | Physical examination

At initial evaluation, cats had a median weight of 4.0 kg (IQR, 3.3-5.2; range, 2.1-11.8 kg) and median body condition score of 5 of 9 (IQR, 3-6; range, 1-9/9). On abdominal palpation, 25 of 118 (21.2%) cats were painful, and 22 of 118 (18.6%) cats had a palpable mass or thickening of the urinary bladder region.

3.4 | Diagnostic results

Clinicopathologic results (CBC and serum biochemistry panel) were available for 102 cats at initial evaluation by the contributing clinic; 94 of 102 samples (92.2%) were obtained before IV fluid administration, and 8 of 102 samples (7.8%) were obtained during or after IV fluid administration. Decreased hematocrit, increased serum creatinine and increased blood urea nitrogen (BUN) concentrations were noted in 31 of 102 (30.4%), 34 of 102 (33.3%), and 58 of 102 (56.9%) cats, respectively. Median BUN concentration was 43 mg/dL (IQR, 32-58; range, 14-262), and median serum creatinine concentration was 1.9 mg/dL (IQR, 1.5-2.6; range, 4.5-15.6). Urinalysis was available for 69 cats. Median urine specific gravity was 1.016 (IQR 1.012-1.025, range 1.000-1.056). Urine culture was performed on 67 cats at initial evaluation by the contributing clinic; culture was performed on samples obtained from voided samples in 10 of 67 (14.9%), cystocentesis in 25 of 67 (37.3%), catheterization in 1 of 67 (1.5%) cats, and method of collection was not reported in 31 of 67 (46.3%) cats. Urine culture was positive for bacterial growth in 10 of 67 (14.9%) cats; organisms cultured included *E. coli* alone (5/10; 50%), *E. coli* and Enterococcus (1/10; 10%), *E. coli* and Bacillus (1/10; 10%), Enterococcus alone (1/10; 10%), Enterococcus and Staphylococcus (1/10; 10%), and *Serratia marcescens* (1/10; 10%).

Abdominal ultrasound examination, thoracic radiographs, abdominal radiographs, and cystoscopy were performed on 110 of 118 (93.2%), 70 of 118 (59.3%), 25 (21.2%), and 5 (4.2%) cats respectively; abdominal computed tomography was not performed on any cat. Diagnostic images were reviewed and interpreted by board-certified radiologists. Ultrasonographic findings included a single bladder mass (95/110; 86.4%), bladder wall thickening with a mass (8/110; 7.3%), and multiple bladder masses (7/110; 6.4%). Tumors were located in the trigone in 32 of 118 (27.1%), ventral bladder wall in 28 of 118 (23.7%), bladder apex in 20 of 118 (17.0%), dorsal bladder wall in 16 of 118 (13.6%), multifocal or diffuse throughout the urinary bladder in 10 of 118 (8.5%), and lateral bladder wall in 3 of 118 (2.5%) cats; tumor location was not

reported in 9 of 118 (7.6%) cats. Urethral involvement of the tumor was documented by ultrasound examination or cystoscopy in 14 of 118 (11.9%) cats, 1 of 14 (7.1%) cats of which were obstructed. Ureteral obstruction was diagnosed in 14 of 118 (11.9%) cats by ultrasound examination, and 6 of 118 (5.1%) cats had evidence of both urethral and ureteral involvement (with 1 cat diagnosed with both urethral and ureteral obstruction). Of the 5 cats that underwent cystoscopy, cystoscopy allowed for visualization and further characterization of the TCC lesion in the lower urinary tract in 4 of 5 (80.0%) cats and resulted in poor visualization without detection of clinically relevant abnormalities in 1 cat.

Cytology results, acquired by fine-needle aspirate (FNA), urine cytospin, or traumatic urethral catheterization and reviewed by board-certified pathologists, were available for 78 of 118 (66.1%) cats and were consistent with TCC in 33 of 78 (42.3%) samples, carcinoma in 26 of 78 (33.3%) samples, or other (including epithelial hyperplasia, proliferation, or atypia [6/78; 7.7%], inflammation [2/78; 2.6%], probable neoplasia [2/78; 2.6%], inflammation with epithelial hyperplasia or atypia [2/78; 2.6%], normal transitional epithelial cells [1/78; 1.3%], sarcoma [1/78; 1.3%], and lymphosarcoma vs. carcinoma [1/78; 1.3%]) in 15 of 78 (19.2%) samples, and were inconclusive in 4 of 78 (5.1%) samples. Histopathology, obtained by surgical biopsy, cystoscopic biopsy, necropsy, or some combination of these, was available for 62 of 118 (52.5%) cats; definitive diagnosis was obtained by cytology without histopathology in 56 of 118 (47.5%) cats. Tumors were described as infiltrative in 43 of 62 (69.4%), high grade in 2 of 62 (3.2%), and low grade in 1 of 62 (1.6%) histopathologic samples. Tumors were not described as in situ or aneuploid in any reports. Prostaglandin E measurements and cyclooxygenase (COX) expression were not reported for any tumor. Diagnosis was obtained by ultrasound-guided FNA alone in 33 of 118 (28.0%) cats, surgical biopsy alone in 30 of 118 (25.4%) cats, necropsy alone in 17 of 118 (14.4%) cats, urine cytospin alone in 14 of 118 (11.9%) cats, and traumatic urethral catheterization alone in 6 of 118 (5.1%) cats. Several cats had multiple diagnostic tests performed (agreement was not noted between cytology and biopsy in all cases): ultrasound-guided FNA and urine cytospin in 5 of 118 (4.2%) cats, ultrasound-guided FNA and surgical biopsy in 4 of 118 (3.4%) cats, ultrasound-guided FNA and necropsy in 3 of 118 (2.5%) cats, cystoscopic

biopsy and surgical biopsy in 2 of 118 (1.7%) cats, cystoscopic biopsy and traumatic urethral catheterization in 1 cat, urine cytospin and surgical biopsy in 1 cat, urine cytospin and necropsy in 1 cat, and a combination of urine cytospin, traumatic urethral catheterization, cystoscopic biopsy, and surgical biopsy in 1 cat.

Based on imaging, cytology, and histopathology results, 15 of 118 (12.7%) cats were considered to have metastatic disease at initial evaluation; 9 of 118 (7.6%) cats had metastasis to regional lymph nodes alone, 3 of 118 cats (2.5%) had abdominal carcinomatosis, 1 cat had metastasis to a regional lymph node and omental tissue near the bladder, 1 cat had presumed pulmonary metastasis based on thoracic radiographs, and 1 cat had both regional lymph node and presumed pulmonary metastasis based on thoracic radiographs. Cases of nonpulmonary metastasis were confirmed by cytology or histopathology, whereas cases of pulmonary metastasis were reported as suspected based on radiographic interpretation by a board-certified radiologist.

3.5 | Treatment

Information regarding treatment (specifically cystectomy) is found in Table 1. Of the 2 cats with trigonal tumors that underwent partial cystectomy, ureteral reimplantation was performed on 1 cat and resection of a ureteral papilla was performed on the other cat. The median estimated percentage of bladder wall excised during partial cystectomy (reported in 15/28 [53.6%] cats) was 50% (range, 20%-65%). Radical cystectomy was not performed on any cat. Surgical biopsy without partial cystectomy was performed on 7 of 118 (5.9%) cats. Tumor location of cats undergoing surgical biopsy included dorsal wall (2/7; 28.6%), trigone with extension into the ureters (1/7; 14.3%), dorsal and ventral wall (1/7; 14.3%), and multifocal or diffuse (1/7; 14.3%); location was not reported in 1 cat. Excision was reportedly complete (ie, tumor-free margins on histopathology) after 9 of 28 (32.1%) partial cystectomies, incomplete (ie, tumor cells extending to margins on histopathology) after 12 of 28 (42.9%) partial cystectomies, and not reported after 7 of 28 (25.0%) partial cystectomies. Four cats had documented margins of normal bladder tissue with a histopathologically complete excision, and a range of 1 to 3 mm of normal bladder wall was noted.

TABLE 1 Information regarding treatment

Treatment pursued?	Treatment	Bladder location where cystectomy performed								
No	45 (38)	Single modality	Multiple modality	No cystectomy	Partial cystectomy					
		35 (48)	38 (52)	45 (62)	28 (38)					
Yes	73 (62)				Ventral wall	Apex	Dorsal wall	Lateral wall	Trigone	Not reported
					9	8	6	2	2	1

Numbers refer to number (percentage) of cats. Nearly 2/3 of cats received treatment and 38% of those that received treatment underwent partial cystectomy. Although many locations of the bladder were excised, the ventral wall and apex were most common.

Three major postoperative complications occurred (septic peritonitis [2/28; 7.1%] and uroperitoneum [1/28; 3.6%]) and 3 minor complications occurred (transient urinary incontinence [1/28; 3.6%], massive abdominal wall bruising [1/28; 3.6%], and hematuria and stranguria [1/28; 3.6%] in cats undergoing partial cystectomy. Of the 2 cats with trigonal tumors that underwent partial cystectomy, both experienced major postoperative complications (septic peritonitis [1/2; 50%] and uroperitoneum [1/2; 50%]). One cat that underwent surgical biopsy without cystectomy had a major complication; during surgery, a cystostomy tube was placed and leakage of the cystostomy tube (requiring revision surgery) was encountered postoperatively.

Improvement in clinical signs was reported after surgery in 21 of 28 (75.0%) cats that underwent partial cystectomy, but it is unknown if this improvement can be completely attributed to surgery because many cats underwent multimodality therapy. No improvement in clinical signs was reported after surgery in 2 of 28 (7.1%) cats that underwent partial cystectomy. Data regarding improvement was not available for the remaining 5 cats that underwent partial cystectomy. After partial cystectomy, 12 of 28 (42.9%) cats received no additional treatment, 7 of 28 (25.0%) cats received NSAIDs only, 6 of 28 (21.4%) cats received chemotherapy and NSAIDs, and 3 of 28 (10.7%) cats received chemotherapy only.

Nonsteroidal anti-inflammatory drugs were administered to 49 of 118 (41.5%) cats; 15 of 49 (30.6%) cats were treated only with NSAIDs, and 34 of 49 (69.4%) cats were treated with NSAIDs as part of a multiple modality treatment plan. Administered NSAIDs included piroxicam only in 30 of 49 (61.2%) cats, meloxicam only in 14 of 49 (28.6%) cats, robenacoxib only in 3 of 49 (6.1%) cats, and both piroxicam and meloxicam (sequential) in 2 of 49 (4.1%) cats. Adverse events were reported in 13 of 49 (26.5%) cats prescribed NSAIDs and included acute onset or progression of azotemia (6/13; 46.2%), nausea, vomiting, or regurgitation (3/13; 23.1%), inappetence (2/13; 15.4%), diarrhea with or without melena (2/13; 15.4%), lethargy (1/13; 7.7%), constipation (1/13; 7.7%), and hematuria (1/13; 7.7%). However, documentation of these clinical signs as directly associated with NSAID administration was not possible in at least 7 of 13 (53.8%) cats because of other concurrent treatments or progressive disease.

Chemotherapy was administered to 33 of 118 (28.0%) cats; 6 of 33 (18.2%) cats were treated with only chemotherapy and 27 of 33 (81.8%) cats were treated with chemotherapy as part of multimodality (ie, surgery, NSAID administration, radiation therapy, or some combination of these) treatment plan. The most common chemotherapy protocol was mitoxantrone alone (17/33; 51.5%). Other protocols included carboplatin alone (4/33; 12.1%); mitoxantrone and vinblastine (2/33; 6.1%); mitoxantrone and chlorambucil (2/33; 6.1%); chlorambucil alone (2/33; 6.1%); vinblastine alone (1/33; 3.0%); doxorubicin and carboplatin (1/33; 3.0%); mitoxantrone and carboplatin (1/33; 3.0%); mitoxantrone and cyclophosphamide (1/33; 3.0%); mitoxantrone, vinblastine, and gemcitabine (1/33; 3.0%); and, mitoxantrone, carboplatin, and vinblastine (1/33; 3.0%). For each protocol with multiple chemotherapy agents utilized, administration of the agents was sequential rather than concurrent. Mitoxantrone was administered as a first-line chemotherapy agent in 24 of 33 (72.7%)

cats. Adverse events were reported in 23 of 33 (69.7%) cats given chemotherapy; grading of neutropenia was based on definitions used by the Veterinary Co-operative Oncology Group—Common Terminology Criteria for Adverse Events. Adverse events included gastrointestinal signs, lethargy, or both (21/23; 91.3%), myelosuppression (5/23 [21.7%]; grade II neutropenia in 1/5 [20.0%], grade III neutropenia in 3/5 [60.0%], grade IV neutropenia in 1/5 [20.0%]), and azotemia (6/23 [26.1%] with at least 2/6 [33.3%] of these cases possibly attributed to another cause of renal injury because azotemia was present before chemotherapy). Reported clinical response rate (ie, improvement of clinical signs) was 25 of 33 (75.8%) in cats given chemotherapy as part of their treatment protocol. However, all but 6 of 33 (18.2%) cats underwent other forms of treatment, and in those cats, improvement in clinical signs cannot be attributed to chemotherapy alone. In the 6 cats that received chemotherapy alone, clinical signs improved in 2 of 6 (33.3%) cats, but information regarding the response in the other 4 of 6 (66.7%) cats was not available.

Radiation therapy was administered to 3 of 118 (2.5%) cats on a once weekly fractionated basis for 2 to 6 treatments; 2 of 3 (66.7%) cats were treated with only radiation therapy and 1 cat was treated with radiation therapy and NSAIDs. One cat received 5 fractions of 6 Gy on a weekly basis, and 1 cat received 6 fractions (dose not reported); both cats experienced improvement in clinical signs. One additional cat received 2 fractions of 6 Gy, and radiation therapy subsequently was discontinued because of reported lack of improvement of clinical signs. One cat was treated using urethral and ureteral stents in addition to chemotherapy. In 1 additional cat, placement of a ureteral stent was unsuccessful.

On multivariable analysis, trigonal disease (OR, 3.91; 95% confidence interval [CI], 1.40-10.9) and a presenting complaint of lethargy (OR, 3.54; 95% CI, 1.26-9.99) increased the odds of not receiving treatment. Body weight, age, sex, BUN concentration, serum creatinine concentration, anorexia, hematuria, vomiting, pollakiuria, stranguria, metastasis at presentation, and duration of clinical signs were not significantly associated with receiving treatment.

3.6 | Outcome

Median follow-up time starting from the first visit was 63 days (range, 0-2095 days), and this calculation included 15 untreated cats that were euthanized at the time of the first visit. Median progression-free survival time was 113 (95% CI, 69-153) days. Data pertaining to tumor progression was available for 81 of 118 (68.6%) cats; 45 of 81 (55.6%) cats had documented progression at a median of 116 days (range, 3-459 days). Documented progression occurred in 9 of 31 (29.0%) untreated cats, 22 of 28 (78.6%) cats treated without partial cystectomy, and 14 of 22 (63.6%) cats that underwent partial cystectomy, including 4 of 9 (44.4%) cats that reportedly had completely excised tumors based on histopathology findings. The median time to tumor recurrence in cats that underwent partial cystectomy was 205 days (range, 42-459 days). Development or increased size of regional or distant metastatic disease, or both was documented in 11 of 66 (16.7%) cats with available data at a median of 176 days (range, 43-407 days). The sites of metastatic

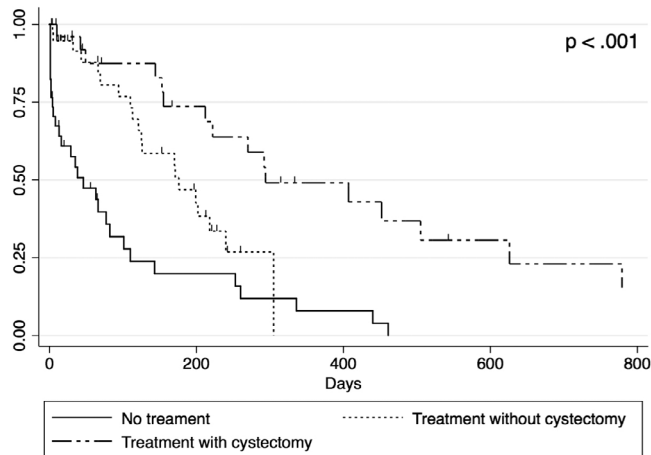


FIGURE 1 Kaplan-Meier estimates of survival with different treatment groups. Survival increased significantly ($P < .001$) when comparing cats across the ordered treatment groups: no treatment, treatment without partial cystectomy, treatment with partial cystectomy

progression included lungs (4/11; 36.4%), lymph nodes (3/11; 27.3%), abdominal carcinomatosis (3/11; 27.3%), tissue adjacent to the urinary bladder ([possible body wall] 2/11; 18.2%), kidney and ureter (1/11; 9.1%), pancreas (1/11; 9.1%), liver (1/11; 9.1%), omentum (1/11; 9.1%), small intestine (1/11; 9.1%), and sacral vertebra (1/11; 9.1%). Necropsy was performed on 31 of 118 (26.3%) cats, and metastatic disease was documented in 6 of 31 (19.4%) cats on necropsy examination. Sites of metastatic disease on necropsy included kidneys, liver, and abdominal lymph nodes (1/6; 16.7%); pancreas (1/6; 16.7%); lungs, pancreatic lymph nodes and mesentery, renal capsule, abdominal lymph nodes, and lymphatic and vascular obstruction with development of chyloabdomen (1/6; 16.7%); and, carcinomatosis (3/6; 50.0%). Overall, at study completion, metastatic disease was documented in 25 of 118 (21.2%) cats (including both cats that had metastatic disease at the time of presentation and those that developed metastatic disease at a later date). One cat with suspected tumor extension into the ventral body wall had a prior FNA performed for evaluation of the bladder tumor (no surgery was performed on this cat). Two cats that developed abdominal carcinomatosis also previously had FNA performed for evaluation of the bladder tumor (no surgery was performed on these cats), and 1 cat that developed abdominal carcinomatosis previously underwent celiotomy without cystectomy.

At the time of analysis, 4 of 118 (3.4%) cats were alive, 77 of 118 (65.3%) cats were dead, and 37 of 118 (31.4%) cats were lost to follow-up at a median of 30 days post-visit (IQR, 8-180; range, 1-541). Of the deceased cats, 68 of 77 (88.3%) were euthanized, 5 of 77 (6.5%) died of natural causes, and cause of death was not reported in 4 of 77 (5.2%) cats. Among the 77 cats that died or were euthanized, 56 (72.7%) deaths were attributed to progressive urinary tract neoplasia with 54 of 56 (96.4%) being euthanized and 2 of 56 (3.6%) dying. Seven of 77 (9.1%) deaths were attributed to other disease conditions, whereas the reason for death was unknown in 14 of 77 (18.2%) cats.

Median survival time for all cats was 155 days (95% CI, 110-222 days). The median survival time was 46 days (95% CI, 8-82 days) for untreated cats, 176 days (95% CI, 113-240 days) for cats treated without partial cystectomy, and 294 days (95% CI, 212-626 days) for cats treated by partial cystectomy with or without other treatments. On unadjusted analysis, survival increased significantly ($P < .001$) when comparing cats across the ordered treatment groups: no treatment, treatment without partial cystectomy, treatment with partial cystectomy (Figure 1). Cystectomy (HR, 0.31; 95% CI, 0.17-0.87) and treatment with NSAIDs (HR, 0.55; 95% CI, 0.33-0.93) were significantly associated with longer survival times on multivariable analysis. The estimated hazard of death for cats that had both cystectomy and treatment with NSAIDs was significantly decreased (HR, 0.17; 95% CI, 0.08-0.38) compared to cats that had neither treatment. Age, sex, body weight, duration of clinical signs, serum creatinine concentration, trigonal location, urethral involvement, chemotherapy, radiation therapy, and metastasis at diagnosis were not significantly associated with overall survival. Estimated 1- and 2-year survival rates were 6.7% and 2.2% for untreated cats, 0% and 0% for cats treated without cystectomy, and 28.0% and 8.0% for cats treated with partial cystectomy with or without other treatments, respectively.

4 | DISCUSSION

To date, information on prognosis and recommended treatments for cats with TCC of the lower urinary tract has been limited because of a lack of data. Our results demonstrate the importance of treatment with cystectomy and NSAIDs in cats with TCC. Our findings highlight several important differences between dogs and cats with TCC, including tumor location, treatment modalities with the greatest effect on outcome, disease progression, and prognosis.

Many of the cats in our study had a history of lower urinary tract disease, and the majority of cats (92/118; 78.0%) were evaluated by veterinarians for urinary tract signs or disease before diagnosis. It is possible that the diagnosis of TCC and subsequent treatment may have been delayed in many of these cats because of the lack of inclusion of TCC as a differential diagnosis. Alternatively, prior lower urinary tract disease and inflammation may have predisposed these cats to the development of TCC. Nevertheless, these findings emphasize the importance of diagnostic testing to evaluate for potential neoplasia of the lower urinary tract even in cats with a history of other common forms of lower urinary disease, particularly when signs are recurrent or refractory to treatment.

Location of TCC appears to be more variable in cats than in dogs, but the trigone appears to be the most common location for occurrence in both species. Whereas trigonal disease is reported in the majority of dogs with TCC, we found trigonal disease in only 32 of 118 (27.1%) cats with TCC.⁵ Although TCC in both dogs and cats is typically invasive in nature (similar to high-grade, invasive TCC in humans), relative to tumor location, TCC in cats may be a better model for TCC in humans because this neoplasm affects the trigone in only 23% of human patients with urinary bladder TCC.^{8,15} Thus, the treatment limitations associated with trigonal location of TCC in dogs

may not be as applicable in the treatment of this disease in cats and humans. Importantly, when TCC was located in the trigone of cats in our study, these cats were less likely to receive treatment. This finding supports the influence of location of TCC on treatments pursued and overall outcomes in these cats, because receiving no treatment was associated with significantly shorter survival.

The potential for seeding TCC within the abdomen or body wall after FNA or biopsy of the tumor as well as peritoneal surgery has been well documented in dogs with TCC.^{3,4,9,16-18} One cat in our study developed potential extension of TCC into the ventral body wall after FNA, and 3 of 118 (2.5%) cats developed abdominal carcinomatosis after FNA (2/3; 66.7%) or celiotomy with urinary surgery (1/3; 33.3%). Therefore, as with TCC in dogs, it is important to consider the potential for neoplastic seeding after tumor sampling (FNA or biopsy) or laparotomy with urinary tract surgery in cats with lower urinary tract TCC. However, given the limited number of cats that developed this complication in our study as well as the relatively poor survival times for cats with TCC, ultimately obtaining a diagnosis and providing treatment generally should be pursued, after careful consultation with owners, in an effort to improve the outcomes of affected cats.

The role of surgery in the treatment of dogs with TCC generally has been considered limited because of the typical trigonal location, high frequency of urethral involvement, and commonly documented metastatic disease at the time of diagnosis.^{5,9} However, a recent study on outcomes in 37 dogs that underwent partial cystectomy with or without other non-surgical treatments for TCC found relatively improved outcomes, despite attaining histopathologically incomplete excision in 60% of the cases.¹⁹ Total cystectomy is not currently pursued in many dogs, and the management of dogs with lower urinary tract TCC often is palliative in nature with placement of urethral or ureteral stents to maintain patency of the urinary tract without directly altering tumor progression.⁹

In cats with TCC in our study, partial cystectomy was associated with significantly improved survival times (when compared to cats not undergoing treatment or cats undergoing treatment not including cystectomy). Cats that underwent partial cystectomy as part of their treatment protocol experienced the longest median survival time and highest 1- and 2-year survival rates. Interestingly, however, although untreated cats had the shortest median survival time, higher 1- and 2-year survival rates were seen in this subgroup than in cats that were treated without cystectomy. We hypothesize that this finding may be attributable to a less aggressive form of disease in a small number of cats that have the potential for longer survival without treatment. These cats may have fewer clinical signs associated with TCC and, subsequently, owners may be less inclined to treat them. However, a potential incorrect diagnosis of TCC in such cats cannot be ruled out.

A relatively large proportion of cats in our study (28/118; 23.7%) underwent partial cystectomy; no cats underwent radical cystectomy. Partial cystectomy was performed in only 2 cats with trigonal disease. Although the postoperative complication rate was relatively low (6/28; 21.4%), 3 of 6 (50.0%) of the complications were considered major, and both cats with trigonal tumors that underwent partial cystectomy developed major complications. Given the potential for major complications after cystectomy in cats with trigonal disease, the possible role of

surgery in these patients should be further investigated with additional studies because of the small sample size of cats with trigonal tumors that underwent partial cystectomy in our study. Importantly, 14 of 22 (63.6%) cats that underwent partial cystectomy developed recurrence of TCC, and recurrence was seen in a large proportion (4/9; 44.4%) of cats that reportedly had completely excised TCC. Overall, however, our data suggests that partial cystectomy can be considered a viable treatment option in cats with TCC, and this surgical procedure can result in improved outcomes for these patients. Additional studies are required to determine the role of radical cystectomy on outcomes in cats with TCC.

A single cat in our study underwent urethral and bilateral ureteral stent placement. However, 14 of 118 (11.9%) cats had evidence of urethral TCC involvement, 14 of 118 (11.9%) cats had evidence of ureteral obstruction, and 6 of 118 (5.1%) cats had evidence of both urethral and ureteral involvement of TCC. This data suggests a possible role for interventional radiology procedures such as urethral and ureteral stenting to maintain patency of the urinary tract in an effort to improve the longevity and quality of life of cats with TCC in the face of malignant urinary obstruction. Several studies have evaluated the use of urethral stents in cats with malignant urethral obstruction and have found favorable outcomes after these minimally invasive procedures.²⁰⁻²² Although reports regarding the use of ureteral stents and SC ureteral bypass devices in cats with malignant causes of ureteral obstruction are lacking, these devices commonly are used in cats with other causes of ureteral obstruction and in dogs with malignant ureteral obstruction. Possible use of these devices in cats with ureteral obstruction secondary to TCC should be considered in an effort to provide palliation for obstructive local disease.^{23,24}

Radiation therapy has been utilized infrequently in the treatment of TCC in dogs, and this appears to be similar in cats as evidenced by only 3 of 118 (2.5%) cats in our study undergoing radiation therapy.^{11,12} The radiation therapy protocols used in the cats of our study all were hypofractionated and palliative in intent. Additional studies are needed to further determine the role of radiation therapy and optimal protocols for its use in the treatment of both dogs and cats with lower urinary tract TCC.

In dogs, systemic medical treatments including chemotherapy agents and COX inhibitors are considered to be mainstay treatments for TCC.^{3,8,9} Multimodal medical therapy has been shown to improve response rates and survival times in dogs with TCC.^{10,25,26} In our study, treatment with NSAIDs was associated with prolonged survival for cats with TCC. Several studies have evaluated the safety of long-term daily meloxicam and piroxicam in cats, and consensus guidelines have been published regarding judicious chronic use of NSAIDs in cats.²⁷⁻³¹ Adverse events were reported in a relatively small percentage of cats in our study treated with NSAIDs (13/49; 26.5%), and, of those adverse events, many were not definitively correlated with NSAID administration. This data suggests that NSAIDs carry a relatively low risk of complications when used appropriately and should be considered as part of the treatment strategy whenever possible for cats with TCC. However, given the retrospective nature of our study, the frequency or severity of adverse events may have been underreported, and thorough discussion of possible adverse events with clients is indicated before long-term use of NSAIDs in cats.

Although chemotherapy and other treatment modalities ultimately may play a role in treatment of cats with TCC, our findings suggest that surgical excision and NSAID administration should be the primary recommended treatments in cats with lower urinary tract TCC in an effort to improve outcomes. However, these treatments will not be possible or appropriate in all cats with lower urinary tract TCC, and any treatment (relative to no treatment) may result in an improved outcome for affected cats.

Overall, the prognosis for cats with lower urinary tract TCC is guarded.^{14,32} This finding points to a need for improvement in our management of these patients. Whereas the overall frequency of metastatic disease in cats with TCC was at least 25 of 118 (21.2%), the frequency of documented tumor progression was 45 of 81 (55.6%), with frequency of recurrence after cystectomy was 14 of 22 (63.6%). The relatively higher rate of tumor progression emphasizes the need to improve local control of this disease. Additional studies regarding radical cystectomy and radiation therapy in cats with TCC are needed to further determine the role of these treatments on local disease control and overall outcomes in cats with TCC.

Our study had several limitations. First, the study was retrospective with resultant potential for incomplete clinical information for some patients. Many cases were lost to follow-up, which can lead to underinterpretation or overinterpretation of many findings, including documentation of metastasis and response to treatment. Because of wide variability in patient, disease, treatment, and outcome information, valid comparisons of outcomes across subgroups of cats could not be made. For example, it was not possible to make assessments of the subgroup of cats with trigonal disease that underwent treatment or cats that underwent treatment with NSAIDs and partial cystectomy compared to NSAIDs alone and partial cystectomy alone because of small numbers of cats in these subgroups and multiple potential confounders. A second limitation is probable selection bias because academic institutions primarily contributed cases, and both patient and client factors likely influenced the type of treatment, if any, that was administered to individual cats. Additionally, prior care at referring practices was not accounted for in this data set, which could have resulted in underestimation of treatment effects or survival times. Cats may have undergone treatment at a referring veterinary clinic that may have improved clinical signs or outcome, but no evidence of any cat undergoing NSAID administration, chemotherapy, or surgery before referral was noted. Many cats with suspected TCC were excluded because of lack of cytological or histopathological confirmation, such that the sample size likely did not include all cats with the disease. Finally, given the long inclusion period of the study, bias may have originated from changes in the recommended diagnostic and treatment modalities for these patients over time.

In conclusion, our study represents the largest report to date on cats with TCC of the lower urinary tract. This information can be used to inform clinicians and owners about this disease process in cats and to guide treatment recommendations and discussions on prognosis. Although the statistically significant findings in this study emphasize the importance of partial cystectomy and NSAID administration in cats with TCC, additional work is necessary to

evaluate larger numbers of cats undergoing these and other treatments.

CONFLICT OF INTEREST DECLARATION

Authors declare no conflict of interest.

OFF-LABEL ANTIMICROBIAL DECLARATION

Authors declare no off-label use of antimicrobials.

INSTITUTIONAL ANIMAL CARE AND USE COMMITTEE (IACUC) OR OTHER APPROVAL DECLARATION

Authors declare no IACUC or other approval was needed.

HUMAN ETHICS APPROVAL DECLARATION

Authors declare human ethics approval was not needed for this study.

ORCID

William T. N. Culp  <https://orcid.org/0000-0001-6132-156X>

Kyle Mathews  <https://orcid.org/0000-0003-3431-6049>

Carrie A. Palm  <https://orcid.org/0000-0003-1445-5113>

REFERENCES

- Norris AM, Laing EJ, Valli VE, et al. Canine bladder and urethral tumors: a retrospective study of 115 cases (1980–1985). *J Vet Intern Med.* 1992;6:145-153.
- Schwarz P, Greene R, Patnaik A. Urinary bladder tumors in the cat: a review of 27 cases. *J Am Anim Hosp Assoc.* 1985;21:237-245.
- Knapp D, McMillan S. Tumors of the urinary system. In: Withrow SJVD, Page RL, eds. *Withrow & MacEwen's Small Animal Clinical Oncology.* 5th ed. St. Louis: Elsevier; 2013:572-582.
- Mutsaers AJ, Widmer WR, Knapp DW. Canine transitional cell carcinoma. *J Vet Intern Med.* 2003;17:136-144.
- Knapp DW, Glickman NW, DeNicola DB, et al. Naturally-occurring canine transitional cell carcinoma of the urinary bladder: a relevant model of human invasive bladder cancer. *Urol Oncol.* 2000;5:47-59.
- Knapp DW. Animal models: naturally occurring canine urinary bladder cancer. In: Lerner SPSM, Sternberg CN, eds. *Textbook of Bladder Cancer.* Oxon, UK: Taylor and Francis; 2006.
- Valli VE, Norris A, Jacobs RM, et al. Pathology of canine bladder and urethral cancer and correlation with tumour progression and survival. *J Comp Pathol.* 1995;113:113-130.
- Knapp DW, Ramos-Vara JA, Moore GE, Dhawan D, Bonney PL, Young KE. Urinary bladder cancer in dogs, a naturally occurring model for cancer biology and drug development. *ILAR J.* 2014;55:100-118.
- Fulkerson CM, Knapp DW. Management of transitional cell carcinoma of the urinary bladder in dogs: a review. *Vet J.* 2015;205:217-225.
- Wimberly H, Lewis R. Transitional cell carcinoma in the domestic cat. *Vet Pathol.* 1979;16:223-228.
- Wilson HM, Chun R, Larson VS, Kurzman ID, Vail DM. Clinical signs, treatments, and outcome in cats with transitional cell carcinoma of the urinary bladder: 20 cases (1990–2004). *J Am Vet Med Assoc.* 2007;231:101-106.

12. Stephenson WT, Holmes FF, Noble MJ, Gerald KB. Analysis of bladder carcinoma by subsite. Cystoscopic location may have prognostic value. *Cancer*. 1990;66:1630-1635.
13. Nyland TG, Wallack ST, Wisner ER. Needle-tract implantation following US-guided fine-needle aspiration biopsy of transitional cell carcinoma of the bladder, urethra, and prostate. *Vet Rad Ultrasound*. 2002;43:50-53.
14. Anderson W, Dunham B, King J, Scott DW. Presumptive subcutaneous surgical transplantation of a urinary bladder transitional cell carcinoma in a dog. *Cornell Vet*. 1989;79:263-266.
15. Higuchi T, Burcham GN, Childress MO, et al. Characterization and treatment of transitional cell carcinoma of the abdominal wall in dogs: 24 cases (1985–2010). *J Am Vet Med Assoc*. 2013;242:499-506.
16. Marvel S, Séguin B, Dailey D, et al. Clinical outcome of partial cystectomy for transitional cell carcinoma of the canine bladder. *Vet Comp Oncol*. 2017;15:1417-1427.
17. Brace MA, Weisse C, Berent A. Preliminary experience with stenting for management of non-urolith urethral obstruction in eight cats. *Vet Surg*. 2014;43:199-208.
18. Christensen N, Culvenor J, Langova V. Fluoroscopic stent placement for the relief of malignant urethral obstruction in a cat. *Aust Vet J*. 2010;88:478-482.
19. Newman RG, Mehler SJ, Kitchell BE, Beal MW. Use of a balloon-expandable metallic stent to relieve malignant urethral obstruction in a cat. *J Am Vet Med Assoc*. 2009;234:236-239.
20. Berent AC, Weisse C, Beal MW, Brown DC, Todd K, Bagley D. Use of indwelling, double-pigtail stents for treatment of malignant ureteral obstruction in dogs: 12 cases (2006–2009). *J Am Vet Med Assoc*. 2011;238:1017-1025.
21. Berent AC. Ureteral obstructions in dogs and cats: a review of traditional and new interventional diagnostic and therapeutic options. *J Vet Emer Crit Care*. 2011;21:86-103.
22. Walker M, Breider M. Intraoperative radiotherapy of canine bladder cancer. *Vet Rad Ultrasound*. 1987;28:200-204.
23. Nolan M, Kogan L, Griffin L, et al. Intensity-modulated and image-guided radiation therapy for treatment of genitourinary carcinomas in dogs. *J Vet Intern Med*. 2012;26:987-995.
24. Henry CJ, McCaw DL, Turnquist SE, et al. Clinical evaluation of mitoxantrone and piroxicam in a canine model of human invasive urinary bladder carcinoma. *Clin Cancer Res*. 2003;9:906-911.
25. Knapp DW, Ruple-Czerniak A, Ramos-Vara JA, Naughton JF, Fulkerson CM, Honkisz SI. A nonselective cyclooxygenase inhibitor enhances the activity of vinblastine in a naturally-occurring canine model of invasive urothelial carcinoma. *Bladder Cancer*. 2016;2:241-250.
26. Boria P, Glickman N, Schmidt B, et al. Carboplatin and piroxicam therapy in 31 dogs with transitional cell carcinoma of the urinary bladder. *Vet Comp Oncol*. 2005;3:73-80.
27. Sparkes AH, Heiene R, Lascelles BDX, et al. ISFM and AAFP consensus guidelines: long-term use of NSAIDs in cats. *J Feline Med Surg*. 2010;12:521-538.
28. Gunew MN, Menrath VH, Marshall RD. Long-term safety, efficacy and palatability of oral meloxicam at 0.01–0.03 mg/kg for treatment of osteoarthritic pain in cats. *J Feline Med Surg*. 2008;10:235-241.
29. Gowan RA, Baral RM, Lingard AE, et al. A retrospective analysis of the effects of meloxicam on the longevity of aged cats with and without overt chronic kidney disease. *J Feline Med Surg*. 2012;14:876-881.
30. Gowan RA, Lingard AE, Johnston L, Stansen W, Brown SA, Malik R. Retrospective case–control study of the effects of long-term dosing with meloxicam on renal function in aged cats with degenerative joint disease. *J Feline Med Surg*. 2011;13:752-761.
31. Bulman-Fleming JC, Turner T, Rosenberg MP. Evaluation of adverse events in cats receiving long-term piroxicam therapy for various neoplasms. *J Feline Med Surg*. 2010;12:262-268.
32. Bommer NX, Hayes AM, Scase TJ, Gunn-Moore DA. Clinical features, survival times and COX-1 and COX-2 expression in cats with transitional cell carcinoma of the urinary bladder treated with meloxicam. *J Feline Med Surg*. 2012;14:527-533.

How to cite this article: Griffin MA, Culp WTN, Giuffrida MA, et al. Lower urinary tract transitional cell carcinoma in cats: Clinical findings, treatments, and outcomes in 118 cases. *J Vet Intern Med*. 2020;34:274–282. <https://doi.org/10.1111/jvim.15656>