

Epstein-Barr Virus-Positive Not Otherwise Specified (EBV+ NOS) Lymphoma Presentation of Primary Bone Tumor Underlying a Pathological Fracture

Review began 06/17/2022
Review ended 06/24/2022
Published 06/26/2022

© Copyright 2022
Tippabhatla et al. This is an open access article distributed under the terms of the Creative Commons Attribution License CC-BY 4.0., which permits unrestricted use, distribution, and reproduction in any medium, provided the original author and source are credited.

Abhishek Tippabhatla¹, Rediet T. Atalay², Alex Gyftopoulos³, Girma M. Ayele², Miriam B. Michael^{2, 3}

1. Orthopedics, Howard University College of Medicine, Washington, D.C., USA 2. Internal Medicine, Howard University College of Medicine, Washington, D.C., USA 3. Internal Medicine, University of Maryland Medical Center, Baltimore, USA

Corresponding author: Miriam B. Michael, mmichael@som.umaryland.edu

Abstract

Diffuse large B-cell lymphoma (DLBCL) is the most common non-Hodgkin's lymphoma (NHL) and accounts for approximately 25% of all NHLs in developed countries. The patients usually present with constitutional symptoms and rapidly enlarging lymphadenopathy and symptomatic mass typically located in the neck or abdomen, along with an aggressive disease course. Most of the patients present with advanced disease with 60% presenting with stage 3 or 4, and those who present with extranodal involvement are usually seen at an earlier stage. Different conditions are associated with non-Hodgkin's lymphoma ranging from hereditary immunodeficiency disorders, autoimmune disorders, infections such as HIV, Epstein-Barr virus (EBV), hepatitis C virus (HCV), *Helicobacter pylori*, and drugs such as immunosuppressants and chemotherapeutic agents. Epstein-Barr virus (EBV) is the main etiology of DLBCLs with an identified cause and it accounts for 10% of all DLBCLs.

We report a case of a 51-year-old woman who came with a non-traumatic left femur fracture and was subsequently found to have EBV-positive DLBCL. Lymphoma commonly presents as a lymph node swelling and it's uncommon to present as primary bone disease.

Categories: Internal Medicine, Oncology, Orthopedics

Keywords: ebv-positive, primary bone tumor, bone lymphoma, pathologic fracture, bone tumor

Introduction

Human herpesvirus 4, commonly known as the Epstein-Barr virus (EBV), is a highly prevalent double-stranded DNA virus associated with a wide range of lymphoid malignancies, such as Burkitt's lymphoma and B-cell lymphoproliferative diseases and Hodgkin's lymphoma. It is linked to the development of 1-2% of all cancers worldwide. EBV causes various structural and epigenetic alterations when inducing malignancies; EBV-encoded gene products and microRNAs modify the tumor growth due to its effect on the host immunity [1].

EBV-positive diffuse large B-cell lymphoma (DLBCL) found to be more common in the Asian population (8-11%) compared to the Western population (<5%) [2]. Meta-analysis on EBV+DLBCL demonstrates the rarity of this disease, with a pooled proportion of only 7.9% among de novo DLBCL cases [3].

Case Presentation

A 51-year-old female presented with a non-traumatic left femur fracture. She has known attention deficit hyperactivity disorder (ADHD) currently maintained on amphetamine-dextroamphetamine. She presented with sudden sharp pain and an audible snap in her left thigh which made her unable to move while she was working in the garden. She presented to the ER with significant pain in her left thigh and was unable to bear weight. On presentation, she admitted that she had some dull left thigh pain for about five months and she has been managing it conservatively with over-the-counter medications. She denied weight loss, fever, dyspnea on exertion, chest pain, nausea, vomiting, or rash. She has a remote history of tobacco use 20 years ago and occasionally vapes.

On examination, her vital signs were stable. Physical examination was significant for swelling and tenderness of the left thigh. The left femur x-ray showed a displaced distal femur fracture (Figures 1, 2). The whole-body scan came back negative. Left femur lesion biopsy showed an EBV-positive diffuse large B-cell lymphoma-not otherwise specified (EBV+DLBCL-NOS). Subsequent fracture stabilization and open reduction and internal fixation (ORIF) were performed. The patient was subsequently appointed to an oncologist for staging and subsequent chemotherapy and radiation.

How to cite this article

Tippabhatla A, Atalay R T, Gyftopoulos A, et al. (June 26, 2022) Epstein-Barr Virus-Positive Not Otherwise Specified (EBV+ NOS) Lymphoma Presentation of Primary Bone Tumor Underlying a Pathological Fracture. Cureus 14(6): e26340. DOI 10.7759/cureus.26340

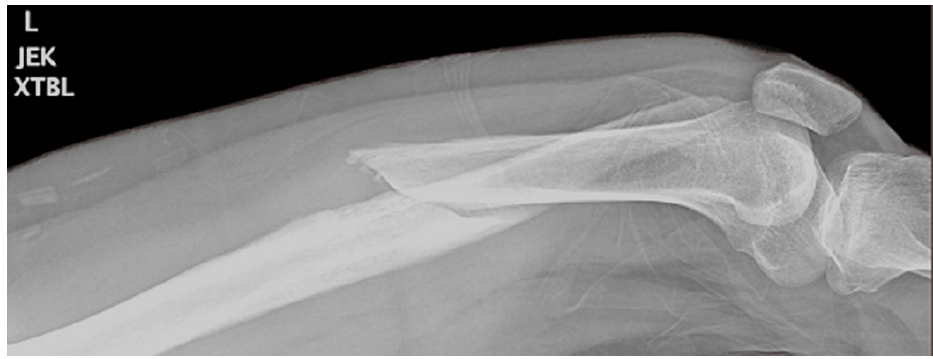


FIGURE 1: Femur x-ray showing the distal displaced femoral fracture (view 1)

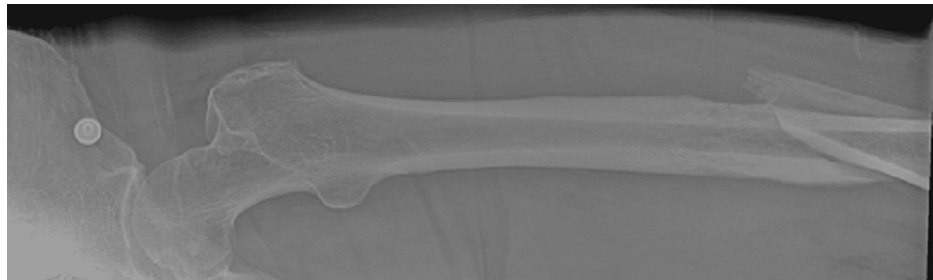


FIGURE 2: Femur x-ray showing the distal displaced femoral fracture (view 2)

Labs at presentation were unremarkable with a WBC count of 7k, RBC of 10.9, and platelets of 316k. Electrophoresis and immunofixation studies are negative. Postoperative follow-up was uneventful, the patient was ambulating well except for mild pain in the left leg and a postoperative x-ray showing good fixation (Figure 3).

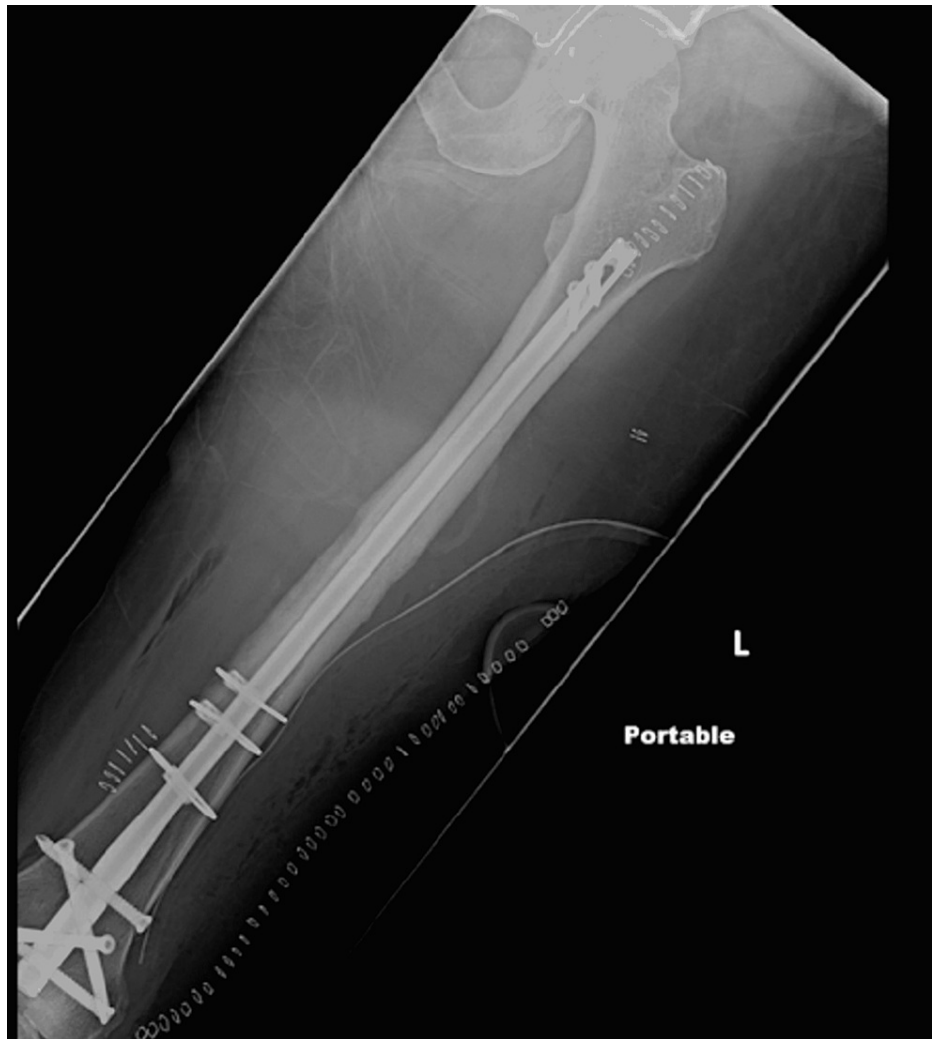

FIGURE 3: Postoperative open reduction and internal fixation (ORIF) x-ray showing good fixation

Discussion

EBV infection is a very common infection affecting most people in the world. Infection occurring in adults can cause infectious mononucleosis even though most infected are children. EBV causes an infection that stays dormant in the B cells due to its unique genes that activate growth. The host immune system, specifically T cells, controls the growth of the B cells that are infected with EBV. Most of the individuals that have been infected with EBV remain asymptomatic but some may develop malignancies that are associated with EBV like Hodgkin's lymphoma, Burkitt's lymphoma, T-cell lymphoma, and B-cell lymphoproliferative disease [4].

It remains recognized that 10% of DLBCL are EBV-positive. The classic demographic of EBV+DLBCL-NOS predominantly affects patients >50 years of age, similar to our case [2]. Yet, the absence of any comorbidities and presence of clinical stability render this case unique. Oftentimes, EBV+DLBCL-NOS is a lymphoma subtype that presents in patients with no underlying immunodeficiency [5]. This case is unique in regards to the development of a pathological fracture secondary to primary lymphoma of bone, which is exceedingly rare.

Primary lymphoma of bone is usually DLBCL with primary bone involvement and no extranodal associations; this malignancy involves the appendicular skeleton in 37% of all cases [6]. Twenty-five percent of patients with primary lymphoma of bone may present with pathological fractures on presentation, and femur involvement is most commonly evidenced similar to our case [7]. Yet, malignant involvement primarily of the bone is rare, and even among cases of primary lymphoma of bone involving the long bones, pathological fractures are very rare. In a large study reporting 131 patients diagnosed with primary lymphoma of bone, only nine patients incurred pathological fractures [8]. In total, only 11 cases are reported in the literature that involve pathological fractures secondary to primary lymphoma of bone, an event that

is noticeably rare [9,7].

It was previously thought that DLBCL patients over 50 years of age with EBV positivity incurred a poorer prognosis with a lower overall survival rate, but recent studies have challenged this notion that EBV positivity portends a poor prognosis for DLBCL, regardless of age [1,9].

The heterogeneous class of DLBCL has distinct clinical presentations, morphologies, and treatment profiles, and they're typically diagnosed with lymph node biopsies. The gold standard for diagnosing EBV+DLBCL is by identifying EBV-encoded RNA in the nuclei of tumor cells by in situ hybridization [6]. Classically, DLBCL is diagnosed based on the following characteristics: diffuse collections of lymphoid cells; immunohistochemistry (IHC) staining of pertinent B-cell markers such as PAX5, CD19, CD20, CD22, CD30, and CD79; and presence of EBV+ RNAs [10].

In general, EBV+ DLBCL responds poorly to front-line treatments in comparison to their EBV-DLBCLs [10]. Current immunochemotherapy protocols include rituximab cyclophosphamide-hydroxydaunorubicin-ondcovin-prednisone (R-CHOP) and rituximab cyclophosphamide-etoposide-prednisone-ondcovin (R-EPOCH) therapies. Since the first introduction of rituximab, clinical outcomes of overall non-Hodgkin lymphomas have significantly improved. Due to the aggressive course of this malignancy, early detection and prompt interventions are critical for managing DLBCL early on [11]. Diverse studies have been done to address this malignancy, however, more research is needed to be done [12].

Conclusions

Diffuse large B-cell lymphoma primarily involving the bone with no extranodal involvement is an infrequent condition. EBV accounts for less than 10% of cases as a causative agent for DLBCL. Our patient presenting with pathologic fracture and no B symptoms makes this insidious case presentation more unique. Few cases exist in the literature regarding lymphoma presenting as a fracture, thus it is important to keep into consideration the possibility of malignancy in patients that present with pathological fractures. More research is needed regarding primary bone lymphoma and its diagnostic approach and management.

Additional Information

Disclosures

Human subjects: Consent was obtained or waived by all participants in this study. **Conflicts of interest:** In compliance with the ICMJE uniform disclosure form, all authors declare the following: **Payment/services info:** All authors have declared that no financial support was received from any organization for the submitted work. **Financial relationships:** All authors have declared that they have no financial relationships at present or within the previous three years with any organizations that might have an interest in the submitted work. **Other relationships:** All authors have declared that there are no other relationships or activities that could appear to have influenced the submitted work.

References

1. Bauer M, Jasinski-Bergner S, Mandelboim O, Wickenhauser C, Seliger B: Epstein-Barr virus-associated malignancies and immune escape: the role of the tumor microenvironment and tumor cell evasion strategies. *Cancers (Basel)*. 2021, 13:10.3390/cancers13205189
2. Castillo JJ, Beltran BE, Miranda RN, Paydas S, Winer ES, Butera JN: Epstein-Barr virus-positive diffuse large B-cell lymphoma of the elderly: what we know so far. *Oncologist*. 2011, 16:87-96. 10.1634/theoncologist.2010-0213
3. Castillo JJ, Beltran BE, Miranda RN, Young KH, Chavez JC, Sotomayor EM: EBV-positive diffuse large B-cell lymphoma of the elderly: 2016 update on diagnosis, risk-stratification, and management. *Am J Hematol*. 2016, 91:529-37. 10.1002/ajh.24370
4. Hong JY, Yoon DH, Suh C, et al.: EBV-positive diffuse large B-cell lymphoma in young adults: is this a distinct disease entity?. *Ann Oncol*. 2015, 26:548-55. 10.1093/annonc/mdu556
5. Cohen JI, Bollard CM, Khanna R, Pittaluga S: Current understanding of the role of Epstein-Barr virus in lymphomagenesis and therapeutic approaches to EBV-associated lymphomas. *Leuk Lymphoma*. 2008, 49:27-34. 10.1080/10428190802511417
6. Hwang J, Suh CH, Won Kim K, Kim HS, Armand P, Huang RY, Guenette JP: The incidence of Epstein-Barr virus-positive diffuse large B-cell lymphoma: a systematic review and meta-analysis. *Cancers (Basel)*. 2021, 13:10.3390/cancers13081785
7. Jawad MU, Schneiderbauer MM, Min ES, Cheung MC, Koniaris LG, Scully SP: Primary lymphoma of bone in adult patients. *Cancer*. 2010, 116:871-9. 10.1002/cncr.24828
8. Lu TX, Liang JH, Miao Y, et al.: Epstein-Barr virus positive diffuse large B-cell lymphoma predict poor outcome, regardless of the age. *Sci Rep*. 2015, 5:10.1038/srep12168
9. Park S, Lee J, Ko YH, et al.: The impact of Epstein-Barr virus status on clinical outcome in diffuse large B-cell lymphoma. *Blood*. 2007, 110:972-8. 10.1182/blood-2007-01-067769
10. Ramadan KM, Shenkier T, Sehn LH, Gascoyne RD, Connors JM: A clinicopathological retrospective study of 131 patients with primary bone lymphoma: a population-based study of successively treated cohorts from the British Columbia Cancer Agency. *Ann Oncol*. 2007, 18:129-35. 10.1093/annonc/mdl329
11. Shibusawa M, Kidoguchi K, Tanimoto T: Chapter 2: Epstein-Barr virus-positive diffuse large B cell

- lymphoma. Lymphoma. Gallamini A, Juweid M (ed): Exon Publications, Brisbane, QL; 2021. 27-46. [10.36255/exon-publications.lymphoma.2021.ebv-dlbcl](https://doi.org/10.36255/exon-publications.lymphoma.2021.ebv-dlbcl)
12. Siddiqui YS, Khan AQ, Sherwani M: Pathological fractures in primary non-Hodgkin's lymphoma of the bone: a case series with review of the literature. J Clin Diagn Res. 2013, 7:513-7. [10.7860/JCDR/2013/3948.2809](https://doi.org/10.7860/JCDR/2013/3948.2809)