



ELSEVIER

Available online at www.sciencedirect.com

ScienceDirect

journal homepage: www.elsevier.com/locate/radcr

Case report

A very rare case: Hydatid cyst surrounding uterus and magnetic resonance imaging findings in the pregnant patient

Ali Fuat Tekin, MD^{a,*}, Hakan Yılmaz, MD^b, Turgay Kara, MD^c, Erdi Seçkin, MD^c, Muhsin Nuh Aybay, MD^d, Ender Alkan, MD^e

^a Yüksekova State Hospital, Department of Radiology, İnanlı Street, Hospital corner, Hakkari, Turkey

^b Ağrı State Hospital, Department of Radiology Ağrı, Turkey

^c SBU Konya Training and Research Hospital, Department of Radiology, Konya, Turkey

^d Mardin State Hospital, Department of Radiology, Mardin, Turkey

^e Aksaray State Hospital, Department of Radiology, Aksaray, Turkey

ARTICLE INFO

Article history:

Received 19 July 2018

Revised 22 September 2018

Accepted 29 September 2018

Available online 2 November 2018

Keywords:

Hydatid cyst

Pregnancy

Pelvic

MRI

ABSTRACT

Hydatid cyst disease is very rare in pregnancy having an incidence of 1 in 20,000 pregnancies and there is no recommended standard treatment. Both surgical and medical modalities have been tried. Modalities that do not use ionizing radiation such as ultrasound and magnetic resonance imaging should be preferred for diagnosis and evaluating acute conditions in a pregnant patient. In this article, a rare pelvic cyst hydatid case surrounding the uterus and MRI findings in a young pregnant patient who was coincidentally determined is represented.

© 2018 Published by Elsevier Inc. on behalf of University of Washington.

This is an open access article under the CC BY-NC-ND license.

(<http://creativecommons.org/licenses/by-nc-nd/4.0/>)

Introduction

Currently, hydatid cyst is one of the most neglected parasitic diseases. The most common form of echinococcal infection in humans is caused by *Echinococcus granulosus* [1]. Parasites are found in dogs (definitive hosts) and in sheep (intermediate hosts). The adult worm is located at the intestine of dogs; eggs or oncospheres are passed in the dog's stool [2]. Humans get infected by ingesting eggs, as people are intermediate hosts

in the life cycle of worms [3]. This occurs when people consume food or drinks contaminated with eggs or come into contact with fecal material containing eggs [4]. Hydatid disease in pregnancy has an incidence of 1/20,000. Although both medical and surgical modalities have been tested, there is no standard treatment that can be recommended. Although it is well known that the hydatid cyst may affect any region in the body, it is necessary to report cases that occur in rare organs because the presentation and the course of the clinical disease are different [5]. In this article, an incidental rare case of hydatid cyst and magnetic resonance imaging (MRI) findings

* Corresponding author.

E-mail address: Md_aliftekin@yahoo.com (A.F. Tekin).

<https://doi.org/10.1016/j.radcr.2018.09.020>

1930-0433/© 2018 Published by Elsevier Inc. on behalf of University of Washington. This is an open access article under the CC BY-NC-ND license. (<http://creativecommons.org/licenses/by-nc-nd/4.0/>)

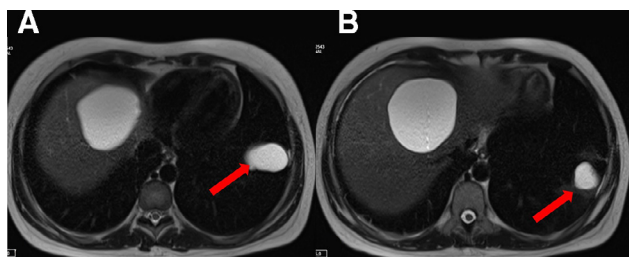


Fig. 1 – In the unenhanced T2-weighted image, 2 hyperintense type-1 hydatid cyst with thin hypointensation wall with left lower lobe in the left lung.

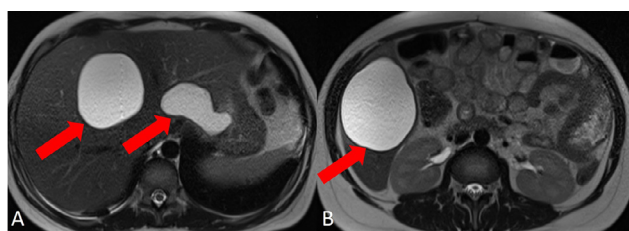


Fig. 2 – In the unenhanced T2-weighted axial conventional images 2 hyperintense cysts at the right lobe of the liver and 1 hyperintense cyst at the left with hypointense thick-wall.

with a pelvic placement surrounding the uterus in a young pregnant patient is presented.

Case report

A 25-year-old, gravida 1, para 0 pregnant female with a history of liver cyst was admitted to the obstetric outpatient clinic for checkup. Patient who did not have any complaints was redirected to radiology clinic for second trimester ultrasound scan. Abdominal ultrasound revealed lesions of type-1 hydatid cyst, 84 × 67 mm in size at the right lobe fifth segment, and 67 × 64 mm in size at the seventh segment of the liver, with millimetric echogenic female cysts and well-defined thick-walls. In addition, a type-2 hydatid cyst with membrane dissociation, 55 × 52 mm in size, was observed at the caudate lobe.

An intrauterine fetus with fetal heart rate was observed with a biparietal diameter concordant with 21 weeks of gestation. Besides, there was a cystic lesion with fine septations surrounding the uterus. The patient was admitted to the obstetric care service with hydatid cyst hydatidosis in the vicinity of the uterus. Only microcytic anemia was detected in the complete blood count. Serologic test results were negative. On conventional abdominal and thoracic MRI, there were 3 cystic lesions up to 8 cm in diameter, which were hyperintense in the T2-weighted images; there were thin hypointense septas on the lesion in the dome of the liver (Fig. 1).

In T2-weighted images, a hyperintense thick-walled cystic lesion up to 5 cm in diameter at its thickest region was observed in the pelvic region around the uterus (Fig. 2). Two hy-

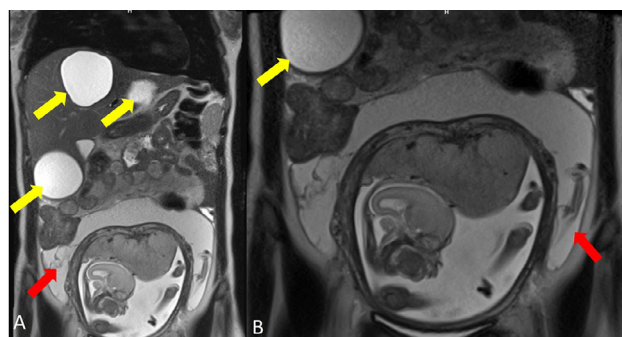


Fig. 3 – In the unenhanced coronal T2-weighted images, 1 hyperintense type-2 hydatid cyst with hypointense thin-walled membrane surrounding the pregnant uterus at the pelvic region.

perintense cystic lesions up to 4 cm in diameter were observed in T2-weighted images, at the left lobe of the thorax (Fig. 3). Albendazole was not considered for treatment, since it was listed in Food and Drug Administration's pregnancy category C. Surgical intervention was preferred, and the patient was informed about the clinical condition and her written consent was obtained. Under general anesthesia, supraumbilical midline abdominal incision was performed to reach the cystic lesions at the liver and around the uterus. Rock water appearance was observed in the aspiration material. The cysts were aspirated and washed with 20% hypertonic saline solution. The cyst around the uterus was attempted to be excised, but the posterior segment could not be reached. Omentum was pulled in to the cystic lesions at the liver and abdominal tube drainage was performed. By performing thoracotomy under general anesthesia, thoracic lesions were reached, the cysts were aspirated and washed with 20% hypertonic saline; the cavity was drained and the surgery site was sutured and closed. Patient did not have any postoperative problems during her pregnancy. The patient was discharged with normal delivery on the 39th week of gestation.

Discussion

There is limited data on the course of symptomatic hydatid disease in pregnancy. Reduced cell-mediated immunity associated with pregnancy causes hydatid disease to progress rapidly and become symptomatic [6]. Patients with pelvic hydatid cysts may suffer from obstetric complications such as dystocia, premature labor, abdominal pain, and uterine rupture [7]. It is important that obstetricians carefully determine the course of birth even, when there is the risk of anaphylactic shock due to cyst rupture during labor. Despite numerous publications on echinococcosis, there is limited knowledge about the disease in pregnant women. The prevalence of the disease in pregnancy ranges from 1 in 20,000 to 30,000. The disease is usually asymptomatic but reported to cause anaphylaxis during ruptured labor [8]. In order to evaluate the acute status of a pregnant patient, nonionizing modalities such as MRI and

ultrasound (US) should be preferred [9]. US has the advantage of real time application, and thus is the primary method for evaluating hydatid cysts to make Gharbi classification based on daughter vesicle, separated membrane, thickened wall, and calcification [10]. MRI is also a nonionizing imaging modality. Water-based T2-weighted images are hyperintense in cystic lesions and are easy to distinguish.

It is difficult to evaluate thoracic cysts with US due to the air in the lungs. MRI is ideal for imaging thoracic cysts. It is also helpful for the classification of hydatid cysts. Gharbi type-1 cysts appear as thin-walled cystic lesions in T2-weighted images, which show the presence of a thin, hypointense, and floating membrane. In the hyperintense, Gharbi type-2 cyst; a thick hypointense wall is observed in the T2-weighted images. Cysts with membrane dissociation are Gharbi type-3 cysts. In T2-weighted image, Gharbi type-4 cysts appear as hypointense membrane with rough calcification and degenerative membrane. In Gharbi type-5 cysts, hyperintense cyst content decreases and the cyst is filled with degenerative hypointense membranes as well as T2 hypointense rough calcifications [11].

In our case, in T2-weighted images, a hyperintense cystic lesion with thin hypointense halos that completely surrounds the uterus was detected in the pelvic region of the pregnant patient. Treatment of hydatid disease during pregnancy is problematic due to the risk of hepatomegaly-induced rupture, premature birth, anaphylaxis, and intrauterine growth restriction. Albendazole is a medicine that exists in the category C of the medications approved for use in pregnancy. If the benefit to the patient is greater than the potential damage to the fetus, the physician can prescribe the medication. When fetal organogenesis is complete, albendazole can be safely managed [12]. In our case, since there is no consensus on the use of albendazole during pregnancy in the literature, it was not used due to its teratogenic effects. Surgical treatment is the main treatment modality in the management of the hydatid disease, and the operation is personalized according to the number and location of the cysts, the physiological condition of the patient, and the presence of complications such as cyst infection and rupture. Often the location of the hydatid cyst, such as the liver, kidney, and spleen, may not have any effect on the pregnancy [13]. If the cyst is located at the pelvic area, problems may arise during pregnancy and delivery. Examples of pregnant patients with pelvic hydatid cysts with surgical intervention involve those with symptoms that require urgent intervention [14]. For the multiple liver, lung, and pelvic region cysts in our patient, percutaneous treatment was considered, but surgical treatment was chosen since thoracic and pelvic cysts were difficult to interfere with and also had high risk of rupture.

As a result, hydatid disease should be considered among the etiologies of abdominal pain in pregnant patients in en-

dem regions. Asymptomatic hydatid disease, which complicates pregnancy, is caused by a management dilemma. Close monitoring of medical treatment and side effects with albendazole after the first trimester should be considered in patients who are not eligible for surgical treatment. Surgical excision of the cysts may be performed in the second trimester, or in postpartum or concurrently during cesarean delivery. In terms of treatment, each patient should be evaluated individually and the best method should be chosen for both fetus and mother.

REFERENCES

- [1] Kappagoda S, Ioannidis JP. Neglected tropical diseases: survey and geometry of randomised evidence. *Bmj* 2012;345:e6512.
- [2] Shameem M, Bhargava R, Ahmad Z, Fatima N, Shah NN. Mediastinal hydatid cyst rupturing into the pleural cavity associated with pneumothorax: case report and review of the literature. *Can Respir J* 2006;13:211–13.
- [3] Al-Ani A, Elzouki A-N, Mazhar R. An imported case of echinococcosis in a pregnant lady with unusual presentation. *Case Rep Infect Dis* 2013:1–4.
- [4] Akarsu M, Kantar FU, Gülcü A. Echinococcosis. zoonosis. *InTech* 2012:324–70.
- [5] Agha RA, Fowler AJ, Rajmohan S, Barai I, Orgill DP, Afifi R, et al. Preferred reporting of case series in surgery; the PROCESS guidelines. *Int J Surg* 2016;36:319–23.
- [6] Kain KC, Keystone JS. Recurrent hydatid disease during pregnancy. *Am J Obstet Gynecol* 1988;159:1216–17.
- [7] Terek MC, Ayhan C, Ulukuş M, Zekiöglü O, Özkinay E, Erhan Y. Primary pelvic hydatid cyst. *Arch Gynecol Obstet* 2000;264:93–6.
- [8] Seenu V, Misra MC, Tiwari SC, Jain R, Chandrashekar C. Primary pelvic hydatid cyst presenting with obstructive uropathy and renal failure. *Postgrad Med J* 1994;70:930–2.
- [9] Wieseler KM, Bhargava P, Kanal KM, Vaidya S, Stewart BK, Dighe MK. Imaging in pregnant patients: examination appropriateness. *Radiographics* 2010;30:1215–29.
- [10] Gharbi HA, Hassine W, Brauner MW, Dupuch K. Ultrasound examination of the hydatid liver. *Radiology* 1981;139:459–63.
- [11] Garcia-Diez AI, Mendoza LR, Villacampa VM, Cozar M, Fuertes MI. MRI evaluation of soft tissue hydatid disease. *Eur Radiol* 2000;10:462–6.
- [12] Pallua K, Putz G, Mitterschiffthaler G, Brezinka C, Biebl M, Paal P. Management of hepatic echinococcosis in pregnancy. *Int J Gynecol Obstet* 2010;109:162.
- [13] Can D, Oztekin O, Oztekin O, Tinar S, Sancı M. Hepatic and splenic hydatid cyst during pregnancy: a case report. *Arch Gynecol Obstet* 2003;268:239–40.
- [14] Goswami D, Tempe A, Arora R, Chaturvedi KU. Successful management of obstructed labor in a patient with multiple hydatid cysts. *Acta Obstet Gynecol Scand* 2004;83:600–3.