

Cancer Pain Control for Advanced Cancer Patients by Using Autonomic Nerve Pharmacopuncture

Hwi-joong Kang, Jung-won Yoon, Ji-hye Park, Chong-kwan Cho, Hwa-seung Yoo*

East-West Cancer Center, Dunsan Korean Medical Hospital of Daejeon University, Daejeon, Korea

Key Words

autonomic nerve pharmacopuncture, cancer pain, Hua-Tuo-Jia-Ji-Xue, mountain ginseng pharmacopuncture, quality of life

Abstract

Objectives: The purpose of this study is to report a case series of advanced cancer patients whose cancer pain was relieved by using autonomic nerve pharmacopuncture (ANP) treatment. ANP is a subcutaneous injection therapy of mountain ginseng pharmacopuncture (MGP) along the acupoints on the spine (Hua-Tuo-Jia-Ji-Xue; 0.5 cun lateral to the lower border of the spinous processes of vertebrae) to enhance the immune system and to balance autonomic nerve function.

Methods: Patients with three different types of cancer (gastric cancer, lung cancer, colon cancer with distant metastases) with cancer pain were treated with ANP. 1 mL of MGP was injected into the bilateral Hua-Tuo-Jia-Ji-Xue on the T1-L5 sites (total 12 — 20 mL injection) of each patient's dorsum by using the principle of symptom differentiation. During ANP treatment, the visual analogue scale (VAS) for pain was used to assess their levels of cancer pain; also, the dosage and the frequency of analgesic use were measured.

Results: The cancer pain levels of all three patients improved with treatment using ANP. The VAS scores of the

three patients decreased as the treatment progressed. The dosage and the frequency of analgesics also gradually decreased during the treatment period. Significantly, no related adverse events were found.

Conclusion: ANP has shown benefit in controlling cancer pain for the three different types of cancer investigated in this study and in reducing the dosage and the frequency of analgesics. ANP is expected to be beneficial for reducing cancer pain and, thus, to be a promising new treatment for cancer pain.

1. Introduction

Of the cancer-related symptoms, cancer pain is a long-standing and unresolved clinical problem. It has been several decades since the World Health Organization (WHO) came up with the analgesic ladder for pain control, but cancer pain still remains one of the most distressing symptoms for cancer patients [1]. According to a meta-analysis on cancer pain, about half of all cancer patients suffer from cancer-related pain [2], and more than 90% of cancer patients have experienced cancer pain at some points during their treatment for cancer [3].

Acupuncture, a traditional Oriental medicine modality, is used in supportive care for cancer pain [4, 5]. Pharmacopuncture is a relatively new form of acupuncture treatment combining meridian-theory-based acupuncture and herbal therapy. While

Received: Aug 20, 2014 Accepted: Aug 29, 2014

© This is an Open-Access article distributed under the terms of the Creative Commons Attribution Non-Commercial License (<http://creativecommons.org/licenses/by-nc/3.0/>) which permits unrestricted noncommercial use, distribution, and reproduction in any medium, provided the original work is properly cited.

© This paper meets the requirements of KS X ISO 9706, ISO 9706-1994 and ANSI/NISO Z39.48-1992 (Permanence of Paper).

*Corresponding Author

Hwa-Seung Yoo. East-West Cancer Center, Dunsan Korean Medical Hospital of Daejeon University, 176-75 Daedukdaero, Seo-gu, Daejeon 302-122, Korea
Tel: +82-42-470-9132 Fax: +82-42-470-9006
E-mail: altyhs@dju.kr

existing acupuncture treatment incorporates physical stimulation of associated meridians and acupoints, pharmacopuncture adds the medicinal effect of herbs injected to the regular effect of acupuncture. Similar to pharmacopuncture is Chinese aqua-acupuncture and European homeopathy. The concept of pharmacopuncture was first introduced to Korea in 1967, and many herbal injections have been researched and developed since then [6]. Pharmacopuncture is mostly used in treating musculo-skeletal disorders, including degenerative arthritis, arthralgia, lumbago, and sprains [7]. The Soyueum (anti-inflammatory) [8] and Bee Venom [9] types of pharmacopuncture have also shown effect in managing cancer pain to some extent. The mountain ginseng pharmacopuncture (MGP) has been shown to improve the quality of life and the survival time in peritoneal-cancer-induced animal models and to suppress tumor growth in colon cancer in liver-metastasized animal models compared to controls [10]. Cases of improved survival times and qualities of life in patients with lung, rectal and gastric cancer types have also been reported [11].

Autonomic nerve pharmacopuncture (ANP) is a subcutaneous injection therapy of mountain ginseng pharmacopuncture along the acupoints on the spine (Hua-Tuo-Jia-Ji-Xue) to enhance the immune system and to balance autonomic nerve function. It contains various flavonoid components from distilled mountain ginseng extract. To briefly explain the process of making mountain ginseng pharmacopuncture, 100 g of wild mountain ginseng is decocted in distilled water for 2 hours, and the decoction is distilled to produce 1,000 mL of pharmacopuncture fluid, which, in turn, is filtered with 0.45- μ m and 0.2- μ m filters and sterilized in vials [12]. It is particularly used to treat patients with deficiency conditions, especially for patients with extreme qi deficiency who are receiving chemotherapy or who have terminal cancer. 1 mL of MGP is injected into each of the bilateral Hua-Tuo-Jia-Ji points (0.5 cun lateral to the lower border of the spinous processes of vertebrae) on the T1-L5 sites (total 12 — 20 mL injection) by using the principle of symptom differentiation [13]. Clinically, we have used ANP at the East-West Cancer Center, Dunsan Korean Medical Hospital, since 2013 for managing cancer pain, cancer-related fatigue, etc. However, there have been no previous studies on ANP for managing cancer pain. Here, the authors report three cases in which cancer pain was controlled using ANP and in which the dosage and the frequency of analgesics was gradually reduced.

2. Case report

2.1. Case 1

This case involved a 41-year-old female patient with a weight of 46.5 kg and a height of 161 cm. The initial diagnosis was made in August, 2011. The pathological diagnosis showed a signet ring cell carcinoma, with chronic mild superficial gastritis. Biopsy revealed a moderately-differentiated tubular adenocarcinoma. The primary lesion was located in the middle third of the stomach (center at the body's anterior wall). Initially 5 of 59 lymph nodes were positive, and metastases were present in the periportal area, Rt. periureter, ascending colon, and transverse colon. The initial stage of the cancer was IIB (pT2N2); the present stage is IV. A total gastrectomy was performed on September 1, 2011, and chemotherapy was administered from December 2011 to July 2012 (a total of 6 times). Common complaints were abdominal pain, diarrhea, nausea, and fatigue. A gastric ulcer had been noted around the year 2000. Adhesion and obstruction of the small bowel were also noted, and surgery was performed on September 8, 2011.

From September 2, 2013, to October 17, 2013, the patients received acupuncture and ANP treatments, as well as analgesics. Acupuncture was administered once a day for 15 minutes each time at acupoints LI11, TE5, LI4, SP10, SP9, ST36, SP6, and LR3. ANP was administered from September 23, 2013, to October 15, 2013, for a total of 20 times. Analgesics included oxycodone hydrochloride (5 mg) and fentanyl (25 mcg/hr).

This patient was initially diagnosed with advanced gastric cancer, which later metastasized to the large intestines in April 2012. The patient refused chemotherapy and only received traditional Korean medicine treatment. Her main complaints were right abdominal tenderness with diarrhea, colicky pain in the ascending and the transverse colon, epigastric bloating after meals and heartburns at night. These different types of pain in multiple sites are common in patients with intraperitoneal metastases as infiltration, compression and distention in the intra-abdominal and the pelvic-cavity regions can stimulate nociceptors and lead to visceral pain. Paralytic ileus caused by opioid analgesics and disturbance of the peritoneal blood supply were also considered to be factors affecting her severe sporadic abdominal pain. At the time of admission, the patient was using opioid analgesics (oxycodone and fentanyl patch) for pain control. After admission, 10 days into receiving the ANP, the patient was able to stop using the fentanyl transdermal patch (25 mcg/hr) and to reduce the amount of oral oxycodone (5-mg tablets) to 1 — 2 tablets a day. The visual analogue scale (VAS) score declined from 7 to 3. With the decreased use of opioid analgesics, adverse effects, such as sedation and nausea, were also

improved (Table 1, Fig. 1, 2).

2.2. Case 2

This case involved a 51-year-old female patient, with a weight of 63 kg and a height of 160 cm. The initial diagnosis was made in January 2010; the pathological diagnosis showed a bronchioalveolar carcinoma, and biopsy revealed an adenocarcinoma. The primary lesion was lo-

cated in the right upper lobe (RUL) of the lung. Initially no lymph nodes tested positive, but metastasis- was found in the Rt. pleura in February 2013. The initial stage of the cancer was IA (TNM: pT1bN0), and the present stage is IV. A RUL lobectomy and a wedge resection of the right middle lobe (RML) were performed on February 16, 2010, and chemotherapy was administered from February 21, 2013, to the present (p.o. Iressa). Common complaints were diz-

Table 1 Laboratory findings (case 1)

Laboratory Findings	Unit	Normal Range	130913	130927	131011	131016
Albumin	g/dL	3.5 — 5.2	3.5	3.9	4.1	4.3
Aspartate transaminase, AST	U/L	0 — 31	16	13	20	29
Alanine transaminase, ALT	U/L	0 — 34	13	8	18	23
Creatinine	mg/dL	0.66 — 1.09	0.78	0.68	0.69	0.72
Blood urea nitrogen, BUN	mg/dL	7.9 — 20	~6.6	~5.6	17.4	15.8
Sodium, Na	mEq/L	135 — 147	137	144	139	139
Potassium, K	mEq/L	3.3 — 5.1	3.4	3.4	4.2	4.3
Chloride, Cl	mEq/L	95 — 110	104	106	104	103
Red blood cell, RBC	10 ⁶ mm ³	4 — 7.2	~3.22	~3.68	~3.50	~3.80
Hemoglobin	g/dL	12 — 16	~8.1	~9.3	~8.9	~9.5
Hematocrit	%	36 — 46	~24.5	~28.0	~26.3	~28.6
Erythrocyte sedimentation rate, ESR	mm/hr	0 — 20	8	30~	26~	29~

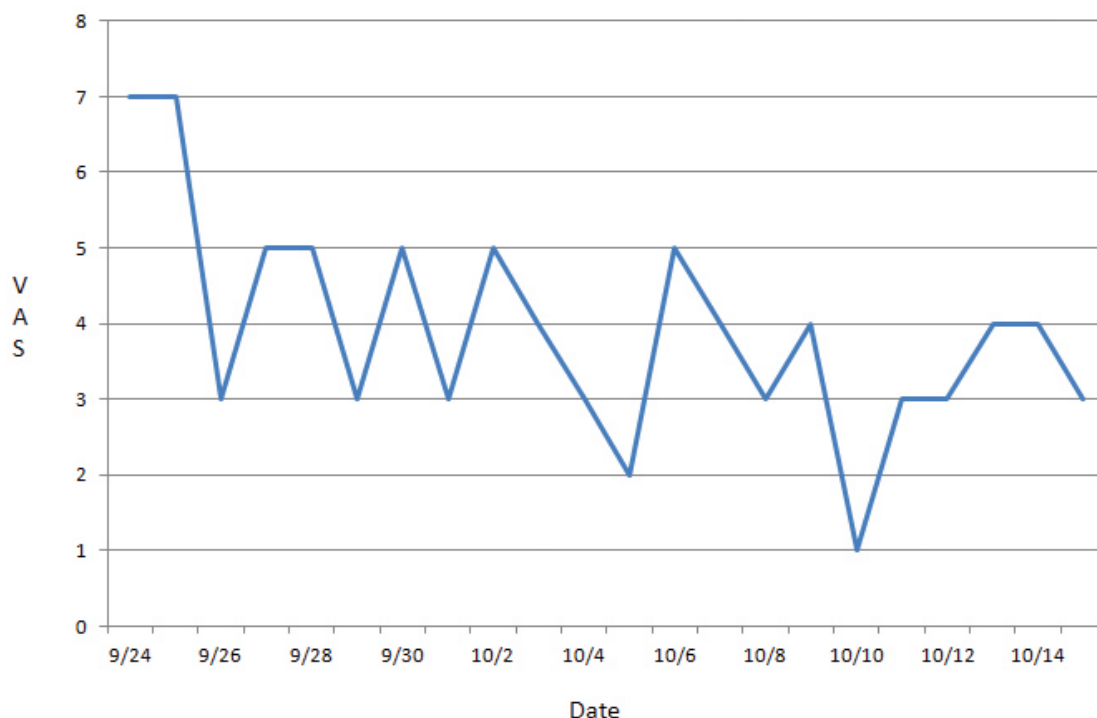


Figure 1 Visual analogue scale (VAS) changes of case 1.

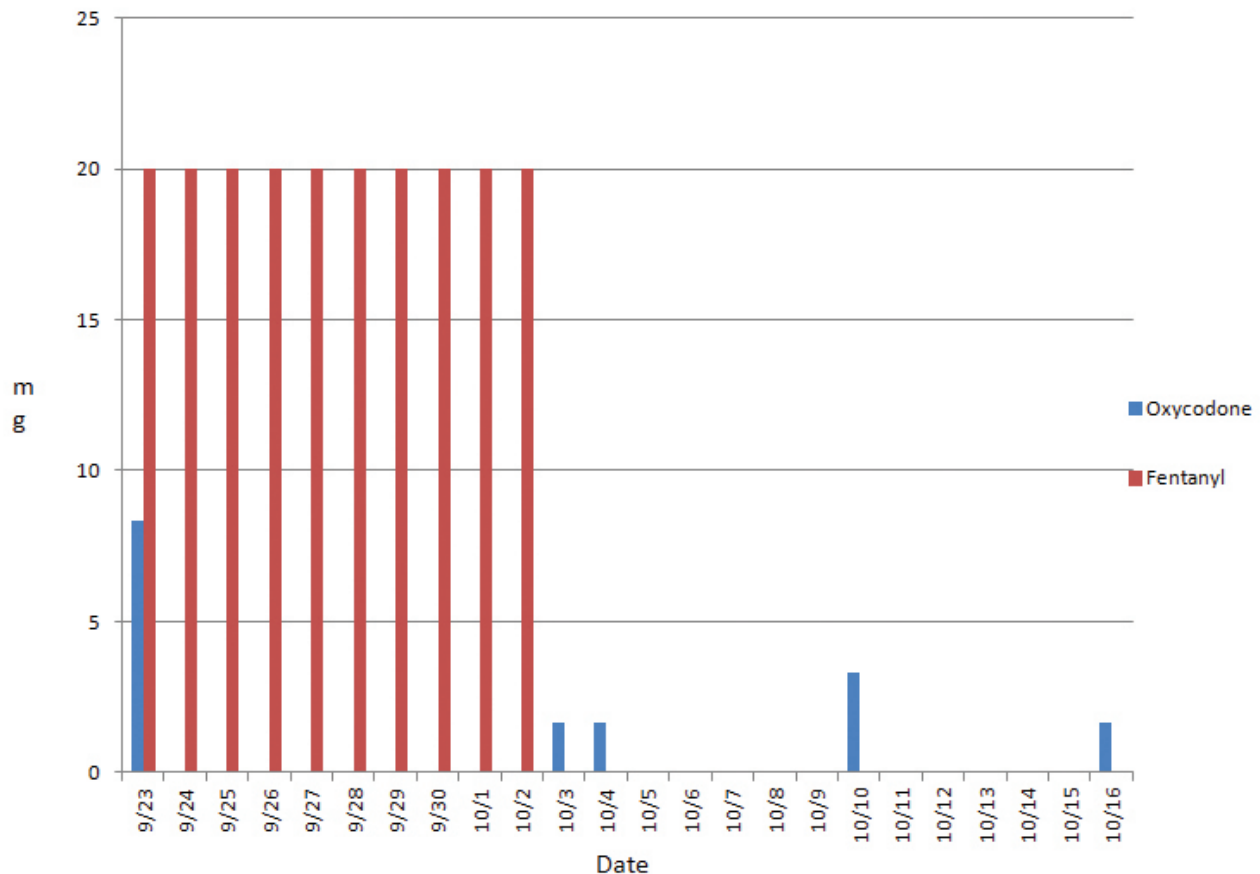


Figure 2 Changes in Dosage of analgesics in case 1. x axis, date used; y axis, dosage of morphine used in mg.

ziness, nausea, vomiting, insomnia, fatigue, diarrhea, and dyspnea.

Medications included Iressa (Gefitinib) 250 mg 1-0-0 antineoplastics. Pulmonary tuberculosis (Rt. lung) was diagnosed in 2008.

The patients was admitted from December 9, 2013, to January 7, 2014, and ANP was administered from December 23, 2013, to January 2, 2014, for a total of 5 times. No analgesics were used.

The patient was initially diagnosed with an adenocarcinoma of the lung in the right upper lobe region and received a RUL lobectomy and a RML wedge resection. After 3 years of follow-up, pleural metastases were confirmed. After taking oral anti-tumor medication for a month, the patient complained of a rash, dry skin, and diarrhea, and 5 days after admission, she also mentioned having pain in the right flank. The pain was described as an electric-shock sensation that radiated from the right flank to the inner upper right abdominal region with a VAS score as high as 7 when severe. This type of cancer pain was suspected to be caused by pleural seeding. The pain disappeared the day after her first ANP treatment. After 5 treatments of ANP, the patient was discharged from the hospital pain free (VAS

score = 0). The patient was able to perform daily activities without taking any analgesics during her admission (Table 2, Fig. 3).

2.3. Case 3

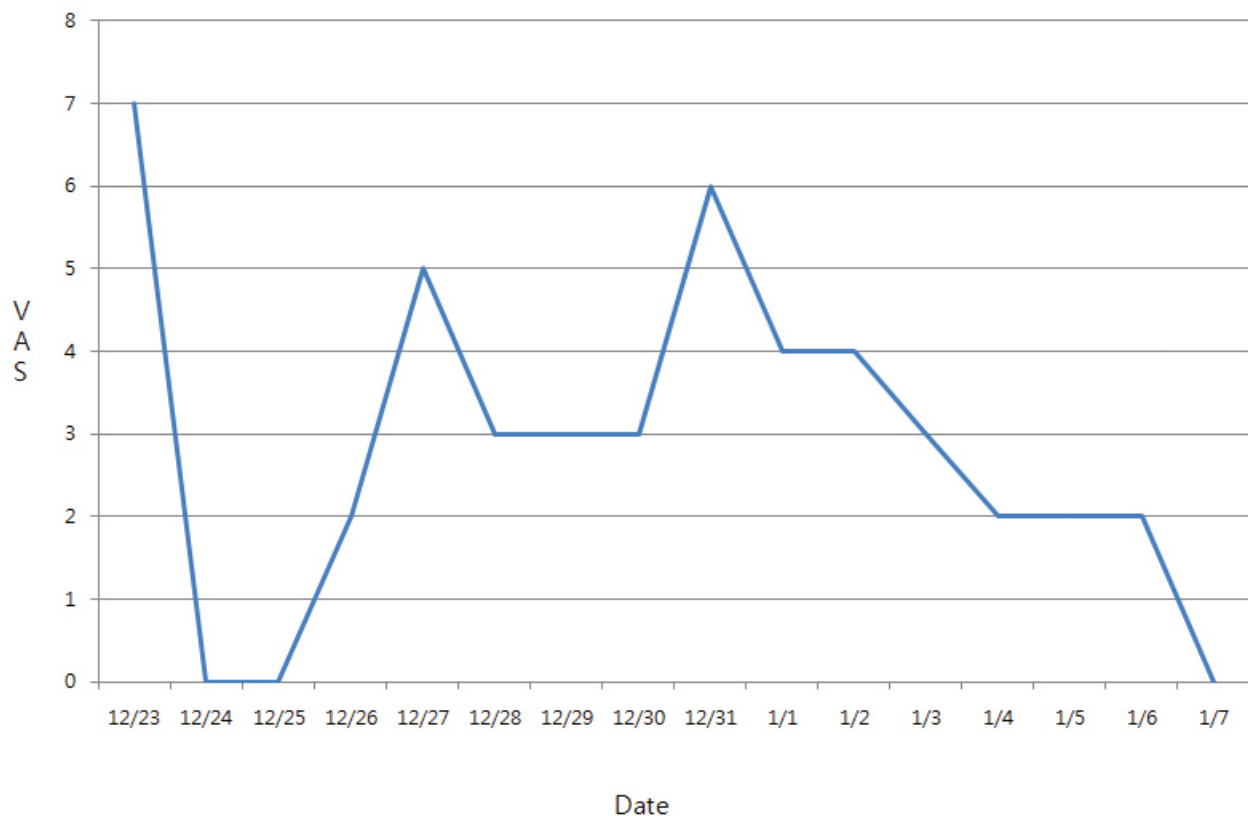
This case involved an 81-year-old male patient with a weight of 58 kg and a height of 167 cm.

The initial diagnosis was made on October 31, 2013. The pathological diagnosis was a tubulovillous adenoma 15 cm above the anal verge, and biopsy revealed a neuroendocrine carcinoma, with the primary lesion located in the rectosigmoid colon. Initially, the parasacral lymph nodes were positive and metastasis was detected in the liver. The initial stage of the cancer was IVA. She had undergone neither surgery nor chemotherapy. Common complaints were diarrhea, abdominal discomfort, rash, and dyspnea.

The patient was admitted from November 13, 2013, to December 14, 2013, and ANP was administered from November 18 to December 14, 2013, for a total of 13 times. The analgesics Diclofenac (2 mL, IM injection) was used as follows: 11/15/2013: at 18:00, 0.5 ample and at 24:00, 0.5 ample, 11/16/2013: at 9:00, 0.5 ample and at 20:00, 1 ample, 11/17/2013: at 10:00, 0.5 ample, 11/21/2013: at 17:00, 0.5

Table 2 Laboratory findings (case 2)

Laboratory Findings	Unit	Normal Range	131220	140106
Albumin	g/dL	3.5 — 5.2	4.4	4.5
Aspartate transaminase, AST	U/L	0 — 31	19	20
Alanine transaminase, ALT	U/L	0 — 34	17	17
Creatinine	mg/dL	0.66 — 1.09	0.78	0.72
Blood urea nitrogen, BUN	mg/dL	7.9 — 20	11.1	14.5
Sodium, Na	mEq/L	135 — 147	145	142
Potassium, K	mEq/L	3.3 — 5.1	4.4	4
Chloride, Cl	mEq/L	95 — 110	106	107
Red blood cell, RBC	10 ⁶ mm ³	4 — 7.2	~3.88	~3.80
Hemoglobin	g/dL	12 — 16	12.5	12.3
Hematocrit	%	36 — 46	37	36.2
Erythrocyte sedimentation rate, ESR	mm/hr	0 — 20	6	7

**Figure 3** Visual analogue scale (VAS) changes of case 2.

ample, 12/03/2013: at 17:00, 0.5 ample, and 12/11/2013: at 12:00, 0.5 ample.

This patient was admitted to the hospital with a diagnosis of a neuroendocrine tumor of the colon with multiple liver metastases. On the third day, he complained of acute right

upper quadrant (RUQ) pain, but no unusual findings of the intra-peritoneal cavity were seen in the CT imaging. The ANP injections were given every day or every other day for his pain, and the VAS score was down to 1-2 on most days, with some days being pain free. After the autonomic nerve

treatment, the patient's condition was improved enough so that only a 1 mL injection of Diclofenac sodium was needed to effectively manage his sporadic pain episodes (Fig. 4). Laboratory findings showed that the liver and the

kidney functions were getting worse, but that was considered not to be due to drug-induced liver injury but to the natural progression of the disease (Table 3).

Table 3 Laboratory findings (case 3)

Laboratory Findings	Unit	Normal Range	131113	131125	131202	131211	131213
Albumin	g/dL	3.5 — 5.2	4.1	3.5	4	3.9	3.9
Aspartate transaminase, AST	U/L	0 — 31	44~	59~	67~	96~	104~
Alanine transaminase, ALT	U/L	0 — 34	20	20	24	38	39
Creatinine	mg/dL	0.66 — 1.09	1.34	1.37	1.36	2.14~	3.82~
Blood urea nitrogen, BUN	mg/dL	7.9 — 20	24.3~	23.9~	21.1~	33.9~	56.0~
Sodium, Na	mEq/L	135 — 147	139	~134	~133	127	~129
Potassium, K	mEq/L	3.3 — 5.1	4.7	5	6.1~	5.4~	6.1~
Chloride, Cl	mEq/L	95 — 110	107	104	102	96	95
Red blood cell, RBC	10 ⁶ mm ³	4 — 7.2	~3.79	-	~4.01	~3.83	~3.98
Hemoglobin	g/dL	12 — 16	~12.3	-	13	~12.7	~12.9
Hematocrit	%	36 — 46	~35.7	-	39.4	~37.3	38.8
Erythrocyte sedimentation rate, ESR	mm/hr	0 — 20	23~	-	24~	23~	34~

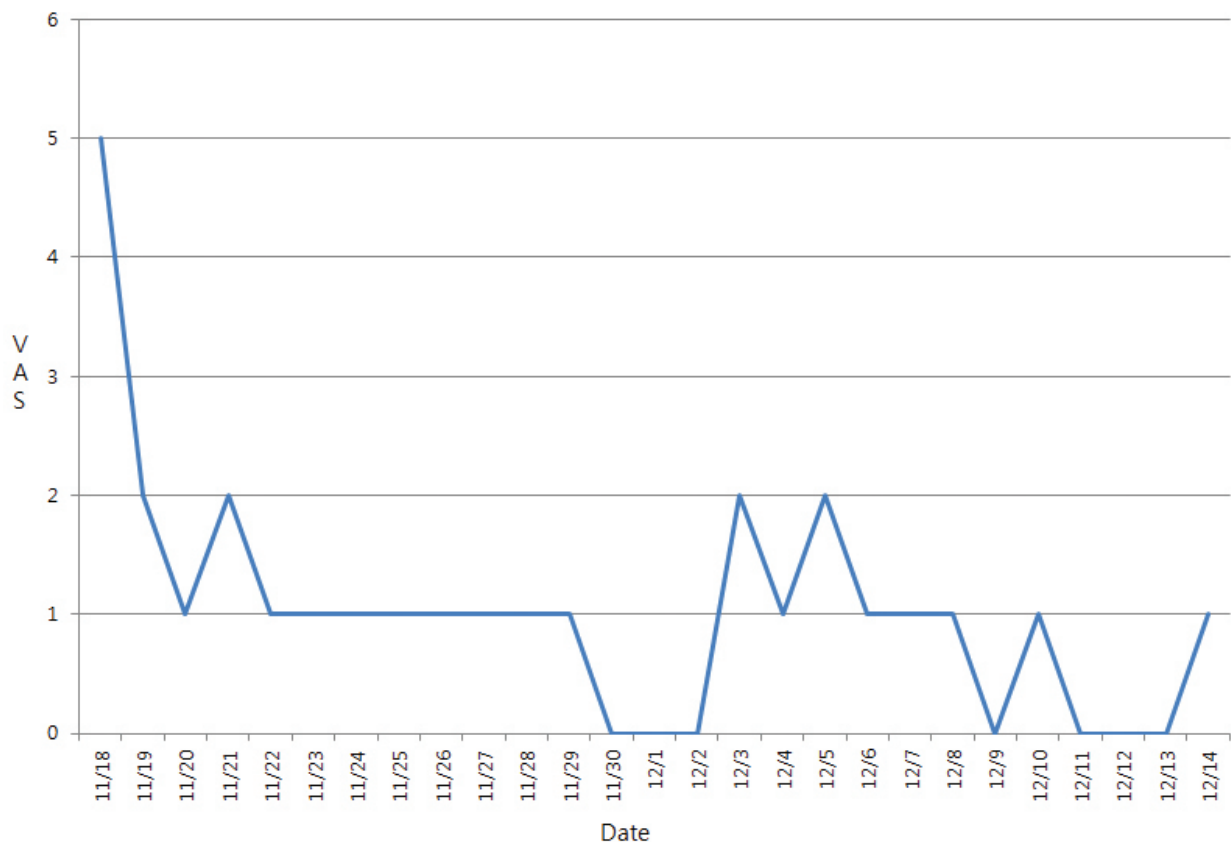


Figure 4 Visual analogue scale (VAS) changes of case 3.

3. Discussion

Pain in cancer is brought on by a combination of biological, psychological and social factors [14]. The analgesic effect induced by acupuncture strongly influences the psychological aspect of pain [15]. Despite the small amount of clinical research done on acupuncture for cancer pain, numerous studies on non-cancer-related pain, e.g., pain associated with osteoarthritis [16] and lumbago [17], chronic knee pain [18], shoulder pain [19], neck pain [20], and dental pain [21], support the effectiveness of acupuncture for alleviating pain of different types. For cancer-related pain, randomized controlled clinical trials have reported acupuncture to be beneficial for cancer pain [22], post-thoracotomy pain in cases of an operable non-small cell lung carcinoma [23], and post-operative pain in cases of breast cancer, bladder cancer, prostate cancer, and ovarian cancer [24].

The mechanism of acupuncture's analgesic effect is still not clear despite its wide usage and the large amount of research. According to research on mice models, adenosine, a neuromodulator with anti-nociceptive actions, is released during acupuncture, and the expression of the adenosine A1 receptor is believed to mediate the analgesic effect of acupuncture [25]. The main ingredient of the ANP, cultivated mountain ginseng, a species of *Panax ginseng*, is one of the chief herbs for invigorating Qi. It is used to tonify primordial energy, augment the middle, recover Qi exhaustion, generate body fluid and stabilize the mind. When ginseng extract is administered to rats intra-nasally for 1 week before ischemia onset, the extract has been reported to inhibit activation of inflammatory cells, to down-regulate pro-inflammatory cytokines, and to suppress a key transcription factor [26]. Therefore, when acupoint injection is used, a synergism of the effects of acupoint stimulation and of easy and fast delivery of the herb's medicinal properties is anticipated. The Hua-Tuo-Jia-Ji points, located bilaterally along the lower border of the spinous processes of T1-L5, are traditionally used to regulate internal organs. The Hua-Tuo-Jia-Ji points are also reported to trigger an analgesic effect through the secretion and the synthesis of neurotransmitters such as acetylcholine, serotonin, adrenalin, dopamine, gamma-aminobutyric acid (GABA) and endorphins [13].

4. Conclusion

Three patients with different types of advanced cancer who received ANP in this case series showed reduced degree of pain. The VAS scores of the patients decreased

during the treatment period. In addition, as the treatment progressed, the analgesics dosage of two patients gradually decreased. In the study, ANP was shown to be beneficial in controlling cancer pain. Although these cases had successful outcomes, caution is needed in generalizing these results as the findings may not be transferable; further research is needed to establish the benefits of using ANP for cancer pain management.

Conflict of interest

The authors declare that there are no conflict of interest.

References

- Marcus DA. Epidemiology of cancer pain. *Curr Pain Headache Rep.* 2011;15:231-4.
- Shaheen PE, Legrand SB, Walsh D, Estfan B, Davis MP, Lagman RL, *et al.* Errors in opioid prescribing: a prospective survey in cancer pain. *J Pain Symptom Man.* 2010;39(4):702-11.
- Goudas LC, Bloch R, Gialeli-Goudas M, Lau J, Carr DB. The epidemiology of cancer pain. *Cancer Invest.* 2005;23(2):182-90.
- Lu W, Dean-Clower E, Doherty-Gilman A, Rosenthal DS. The value of acupuncture in cancer care. *Hematol Oncol Clin North Am.* 2008;22(4):631-48.
- O Regan D, Filshie J. Acupuncture and cancer. *Auton Neurosci.* 2010;157(1-2):96-100.
- Korean institute of herbal acupuncture. [Pharmacopunctureology]. 1sted. Seoul: ELSEVIER; 2008; p. 3-5, 229-29. Korean.
- Park BK, Cho JH, Son CG. Randomized clinical controlled trials with herbal acupuncture (pharmacopuncture) in Korea - a systematic review. *J Korean Oriental Medicine.* 2009;30(5):115-26.
- Yoo HS, Cho JH, Cho CK. [Effects of herbal acupuncture (soyeum) on cancer patients accompanied by pain]. *J Pharmacopunct.* 2003;6(1):16-7. Korean.
- Yoo HS, Kim JS. [The effect of sweet bee venom pharmacopuncture (SBVP) on cancer-related pain: a randomized controlled trial and double blinded - pilot study]. *J Pharmacopunct.* 2008;11(1):21-9. Korean.
- Lim SY, Lee SJ, Kwon KR. Anti-cancer and immune promoting effects of cultivated wild ginseng herbal acupuncture on hepatic metastatic model using colon26-L5 carcinoma cells. *J Korean Acupunct Mox.* 2006;23(1):121-34.
- Lee JH, Kwon KR, Cho CK, Han SS, Yoo HS. Advanced cancer cases treated with cultivated wild gin-

- seng pharmacopuncture. *J Acupunct Meridian Stud.* 2010;3(2):119-24.
12. Han JB, Im CR, Lee JW, Kim SS, Seong S. A case of inoperable klatskin tumor showing response to wild ginseng pharmacopuncture, *Orient Pharm Exp Med.* 2013;13(3):235-7.
 13. Heo TY, Wang YM. [Huatuojiayizhibailing]. Beijing: Zzhongguoyiyaokejichubanshe; 2007. 25 p. Chinese.
 14. Clark D. 'Total pain,' disciplinary power and the body in the work of cicely saunders. *Soc Sci Med.* 1999;49(6):727-36.
 15. Kaptchuk TJ, Stason WB, Davis RB, Legedza ART, Schnyer RN, Kerr CE, *et al.* Sham device v inert pill: randomised controlled trial of two placebo treatments. *BMJ.* 2006;332:391-7.
 16. Kwon YD, Pittler MH, Ernst E. Acupuncture for peripheral joint osteoarthritis: a systematic review and meta-analysis. *Rheumatology (Oxford Journals).* 2006;45(11):1331-7.
 17. Furlan A.D, van Tulder MW, Cherkin DC, Tsukayama H, Lao L, Koes BW, *et al.* Acupuncture and dry-needling for low back pain. *Cochrane Database Syst Rev.* 2005;25(1):CD001351.
 18. White A, Foster NE, Cummings M, Barlas P. Acupuncture treatment for chronic knee pain: a systematic review. *Rheumatology (Oxford Journals).* 2007;46(3):384-90.
 19. Manheimer E, Linde K, Lao L, Bouter LM, Berman BM. Meta-analysis: acupuncture for osteoarthritis of the knee. *Ann Intern Med.* 2007;146(12):868-77.
 20. Green S, Buchbinder R, Hetrick S. Acupuncture for shoulder pain. *Cochrane Database Syst Rev.* 2005;18(2):CD005319.
 21. Trinh K, Graham N, Gross A, Goldsmith CH, Wang E, Cameron ID, *et al.* Acupuncture for neck disorders. *Cochrane Database Syst Rev.* 2006;19(3):CD004870.
 22. Garcia MK, Driver L, Haddad R, Lee R, Palmer JL, Wei Q. *et al.* Acupuncture for treatment of uncontrolled pain in cancer patients: a pragmatic pilot study. *Integr Cancer Ther.* 2014;13(2):133-40.
 23. Wong RH, Lee TW, Sihoe AD, Wan IY, Ng CS, Chan SK, *et al.* Analgesic effect of electroacupuncture in post-thoracotomy pain: a prospective randomized trial. *Ann Thorac Surg.* 2006;81(6):2031-6.
 24. Mehling WE, Jacobs B, Acree M, Wilson L, Bostrom A, West J, *et al.* Symptom management with massage and acupuncture in postoperative cancer patients: a randomized controlled trial. *J Pain Symptom Manage.* 2007;33(3):258-66.
 25. Goldman N, Chen M, Fujita T, Xu Q, Peng W, Liu W, *et al.* Adenosine A1 receptors mediate local anti-nociceptive effects of acupuncture. *Nat Neurosci.* 2010;13(7):883-8.
 26. Zhu J, Jiang Y, Wu L, Xu G, Liu X. Suppression of local inflammation contributes to the neuroprotective effect of ginsenoside Rb1 in rats with cerebral ischemia. *Neuroscience.* 2012;202:342-51.