

## Periorbital and Mediastinal Emphysema after Upper Gastrointestinal Endoscopy: Case Report of a Rare Complication

Thankappan Lekha<sup>1</sup>, FRCS; Leelakrishnan Venkatakrishnan<sup>2</sup>, DM; Karuppannasamy Divya<sup>1</sup>, MS  
Perumal Lavanya<sup>1</sup>, MBBS

<sup>1</sup>Department of Ophthalmology, PSG Institute of Medical Sciences and Research, Coimbatore, Tamilnadu, India

<sup>2</sup>Department of Gastroenterology, PSG Institute of Medical Sciences and Research, Coimbatore, Tamilnadu, India

### Abstract

**Purpose:** To report a rare case of periorbital emphysema concurrent with cervicofacial and mediastinal emphysema in an elderly woman who underwent upper gastrointestinal endoscopy for chronic liver disease.

**Case Report:** An elderly woman with decompensated chronic liver disease presented with features of periorbital, facial, and mediastinal emphysema, characterized with crepitant swelling over the right periorbital area, face, neck, and mediastinum after undergoing upper gastrointestinal endoscopy. There was no history of trauma or Valsalva maneuver. Ocular findings were stable with no evidence of orbital compartmental syndrome. Urgent computed tomography scans of the orbit and chest were performed, and emergency systemic treatment with nasogastric decompression and antibiotics was initiated. However, she suddenly collapsed and succumbed despite all resuscitative efforts.

**Conclusion:** Our case demonstrates that periorbital emphysema can occur following procedures such as upper gastrointestinal endoscopy, in the eyes without history of local trauma. This complication should be suspected especially if there is associated cervicofacial and mediastinal emphysema. Subcutaneous emphysema is usually self-resolving; however, extension of air into deeper planes can cause dangerous complications such as blindness due to orbital emphysema or mortality due to mediastinal emphysema. Hence, prompt diagnosis and urgent intervention are crucial to avoid vision and life threatening complications.

**Keywords:** Mediastinal Emphysema; Periorbital Emphysema; Upper Gastrointestinal Endoscopy

*J Ophthalmic Vis Res* 2017; 12 (3): 345-347

### INTRODUCTION

Periorbital emphysema or abnormal presence of air within the soft tissues of the orbit most commonly results from

#### Correspondence to:

Thankappan Lekha, FRCS. Marutham Maagnus, V.K.K. Menon Road, New Siddhapudur, Coimbatore 641004, Tamil Nadu, India.

E-mail: lekhat@rediffmail.com

Received: 17-12-2015

Accepted: 30-05-2016

orbital fracture with a paranasal sinus communication.<sup>[1,2]</sup> It presents as a transient, crepitant swelling of the lids and periorbital areas. Rarely, trapped intraorbital air can lead to compressive orbital emphysema, which can threaten vision due to central retinal artery occlusion or ischemic optic neuropathy. Mediastinal emphysema is the presence of extra-alveolar air in the mediastinum and can be spontaneous or due to severe thoraco-abdominal injury.<sup>[3]</sup> The patient may be asymptomatic or develop

This is an open access article distributed under the terms of the Creative Commons Attribution-NonCommercial-ShareAlike 3.0 License, which allows others to remix, tweak, and build upon the work non-commercially, as long as the author is credited and the new creations are licensed under the identical terms.

For reprints contact: reprints@medknow.com

**How to cite this article:** Lekha T, Venkatakrishnan L, Divya K, Lavanya P. Periorbital and mediastinal emphysema after upper gastrointestinal endoscopy: Case report of a rare complication. *J Ophthalmic Vis Res* 2017;12:345-7.

#### Access this article online

##### Quick Response Code:



##### Website:

www.jovr.org

##### DOI:

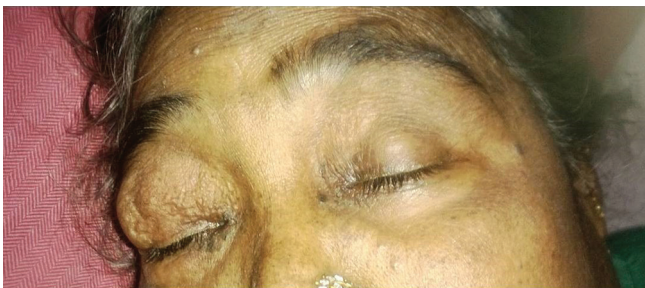
10.4103/jovr.jovr\_270\_15

chest pain, cough, vomiting, and even cardiopulmonary distress, which can be fatal. Prompt diagnosis using Computed Tomography (CT) and urgent intervention of these conditions by decompression is paramount to prevent blindness due to orbital emphysema or fatality due to mediastinal emphysema. We describe a case of an elderly woman who developed simultaneous periorbital and mediastinal emphysema following upper gastrointestinal endoscopy with a fatal outcome. To the best of our knowledge, this is the first report of such a rare complication.

## CASE REPORT

Our patient was a 74-year-old woman, who underwent treatment in the gastroenterology department of our hospital for decompensated chronic liver disease, cirrhosis of liver with portal hypertension, volume overload status, and dysphagia. An ophthalmology consultation was arranged when she complained of swelling of the right upper and lower eyelids following a routine upper gastrointestinal endoscopy. It was not associated with defective vision, diplopia, pain, or redness. She also complained of hoarseness of voice without breathing difficulties. There was no history of trauma, forceful nose blowing, or Valsalva maneuver. Past medical history revealed cataract surgery in both eyes four years ago.

On examination, she was conscious, oriented, and afebrile with no respiratory distress. She was obese with ascites, pedal edema, and puffiness of face. There was swelling of the right upper and lower lids and periorbital area with mechanical ptosis. Palpation revealed crepitus suggestive of emphysema. Generalized swelling and crepitus were also noted over the face, neck, and front of the chest [Figures 1 and 2]. On ocular examination, vision was 6/9, N.6 in both eyes. Pupils were briskly reacting, and the extraocular movements were full. There was no proptosis, conjunctival congestion, chemosis, or discharge. Both eyes were pseudophakic with normal intraocular pressure and fundus. As there was no pressure effect on the globe, she was treated conservatively with antibiotics and decongestants. She

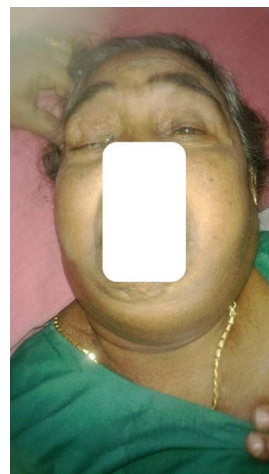

**Figure 1.** External photograph of the face showing corrugated appearance of the right upper eyelid due to the presence of subcutaneous air, suggesting emphysema.

was advised to avoid nose blowing or straining and to inform immediately if any visual change is noticed. Nevertheless, considering the features of periorbital and mediastinal emphysema, she was advised to undergo emergency CT scan of the orbit and chest, and immediate gastric aspiration and antibiotic therapy were initiated by the physician. However, the patient developed sudden seizures followed by collapse, and could not be revived despite aggressive resuscitative efforts.

## DISCUSSION

Subcutaneous emphysema in the head and neck region occurs when air is introduced into the fascial planes of the connective tissue through a site of trauma.<sup>[4,5]</sup> The trapped air may sometimes extend deep along the facial planes of the neck causing para- and retropharyngeal emphysema with possible extension into the thorax and mediastinum. This complication, although rare, can be life threatening due to close proximity to vital structures in the neck and mediastinum. Orbital and cervicofacial emphysema extending into the mediastinum have been reported following orofacial trauma including fractures, compressed air injuries, and dental procedures involving the use of high speed air-driven hand pieces.<sup>[3,5-7]</sup> Similarly pneumomediastinum, pneumoperitoneum, and subcutaneous emphysema are known complications following procedures such as upper endoscopy, endoscopic retrograde cholangiopancreatography (ERCP), and colonoscopy, and can occur with or without perforation.<sup>[8-10]</sup> Pathophysiology of these complications is explained by the anatomical connections between the deep neck fascia, mediastinum, and retroperitoneum, and continuous air insufflations during procedures such as ERCP. When a perforation occurs, free air flows from the duodenum to the retroperitoneal space



**Figure 2.** External photograph of the face and upper part of chest showing emphysema involving the right periorbital area, face, and neck.

and then extends to diaphragmatic hiatus causing pneumomediastinum, pneumothorax, and cervical subcutaneous emphysema.<sup>[8,11]</sup> In those cases without overt perforation, it is postulated that trauma to the duodenal wall by the endoscope causes the insufflated air under pressure to enter the mucosa and track along the perineural and perivascular sheaths to enter the mediastinum.<sup>[12]</sup> However, pneumomediastinum with associated orbital emphysema without any cervicofacial trauma is extremely rare. Aydin et al reported the case of a 63-year-old woman who developed bilateral periorbital emphysema associated with diffuse mediastinal and subcutaneous emphysema following ERCP.<sup>[11]</sup> The findings were confirmed using imaging, and she recovered following nasogastric decompression and antibiotic therapy.

We report a case of right-sided periorbital emphysema with cervicofacial and mediastinal emphysema following routine upper gastrointestinal endoscopy, which has not been reported so far. In our patient with chronic liver disease and volume overload status, lid swelling and facial puffiness could have been mistaken as passive edema due to the systemic comorbidities; however, the characteristic crepitus felt on palpation was pathognomonic of emphysema. It also ruled out any allergic causes and angioedema. Negative history of trauma or straining and lack of inflammation on ocular examination excluded local causes of orbital emphysema. A CT scan of the orbit and thorax would have been informative but was precluded by her sudden death. High index of suspicion and prompt and aggressive management is required to prevent vision threatening as well as life threatening sequelae in such scenarios. Ocular management includes close observation for pressure effect on the orbit manifested by increasing proptosis, intraocular pressure, or worsening of vision.<sup>[1]</sup> If any of these symptoms develop, emergency orbital decompression should be performed by lateral canthotomy/cantholysis, needle aspiration, or bony decompression depending on the severity. Similarly, those with pneumomediastinum should be evaluated for any aero-digestive tract injury and monitored for potential airway obstruction, air embolism, cardiovascular, or infectious processes.<sup>[5]</sup>

Identification of emphysema should prompt the search for associated injury, and ophthalmologists should be aware that periorbital emphysema can develop due to remote causes without direct or indirect periorbital trauma. Fatal outcome in our patient emphasizes the need for prompt recognition with urgent intervention to prevent disastrous consequences.

## Declaration of patient consent

The authors certify that they have obtained all appropriate patient consent forms. In the form the patient(s) has/have given his/her/their consent for his/her/their images and other clinical information to be reported in the journal. The patients understand that their names and initials will not be published and due efforts will be made to conceal their identity, but anonymity cannot be guaranteed.

## Financial Support and Sponsorship

Nil.

## Conflicts of Interest

There are no conflicts of interest

## REFERENCES

1. Zimmer-Galler IE, Bartley GB. Orbital emphysema: Case reports and review of the literature. *Mayo Clin Proc* 1994;69:115-121.
2. Hunts JH, Patrinely JR, Holds JB, Anderson RL. Orbital emphysema. Staging and acute management. *Ophthalmology* 1994;101:960-966.
3. Abdelrahman H, Shunni A, El-Menyar A, Ajaj A, Afifi I, Zarour A, et al. Mediastinal emphysema following fracture of the orbital floor. *J Surg Case Rep* 2014:rju032.
4. Saleem A, Chaudhary A, Ali MU, Iqbal ZH. Cervicofacial emphysema. *J Coll Physicians Surg Pak* 2010;20:556-557.
5. Mather AJ, Stoykewych AA, Curran JB. Cervicofacial and mediastinal emphysema complicating a dental procedure. *J Can Dent Assoc* 2006;72:565-568.
6. Ong WC, Lim TC, Lim J, Sundar G. Cervicofacial, retropharyngeal and mediastinal emphysema: A complication of orbital fracture. *Asian J Surg* 2005;28:305-308.
7. Hiraoka T, Ogami T, Okamoto F, Oshika T. Compressed air blast injury with palpebral, orbital, facial, cervical, and mediastinal emphysema through an eyelid laceration: A case report and review of literature. *BMC Ophthalmol* 2013;13:68.
8. Schiavon LL, Rodrigues RA, Nakao FS, Sena VOD, Ferrari AP, Jr EDL. Subcutaneous Emphysema, Pneumothorax and Pneumomediastinum Following Endoscopic Sphincterotomy. *Gastroenterol Res* 2010;3:216-218.
9. Yen HH, Chen YY. Pneumomediastinum, pneumoperitoneum, pneumoretroperitoneum, and subcutaneous emphysema after ultrathin endoscopy. *Endoscopy* 2011;43:E49-E50.
10. Minocha A, Richards RJ. Pneumomediastinum as a complication of upper gastrointestinal endoscopy. *J Emerg Med* 1991;9:325-329.
11. Aydin M, Kisli E, Ozgoren E, Soylemez O, Baser M, Aslaner A. Mediastinal and retro-orbital emphysema following an uncomplicated endoscopic sphincterotomy. *Indian J Surg* 2005;67:147-149.
12. Jaiswal SK, Sreevastava DK, Datta R, Lamba NS. Unusual occurrence of massive subcutaneous emphysema during ERCP under general anaesthesia. *Indian J Anaesth* 2013;57:615-617.