

Large cell acanthoma: a debate throughout the decades

Aikaterini Patsatsi¹, Elizabeth Lazaridou², Christina Fotiadou², Aikaterini Kyriakou¹,
Dimitrios Sotiriadis¹

¹ Second Department of Dermatology, Aristotle University School of Medicine, Thessaloniki, Greece

² First Department of Dermatology, Aristotle University School of Medicine, Thessaloniki, Greece

Keywords: acanthoma, large cell acanthoma, solar lentigo

Citation: Patsatsi A, Lazaridou E, Fotiadou C, Kyriakou A, Sotiriadis D. Large cell acanthoma: a debate throughout the decades. *Dermatol Pract Concept*. 2014;4(1):5. <http://dx.doi.org/10.5826/dpc.0401a05>

Received: August 31, 2013; **Accepted:** October 23, 2013; **Published:** January 31, 2014

Copyright: ©2014 Patsatsi et al. This is an open-access article distributed under the terms of the Creative Commons Attribution License, which permits unrestricted use, distribution, and reproduction in any medium, provided the original author and source are credited.

Funding: None.

Competing interests: The authors have no conflicts of interest to disclose.

All authors have contributed significantly to this publication.

Corresponding author: Aikaterini Patsatsi, M.D., Plagiari PO Box 461, 57500 Thessaloniki, Greece. Tel. +302313323291; Fax. +302310991473. Email: katerinapatsatsi@gmail.com

Have we really concluded what a large cell acanthoma is? Is it a distinct entity, a solar lentigo, a subtype of seborrheic keratosis, or an HPV-induced acanthoma?

In 1970, large cell acanthoma (LCA) was first described by Pinkus, as a sharply demarcated, hyperkeratotic patch, often on sun-exposed skin, characterized by extraordinarily large cells with polyploidy [1]. LCA presents sharply demarcated hyperorthokeratosis, hypergranulosis, and enlarged keratinocytes without signs of atypical mitoses or nuclear dysplasia. Pinkus separated actinic keratosis from LCA by its tendency towards invasion, and postulated that LCA may be a variant of lentigo senilis or that lentigo senilis may evolve into an LCA [1]. The prevalence of this, by that time, newly described entity seemed to be low, according to a retrospective histopathologic analysis held at the Department of Dermatology, University of Cologne, in which 4 cases of LCA out of 4268 cases of actinic and seborrheic keratoses were identified [2].

Since its original description, a debate in the literature has occurred as to whether LCAs are distinctive lesions or solar lentigos with large nuclei. In 1988, Sánchez Yus et al. discussed that the nature of LCA, mostly based on the frequent

disordered arrangement of the malpighian cells, the nuclear variability and the occasional finding of dyskeratoses and suprabasal mitoses, and concluded that LCA is probably a cytologic variant of Bowen's disease [3]. In 1992, there was a long, constructive series of papers published in the April issue of the *American Journal of Dermatopathology*, analyzing the concepts for the origin of LCA.

Rabinowitz and Inghirami claimed that LCA was a distinctive keratosis, different from solar lentigo on the basis of the lack of color, absence of elongated hyperpigmented hockey-stick-shaped buds, and presence of hyperploid keratinocytes [4].

Sánchez Yus et al. concluded that LCA is a distinctive entity with various stages of development, probably related to stucco keratosis, but histologically separate from solar lentigo [5].

On the other hand, Roewert and Ackerman stated that LCA is a variant of solar lentigo and that solar lentigo (including the large cell variant) is a stage in the evolution of reticulated seborrheic keratosis and of lichen planus-like keratosis [6].

The origin of LCA still remains unclear or not well understood. During the last decade, in a small series of papers, a

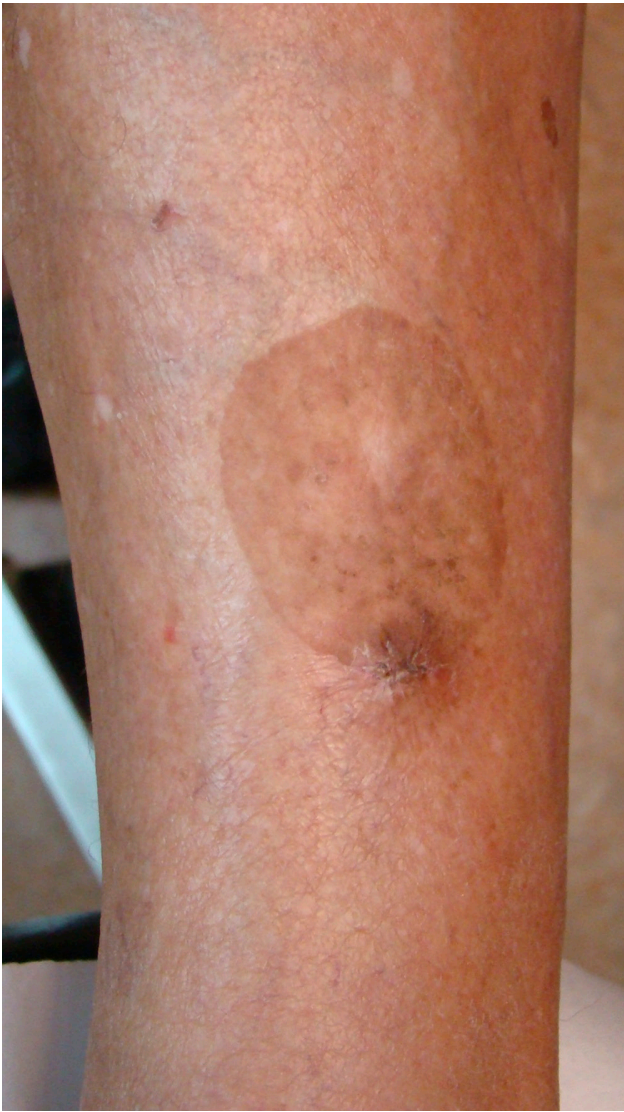

Figure 1A. A sharply demarcated patch on sun exposed skin. [Copyright: ©2014 Patsatsi et al.]

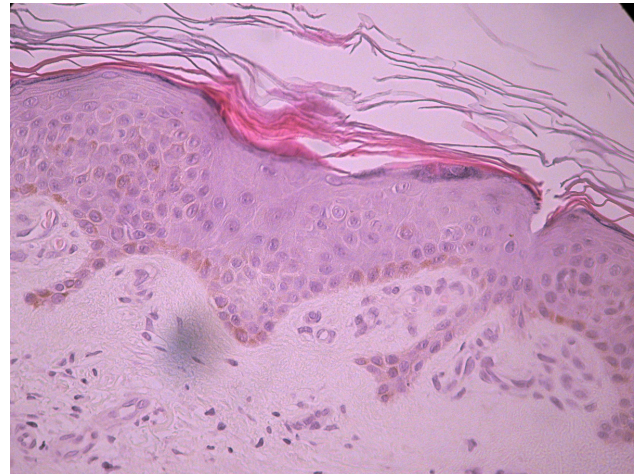

Figure 1B. Hyperorthokeratosis, enlarged keratinocytes without signs of atypical mitoses, increased number of melanocytes (H&E X40). [Copyright: ©2014 Patsatsi et al.]

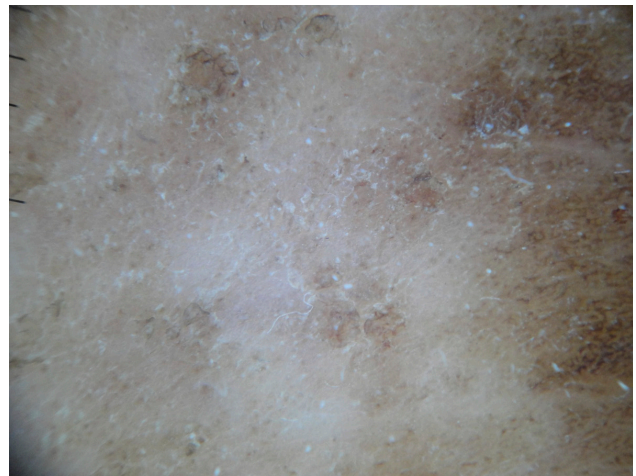


Figure 1C. A brown, "broken up" pseudonetwork, scattered gray, brown dots and foci of surface scale. [Copyright: ©2014 Patsatsi et al.]

discussion around a possible link of LCA origin with HPV infection has started. May HPV infection serve as a cofactor, possibly in conjunction with solar ultraviolet irradiation, in the generation of LCAs, based on the detection of HPV DNA in lesional skin? [7-9]

If the reader scrutinizes the clinical and histological features of the HPV-induced LCAs, many questions arise on whether the described lesions are LCAs or plane warts, as well opposed by the correspondence paper of Lora et al. in 2009. The authors suggest that in ambiguous cases, immunohistochemistry and/or in-situ hybridization (along with PCR) must be performed so as to precisely localize HPV-infected cells within the lesion, thus avoiding misdiagnosis of plane warts as LCA [10].

Moreover, most of the HPV-associated LCAs are multiple and non-pigmented. As noted in most papers, LCAs are hyperpigmented macules or plaques on sun-damaged skin. Whether the hyperpigmentation is a stable finding of a true

LCA is still in question. In most cases, clinically, LCA may be difficult to be differentiated from a solar lentigo, a pigmented actinic keratosis, or a flat and pigmented seborrheic keratosis.

In 2003, Mehregan et al., having studied 19 cases of LCA, defined as histological characteristics of LCA the presence of epidermal keratinocytes with nuclei roughly twice the size of adjacent epidermal or adnexal keratinocytes and with minimal nuclear pleomorphism. The authors concluded that on the basis of clinical, histologic, and immunohistochemical staining similarities, LCA should be considered as a reaction pattern, possibly related to solar lentigo [11]. In the same study, solar lentigo and large cell acanthoma showed statistically significant increased numbers of melanocytes compared with both normal skin and actinic keratosis. The number of melanocytes did not differ significantly between LCA and solar lentigo.

In the era of dermoscopy, dermoscopic features of a large series of LCAs have not been defined yet. Our unpublished experience supports the option that LCA is a solar lentigo.

Dermoscopy may reveal pseudofollicular openings, gray and brown dots and globules, yellow opaque homogeneous areas, surface scale and a delicate, light brown, pseudonetwork commonly seen in solar lentigos. The prominent dermoscopic features in a case of ours were a brown, “broken up” pseudonetwork, scattered gray, brown dots and foci of surface scale (Figure 1A-C).

Should we agree, instead of a conclusion, with the statement of Dr Ackerman, in one of the response letters regarding the LCA origin, in 1992, that “ *we insist that every large cell acanthoma has long had a place in the sun—and that is precisely how it came to be a solar lentigo!*” [12]

References

1. Pinkus H. Epidermal mosaic in benign and precancerous neoplasia (with special reference to large cell acanthomas). *Acta Dermatol (Kyoto)*. 1970;65(2):75-81.
2. Scholl W. Large cell acanthoma. *Z Hautkr*. 1982;57(13):1002-5.
3. Sánchez Yus E, de Diego V, Urrutia S. Large cell acanthoma. A cytologic variant of Bowen's disease? *Am J Dermatopathol*. 1988;10(3):197-208.
4. Rabinowitz AD, Inghirami G. Large-cell acanthoma. A distinctive keratosis. *Am J Dermatopathol*. 1992;14(2):136-8.
5. Sánchez Yus E, del Rio E, Requena L. Large-cell acanthoma is a distinctive condition. *Am J Dermatopathol*. 1992;14(2):140-7.
6. Roewert HJ, Ackerman AB. Large-cell acanthoma is a solar lentigo. *Am J Dermatopathol*. 1992;14(2):122-32.
7. Berger T, Stockfleth E, Meyer T, Kiesewetter F, Funk JO. Multiple disseminated large-cell acanthomas of the skin associated with human papillomavirus type 6. *J Am Acad Dermatol*. 2005;53(2):335-7.
8. Garrido-Rios AA, Sanz-Munoz C, Aragonese-Fraile MH, et al. Human papillomavirus detection in multiple large-cell acanthomas. *J Eur Acad Dermatol Venereol*. 2009;23(4):454-5.
9. Wu YF, Ko JH, Kuo T, et al. Large cell acanthoma manifesting as multiple white papules on extremities. *Dermatologica Sinica*. 2011;29:144-6.
10. Lora V, Kanitakis J. HPV detection in ‘large-cell acanthomas’: a word of caution. *J Eur Acad Dermatol Venereol*. 2009;23(12):1468-9.
11. Mehregan DR, Hamzavi F, Brown K. Large cell acanthoma. *Int J Dermatol*. 2003;42(1):36-9.
12. Ackerman AB. Response to Drs Rabinowitz and Inghirami. *Am J Dermatopathol*. 1992;14(2):139.