



## Case report

## The link between colon cancer and congenital hypertrophy of the retinal pigment epithelium (CHRPE)

Brent Deibert<sup>a,b,\*</sup>, Letisha Ferris<sup>a,b</sup>, Noel Sanchez<sup>a</sup>, Paul Weishaar<sup>a</sup><sup>a</sup> University of Kansas Medical Center – Wichita, 1010 North Kansas, Wichita, KS, USA<sup>b</sup> University of Nebraska Medical Center, 42nd and Emile, Omaha, NE, USA

## ARTICLE INFO

## Keywords:

Congenital hypertrophy of the retinal epithelium (CHRPE)  
 Gardner syndrome  
 Familial adenomatous polyposis (FAP)  
 Grouped pigmentation of the retina  
 Bear tracks  
 Colon cancer

## ABSTRACT

**Purpose:** Clarify the differences between Familial Adenomatous Polyposis (FAP)-associated Congenital Hypertrophy of the Retinal Epithelium (CHRPE) and benign variants with regards to lesion characteristics and associated risk.

**Observations:** An eighteen-year-old man with no past medical history was found to have multiple lesions in both eyes that were consistent with FAP-associated CHRPE. Although family history was negative for colon cancer, a colonoscopy was performed, and hundreds of polyps were found extending from the rectum to the distal colon with pathological findings of tubular adenoma. Genetic testing was consistent with a possible *de novo* Adenomatous Polyposis Coli (APC) mutation.

**Conclusions:** FAP is an autosomal dominant syndrome that causes colorectal cancer by age thirty-five in ninety-five percent of cases. There has been no established relationship between the benign variants of CHRPE and FAP, and patients with benign variants have no increased risk of colon cancer. While the lack of distinction in nomenclature and similar lesion appearance often leads to misdiagnosis and overtreatment, there are distinct ocular exam features that can provide the correct diagnosis. The exam findings that distinguish FAP-associated CHRPE lesions are (1) bilateralism, (2) occurrence in multiple quadrants, (3) pisiform shape, and (4) irregular borders. Knowing these features can be of great aid, especially in the setting of suspected *de novo* Familial Adenomatous Polyposis.

## 1. Introduction

The characteristics of the congenital hypertrophy of the retinal pigment epithelium (CHRPE) variant that is related to Familial Adenomatous Polyposis (FAP) differs from benign variants of CHRPE (classic CHRPE and Grouped Pigmentation of the Retina). While the lack of distinction in nomenclature and similar appearance often leads to misdiagnosis and overtreatment, there are distinct ocular exam features that can provide the correct diagnosis. Knowing these features can be of great aid, especially in the setting of suspected *de novo* FAP.

## 2. Case report

An eighteen-year-old man was seen by his optometrist for an annual eye exam. The optometrist noted several 1–2 mm pisiform (peapod-shaped) or fusiform lesions in multiple quadrants of the right eye, with additional small pigmented punctate lesions (Figs. 1 and 2). The left eye had similar findings (Figs. 3 and 4). Referral to a retinal

ophthalmologist confirmed that these lesions had a high probability of correlation with FAP. Review of systems revealed diarrhea and rectal bleeding.

Although family history was negative for colon cancer, a referral for a diagnostic colonoscopy was made. The colonoscopy revealed hundreds of polyps extending from the rectum to the distal colon. The polyps were both sessile and pedunculated, and ranged from 1 to 3 cm in size. Polyp biopsies revealed tubular adenoma that were negative for high-grade dysplasia or malignancy. Adenomatous polyposis coli (APC) gene sequencing showed a deletion of 5 nucleotides, denoted as APC 3183del5, which results in premature truncation of the APC protein at amino acid 1062 located in the middle of the gene. Analysis of the MUTYH gene was normal.

Due to the presence of polyps throughout the colon and rectum and the presence of symptoms, a complete proctocolectomy was performed and well tolerated. At six months, a pouchoscopy was performed along with an EGD. EGD revealed multiple 2–3 mm sessile gastric polyps in the gastric fundus. Biopsies of the gastric polyps showed fundic gland

\* Corresponding author. Truhlsen Eye Institute, 3902 Leavenworth St, Omaha, NE, 68105, USA.

E-mail address: [brent.deibert@unmc.edu](mailto:brent.deibert@unmc.edu) (B. Deibert).

<https://doi.org/10.1016/j.ajoc.2019.100524>

Received 24 April 2019; Received in revised form 10 July 2019; Accepted 21 July 2019

Available online 24 July 2019

2451-9936/© 2019 The Authors. Published by Elsevier Inc. This is an open access article under the CC BY-NC-ND license (<http://creativecommons.org/licenses/by-nc-nd/4.0/>).

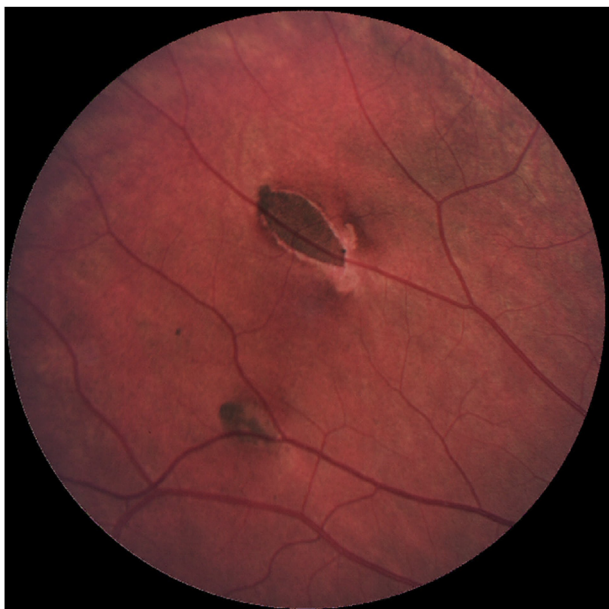

Fig. 1. Right eye, pisiform lesions with halo and small adjunct pigmented spot.

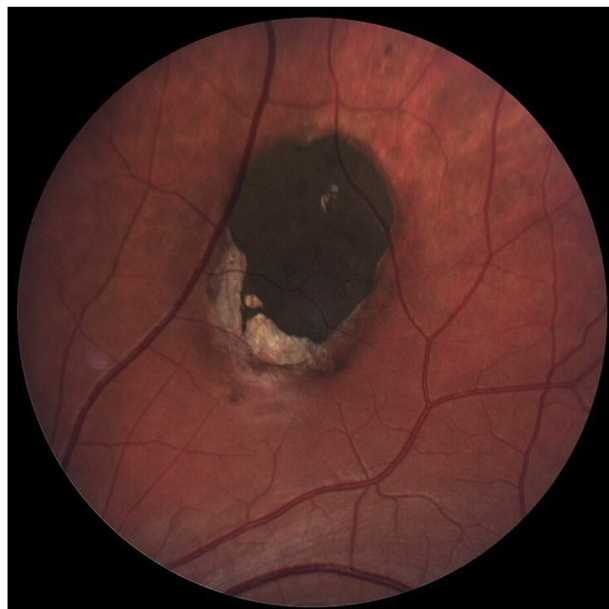


Fig. 3. Left eye, large pisiform lesion superior to optic disc.

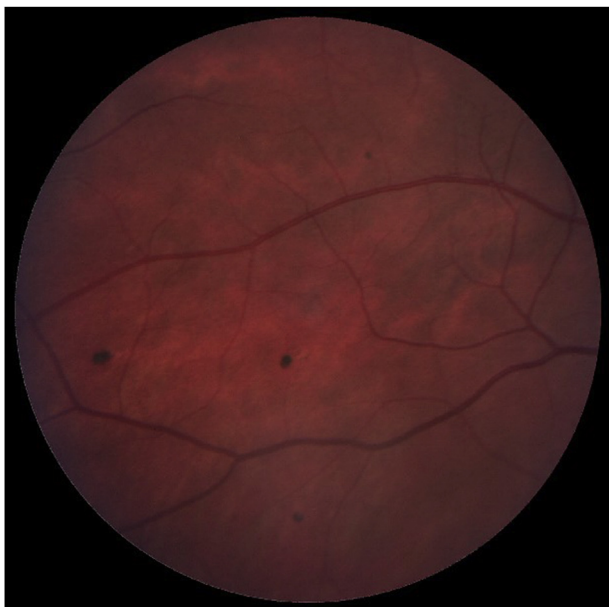

Fig. 2. Right eye, punctate pigmentations.

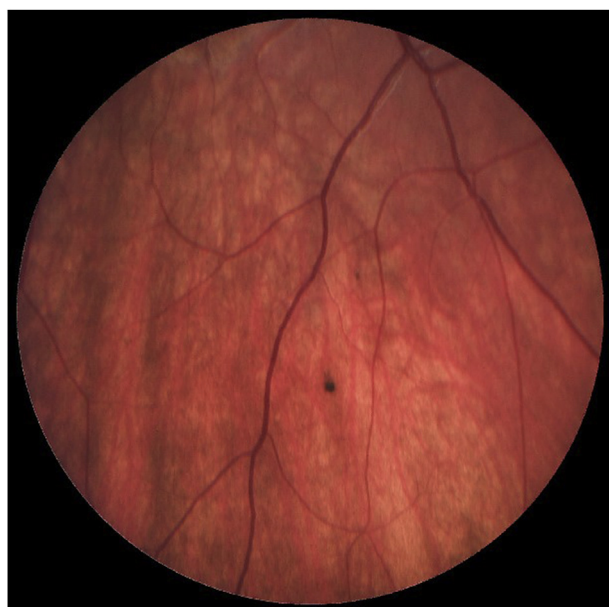

Fig. 4. Left eye, punctate pigmentations.

polyps.

### 3. Discussion

FAP is an autosomal dominant syndrome that causes numerous colonic polyps that result in colorectal cancer by age thirty-five in ninety-five percent of cases and can be associated with multiple extracolonic features: desmoid tumors, epidermoid cysts, osteomas, numerous dental abnormalities, skin cancers, and CHRPE.<sup>1-8</sup> No differentiation has been made in nomenclature between the benign variants of CHRPE and the FAP-associated version despite risk of severe consequences associated with overtreatment or missed diagnosis.

The retinal pigmented epithelial (RPE) cells that constitute all types of CHRPE lesions are columnar to cuboidal and taller than the unaffected surrounding RPE.<sup>1,9-12</sup> They contain many large spherical melanosomes and have no lipofuscin granules.<sup>9-12</sup> The lack of

lipofuscin is due to a dysfunction in phagocytosis and the catabolism of shed photoreceptor membranes.<sup>9,12</sup> This results in hypo-autofluorescence of the CHRPE lesions.<sup>13</sup>

Classic CHRPE is unifocal and typically located in the mid-periphery of the fundus.<sup>1,5,9-15</sup> It is a flat lesion and can be pigmented or non-pigmented, although pigmented lesions are much more common.<sup>5,9-11,13,14</sup> Pathological findings consist of retinal thinning, photoreceptor loss, and increased thickness of the retinal pigment epithelium (RPE).<sup>1,9,11-13</sup> The degeneration of photoreceptors is progressive and is linked to visual field defects.<sup>11,12</sup> Classic CHRPE lesions also exhibit diameter growth in the majority of cases, but malignant transformation to adenocarcinoma only occurs in one percent of cases and there have never been reports of metastasis.<sup>11</sup> However, blindness can develop as the lesion grows and gives way to exudative retinal detachment.<sup>11</sup>

Grouped Pigmentation of the Retina is another CHRPE variant made

up of multiple lesions, giving it the appearance of animal tracks and the nickname “bear tracks”. It usually lacks halos, occupies one quadrant, and is comprised of smaller lesions than classic CHRPE and FAP-associated CHRPE.<sup>5,9</sup>

There has been no established relationship between classic CHRPE or Grouped Pigmentation of the Retina and FAP.<sup>10</sup> Patients with classic CHRPE or Grouped Pigmentation of the Retina are not at a greater risk than the general population for developing colon cancer and the presence of these lesions does not warrant screening for FAP by colonoscopy or genetic testing.<sup>5</sup>

FAP-associated CHRPE lesions are histologically like classical CHRPE lesions. However, they can be distinguished based on ocular exam. The exam findings that distinguish FAP-associated CHRPE lesions are (1) bilateralism, (2) occurrence in multiple quadrants, (3) pisiform shape, and (4) irregular borders.<sup>1,5,9,14</sup> If any of these are present on exam it is reasonable to refer for complete gastroenterological work up.

The mutated gene responsible for FAP is the tumor suppressor gene APC.<sup>3,7,8</sup> The inheritance pattern of FAP is autosomal dominant and there is both a classic and attenuated form of this syndrome thought to be related to the location of the deletion in APC, though distinguishing the two forms is ultimately a clinical diagnosis.<sup>3,6,8,15,16</sup> The degree of penetrance is unclear for the attenuated form but is nearly one hundred percent for the classic form.<sup>3,4,17</sup> Classic FAP presents with hundreds to thousands of colonic polyps around the second decade of life, while attenuated FAP presents later in life with an average of thirty colonic polyps.<sup>18</sup> Genetic testing involves analysis of the APC gene and the MUTYH gene to distinguish between FAP and MUTYH-associated polyposis. Identification of the mutation within the APC gene allows for familial testing, which is significant because there is a fifty percent chance the offspring of an affected individual will inherit the pathogenic variant.<sup>18</sup>

FAP-associated mutations are present in 1 in 6850 to 1 in 31,250 live births displaying consistent incidence worldwide equal between men and women.<sup>3,7,15</sup> It is estimated by the latest CDC statistics (2015) that 140,788 new cases of colorectal cancer are diagnosed each year.<sup>16</sup> It is thought that FAP accounts for 0.5–2% of all colorectal cancer.<sup>6,15,18</sup> The incidence of *de novo* mutations accounts for 11–33% of FAP.<sup>3,6,7</sup>

Genetic screening for adenomatous polyposis syndromes is recommended when colonoscopy reveals greater than ten polyps whether or not there is a positive family history, as a *de novo* mutation could be present.<sup>3</sup> Surveillance colonoscopy or sigmoidoscopy is indicated every 1–2 years for patients with genetically-confirmed classic FAP beginning at age 10–12, or at the onset of puberty if this occurs earlier, and a colonoscopy is indicated every 1 year once polyps present.<sup>3,5,18</sup> Surveillance initiation can be delayed to late teens and performed every 2–3 years in attenuated FAP, with frequency increasing to every 1–2 years once polyps appear.<sup>18</sup> Due to the high risk of adenoma to adenocarcinoma transformation, early prophylactic colectomy after polyps begin to appear is advised in classic FAP.<sup>2,3,6</sup> Recommendation for colectomy in attenuated FAP is less clear and based on polyp burden and polyp characteristics. If polyps are small (less than 6.0 mm), non-villous, and lack high grade dysplasia, colectomy may be delayed until after age 20 in both classic and attenuated FAP.<sup>18</sup> Surveillance of the remnants of a subtotal colectomy should be performed every 6–12 months, but only every 2 years if a total colectomy was performed.<sup>3,19,22</sup> Other screening recommendations for classic FAP include EGD for gastric polyps and duodenal adenomas starting at age 20–30 every 6 months–4 years depending on burden of findings and referenced guidelines.<sup>5,8,19,23</sup> Annual physical exam should be performed on all patients with either classic or attenuated FAP and include neurological testing to screen for CNS neoplasms and thyroid palpation to screen for nodules, with possible addition of thyroid ultrasound regardless of physical exam findings.<sup>19–21</sup> Screening for desmoid tumors and hepatoblastoma should also be considered in those with classic FAP.<sup>18</sup>

#### 4. Conclusions

It is important to assess lesion characteristics to differentiate between FAP-associated CHRPE and benign forms of CHRPE. The exam findings that distinguish FAP-associated CHRPE lesions are (1) bilateralism, (2) occurrence in multiple quadrants, (3) pisiform shape, and (4) irregular borders.<sup>1,5,9,14</sup> FAP-associated CHRPE is rare and referral for colonoscopy should only be made when there is high suspicion based on lesion characteristics to prevent morbidity from unnecessary colonoscopies.

Identification of patients with FAP-associated CHRPE from *de novo* APC mutations is especially important, as there is a high probability of invasive adenocarcinoma at a young age prior to the initiation of average-risk screening colonoscopies. Thus, an ability to differentiate between the various forms of CHRPE is imperative to providing appropriate care.

#### Patient consent

Written consent to publish this case has not been obtained. This report does not contain any personal identifying information.

#### Funding

No funding or grant support.

#### Conflicts of interest

The following authors have no financial disclosures: BD, LF, NS, PW.

#### Authorship

All authors attest that they meet the current ICMJE criteria for Authorship.

#### Acknowledgements

None.

#### References

- Shields JA, Shields CL, Shah PG, Pastore DJ, Imperiale Jr SM. Lack of association among typical congenital hypertrophy of the retinal pigment epithelium, adenomatous polyposis, and Gardner syndrome. *Ophthalmology*. 1992;99(11):1709–1713.
- Blair NP, Trempe CL. Hypertrophy of the retinal pigment epithelium associated with Gardner's syndrome. *Am J Ophthalmol*. 1980;90(5):661–667.
- Syngal S, Brand RE, Church JM, Giardiello FM, Hampel HL, Burt RW. ACG clinical guideline: genetic testing and management of hereditary gastrointestinal cancer syndromes. *Am J Gastroenterol*. 2015;110(2):223–263.
- Traboulsi EI, Murphy SF, de la Cruz ZC, Maumenee IH, Green WR. A clinicopathologic study of the eyes in familial adenomatous polyposis with extracolonic manifestations (Gardner's syndrome). *Am J Ophthalmol*. 1990;110(5):550–561.
- Ponti G, Tomasi A, Manfredini M, Pellacani G. Oral mucosal stigmata in hereditary-cancer syndromes: from germline mutations to distinctive clinical phenotypes and tailored therapies. *Gene*. 2016;582(1):23–32.
- Sandoval JA, Fernandez-Pineda I, Malkan AD. Risk-reduction surgery in pediatric congenital oncology: a perspective. *J Pediatr Surg*. 2016;51(4):675–687 (4):675–687.
- Aretz S, Uhlhaas S, Caspari R, et al. Frequency and parental origin of *de novo* APC mutations in familial adenomatous polyposis. *Eur J Hum Genet*. 2003;12(1):52–58.
- Brosens LA, Wood LD, Offerhaus GJ, et al. Pathology and genetics of syndromic gastric polyps. *Int J Surg Pathol*. 2015;24(3):185–199.
- Shields CL, Materin MA, Walker C, Marr BP, Shields JA. Photoreceptor loss overlying congenital hypertrophy of the retinal pigment epithelium by optical coherence tomography. *Ophthalmology*. 2006;113(4):661–665.
- Shields CL, Mashayekhi A, Ho T, Cater J, Shields JA. Solitary congenital hypertrophy of the retinal pigment epithelium: clinical features and frequency of enlargement in 330 patients. *Ophthalmology*. 2003;110(10):1968–1976.
- Shields JA, Eagle Jr RC, Shields CL, Brown GC, Lally SE. Malignant transformation of congenital hypertrophy of the retinal pigment epithelium. *Ophthalmology*. 2009;116(11):2213–2216.
- Shields CL, Manalac J, Das C, Saktanasate J, Shields JA. Review of spectral domain-enhanced depth imaging optical coherence tomography of tumors of the retina and retinal pigment epithelium in children and adults. *Indian J Ophthalmol*.

- 2015;63(2):128–132.
13. Shields CL, Pirondini C, Bianciotto C, Harmon SA, Shields JA. Autofluorescence of congenital hypertrophy of the retinal pigment epithelium. *Retina*. 2007;27(8):1097–1100.
  14. Arepalli S, Kaliki S, Shields JA, Shields CL. Growth of congenital hypertrophy of the retinal pigment epithelium over 22 years. *J Pediatr Ophthalmol Strabismus*. 2012;49:e73–75 Online.
  15. Ghorbanoghli Z, Nieuwenhuis MH, Houwing-Duistermaat JJ, et al. Colorectal cancer risk variants at 8q23.3 and 11q23.1 are associated with disease phenotype in APC mutation carriers. *Fam Cancer*. 2016.
  16. U.S. Cancer Statistics Working Group. *U.S. Cancer Statistics Data Visualizations Tool, Based on November 2017 Submission Data (1999-2015)*. U.S. Department of Health and Human Services, Centers for Disease Control and Prevention and National Cancer Institute; June 2018 [www.cdc.gov/cancer/dataviz](http://www.cdc.gov/cancer/dataviz).
  17. Neklason DW, Stevens J, Boucher KM, et al. American founder mutation for attenuated familial adenomatous polyposis. *Clin Gastroenterol Hepatol*. 2008;6(1):46–52. <https://doi.org/10.1016/j.cgh.2007.09.017>.
  18. Jasperson KW, Patel SG, Ahnen DJ. APC-associated polyposis conditions. [Updated 2017 Feb 2]. In: Adam MP, Ardinger HH, Pagon RA, eds. *GeneReviews [Internet]*. Seattle (WA): University of Washington, Seattle; 1993-2019, Available from <https://www.ncbi.nlm.nih.gov/books/NBK1345/>.
  19. NCCN guidelines version 1.2019 genetic/familial high-risk assessment: colorectal. [https://www.nccn.org/professionals/physician\\_gls/pdf/genetics\\_colon.pdf](https://www.nccn.org/professionals/physician_gls/pdf/genetics_colon.pdf); 2019.
  20. Jarrar A, Milas M, Mitchell J, et al. *Screening for Thyroid Cancer in Patients with Familial Adenomatous Polyposis*. *Annals of Surgery*. Wolters Kluwer Health, Inc; Mar 1, 2001.
  21. Herraiz M, Barbesino G, Faquin W, et al. Prevalence of thyroid cancer in familial adenomatous polyposis syndrome and the role of screening ultrasound examinations. *Clin Gastroenterol Hepatol*. March 2007;5(3):367–373.
  22. Church J, Burke C, McGannon E, Pastean O, Clark B. Risk of rectal cancer in patients after colectomy and ileorectal anastomosis for familial adenomatous polyposis: a function of available surgical options. *Dis Colon Rectum*. 2003 Sep;46(9):1175–1181.
  23. Syngal S, Brand RE, Church JM, et al. ACG clinical guideline: genetic testing and management of hereditary gastrointestinal cancer syndromes. *Am J Gastroenterol*. 2015 Feb;110(2):223–262. <https://doi.org/10.1038/ajg.2014.435>. Epub 2015 Feb 3 quiz 263.