

Endovascular Treatment for Thoracoabdominal Aortic Aneurysm and Complex Abdominal Aortic Aneurysm Using Fenestrated and Branched Grafts

Department of Radiology, Okinawa Prefectural Chubu Hospital, Okinawa, Japan

Wataru Higashiura

Abstract

Fenestrated and branched endovascular aneurysm repair (F/B-EVAR) is a less invasive treatment for thoracoabdominal aortic aneurysm (TAAA) and complex abdominal aortic aneurysm. Fenestrated and branched (cuff) grafts facilitate safe and durable repair, and bail-out maneuvers for target vessel cannulation and stenting have been established; however, the available bridging stent grafts have differences. The present article discusses the optimal selection of fenestrated or branched grafts, the cannulation of target vessels that have difficult anatomies, and the advantages and disadvantages of various bridging stents. We review the causes and risk factors of spinal cord injury (SCI), the protocol for prevention of SCI, and the outcomes of target vessel stent grafting, including patency and endoleak.

Although conventional open surgery is the gold standard for the repair of thoracoabdominal aortic aneurysm (TAAA), it is highly invasive. To reduce invasiveness, hybrid surgery that combines open surgery and endovascular therapy has been developed [1, 2], and fenestrated and branched endovascular aneurysm repair (F/B-EVAR) is frequently performed at centers in the USA, Europe, and Japan [3-5]. Additionally, a hostile neck may be an independent factor for sac enlargement after EVAR for abdominal aortic aneurysm (AAA) [6], but a previous study reported that 41% of AAA cases presented with neck lengths outside the range prescribed by the traditional instruction for use [7]. Stark et al. showed that extending the graft above the highest renal artery would create an augmented neck length in 90% of patients with AAA [7]. F/B-EVAR is based on this principle. However, there are some technical tips for, and limitations of, fenestrated and/or branched graft. F/B-EVAR for TAAA and complex AAA will be reviewed in the present article.

Key words: thoracoabdominal aortic aneurysm, complex abdominal aortic aneurysm, endovascular aneurysm repair, fenestrated and branched endovascular repair, stent graft

(Interventional Radiology 2020; 5: 103-113)

Types of Stent Grafts

Several companies have developed stent grafts for the treatment of TAAA. The present article reviews the fenestrated and branched stent grafts manufactured by Zenith (Cook Medical, Bloomington, IN, USA); they are commonly used globally.

There are two methods for the reestablishment of renal

and visceral arteries in the case of TAAA: fenestrated and branched endograft.

The fenestrations have a diameter of 6-12 mm with no strut crossing them for TAAA, and they are marked by radiopaque markers for accurate alignment.

For complex AAA, the fenestrations had a diameter of 6-8 mm, and they were located at ≥ 15 mm distal to the top of the graft fabric. Large fenestrations showed greater diameters (8-12 mm) with a strut crossing them. Large fenest-

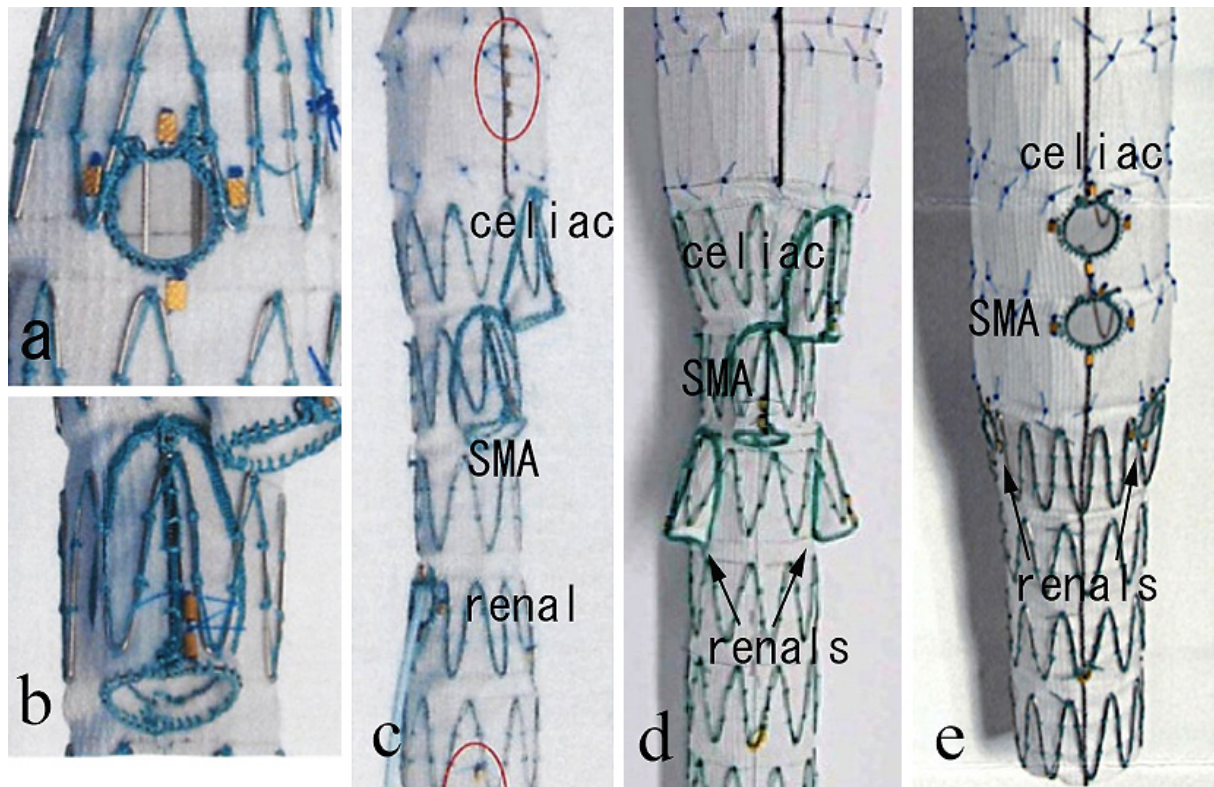


Fig. 1. Fenestrated and Branched stent grafts

(a) A fenestration with no strut crossing it, and it is marked by radiopaque markers for accurate alignment. (b) A branch based on a pre-sewn cuff. (c) Endograft with directional cuffs for the celiac axis and SMA, and fenestrations for the renal artery. (d) Endograft with directional cuffs for the celiac axis, SMA, and renal arteries. (e) Endograft with fenestrations for all visceral and renal arteries.

trations were located at ≥ 10 mm distal to the top of the graft fabric. Scallop fenestrations, which allow the incorporation of at least 1 vessel, may be carved out of the proximal end of the graft fabric with a width of 10 mm and height of 6-12 mm. Lining the fenestrations with nitinol rings strengthens the seal between them and the bridging stent grafts (**Fig. 1a**). The renal or visceral artery is bridged through the fenestration by a balloon-expandable stent graft that is flared by a large-diameter balloon.

Branch stent grafts employ a cuff to connect renal and visceral arteries, and they are available as both balloon-expandable and self-expanding stent grafts. Branches are based on pre-sewn cuffs, and they can be straight, helical, upgoing, downgoing, external, or internal (**Fig. 1b**). Compared with fenestrated stent grafts, branched grafts have the following advantages: the simplified estimation of the characteristics of the visceral or renal artery and the reduced incidence of type III endoleaks.

Planning for F/B-EVAR

The preoperative routine multiphase CT scan protocol includes image acquisition in the plain and the arterial (bolus tracking) and delayed phases following the injection of iodinated contrast. CTA with thin-slice (1 mm) cuts from the aortic arch to the common femoral artery is recommended.

Tortuosity, stenosis, small vessel diameter, and early branch bifurcation increase the technical difficulty of stenting into the target visceral artery. Fenestrated and branched devices are custom designed on a 3D workstation with reference to the CT multiplanar reconstruction (MPR) images and the centerline of flow (CLF) images [5, 8]. The design of a fenestrated device is chosen to maximize the proximal sealing zone, accommodate native aortic angulation, and provide durable fixation. The distances between the ostia of the branch arteries that are to be incorporated into grafts are measured using the CLF imaging technique. The clock positions of the branch ostia are determined based on the MPR images. The suprarenal aorta is currently preferred as the proximal landing zone in the case of a juxtarenal AAA to the suprarenal aorta because it provides sufficient long-term durability [9].

A minimum sealing zone of at least 25 mm should be selected in normal suprarenal or thoracic aortic segments [10]. A normal aortic segment is defined as a parallel aortic wall without thrombus or calcium that has a change in diameter of $< 10\%$.

There are several anatomic exclusion criteria: (a) inadequate femoral or iliac access compatible with the required delivery systems (18F-22F); (b) inability to perform a temporary or permanent open surgical or endovascular iliac conduit for patients with inadequate femoral/iliac access; (c) ab-

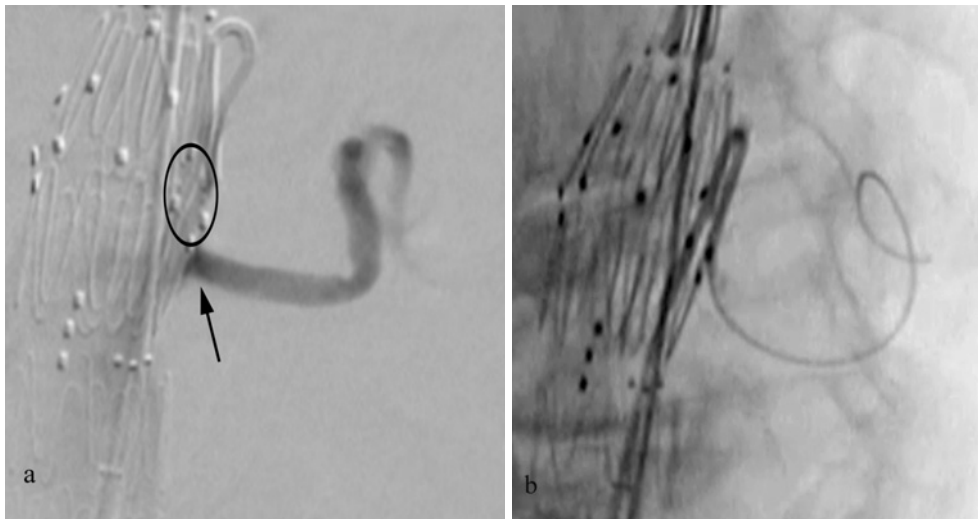


Fig. 2. Bail-out technique; malalignment between the fenestration and the target artery
(a) Malalignment between the fenestration (circle) and the left renal artery (arrow). (b) VS reversed shaped catheter can be used for cannulation.

sence of a non-aneurysmal aortic segment in the distal thoracic aorta; (d) visceral vessel anatomy with an excessive occlusive disease or small size not amenable to a stent graft; (e) unsuitable distal iliac artery fixation site and anatomy [10].

Design selection: fenestrated or branched?

There is less room for error in the design or deployment of fenestrated grafts because of the proximity of the fenestration to the aortic wall. A comparatively greater margin of error is allowable for the directional cuff of branched grafts. In general, the cannulation of the target vessel with the directional cuff is easily achieved.

Despite these advantages, a branched stent graft with a directional cuff requires a minimum diameter of the aortic flow lumen of 25 mm to open [11]. The small aortic diameters of the visceral or renal segments may favor the choice of the fenestrated over directional branch grafts. From the perspective of the patency of the target artery during follow-up and in the case of the renal artery, fenestrated grafts are preferable to directional branch grafts [12-14], although, for the celiac axis and SMA, directional cuff patency is acceptable [10, 15]. In patients with Crawford type II and III TAAA [10, 16, 17], directional branch grafts are generally preferred for the celiac axis and SMA, and fenestrated grafts are preferred for the renal artery (**Fig. 1c**). Directional renal branch grafts are used to prevent type III endoleaks when the aortic lumina are large (> 40 mm) and the renal artery orientation is down-going (**Fig. 1d**) [10, 15]. In contrast, fenestrated grafts are preferred for all visceral and renal arteries in patients with Crawford type IV and juxta-renal AAA (**Fig. 1e**) [10, 18]. Recent technological developments may help to overcome inner-branch anatomical limitations [19].

Tips for Cannulation of Target Vessels

Fenestrated grafts

In general, target vessel cannulation is performed through a fenestration from the contralateral common femoral artery. After the fenestrated device is unsheathed, a selective catheter is used to gain access to the fenestrated stent graft, the fenestration, and the target artery. Target vessel cannulation is performed from the lowest to the highest targeted artery to enable the clearance of the aortic space at the target vessel off other catheters.

After the target artery is catheterized, the soft guidewire (Radifocus 0.035 inch; Terumo, Tokyo, Japan) is removed, and a small amount of contrast medium is injected to confirm the diameter for a Rosen guidewire (COOK Medical) or Amplatz stiff guidewire (COOK Medical). After the stiff guidewire is inserted, a 6 or 7F guiding sheath is advanced; straight, Ansel 1 curved, and Ansel 2 curved guiding sheaths are most commonly used. In general, it is easier to cannulate the renal artery from the ipsilateral femoral access using a curved guiding sheath. However, renal artery cannulation from the contralateral femoral access is most easily achieved using a straight guiding sheath.

Although the target vessel can be accessed without difficulty in most cases, bail-out techniques are necessary in the event of errors of design or deployment and cases of complicated vessel morphology. Aortic angulation around visceral and renal arteries can lead to malalignments between the fenestration and the target artery, in which case a reverse-shaped catheter (e.g., VS; COOK Medical) can be used (**Fig. 2**) [20]. Target vessel calcification/stenosis and downgoing orientation of the renal artery may also increase the difficulty of cannulation. In a target artery with ostium calcification or stenosis, the sheath and dilator often cannot

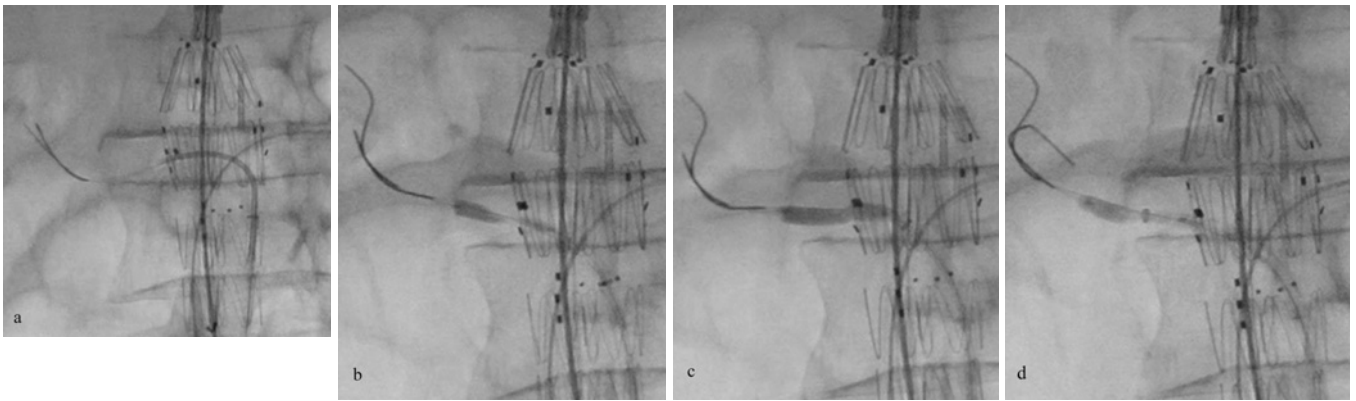


Fig. 3. Bail-out technique; balloon anchor technique for a target artery with ostium calcification or stenosis

(a) Two 0.018-inch guidewires are inserted into the right renal artery through the fenestration. (b) A 0.035-inch undersized balloon catheter is advanced over double 0.018-inch guidewires and used as an alternative to the sheath dilator. After balloon inflation at the orifice and fenestration (c), the sheath is advanced over the balloon as it is slowly deflated (d).

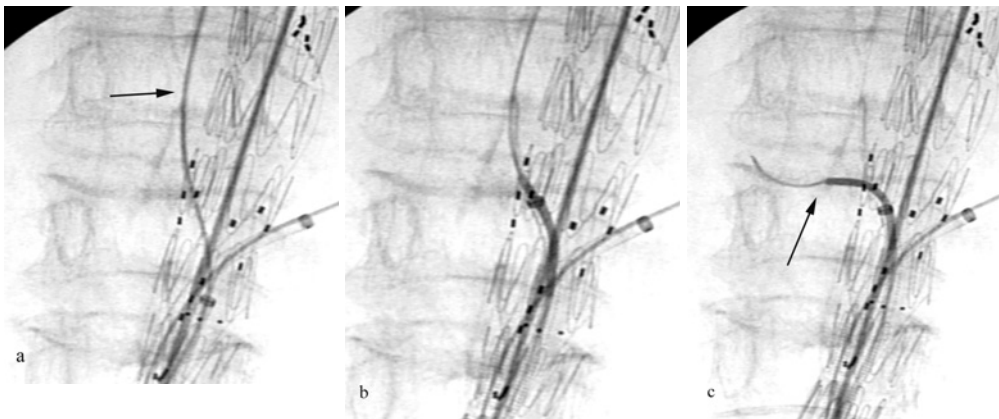


Fig. 4. Bail-out technique; the buddy catheter technique for a downgoing renal artery

(a) A 0.035-inch guidewire (arrow) is advanced between the aortic wall and the stent graft into the target vessel. (b) A guiding sheath is repositioned at the fenestration. (c) After interchanging the 0.035- and 0.014-inch guidewires, the renal artery is then located using a buddy catheter (arrow). The 0.014-inch guidewire helps to keep the guiding sheath close to the fenestration.

be advanced into the target vessel, and an undersized balloon catheter is used as an alternative to the sheath dilator [21]. After balloon inflation at the orifice and the fenestration, the sheath is advanced over the balloon as the balloon is slowly deflated (balloon anchor technique). If there is a difficulty in inserting a 0.035-inch stiff guidewire, a microballoon (0.018 inches, guidewire compatible) is used over a stiff 0.018-inch guidewire (SV, Cordis, Miami Lakes, FL, USA; or V-18, Boston Scientific, Natick, MA, USA). A 0.035-inch balloon catheter is advanced over two stiff 0.018-inch guidewires (Fig. 3). Cannulation through the fenestration into a downgoing artery from the femoral artery is one of the most difficult procedures. The catheter and Radifocus guidewire can be bounced off the top cap to facilitate the advancement of the catheter into the target artery [21]; however, this procedure is not applicable in patients with Crawford type II or III TAAA. An alternative maneuver for a

downgoing renal artery is the buddy catheter technique, in which the guidewire is advanced between the aortic wall and the stent graft into the target vessel rather than directly through the fenestration (Fig. 4). To prevent losing access to the fenestration, a 0.014-inch guidewire is advanced between the aortic wall and the stent graft, and the guidewire and guiding sheath are repositioned at the fenestration. The 0.014-inch guidewire helps to keep the guiding sheath close to the fenestration. The renal artery is then located using a buddy catheter (e.g., Van Schie 3 with a 90° angle; COOK Medical) [21]. Another bail-out maneuver is the molding balloon technique [22].

It is extremely difficult to cannulate a target artery that has stenoses at the orifice and in the downgoing direction (e.g., celiac artery with compression from the median arcuate ligament) through a standard fenestration from the femoral artery [23]. For such a target vessel, fenestration with a

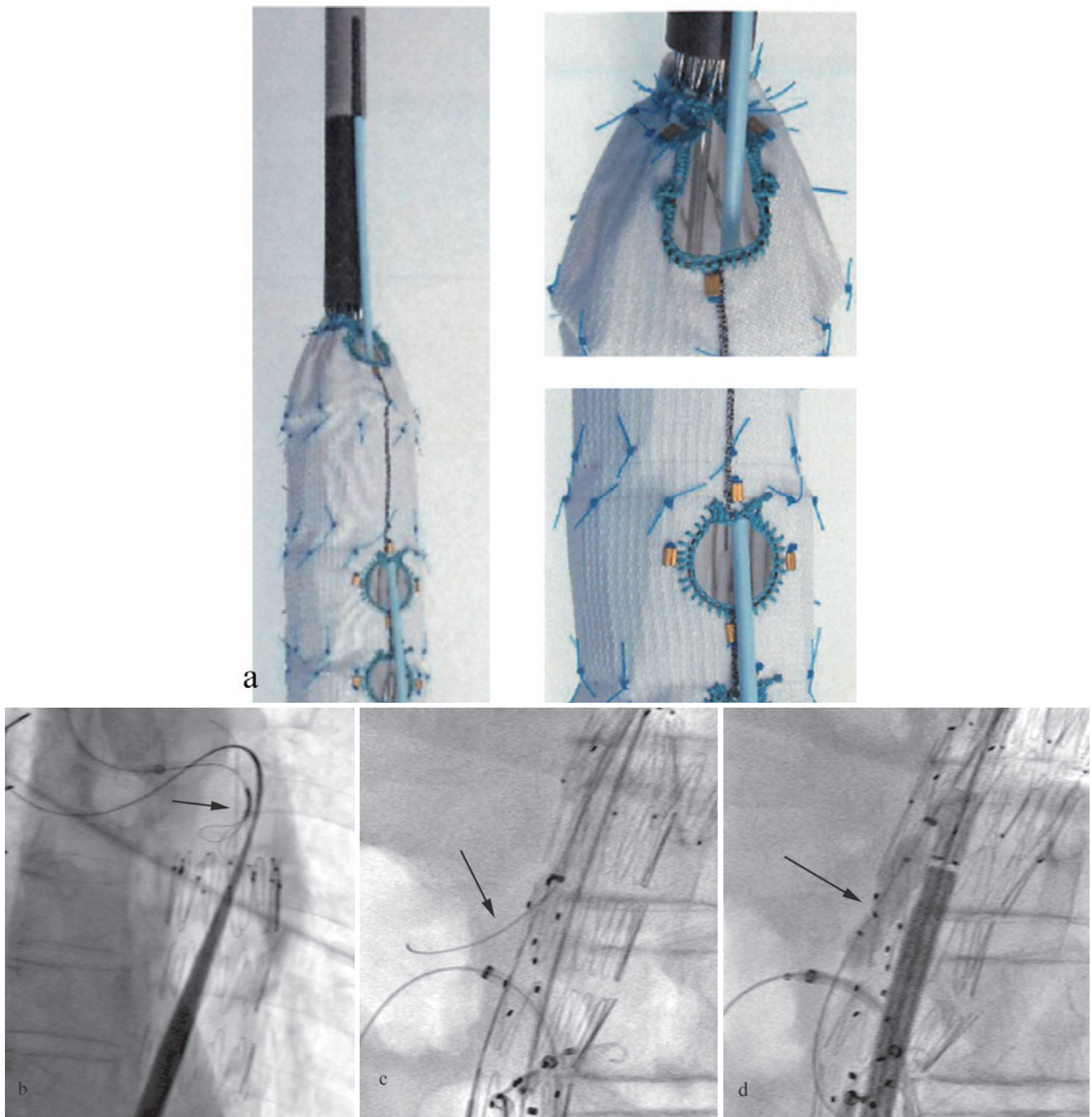


Fig. 5. Endograft with fenestration with a preloaded system

(a) Endograft with a fenestration with a preloaded system for the celiac axis. (b) The guidewire is advanced into a preloaded catheter and snared using a snare catheter (arrow) via the brachial approach. (c) The guiding sheath is advanced over the pull-through wire via the brachial approach into the fenestration. The catheter and guidewire (arrow) are easily cannulated into the target artery. (d) The bridging stent (arrow) is deployed via the brachial approach.

preloaded guidewire via the brachial artery is preferable (Fig. 5) [24, 25].

Target vessel stenting should begin with the highest fenestration to prevent damage to the other stents during ballooning and flaring [20]. A balloon-expandable stent graft is used for bridging in fenestrated EVAR [20]. The bridging stent graft should be deployed 5 mm into the aorta and flared using a 10 mm × 2 cm or 12 mm × 2 cm balloon.

The flaring balloon should be tilted upward to achieve circumferential flaring [20].

Branched graft (directional cuff)

Standard access with a directional cuff is from the axillary or brachial artery. A 12F sheath is advanced into the descending aorta via a small incision and positioned inside the main body of the branch. From this point, a 0.014-inch

guidewire is advanced via a pull-through from the left axillary to the femoral artery. This maneuver helps to stabilize the 12F sheath in the aorta. To guide the deployment of the branched stent graft, a renal artery or the SMA is precannulated via the common femoral approach. Each directional cuff is individually catheterized through the 12F sheath sequentially, beginning at the lowest branch with the pull-through wire maintained in position [11]. The bridging stent graft should be placed within the cuff and extended 2-5 mm into the aortic lumen of the branched stent graft. The bridging stent graft placed into the highest target vessel can disturb the cannulation of the lower target vessel, and this is why starting from the lowest target vessel is preferable. A 4 F or 5F catheter and a Radifocus guidewire are advanced into the directional cuff and target artery, and the Radifocus guidewire is exchanged with a Rosen guidewire. If the aortic arch is tortuous, an Amplatz stiff guidewire is preferable to a Rosen guidewire. Guidewire placement into the correct cuff is confirmed on oblique fluoroscopy views. Following the guidewire placement, a 7F guiding sheath is advanced over the wire into the target vessel.

If a self-expanding stent graft is used as the bridging stent graft, it should be oversized by 1-2 mm, and it must provide a distal landing zone of at least 20 mm in the target artery and extend 5 mm into the aortic lumen.

Bridging Stent Grafts for Fenestrated and Branched Grafts

For a fenestrated graft, a balloon-expandable stent graft is used for bridging the fenestrations to the renal or visceral artery. For a branched stent graft, a balloon-expandable or self-expanding stent graft can be used; since the introduction of F/B-EVAR, we have used Advanta V12 balloon-expandable stent grafts (Maquet, Wayne, NJ, USA) and Fluency plus self-expanding covered stents (Bard peripheral vascular, Medicon Inc. Osaka, Japan). Gore Viabahn self-expanding stent grafts (WL Gore, Flagstaff, AZ, USA) and VBX balloon-expandable stent grafts (WL Gore, Flagstaff, AZ, USA) have recently become available in Japan for the treatment of peripheral arterial disease, but not for use in F/B-EVAR. The following are currently distributed in Japan.

Maquet Atrium Advanta V12 (iCAST)

The Advanta V12 is the most frequently used balloon-expandable stent graft for F/B-EVAR; more experience and data have been accumulated globally for this stent graft than for any other. It is constructed from 316L stainless steel with two layers of polytetrafluoroethylene (PTFE) with a porosity of 100-120 μm [26]. The stent graft is mounted on a 0.035-inch-compatible non-compliant balloon catheter, and it should be delivered through a 6F or 7F guiding sheath. The advantages of this stent graft are its precise deployment, excellent radial force, and resistance to fracturing; however, it has less flexibility compared with other bridging stents, which may result in arterial kinking at its distal edge in the

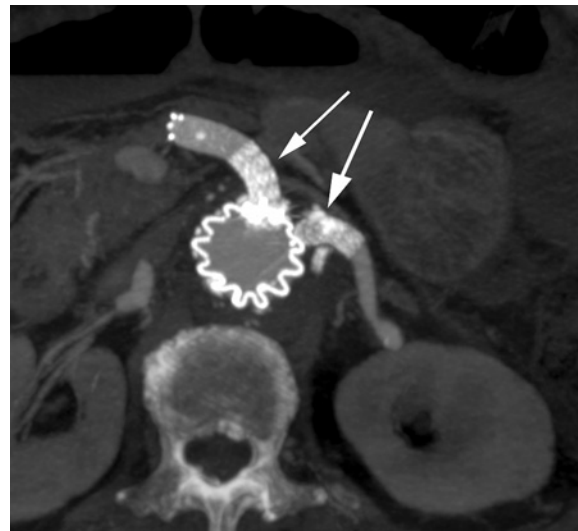

Fig. 6. Gore VBX balloon-expandable stent graft used as a bridging stent graft

Gore VBX balloon-expandable stent grafts (arrow) are placed into the SMA and the left renal artery to overcome the tortuous anatomy.

case of an extremely tortuous renal artery [26]. For this reason, a self-expanding bare metal stent is placed for reinforcement. To prevent arterial dissection when an Advanta V 12 bridging stent graft is used for the SMA, a self-expanding bare metal stent should be placed to cover the distal edge of the graft.

Gore Viabahn VBX balloon-expandable stent graft

The VBX stent graft is designed as a bridging stent for the Gore thoracoabdominal branched endoprosthesis [26, 27]. The endoprosthesis is composed of 316L surgical grade stainless steel and a PTFE graft with a heparin-coated surface. The VBX has no longitudinal stent struts, and it is, therefore, more flexible than other balloon-expandable stent grafts (**Fig. 6**) [26, 28]. Its design advantages include an attractive size matrix, superior deliverability, and safe overdilatation [29, 30].

According to a study, stenosis or occlusion occurred in 5 of 95 F/B-EVAR procedures that used VBX during fenestrated, branched, and parallel grafting and had a mean follow-up of 3.6 months (renal, n = 3; SMA, n = 1; Celiac, n=1) [31]. Another study reported a 100% patency rate for the VBX bridging stent at a median follow-up of 223 days (range, 2-462 days) [32]. However, a study described a case of near occlusion of a VBX celiac branch due to kinking at the interspace between the stent rings from a lateralizing force, which occurred because of its design [33]. Further evaluation of its use in F/B-EVAR should be performed with long-term follow-up.

Fluency Plus self-expanding covered stent

Fluency Plus is a self-expanding covered stent comprising a nitinol stent and a PTFE graft. As it is Pharmaceuticals

and Medical Devices Agency (PMDA)-approved for the treatment of biliary stenosis, Fluency Plus is available with diameters of 8 and 10 mm, lengths of 40, 60, and 80 mm, and a working length of 80 mm in Japan. Its durability as a bridging stent graft in F/B-EVAR has been proven, especially for the celiac artery and SMA [15, 16]. However, for the renal artery, it has relatively low patency when used in directional branch grafting due to its rigidity [15]. A downward-facing directional branch coupled with a Fluency stent graft may not work well in vessels that are < 6 mm and > 270 degrees in curvature [34]. To prevent kinks in the transition between the Fluency Plus and the target vessel, the Fluency Plus is reinforced by a self-expanding bare stent [15]. The blunt profile of its tip can make it difficult to pass the graft into the branch [28].

Gore Viabahn self-expanding stent graft

The Gore Viabahn self-expanding stent graft is made of PTFE, with a heparin-coated surface, attached to an external nitinol stent structure. It is available for use with 0.018- and 0.035-inch guidewire systems. Its main advantage over other stent grafts is its flexibility; therefore, it is ideal for use in tortuous and long vessels [26]. The disadvantages of this stent graft are its low radial force and visibility [28]. The release mechanism can complicate positioning and result in misplacement, especially in an angled situation [28]. A useful technique is to position the sheath in the middle of the Viabahn stent graft. The stent graft is then slowly deployed to the middle position and the sheath is retracted to complete its release [11].

Outcomes of F/B-EVAR

The in-hospital or 30-day mortality after F/B-EVAR is 0%-9% [10, 15, 17], and the incidence of type I or III endoleak during the procedure is 2.8% [17]. Spinal cord ischemia (SCI) is the most critical complication, and it is associated with elevated morbidity and mortality [35, 36]. Moreover, a previous study indicated that 37% of SCI cases occurred after 30 days of follow-up, emphasizing the importance of consequent postoperative surveillance [35].

Because a long section of the aorta is covered in F/B-EVAR for TAAA, multiple intercostal and lumbar artery occlusions can occur. Therefore, SCI is more common after F/B-EVAR than after simple endovascular repair for TAA or AAA, and recent studies have reported its incidence as 2%-31% [10, 36-40]. The most likely causes of SCI after F/B-EVAR are insufficient development of collateral flow to the spinal cord and micro-embolization. The risk of SCI is higher for F/B-EVAR for TAAA than F/B-EVAR for complex AAA [35], and previous studies have reported a significant increase in the incidence of SCI with increased percentage and length of aortic coverage [38, 41, 42]. Some studies have reported that collaterals to segmental arteries from the subclavian, external iliac, and internal iliac arteries are critical [43, 44]. Therefore, several high-volume centers recom-

mend that the subclavian and internal iliac arteries should be preserved or reestablished to prevent SCI [36, 45]. Other studies have revealed the importance of procedure time [35, 44], which can lead to the interruption of blood flow to the internal and external arteries by the large-diameter sheath if prolonged [45, 47]. In terms of device, a multibranched stent graft (such as the t-Branch) has a higher risk of SCI after endovascular repair than a fenestrated endograft [38], because it has a relatively longer aortic coverage, and it completely shuts off blood supply.

SCI prevention protocols have recently been developed [40]. A staged procedure should be considered in patients with Crawford type I and II TAAA. In their staged approach, Oderich et al. performed coverage of > 2 of the thoracic aorta sealing stents above the celiac artery in the first stage, with completion of F/B-EVAR 6 to 8 weeks later [10, 48]. The staged approach also has the potential benefit of staged thrombosis of the sac, which may influence coagulopathy and systemic inflammatory reaction after F/B-EVAR [10, 49]. The Cleveland Clinic Group reported that staged repair appeared to protect against SCI, and it also enhanced overall survival in patients with a Crawford type II repair [50]. Immediate removal of the large sheath is a crucial protocol that restores pelvic and limb perfusion [10, 45]. Temporary iliac or femoral artery conduits and reperfusion of the lower limb using a sheath should be considered to enable lower extremity flow in patients with compromised anatomies. Blood pressure control is also important, both during the procedure and afterward [45]. The target mean arterial pressure (MAP) is ≥ 80 -85 mmHg intraoperatively and for the first 72 hours after F/B-EVAR [11, 45]. A target hemoglobin level of ≥ 10 g/dl should be maintained during the first 48 hours by transfusion if necessary [11, 45]. Cerebrospinal fluid (CSF) drainage is a well-known and effective method for reducing the incidence and improving the symptoms of SCI by decreasing intrathecal pressure. However, there is a lack of consensus on the routine prophylactic use of CSF drainage because of the risks of hematoma, infection, and catheter retention. High-volume centers advocate routine prophylactic CSF drainage for all patients and a baseline spinal pressure of 10 mmHg. CSF pressure is lowered to 0-5 mmHg if there is a change in neuromonitoring or physical assessment. Oderich et al. recommended that CSF drainage should be continued for 24 hours in patients with type IV TAAA and 48-72 hours in those with type I, II, and III TAAA [11]. Maurel et al. proposed that the incidence of SCI could be reduced by using an aggressive perioperative management protocol that included early pelvic and lower extremity perfusion, aggressive revascularization of the left subclavian and internal iliac arteries, staged repair together with systematic CSF drainage for type I-III TAAA, assiduous blood pressure management (MAP > 85 mmHg), and a pre-emptive strategy of blood, plasma, and platelet transfusion [45].

Micro-embolization of the Adamkiewicz artery and/or the collateral network is a recognized cause of SCI after de-

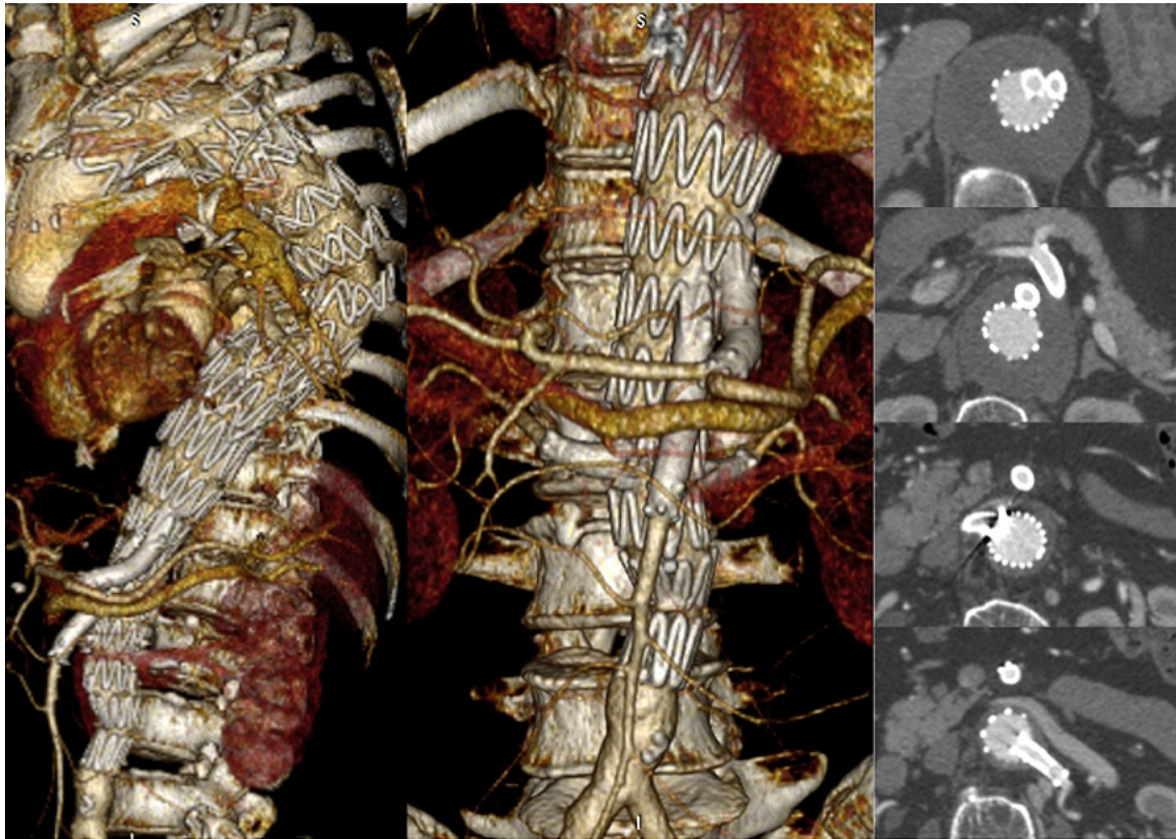


Fig. 7. Computed Tomography after F/B-EVAR
CT shows no endoleak or branch occlusion after F/B-EVAR for TAAA.

scending TAA and TAAA. In a magnetic resonance imaging study, Tanaka et al. demonstrated that embolism was a major cause of SCI [51]. Moreover, Rossi et al. showed a significant correlation between cutaneous micro-embolization and the development of SCI [47]. Endovascular manipulation can lead to micro-embolization from aortic atheroma with concomitant infarction of the spinal cord. Careful manipulation during the endovascular procedure and careful patient selection is mandatory.

Another important issue is target vessel stenting and the outcomes, including patency and endoleak. Target vessel stenting has a high rate of technical success (99%) (Fig. 7). However, intraoperative complications occur most commonly during target vessel cannulation and stenting [52]. Cannulation/stenting failure and prolonged procedures during the cannulation of the target vessel are associated with mortality and morbidity [52]. Therefore, it is important that the target vessel cannulation and stenting are performed safely and quickly. A previous study reported that the following anatomical factors were associated with the difficulty of cannulation into the renal artery in standard fenestrated repair: caudal direction, significant stenosis, and severe calcification of the renal artery [53]. This is consistent with our observations. The celiac artery is frequently compressed and stenosed by the median arcuate ligament. Cannulation into the celiac artery in the presence of median arcuate ligament syndrome (MALS) may be a complex procedure (33% in 45

patients with MALS vs. 14% in 113 patients without MALS; $p < 0.001$) [23]. However, if a bridging stent graft is successfully implanted in a celiac artery with MALS, mid-term patency is acceptable (stent kinking, 16%; thrombosis, 0%; endoleak, 0%) [23].

A study from a high-volume center reported patency rates of 93%, 95%, and 96% in the renal artery, SMA, and celiac artery at 3 years [17], respectively. Another study reported no occlusion after F/B-EVAR in 94% of renal arteries at 5 years [54], which is comparable to that after conventional open repair of TAAA [55]. A study that included 856 renal arteries recommended fenestrated rather than branched endografts (directional cuffs) for renal arteries due to the lower occlusion rate of fenestrated grafts (2.3% vs 9.6%) [12]. Similar results were reported in another study in which the patency at 3 years was 98% for targeted vessels with fenestrated grafts and 92% for those with branched grafts ($p = 0.009$) [56].

Endoleak after F/B-EVAR is more complex than that after simple TEVAR or EVAR because of the multiple stent graft connections. Oderich et al. proposed additional endoleak classifications associated with F/B-EVAR bridging stents: type Ic (endoleak originating from sealing site of a bridging stent graft or fenestration leakage), type IIIc (side branch component endoleak), and type IIIId (tear, perforation or fracture in the stent-graft or branches) [57]. In a study conducted by the Mayo Clinic that involved 382 patients treated

with F/B-EVAR, 52 target vessel endoleaks were identified in 1204 targeted renal-mesenteric arteries. Of these 52, 41 were type IIIc, 10 were type Ic, and 1 was type IIIb; compared with fenestration endoleaks, more branch endoleaks resolved spontaneously. In addition, 11 secondary endoleaks associated with the target vessel developed, all of which required intervention [58].

Finally, another issue associated with F/B-EVAR is that the design of the stent graft can be customized specifically for the patient; off-the-shelf stent grafts are not suitable for all patients. Custom-designed stent grafts take 6-8 weeks to construct and deliver; however, 1.7% of patients die due to aneurysm rupture during the waiting time. Aneurysm diameter is greater in patients who die from aneurysm rupture (79.2 mm vs. 66.7 mm) [59]. The development of an off-the-shelf device that could be adapted to most patients would be advantageous, and it could lead to PMDA approval for F/B-EVAR in Japan.

Conclusions

The outcomes of F/B-EVAR for TAAA and complex AAA have been improved by optimal graft design, innovative fenestration/branch technology, and the establishment of bail-out techniques during target vessel cannulation. However, the prevention of SCI remains challenging. An off-the-shelf device that is customizable for several patients should be developed, and this may lead to PMDA approval for F/B-EVAR in Japan.

Conflict of interest: The author declares that no conflict of interest exists.

Disclaimer: Wataru Higashiura is one of the Editorial Board members of *Interventional Radiology*. This author was not involved in the peer-review or decision-making process for this paper.

References

- Shuto T, Wada T, Miyamoto S, Kamei N, Hongo N, Mori H. Ten-year experience of the thoraco-abdominal aortic aneurysm treatment using a hybrid thoracic endovascular aortic repair. *Interact Cardiovasc Thorac Surg* 2018; 26: 951-956.
- Kuratani T, Kato M, Shirakawa Y, Shimamura K, Sawa Y. Long-term results of hybrid endovascular repair for thoraco-abdominal aortic aneurysms. *Eur J Cardiothorac Surg* 2010; 38: 299-304.
- Kanaoka Y, Ohki T. Midterm results of endovascular treatment for the patients with thoracoabdominal aortic aneurysms. *Ann Vasc Dis* 2019; 12: 163-170.
- Kato M, Motoki M, Isaji T, Suzuki T, Kawai Y, Ohkubo N. Spinal cord injury after endovascular treatment for thoracoabdominal aneurysm or dissection. *Eur J Cardiothorac Surg* 2015; 48: 571-577.
- Higashiura W, Nagata T, Tabayashi N, Itoh H, Sakaguchi S, Taniguchi S, et al. Initial experience of branched endovascular graft for abdominal aortic aneurysm with complex anatomy of proximal neck: planning and technical considerations. *Jpn J Radiol* 2010; 28: 66-74.
- Iwakoshi S, Ichihashi S, Higashiura W, Itoh H, Sakaguchi S, Tabayashi N, et al. A decade of outcomes and predictors of sac enlargement after endovascular abdominal aortic aneurysm repair using Zenith endografts in a Japanese population. *J Vasc Interv Radiol*. 2014; 25: 694-701.
- Stark M, Suresh A, Alexander J, Cragg A. An analysis of variables affecting aortic neck length with implications for fenestrated endovascular repair of abdominal aortic aneurysm. *Ann Vasc Surg* 2014; 28: 808-815.
- Banno H, Kobeiter H, Brossier J, Marzelle J, Presles E, Becquemain JP. Inter-observer variability in sizing fenestrated and/or branched aortic stent-graft. *Eur J Vasc Endovasc Surg*. 2024; 47: 45-52.
- O'Callaghan A, Greenberg RK, Eagleton MJ, Bena J, Mastracci TM. Type Ia endoleaks after fenestrated and branched endografts may lead to component instability and increased aortic mortality. *J Vasc Surg* 2015; 61: 908-914.
- Oderich GS, Ribeiro M, Hofer J, Wigham J, Cha S, Chini J, et al. Prospective, nonrandomized study to evaluate endovascular repair of pararenal and thoracoabdominal aortic aneurysms using fenestrated-branched endografts based on supraceliac sealing zones. *J Vasc Surg* 2017; 65: 1249-1259.
- Oderich GS, Mendes B. Endovascular repair of TAAAs with the t-Branch multibranch stent graft. *Endovascular Today* 2015; 11 (suppl): 11-18.
- Martin-Gonzalez T, Mastracci T, Carrel T, Constantinou J, Dias N, Katsargyris A, et al. Mid-term outcomes of renal branches versus renal fenestrations for thoraco-abdominal aneurysm repair. *Eur J Vasc Endovasc Surg* 2016; 52: 141-148.
- Mastracci TM, Carrell T, Costantinou J, Disa N, Martin-Gonzalez T, Katsargyris A, et al. Editor's choice - Effect of branch stent choice on branch-related outcomes in complex aortic repair. *Eur J Vasc Endovasc Surg* 2016; 51: 536-542.
- Katsargyris A, Marques de Marino P, Verhoeven EL. Graft design and selection of fenestrations vs. branches for renal and mesenteric incorporation in endovascular treatment of pararenal and thoracoabdominal aortic aneurysms. *J Cardiovasc Surg (Torino)* 2019; 60: 35-40.
- Reilly LM, Rapp JH, Grenon SM, Hiramoto JS, Sobel J, Chuter TAM. Efficacy and durability of endovascular thoracoabdominal aortic aneurysm repair using the caudally directed cuff technique. *J Vasc Surg* 2012; 56: 53-64.
- Greenberg R, Eagleton M, Mastracci T. Branched endografts for thoracoabdominal aneurysms. *J Thorac Cardiovasc Surg* 2010; 140: S171-178.
- Eagleton MJ, Follansbee M, Wolski K, Mastracci T, Kuramochi Y. Fenestrated and branched endovascular aneurysm repair outcomes for type II and III thoracoabdominal aortic aneurysms. *J Vasc Surg* 2016; 63: 930-942.
- Mastracci TM, Eagleton MJ, Kuramochi Y, Bathurst S, Wolski K. Twelve-year results of fenestrated endografts for juxtarenal and group IV thoracoabdominal aneurysms. *J Vasc Surg* 2015; 61: 355-364.
- Katsargyris A, Marques de Marino P, Mufty H, Pedro LM, Fernandes R, Verhoeven EL. Early experience with the use of inner branches in endovascular repair of complex abdominal and thoraco-abdominal aortic aneurysms. *Eur J Vasc Endovasc Surg* 2018; 55: 640-646.
- Verhoeven ELG, Katsargyris A, Fernandes R, Bracale UM, Houthoofd S, Maleux G. Practical points of attention beyond instruction for use with the Zenith fenestrated stent graft. *J Vasc Surg* 2014; 60: 246-252.
- Oderich GS, Mendes BC, Kanamori KS. Technique of impalant-

- tion and bail-out maneuvers for endovascular fenestrated repair of juxtarenal aortic aneurysms. *Perspect Vasc Surg Endovasc Ther* 2013; 25: 28-37
22. Bicknell C, Riga C, Mireskandari M, Haulon S, Hamady M, Jenkins M. Use of a molding balloon to facilitate introduction of guiding catheters in fenestrated stent-graft procedure. *J Endovasc Ther* 2008; 15: 514-517
 23. Watez H, Martin-Gonzalez T, Lopez B, Spear R, Clough RE, Hertault A, et al. Results of celiac trunk stenting during fenestrated or branched aortic endografting. *J Vasc Surg* 2016; 64: 1595-1601
 24. Unno N, Yamamoto N, Higashiura W, Inuzuka K, Sano M, Konno H. Utility of a preloaded fenestrated graft in thoracoabdominal aneurysm repair. *Asian Cardiovasc Thorac Ann* 2016; 24: 699-702
 25. Chini J, Mendes BC, Tenorio ER, Ribeiro MS, Sandri GA, Cha S, et al. Preloaded catheters and guide-wire systems to facilitate catheterization during fenestrated and branched endovascular aortic repair. *Cardiovasc Intervent Radiol*. 2019; 42: 1678-1686
 26. Mendes BC, Oderich GS. Selection of optimal bridging stents for fenestrations and branches. In: Oderich GS editor. *Endovascular aortic repair*. Springer; 2017: 359-374.
 27. Oderich GS, Farber MA, Silveira PG, Tadros R, Marin M, Fillingger M, et al. Technical aspects and 30-day outcomes of the prospective early feasibility study of the GORE EXCLUDER thoracoabdominal branched endoprosthesis (TAMBE) to treat pararenal and extent IV thoracoabdominal aortic aneurysms. *J Vasc Surg* 2019; 70: 358-368
 28. Lindström D, Mani K, Lundberg G, Wanhainen A. Bridging stent grafts in fenestrated and branched endovascular aortic repair: current practice and possible complications. *J Cardiovasc Surg (Torino)* 2019; 60: 476-484
 29. Torsello GF, Herten M, Muller M, Frank A, Torsello GB, Austermann M. In vitro evaluation of the Gore viabahn balloon-expandable stent-graft for fenestrated endovascular aortic repair. *J Endovasc Ther* 2019; 26: 361-368
 30. Torsello GF, Herten M, Muller M, Frank A, Torsello GB, Austermann M. Comparison of the biomechanical properties of the Advanta V12/iCast and Viabahn stent-grafts as bridging devices in fenestrated endografts: an in vitro study. *J Endovasc Ther* 2020; 27: 258-265
 31. Rao A, Beckerman W, Radros RO, McKinsey J. Use of a novel flexible covered stent (GORE VIABAHN VBX) in fenestrated and parallel grafts during endovascular treatment of complex perivisceral aortic aneurysms: acute results. *Abstract J Vasc Surg* 2018; 67: e175-176
 32. Mafeld S, Annamalai G, Lindsay TF, Zhong I, Tarulli E, Mironov O, et al. Initial experience with Viabahn VBX as the bridging stent graft for branched and fenestrated endovascular aneurysm repair. *Vasc Endovascular Surg* 2019; 53: 395-400
 33. Yi JA, Kuwayama DP. Fenestrated aortic endograft branching with Gore VBX poses failure risk from delayed-onset branch kinking. *J Vasc Surg and Innovative Techniques* 2019; 5: 18-21
 34. Mastracci TM, Greenberg RK, Eagleton MJ, Hernandez AV. Durability of branches in branched and fenestrated endografts. *J Vasc Surg* 2013; 57: 926-933
 35. Heidenmann F, Kölbl T, Kuchenbecker J, Kreutzburg T, Debus ES, Larena-Avellaneda A, et al. Incidence, predictors, and outcomes of spinal cord ischemia in elective complex endovascular aortic repair: an analysis of health insurance claims. *J Vasc Surg*. In press
 36. Eagleton MJ, Sha S, Petkosevek D, Mastracci TM, Greenberg RK. Hypogastric and subclavian artery patency affects onset and recovery of spinal cord ischemia associated with aortic endografting. *J Vasc Surg* 2014; 59: 89-95
 37. Sobel JD, Vartanian SM, Gasper WJ, Hiramoto JS, Chuter TA, Reilly LM. Lower extremity weakness after endovascular aneurysm repair with multibranched thoracoabdominal stent grafts. *J Vasc Surg* 2015; 61: 623-628
 38. Baba T, Ohki T, Kanaoka Y, Maeda K, Ohta H, Fukushima S, et al. Clinical outcomes of spinal cord ischemia after fenestrated and branched endovascular stent grafting during total endovascular aortic repair for thoracoabdominal aortic aneurysms. *Ann Vasc Surg* 2017; 44: 146-157
 39. Dias NV, Sonesson B, Kristmundsson T, Holm H, Resch T. Short-term outcome of spinal cord ischemia after endovascular repair of thoracoabdominal aortic aneurysms. *Eur J Vasc Endovasc Surg* 2015; 49: 403-409
 40. Dijkstra ML, Vainas T, Zeebregts CJ, Hooft L, vander Laan MJ. Spinal cord ischemia in endovascular thoracic and thoracoabdominal aortic repair: review of preventive strategies. *Eur J Vasc Endovasc Surg* 2018; 55: 829-841
 41. Spanos K, Kolbel T, Kubitz JC, Wipper S, Konstantiou N, Heidemann F, et al. Risk of spinal cord ischemia after fenestrated or branched endovascular repair of complex aortic aneurysms. *J Vasc Surg* 2019; 69: 357-366
 42. Drinkwater SL, Goebells A, Haydar A, Bourke P, Brown L, Hamady M, et al. The incidence of spinal cord ischemia following thoracic and thoracoabdominal aortic endovascular intervention. *Eur J Vasc Endovasc Surg* 2010; 40: 729-735
 43. Shijo T, Kuratani T, Shimamura K, Kin K, Masada K, Goto T, et al. Extrathoracic collaterals to critical segmental arteries after endovascular thoraco-abdominal aneurysm repair. *Interact Cardiovasc Thorac Surg*. doi: 10.1093/icvts/ivaa024
 44. Tanaka R, Yoshioka K, Kamada T, Abiko A. Intentional preservation of collateral circulation to the artery of adamkiewicz using axillo-axillary bypass, concomitant with thoracic endovascular aneurysm repair. *Eur J Cardiothorac Surg* 2014; 45: 391
 45. Maurel B, Delclaux N, Sobocinski J, Hertault A, Martin-Gonzalez T, Moussa M, et al. The incidence of early pelvic and lower limb reperfusion and attentive peri-operative management on the incidence of spinal cord ischemia during thoracoabdominal aortic aneurysm endovascular repair. *Eur J Vasc Endovasc Surg* 2015; 49: 248-254
 46. Katsargyris A, Okinomu K, Kouvelos G, Renner H, Ritter W, Verhoeven ELG. Spinal cord ischemia after endovascular repair of thoracoabdominal aortic aneurysms with fenestrated and branched stent grafts. *J Vasc Surg* 2015; 62: 1450-1456
 47. Rossi SH, Patel A, Saha P, Gwozdz A, Salter R, Gkoutzios P, et al. Neuroprotective strategies can prevent permanent paraplegia in the majority of patients who develop spinal cord ischemia after endovascular repair of thoracoabdominal aortic aneurysms. *Eur J Vasc Endovasc Surg* 2015; 50: 599-607
 48. Banga PV, Oderich GS, Reis de Souza L, Hofer J, Cazares Gonzalez ML, Pulido JN, et al. Neuromonitoring, cerebrospinal fluid drainage, and selective use of iliofemoral conduits to minimize risk of spinal cord injury during complex endovascular aortic repair. *J Endovasc Ther* 2016; 23: 139-149
 49. Chang CK, Chuter TA, Niemann CU, Shlipak MG, Cohen MJ, Reilly LM, et al. Systemic inflammation, coagulopathy, and acute renal insufficiency following endovascular thoracoabdominal aortic aneurysm repair. *J Vasc Surg* 2009; 49: 1140-1146
 50. O'Callaghan A, Mastracci TM, Eagleton MJ. Staged endovascular repair of thoracoabdominal aortic aneurysms limits incidence and severity of spinal cord ischemia. *J Vasc Surg* 2015; 61: 347-354
 51. Tanaka H, Minatoya K, Matsuda H, Sasaki H, Iba Y, Oda T, et al.

- Embolism is emerging as a major cause of spinal cord injury after descending and thoracoabdominal aortic repair with a contemporary approach: magnetic resonance findings of spinal cord injury. *Interact Cardiovasc Thorac Surg* 2014; 19: 205-210
52. Cohennec F, Kobeiter H, Gohel MS, Majewski M, Marzelle J, Desgranges P, et al. Impact of intraoperative adverse events during branched and fenestrated aortic stent grafting on postoperative outcome. *J Vasc Surg* 2014; 60: 571-578
53. Ullery BW, Chandra V, Dalman RL, Lee JT. Impact of renal artery angulation on procedure efficiency during fenestrated and snorkel/chimney endovascular aneurysm repair. *J Endovasc Ther* 2015; 22: 594-602
54. Martin-Gonzalez T, Pincon C, Maurel B, Hertault A, Sobocinski J, Spear R, et al. Renal outcomes following fenestrated and branched endografting *Eur J Vasc Endovasc Surg* 2015; 50: 420-430
55. Youssef M, Neufang A, Jungmann F, Vahl CF, Dorweiler B. Patency of renal and viscerals after open thoracoabdominal aortic replacement. *J Vasc Surg* 2015; 62: 594-599
56. Katsargyris A, Marques de Marino P, Verhoeven EL. Graft design and selection of fenestrations vs. branches for renal and mesenteric incorporation in endovascular treatment of pararenal and thoracoabdominal aortic aneurysms. *J Cardiovasc Surg* 2019; 60: 35-40
57. Vrtiska T, Macedo TA, Oderich GS. Computed tomography/computed tomography angiography for evaluation, planning, and surveillance of complex endovascular repair. In: Oderich GS editor. *Endovascular aortic repair*. Springer; 2017: 149-188
58. Kärkkäinen JM, Tenorio ER, Jain A, Mendes BC, Macedo TA, Pather K, et al. Outcomes of target vessel endoleaks after fenestrated-branched endovascular aortic repair. *J Vasc Surg*. doi: 10.1016/j.jvs.2019.09.055
59. Katsargyris A, Uthayakumar V, Marques de Marino P, Botos B, Verhoeven EL. Aneurysm rupture and mortality during the waiting time for a customized fenestrated/branched stent graft in complex endovascular aortic repair. *Eur J Vasc Endovasc Surg*. doi: 10.1016/j.ejvs.2020.03.003.

Interventional Radiology is an Open Access journal distributed under the Creative Commons Attribution-NonCommercial 4.0 International License. To view the details of this license, please visit (<https://creativecommons.org/licenses/by-nc/4.0/>).