

Low Dose of Octreotide Can be Helpful in the Management of Congenital Chylothorax

Shahla Afsharpaiman¹; Mohammad Saeid Rezaee Zavareh^{2,3,*}; Mohammad Torkaman³

¹Health Research Center, Baqiatallah University of Medical Sciences, Tehran, IR Iran

²Students' Research Committee, Baqiatallah University of Medical Sciences, Tehran, IR Iran

³Pediatric Department, Faculty of Medicine, Baqiyatallah University of Medical Sciences, Tehran, IR Iran

*Corresponding Author: Mohammad Saeid Rezaee Zavareh, Students' Research Committee, Baqiatallah University of Medical Sciences, Tehran, IR Iran. Tel/Fax: +98-2181264354, E-mail: dr_rezaee@live.com

Received: March 12, 2014; **Revised:** August 16, 2014; **Accepted:** April 14, 2015

Introduction: A rare condition in newborns called congenital chylothorax (CC) occurs when lymphatic fluid accumulates within the pleural cavity. Here is a presentation of a birth traumatic case with bilateral pleural effusion successfully treated by octreotide.

Case Presentation: A 3100-g-term male newborn delivered vaginally from a 33-year-old mother was admitted to the neonatal intensive care unit with respiratory distress signs. Early chest x-ray (CXR) showed bilateral pleural effusion. The thoracentesis pleural fluid had been drained with these characteristics: glucose: 1.9425 mmol/l, protein: 11 g/l, cholesterol: 1.295 mmol/l, and triglycerides: 3.39 mmol/l. Counts of red blood cells and white blood cells were 10,000 and 2500 per Cu/mm, respectively; so, congenital chylothorax was diagnosed and total parenteral nutrition (TPN) were initiated. Accumulation of plural fluid was approximately stopped after begging TPN for two weeks. Therefore, we started feeding with a medium chain triglyceride (MCT), but plural effusion was seen once again and we had to restart TPN. We decided to start octreotide subcutaneously (1 µg/kg/day). Finally, the CXR and ultrasound 'did not show any pleural effusion in both sides and the ultrasound done in the third month showed no pleural effusion either.

Conclusions: Octreotide therapy as one of the conservative managements for CC can be considered before surgical methods. This treatment method also had some effects on the feeding initiation time and helped us to start feeding sooner. However, more studies like clinical trials are still necessary to investigate all aspects of octreotide treatment to determine the amount of its dose, initiation time, treatment duration, etc.

Keywords: Congenital; Chylothorax; Octreotide; Pleural Effusion

1. Introduction

A rare condition in newborns called congenital chylothorax (CC) occurs when lymphatic fluid accumulates within the pleural cavity (1). Diagnosis of CC is confirmed when analysis of pleural fluid shows a triglyceride content equal to or more than 1.13 mmol/l with a cell count equal to or more than 1000 cells/µL (80% or more lymphocytes) (2). In the post natal period, supportive methods like ventilator care, immediate drainage of effusion, and total parenteral nutrition (TPN) must be considered as first line treatment. Recently, using different doses of octreotide with different treatment responses was reported in some case reports (2, 3). Surgical methods can be useful as a final option when using those managements could not help (4). Here is a presentation of a birth traumatic case with bilateral (right prominent) pleural effusion successfully treated by supportive care and low dose of octreotide.

2. Case Presentation

This newborn male, weighing 3100 g, was delivered at 38th week of gestation from a 33-year-old mother through normal vaginal delivery. The score of Apgar was

6 in 5 minutes. The patient was hypotone and had no dysmorphic features. There were acrocyanosis, subcostal, and intercostal retractions, and the acceleratory muscles were used for breathing that showed respiratory distress. Therefore, the infant was ventilated with ambo bag (O₂ sat was about 75% - 80%) admitted to the neonatal intensive care unit (NICU) and finally connected to a ventilator at Baqiyatallah hospital in Tehran, Iran.

An early chest x-ray (CXR) showed bilateral (right more than left) pleural effusion with left-sided heart shift (Figure 1). Ultrasound revealed normal spleen, liver, and no ascites. Kidney, urinary tract, and bladder also were reported normal in ultrasound but the report confirmed bilateral pleural effusion (right prominent). Insertion of intercostal tubes (ICD) was performed and about 60 cc of pleural fluid was drained (First its color was light red and then gradually changed to white). Biochemistry analysis of pleural fluid showed following characteristics: glucose: 1.9425 mmol/l, protein: 11g/l, cholesterol: 1.295 mmol/l and triglycerides: 3.39 mmol/l. Counts of RBC and WBC were 10,000 and 2500 per Cu/mm.

After this, CC was diagnosed and TPN was initiated. After two weeks of begging TPN, accumulation of plural fluid was approximately stopped; therefore, we started feeding with a medium chain triglyceride (MCT). But plural effusion was seen once again and we had to restart TPN. Here we decided to start octreotide subcutaneously ($1 \mu\text{g}/\text{kg}/\text{day}$). With initiation of octreotide, bilateral pleural effusion was decreased, and respiratory status improved. Thus, after one week we started feeding again with MCT. No adverse effects of octreotide were seen. Ultrasound was performed daily and showed a decrease of pleural effusion in the right side. Moreover, there was no evidence of pleural fluid in the left side (Figure 2). After 20 days of using octreotide, the CXR and ultrasound did not show any pleural effusion accumulation in the both sides, and the patient was discharged. Follow-up physical examination and ultrasound done during 3 months showed no pleural effusion.

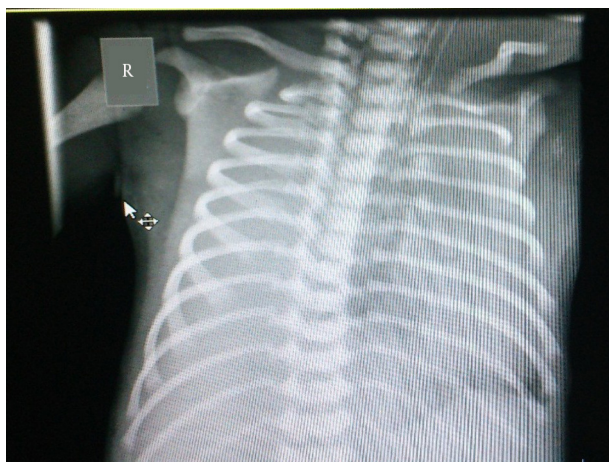


Figure 1. Bilateral Pleural Effusion

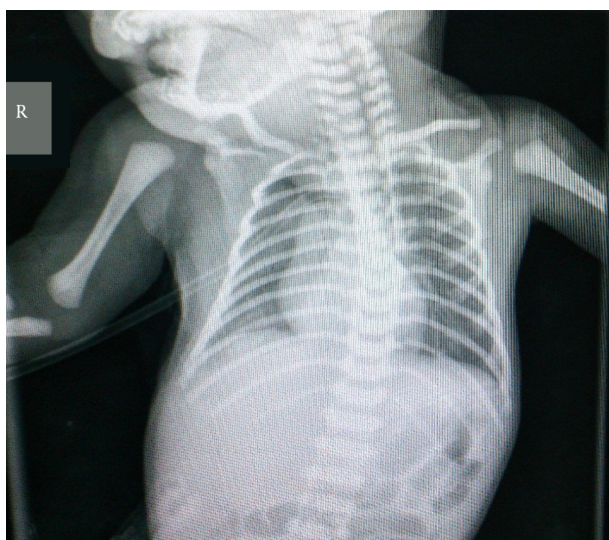

Figure 2. Decreasing the Plural Effusion

3. Discussion

As mentioned above chylothorax means accumulation of chyle within the pleural cavity, and it is based on the etiology. It is usually categorized in several forms like traumatic, spontaneous, and congenital (1). Here we presented a case of CC in a newborn male with trauma birth that was successfully treated by continuous administration of low dose of octreotide. The patient had a low Apgar score and was in respiratory distress status; so, he was shifted to the NICU and connected to a ventilator. After thoracentesis the baby had all criteria for diagnosis of CC. (Triglyceride content $\geq 1.13 \text{ mmol/l}$ with a cell count $\geq 1000 \text{ cells}/\mu\text{L}$ (80% or more lymphocytes)) (2) All options of therapeutic approaches for management of CC usually begin with supportive and conservative methods. Ligation of thoracic duct, pleural absorption, and pleurodesis as the surgery methods can be useful when all medical and conservative methods fail to reduce the pleural effusion and treatment of CC (4), conservative methods include long hospitalization, thoracentesis and insertion of chest tube, total parenteral nutrition, and introduction of a MCT diet (1, 4).

Also, octreotide is another option of conservative management that has been used in some cases for treatment of chylothorax. It is a peptide that mimics the effect of somatostatin pharmacological and results in the reduction of gastrointestinal secretions, intrahepatic venous flow, amount of triglyceride, and chyle output of pleural effusion (1, 5, 6). Intravenous infusion is necessary for somatostatin while octreotide can be used subcutaneously or intravenously (1). Table 1 shows the studies that have previously used octreotide for the treatment of CC (2-4, 7-16). Based on this table, octreotide has been successfully used for the treatment of CC in some studies; however, it should be taken into account that this treatment method cannot be applied in all cases of CC. In the majority of these studies, octreotide usually starts initially 0.5 to $1 \mu\text{g}/\text{kg}/\text{h}$ then gradually increases to $10 \mu\text{g}/\text{kg}/\text{h}$ (for 5 to 28 days). Mildly distended abdomen in two cases and pulmonary hypertension in 4 patients were side effects of the octreotide therapy reported in these studies.

In our case, low dose of octreotide ($1 \mu\text{g}/\text{kg}/\text{day}$) was given subcutaneously and after 20 days there was no pleural effusion. One of the advantages of using octreotide in our case was related to the feeding initiation time. After one week of using octreotide, we could start feeding with MCT without re-accumulation of fluid in the pleural cavity. Adverse effects are rare but diarrhea or constipation, nausea, vomiting and hyperglycemia, or hypoglycemia have been reported in some cases (1, 5). In our case, we did not see any side effects of octreotide even with 20 days of the octreotide therapy.

ongenital chylothorax even as a rare etiology of pleural effusion should be considered in neonate with pleural effusion and in respiratory distress. Low dose of octreotide has been used successfully in our case. Also, based

Table 1. Previous Studies Using Octreotide as a Treatment Method for Congenital Chylothorax (CC)

Author	Year	Number of Patients	Treatment Method	Failure	Side Effect
Rasiah (7)	2004	1	0.5 to 10 µg/kg/h for 10 days	No	Mildly distended abdomen
Young (8)	2004	1	40 µg/kg/day to a maximum dose of 70 µg/kg/day for 16 days	No	No
Sahin (9)	2005	1	0.5 to 10 µg/kg/h for 10 days	No	Mildly distended abdomen
Paget-Brown (10)	2006	1	3.5 to 10 µg/kg/h for 5 days	No	No
Altuncu (3)	2007	1	1 to 10 µg/kg/h for 28 days	yes	No
Bulbul (11)	2009	1	10 µg/kg/h	No	No
Matsukuma (12)	2009	2	0.5 to 10 µg/kg/h for 5 days	Both cases	No
Murki (13)	2010	1	1-10 µg/kg/h	yes	No
Sousa (2)	2010	1	3.5 to 10 µg/kg/h for 15 days	No	No
Foo (4)	2011	1	16 µg/kg/h subcutaneously in two divided doses and gradually increased to 48 µg/kg/h, and a 7-day course was completed	No	No
Horvers (14)	2012	7	5 - 6 µg/kg/min	No	Pulmonary hypertension in 4 patients
Shah (15)	2012	6	0.5 to 10 µg/kg/min for 12 - 27 days	No	No
Downie (16)	2014	3	Not mentioned	No	No

Con the Table 1, it can be concluded that octreotide can be considered as a good option for conservative management of CC. However, in which cases and how the use of octreotide is helpful? More studies like clinical trials are still necessary to investigate all aspects of octreotide treatment to determine the amount of its dose, time of initiation and duration of treatment, its treatment effect together with other conservative treatment and etc.

Authors' Contributions

Shahla Afsharpaiman: Study concept and design, critical revision of the manuscript for important intellectual content, study supervision. Mohammad Saeid Rezaee Zavareh: Study concept and design, acquisition of data, and drafting of the manuscript. Mohammad Torkaman: Study concept and design, and drafting of the manuscript.

References

- Barkat A, Benbouchta I, Karboubi L, Ghanimi Z, Kabiri M. A patient with traumatic chylothorax. *Int J Gen Med.* 2012;5:759-62.
- Sousa PR, Leitão H, Camacho MC, Nunes JL. Idiopathic congenital chylothorax treated with octreotide. *BMJ Case Rep.* 2010;2010:bcr0620091950.
- Altuncu E, Akman I, Kiyani G, Ersu R, Yurdakul Z, Bilgen H, et al. Report of three cases: congenital chylothorax and treatment modalities. *Turk J Pediatr.* 2007;49(4):418-21.
- Foo NH, Hwang YS, Lin CC, Tsai WH. Congenital chylothorax in a late preterm infant and successful treatment with octreotide. *Pediatr Neonatol.* 2011;52(5):297-301.
- Moreira-Pinto J, Rocha P, Osorio A, Bonet B, Carvalho F, Duarte C, et al. Octreotide in the treatment of neonatal postoperative chylothorax: report of three cases and literature review. *Pediatr Surg Int.* 2011;27(8):805-9.
- Cheung Y, Leung MP, Yip M. Octreotide for treatment of postoperative chylothorax. *J Pediatr.* 2001;139(1):157-9.
- Rasiah SV, Oei J, Lui K. Octreotide in the treatment of congenital chylothorax. *J Paediatr Child Health.* 2004;40(9-10):585-8.
- Young S, Dalgleish S, Eccleston A, Akierman A, McMillan D. Severe congenital chylothorax treated with octreotide. *J Perinatol.* 2004;24(3):200-2.
- Sahin Y, Aydin D. Congenital chylothorax treated with octreotide. *Indian J Pediatr.* 2005;72(10):885-8.
- Paget-Brown A, Kattwinkel J, Rodgers BM, Michalsky MP. The use of octreotide to treat congenital chylothorax. *J Pediatr Surg.* 2006;41(4):845-7.
- Bulbul A, Okan F, Nuhoglu A. Idiopathic congenital chylothorax presented with severe hydrops and treated with octreotide in term newborn. *J Matern Fetal Neonatal Med.* 2009;22(12):1197-200.
- Matsukuma E, Aoki Y, Sakai M, Kawamoto N, Watanabe H, Iwagaki S, et al. Treatment with OK-432 for persistent congenital chylothorax in newborn infants resistant to octreotide. *J Pediatr Surg.* 2009;44(3):e37-9.
- Murki S, Faheemuddin M, Gaddam P. Congenital chylothorax-successful management with chemical pleurodesis. *Indian J Pediatr.* 2010;77(3):332-4.
- Horvers M, Mooij CF, Antonius TA. Is octreotide treatment useful in patients with congenital chylothorax? *Neonatology.* 2012;101(3):225-31.
- Shah D, Sinn JKH. Octreotide as therapeutic option for congenital idiopathic chylothorax: a case series. *Acta Paediatr.* 2012;101(4):e151-5.
- Downie L, Sasi A, Malhotra A. Congenital chylothorax: associations and neonatal outcomes. *J Paediatr Child Health.* 2014;50(3):234-8.