



Case Report

Subdural electrode recording of generalized photoepileptic responses

L. Mukundan^a, O.V. Lie^{a,d}, L.D. Leary^{a,b,d}, A.M. Papanastassiou^{c,d}, L.C. Morgan^{a,d}, C.Á. Szabó^{a,c,d,*}^a Department of Neurology, University of Texas Health Science Center at San Antonio, San Antonio, TX, USA^b Department of Pediatrics, University of Texas Health Science Center at San Antonio, San Antonio, TX, USA^c Department of Neurosurgery, University of Texas Health Science Center at San Antonio, San Antonio, TX, USA^d South Texas Comprehensive Epilepsy Center, San Antonio, TX, USA

ARTICLE INFO

Article history:

Received 6 October 2014

Received in revised form 9 October 2014

Accepted 15 October 2014

Available online 26 December 2014

Keywords:

Photosensitivity

Generalized photoconvulsive response

Intracranial EEG

Cortical dysplasia

Epilepsy surgery

ABSTRACT

We evaluated the spatiotemporal distribution of photic driving (PDR), photoparoxysmal (PPR), and photoconvulsive (PCR) responses recorded by intracranial electrodes (ic-EEG) in a patient with generalized photosensitivity and right frontal lobe cortical dysplasia. Intermittent light stimulation (ILS) was performed thirteen times in nine days. Cortical responses to ILS recorded by ic-EEG were reviewed and classified as PDRs, PPRs, and PCRs. Photic driving responses were restricted to the occipital lobe at ILS frequencies below 9 Hz, spreading to the parietal and central regions at >9 Hz. Photoparoxysmal responses commonly presented as focal, medial occipital, and parietal interictal epileptic discharges (IEDs), the latter propagating to the sensorimotor cortices. Generalized IEDs were also generated in the setting of PPRs. Photoconvulsive responses, characterized by repetitive bilateral upper extremity myoclonus sustained until the end of the stimulus, were associated with propagation of the medial parieto-occipital discharge to the primary sensorimotor and supplementary area cortices, while generalized myoclonic seizures were associated with a generalized spike-and-wave discharge with an interhemispheric posterior cingulate onset sparing the sensorimotor cortices. Both types of PCR could occur during the same stimulus. Regardless of the pathway, PCRs only occurred when PDRs involved the parietal cortices. While there may be more than one pathway underlying PCRs, parietal lobe association cortices appear to be critical to their generation.

© 2014 The Authors. Published by Elsevier Inc. This is an open access article under the CC BY-NC-ND license (<http://creativecommons.org/licenses/by-nc-nd/3.0/>).

1. Introduction

Photosensitivity is encountered in 5% of patients with epilepsy, with increased prevalence in association with genetic generalized epilepsies (GGEs) [1]. As patients with genetic generalized epilepsies (GGEs) are not typically evaluated for epilepsy surgery, generalized photoparoxysmal (PPR) or photoconvulsive (PCR) responses have not been recorded with intracranial electroencephalography (ic-EEG). However, photoepileptic responses were reported in two patients with medically refractory localization-related epilepsy undergoing ic-EEG monitoring for resective surgery [2,3]. In these cases, intermittent light stimulation (ILS) triggered habitual complex partial seizures but not generalized photoepileptic responses. While magnetoencephalography (MEG) and functional MRI studies of photosensitivity in GGEs

provide insight into the networks underlying generalized PPRs and PCRs, the mechanisms are still largely unknown [4–6].

2. Case report

An 18-year-old right-handed young man with medically refractory localization-related epilepsy since age 3 years old was evaluated for epilepsy surgery at the South Texas Comprehensive Epilepsy Center in San Antonio, Texas. The patient provided consent for this presentation of his clinical history, MRI, and video-EEG findings. He had focal left-sided myoclonic seizures, focal seizures with left-sided or bilateral tonic activity, and associated loss of awareness, as well as secondary generalized tonic-clonic seizures (GTCSs) following left head version, often triggered by decreased sleep and excessive fatigue. He had a family history of epilepsy but no other etiological factors. His brain MRI showed right inferior frontal gyrus cortical dysplasia abutting the motor cortex. On scalp video-EEG monitoring, habitual partial seizures as well as focal and generalized interictal epileptic discharges (IEDs) were recorded. Furthermore, generalized PPRs and PCRs were elicited by ILS at 6–30 Hz.

Intracranial electrodes were implanted to confirm the right frontal onset of his spontaneous clinical seizures and map the motor cortex. Subdural electrodes over parietal and occipital regions were implanted

* Corresponding author at: Department of Neurology, University of Texas Health Science Center at San Antonio, 8300 Floyd Curl Drive, San Antonio, TX 78229-7883, USA. Tel.: +1 210 450 9700; fax: +1 210 562 9367.

E-mail address: szabo@uthscsa.edu (C.Á. Szabó).

in order to study the relationship of the epileptogenic dysplastic cortex and the suspected generalized photosensitivity and epilepsy phenotypes.

His ic-EEG evaluation (Nihon Kohden, Japan; sampling rate: 500 Hz, 1- to 70-Hz frequency bandpass) included both subdural grid and strip electrodes (PMT, Minnesota, USA; 8 × 8 grid with closely spaced electrodes 2 mm in diameter, 5-mm spacing; all other electrodes were 3 mm in diameter, 10-mm spacing) implanted through a right craniotomy. An 8 × 8 contact grid (IFG) was placed over the right inferior perirolandic area, covering the area of cortical dysplasia, while a 5 × 2 contact grid (SFG) covered the more superior sensorimotor cortices (Fig. 1). Anteriorly, there were three 1 × 6 contact frontal strips (SF7–12, MF7–12, IF1–6) and a 1 × 6 superomedial strip (AIH1–6), while posteriorly, there were two 1 × 12 strips, an occipital strip (O1–12) and a parietal strip (P), which was reduced to eight contacts (5–12). Medially, the O strip crossed the calcarine sulcus, and a posterior interhemispheric 1 × 6 contact strip (PIH1–6) traversed the supplementary motor area, reaching the posterior cingulate. An additional 1 × 4 contact strip (G) was used as a ground and reference.

Antiepileptic medications were rapidly tapered (carbamazepine when video-EEG monitoring was initiated, lacosamide 24 h later). Our patient underwent ILS and hyperventilation on a daily basis, procedures that are routinely performed in order to provoke seizures. As soon as the patient exhibited generalized PCRs during ILS, he was asked whether he wanted to continue with the procedure, and he invariably agreed. Intermittent light stimulation provoked only generalized myoclonic seizures, never activating any of his habitual focal seizures with loss of awareness or any type of GTCSs. Once his habitual seizures were recorded, stimulations were discontinued. Extraoperative electrocortical stimulation activated face motor cortex rostral to the epileptogenic zone on IFG and hand and arm motor cortices at SFG5 and 7, respectively. He underwent a resection of the right frontal lesion covered by IFG, and cortical dysplasia was confirmed by pathological examination. After resolution of a transient left facial paresis, he remains seizure-free at more than three years postoperatively off antiepileptic medications. However, a postoperative EEG demonstrated persistent generalized IEDs.

Intermittent light stimulation was performed at ascending and descending frequencies of 1–30 Hz for 10 s at each frequency. He was exposed to ILS 13 times during a period of nine days until he exhibited his first habitual seizure (Fig. 2). Photic driving responses (PDRs) were elicited at all frequencies at contacts O1–3, never extending beyond electrodes O1–6 below 9 Hz. At ILS frequencies 9–30 Hz, PDRs involved P5–7 (medial parietal) electrodes. Intermittent light stimulation induced PPRs on 104 occasions. Photoparoxysmal responses presented as focal spikes at O7 (lateral occipitoparietal) at all frequencies, occurring within 200 ms of PDR onset. Off AEDs, P5–8 spikes were encountered at ILS frequencies >9 Hz, often preceding O7 spikes, with secondary propagation to contacts

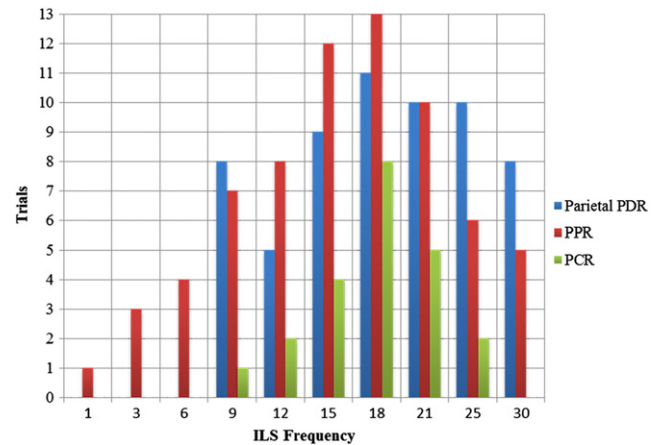


Fig. 2. Relationship of ILS frequency to photic responses. Legend: PCRs include Types 1 and 2.

PIH1–2 (posterior cingulate) and AIH2 (medial frontal convexity), or in the form of generalized, frontally-predominant, spike-and-wave complexes within 200–400 ms of PDR onset. Similarly, PCRs recorded in 34 stimulations consisted of either a repetitive low-amplitude myoclonus, affecting the upper more than the lower extremities, and the trunk and face to a lesser extent, which lasted until the end of the stimulus (Type 1), or a brief generalized myoclonic seizure affecting the face and entire body (Type 2). Type 1 PCR was associated with propagation of the ictal discharge to contacts P7/8 and 12, PIH1–2 and 5–6, as well as SFG5/7/8 and 10 within 800–1200 ms of PDR onset (Fig. 3). Type 2 PCR was associated with a generalized spike-and-wave discharge triggered only at ILS frequencies of 15–25 Hz about 600–1000 ms after PDR onset (Fig. 4). The frontally predominant discharges were preceded by P5–7 (medial parietal) spiking but with lead from contacts PIH1–2 (posterior cingulate). The ictal discharge also involved contacts P10, SFG3/4/6/8, PIH1–4, and AIH1–2, as well as the entire SF, MF, and IF strips. Although the electrode distribution was distinct for each type of PCR, both types of PCRs could be observed during the same stimulus and always in the setting of a medial parietal PDR or spiking. During PCRs, the PDR was briefly visible more anteriorly, at PIH1–2 and/or 5–6, at SFG3/5/7/8 and 10, and at AIH2, but only after onset of the myoclonus.

The O and P strips did not demonstrate any spontaneous ictal or interictal discharges. While the right frontal cortex demonstrated continuous periodic IEDs interictally, these were not altered by ILS or photoepileptic responses. Following one GTCS, our patient demonstrated a cluster of spontaneous generalized myoclonic seizures, and the associated ictal discharge involved the same electrodes as the Type 2 PCR, with the exception of the O and P strips.

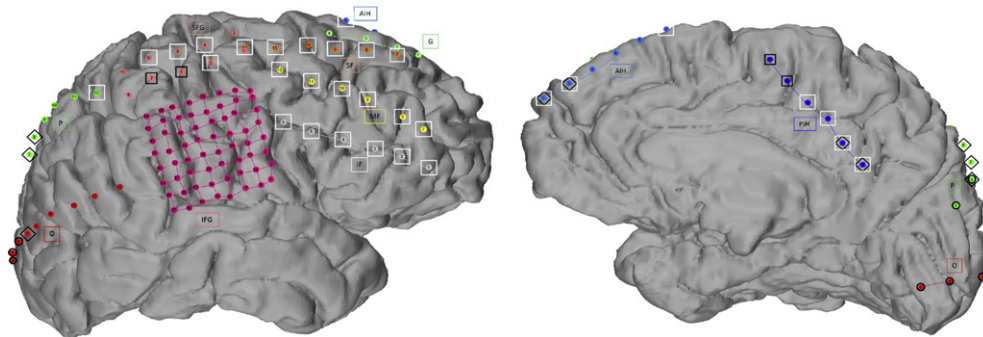


Fig. 1. Intracranial electrode map demonstrating photic driving response and distribution of ictal discharge during both types of photoconvulsive response. Legend: Lateral and medial views of the intracranial electrodes and maps. Inferior frontal grid (IFG, magenta) covering cortical dysplasia and superior frontal grid (SFG, maroon); frontal (SF, orange; MF, yellow; IF, gray), anterior interhemispheric (AIH, light blue) and posterior interhemispheric (PIH, dark blue), parietal (P, green), occipital (O, red), and ground (G, light green) strips. The first contact of each grid or strip is marked by a diagonal bar for orientation. Black circles represent PDRs, black diamonds Type 1 PCRs, and white squares Type 2 PCRs.

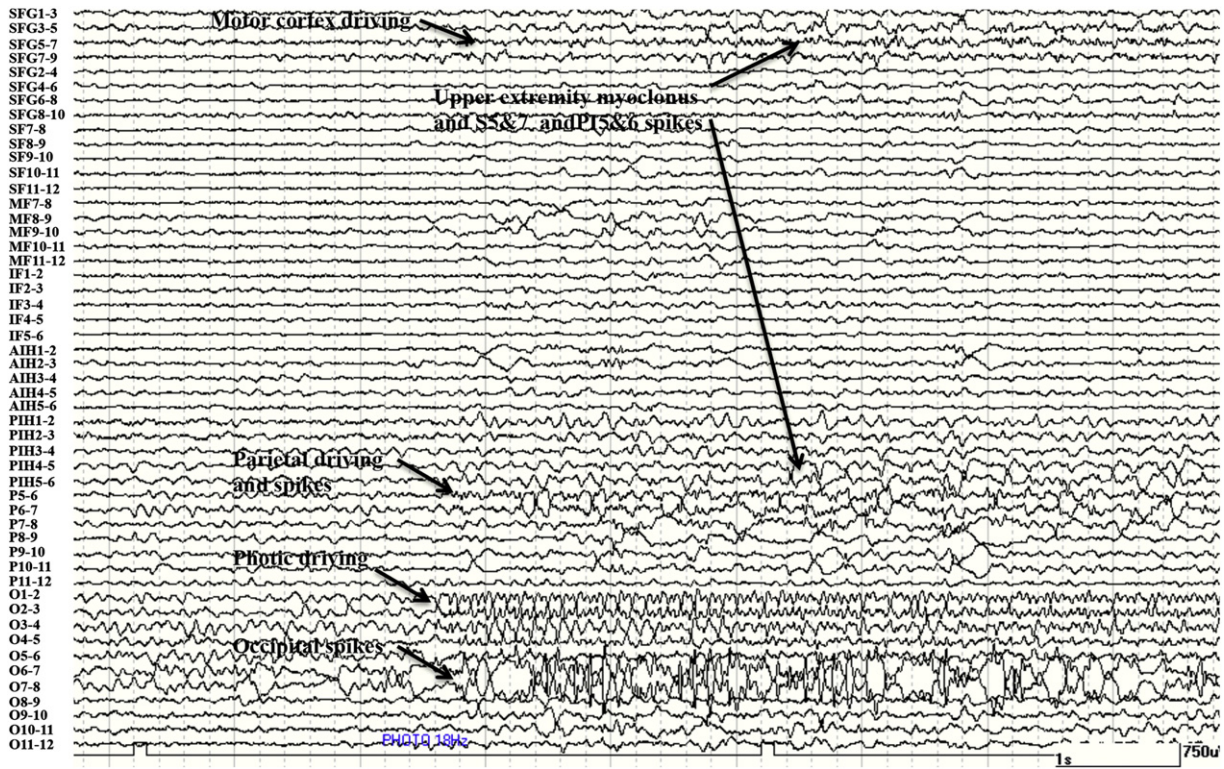


Fig. 3. Intracranial EEG recording of Type 1 PCR. Legend: Type 1 PCR demonstrating posterior–anterior propagation of the ictal discharge. Note the driving response at O1–6, P5–6, AIH2, PIH5–6, and the SFG grid. For electrode abbreviations see Fig. 1.

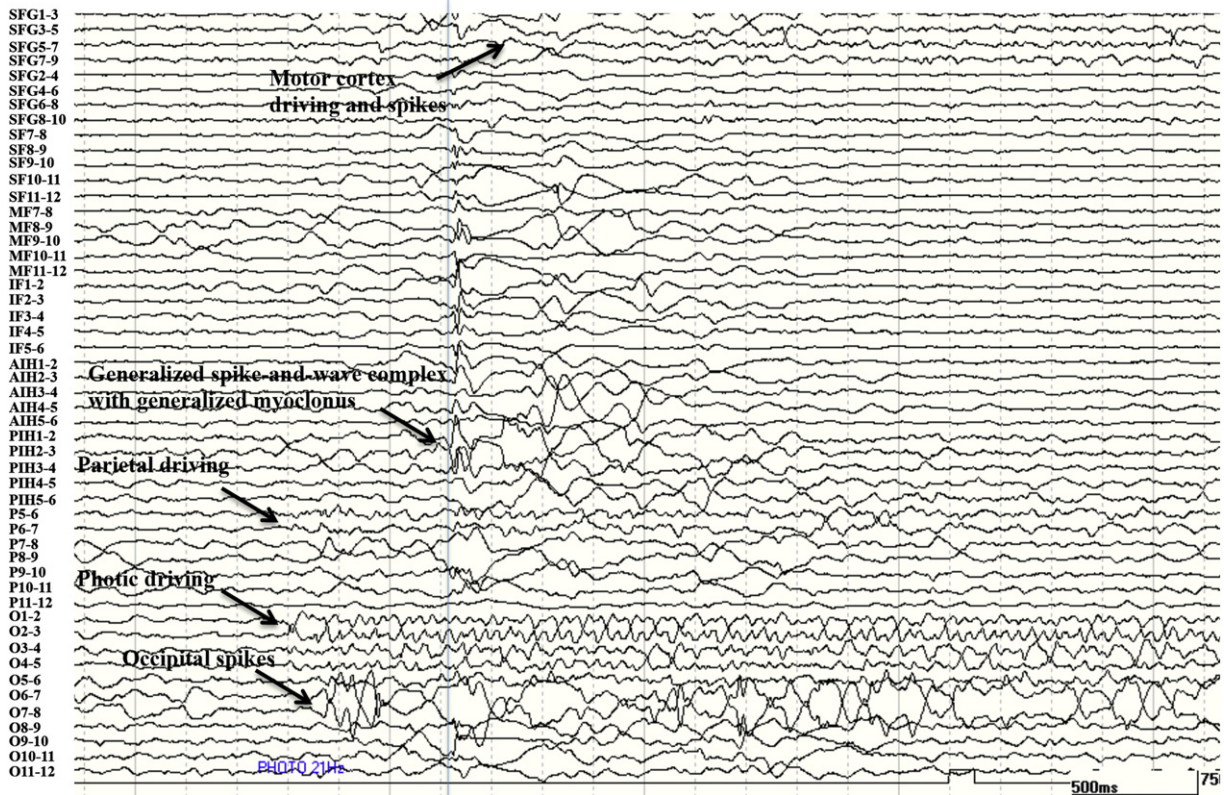


Fig. 4. Intracranial EEG recording of Type 2 PCR. Legend: Type 2 PCR demonstrating generalized epileptic discharge at higher temporal resolution (the transparent line marks the initial phase of generalized discharge at P11–2). Note the driving response at O1–6, P5–6, PIH1–2, and the SFG grid. For electrode abbreviations see Fig. 1.

3. Discussion

Our patient with medically refractory partial epilepsy due to focal cortical dysplasia demonstrated generalized and PCRs, which were recorded by ic-EEG for the first time. Despite the focal cortical dysplasia underlying his refractory partial epilepsy, our patient had spontaneous generalized myoclonic seizures, as well as generalized PPRs and PCRs, which were electroclinically distinct from his focal IEDs and seizures. Evidence of persistent generalized IEDs and PPRs even after successful epilepsy surgery further supports the presence of a separate GGE phenotype. The coexistence of genetic generalized and symptomatic focal epilepsies has been described in the setting of ic-EEG evaluations and EEG–fMRI studies [7,8]. In one surgical case series, as in our patient, the generalized epilepsy phenotype persisted despite the successful treatment of the focal epilepsy [7].

Photoparoxysmal responses were characterized by activation of multifocal discharges in the parieto-occipital, posterior cingulate, and medial prefrontal cortices, demonstrating a posterior-to-anterior propagation or by a frontally predominant generalized discharge. The prominent parietal activation during PPRs reflects findings of cortical synchronization in MEG and fMRI studies [4,5]. Photoconvulsive responses were characterized by either a bilateral upper extremity myoclonus lasting throughout the stimulus associated with activation of the motor cortices (Type 1) or a brief generalized myoclonic seizure associated with a frontally-predominant generalized ictal discharge extensively involving the premotor cortices (Type 2). Regional posterior-to-anterior propagation was noted in the Type 1 PCR, from the parietal lobe cortices to the motor and premotor cortices. The Type 2 PCR did not demonstrate a similar corticocortical propagation; rather, the emergence of a generalized spike-and-wave discharge suggests activation of a cortical–subcortical network, albeit with a lead from the posterior cingulate region and after medial parietal spiking. Both types of PCRs could occur during the same stimulus but could involve different cortical areas, suggesting activation of distinct corticocortical or cortical–subcortical networks. Regardless of the pathway, PCRs only occurred when PDRs involved the medial parietal cortices. Furthermore, spiking during ILS was first noted in occipital and parietal regions prior to the sensorimotor cortices and frontal lobes. This finding contradicts the pervasive view that photoepileptic responses are generated frontocentrally [6,9,10].

Nonetheless, it is important to point out that our observations are limited to a single case, and PPRs or PCRs may be expressed differently in people with pure genetic generalized epilepsies, and particular pathways may be specific to some GGE syndromes. The interpretation of our data may also be limited by temporal and spatial EEG sampling. Increased EEG sampling rates and high-frequency filter settings may

have helped demonstrate synchronization of gamma-frequency activity across larger cortical areas even before the appearance of photoepileptic responses [4]. More closely spaced medial (interhemispheric) coverage may have yielded better spatial resolution of potential cortical generators and propagation of the ictal discharge. Furthermore, thalamic sampling was not clinically indicated but may have elucidated potential cortical–subcortical interactions in each type of PCR.

4. Conclusions

In summary, photosensitivity appears to be associated with PDRs extending beyond the primary visual areas. The parietal lobes appear to play an important role in the generation of generalized PPRs and PCRs, regardless of their electroclinical characterization.

Acknowledgments

This study was presented at the American Academy of Neurology Meeting held in San Diego, CA, in April 2013.

Disclosures

The authors declare that they have no conflicts of interest in the publication of this report.

References

- [1] de Bittencourt PRM. Photosensitivity: the magnitude of the problem. *Epilepsia* 2004; 45(Suppl. 1):30–4.
- [2] Benbadis SR, Gerson WA, Harvey JH, Lüders HO. Photosensitive temporal lobe epilepsy. *Neurology* 1996;46:1540–2.
- [3] Isnard J, Guenot M, Fischer C, Mertens P, Sindou M, Maugiere F. A stereoelectroencephalographic (SEEG) study of light-induced mesiotemporal epileptic seizures. *Epilepsia* 1998;39:1098–103.
- [4] Parra J, Kalitzin SN, Iriarte J, Blanes W, Velis DN, Lopes da Silva FH. Gamma-band phase clustering and photosensitivity: is there an underlying mechanism common to photosensitive epilepsy and visual perception? *Brain* 2003;126:1164–72.
- [5] Moeller F, Siebner HR, Ahlgrim N, Wolff S, Muhle H, Granert O, et al. fMRI activation during spike and wave discharges evoked by photic stimulation. *Neuroimage* 2009;48:682–95.
- [6] Bartolini E, Pesaresi I, Fabbri S, Cecchi P, Giorgi FS, Sartucci F, et al. Abnormal response to photic stimulation in juvenile myoclonic epilepsy: an EEG–fMRI study. *Epilepsia* 2014;55:1038–47.
- [7] Jeha LE, Morris HH, Burgess RC. Coexistence of focal and idiopathic generalized epilepsy in the same patient population. *Seizure* 2006;15:28–34.
- [8] Chassagnon S, Hawko CS, Bernasconi A, Gotman J, Dubeau F. Coexistence of symptomatic focal and absence seizures: video-EEG and EEG–fMRI evidence of overlapping but independent epileptogenic networks. *Epilepsia* 2009;50:1821–6.
- [9] Naquet R, Catier J, Menini C. Neurophysiology of photically induced epilepsy in *Papio papio*. *Adv Neurol* 1975;10:107–18.
- [10] Varotto G, Visani E, Canafoglia L, Franceschetti S, Avanzini G, Panzica F. Enhanced frontocentral EEG connectivity in photosensitive generalized epilepsies: a partial directed coherence study. *Epilepsia* 2012;53:359–67.