



ELSEVIER

Contents lists available at [ScienceDirect](https://www.sciencedirect.com)

Trauma Case Reports

journal homepage: www.elsevier.com/locate/tcr

Case Report

A case report of blunt intraoral cerebrovascular injury in a child following intraoral trauma: The pen is mightier than the sword[☆]Kay Hon^{a,b,*}, Denise Roach^{b,c}, Joseph Dawson^{a,c,d}^a Department of Vascular & Endovascular Surgery, Royal Adelaide Hospital, South Australia, Australia^b Faculty of Health & Medical Sciences, The University of Adelaide, South Australia, Australia^c South Australia Medical Imaging, Central Adelaide Local Health Network, South Australia, Australia^d Trauma Surgery Unit, Royal Adelaide Hospital, South Australia, Australia

ARTICLE INFO

Keywords:

Carotid
Dissection
Intraoral
Blunt
Trauma
Paediatric

ABSTRACT

Carotid artery dissection in the paediatric population is uncommon and in rare cases it can be due to intraoral blunt trauma associated with a stick-like object such as pen or chopstick in the mouth at the time of injury. Given the rarity of the condition, there is significant knowledge gap in evidence-based diagnosis and management of paediatric blunt cerebrovascular injury (BCVI). This case report presents a rare case of asymptomatic carotid artery dissection due to intraoral blunt trauma in a young patient and the successful conservative management. This report also demonstrated the sonographic progression of the carotid artery dissection on follow up imaging.

Introduction

Blunt cerebrovascular injury (BCVI) in children, whilst rare, can lead to stroke in the paediatric population [1]. Intraoral blunt trauma is a rare cause for carotid dissection and has only been described by a limited number of case series [2,3]. It is often associated with a stick-like object such as pen in the mouth during a fall or blow to the head or neck. There is very limited knowledge regarding initial management, imaging findings and progression of BCVI in paediatric patients. We present a case study demonstrating progressive remodelling a carotid artery dissection on repeat ultrasound imaging.

Case report

A healthy 5-year-old boy was brought into the emergency department following a fall into his face whilst having a pen in the mouth. He complained of pain inside the mouth with some intraoral bleeding.

Initial examination revealed right upper palate contusion with minimal laceration but no evidence of penetrating injury. He was neurologically intact and with no evidence of airway compromise. However, a soft bruit was heard on auscultation over the right carotid artery. An arterial duplex ultrasound was performed demonstrating an intimal flap within the right internal carotid artery (ICA) (Fig. 1). A CT (computed tomography) angiogram of his carotid arteries and brain was performed to further delineate the injury. This confirmed a right ICA dissection, with the intimal flap extending 19 mm along the lateral wall of the ICA with no significant stenosis or occlusion (Fig. 2). Neuroimaging was otherwise unremarkable.

[☆] This work has not been presented in any meeting

* Corresponding author at: 1 Port Road, Adelaide, SA 5000, Australia.

E-mail address: Kay.hon@sa.gov.au (K. Hon).

<https://doi.org/10.1016/j.tcr.2021.100567>

Accepted 4 December 2021

Available online 8 December 2021

2352-6440/Crown Copyright © 2021 Published by Elsevier Ltd. This is an open access article under the CC BY-NC-ND license

(<http://creativecommons.org/licenses/by-nc-nd/4.0/>).

He was started on 100 mg acetylsalicylic acid (ASA, aspirin) and was admitted for observation overnight. He was discharged home the following day with advice to avoid strenuous physical activity for at least one week with graduated return to normal activity. Carers were also educated to monitor for neurological signs and symptoms and to seek medical attention if any new or worsening symptoms. ASA was ceased after 12 months, and patient did not experience any adverse events from ASA. Arterial duplex ultrasound repeated 2 months after the injury demonstrated favourable arterial remodelling characterised by thrombosis of the false lumen of the dissection, whilst the true lumen remained patent (Fig. 3).

Over the next four years serial duplex ultrasound performed at 6, 12, 24 and 48 months demonstrated progressive arterial remodelling, and whilst the injured area remained identifiable, the original flap is well adhered and integrated into the proximal ICA vessel wall (Fig. 4).

Discussion

There are four described mechanisms for blunt carotid injury. The present case conforms to a type III mechanism leading to carotid injury due to blunt trauma to the ICA behind the soft palate at the angle of the jaw. It has been previously highlighted that blunt lateral oropharyngeal trauma at this location is more likely to injure the ICA due to its proximity to bony structures such as the skull base and cervical transverse processes [3]. This compressive force can then lead to intimal disruption, vessel wall dissection, platelet activation and aggregation, leading to thrombus formation. The development of neurological deficits can be attributed to acute vessel occlusion, formation of a pseudoaneurysm, or because of distal embolization of thrombus into the cerebral circulation.

Intraoral injury accounted for only 7 cases of traumatic carotid dissection in a review of 34 case reports published between 1961 and 2007 [2]. Within this cohort all 7 patients were reported to have intact neurological status immediately post injury, but only one remained asymptomatic on presentation [3]. The patient who was asymptomatic on presentation underwent imaging which showed flow disruption suggestive of carotid artery dissection and was treated with low molecular weight heparin. On review at 21 months patient remained asymptomatic. One patient underwent thrombectomy of the ICA in the setting of right hemiparesis and aphasia. A year later speech had recovered but residual hemiparesis persisted. A further three cases have been reported with one patient being symptomatic almost immediately post injury [4–6]. Lubarsky et al. presented a case of a 6-year-old boy whose imaging showed abrupt stenosis of left ICA with an evolving pseudoaneurysm proximally. He fell whilst chewing on a wooden arrow and developed significant neurological symptoms: loss of consciousness, decorticate posturing and apnoeic episode. He was treated with intravenous heparin and improved significantly. He was discharged home with enoxaparin injection which was eventually transitioned to aspirin 100 mg as he remained neurologically intact. His follow-up imaging also showed recanalization of the ICA. Bent et al. reported a 16-month-old girl who fell onto her toothbrush required decompressive craniotomy and therapeutic anticoagulation for occlusion of right ICA with large right MCA territory infarct. She has residual left hemiparesis on follow up at 4 month [4]. These cases showed that neurological symptoms secondary to BCVI from intraoral trauma could manifest from 1 h to 48 h after the initial injury if patients were not already symptomatic from the impact of injury or they may not be symptomatic at all [7]. Given the variability in time of onset of symptoms in paediatric patients who sustained BCVI due to intraoral trauma, decision to proceed to imaging and subsequent management will need careful consideration taking into consideration of time of injury, characteristics of objects impaled (sharp or blunt), and if any other risk factors or predictors of BCVI are present [1]. We recommend close observation of the patient with a diagnosed BCVI on imaging for

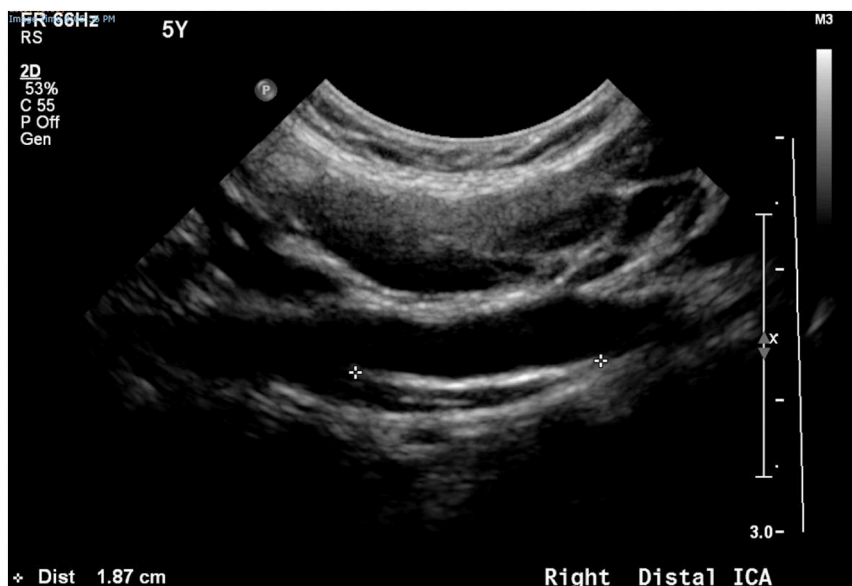

Fig. 1. B-mode ultrasound on presentation demonstrating ICA dissection and extent of intimal flap (green cross). (For interpretation of the references to colour in this figure legend, the reader is referred to the web version of this article.)

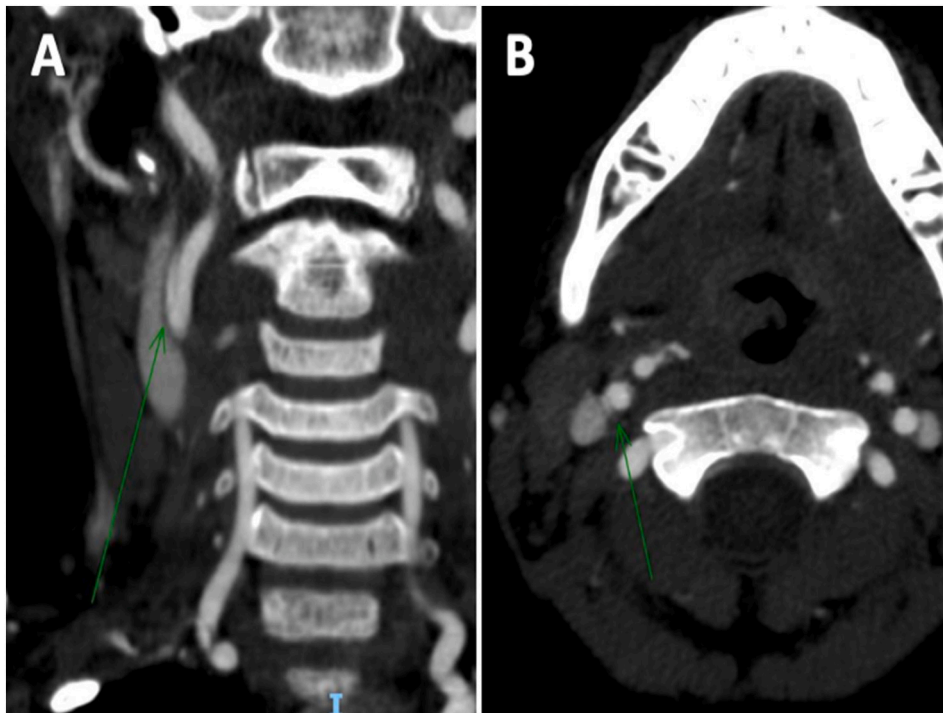


Fig. 2. CT Angiogram on presentation demonstrating ICA dissection (green arrow) in coronal (A) and axial (B) views. (For interpretation of the references to colour in this figure legend, the reader is referred to the web version of this article.)

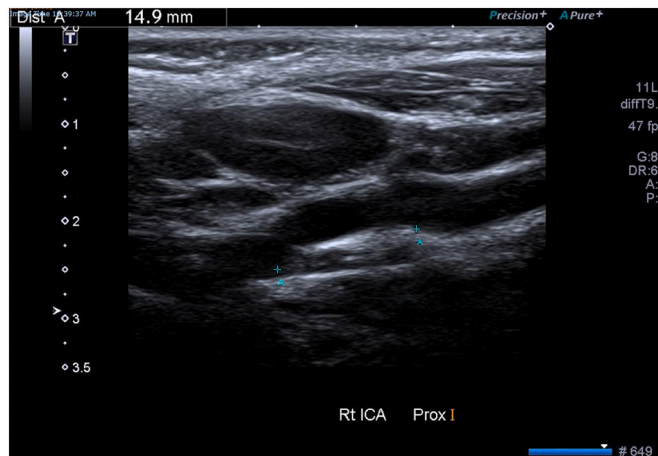


Fig. 3. B-mode ultrasound at 2 months demonstrating favourable arterial remodelling with thrombosis of the false lumen with patent true lumen.

at least 24 h. If a decision was made not to proceed with imaging due to low suspicion, then the patient should be monitored either as an inpatient or if discharged, clear instructions and education must be provided to cares, recognising that delayed symptoms can present 48 h after the injury.

Whilst screening for BCVI has rapidly gained traction in adult trauma, there is no consensus on screening guidelines in paediatrics. Many paediatric trauma centres are extrapolating the modified Memphis or Denver criteria developed for use in adults. In a multi-institutional study, when applying the Memphis criteria to the paediatric population, screening rates are lower compared to adults, with a consequential risk of missed diagnosis [8]. However, Mallicote et al. reported that 97% of paediatric patients who fulfilled both the Denver and Memphis criteria for screening with CTA had negative imaging findings [9]. Our patient underwent imaging as carotid bruit was present on examination, one of the six clinical criteria in the Denver criteria. Adherence to the Memphis criteria would not have led to imaging. The McGovern screening score is a recently developed tool aimed to address the lack of paediatric specific BCVI screening instrument. It differs to the modified Denver and Memphis criteria by assigning the mechanism of injury with a point value of

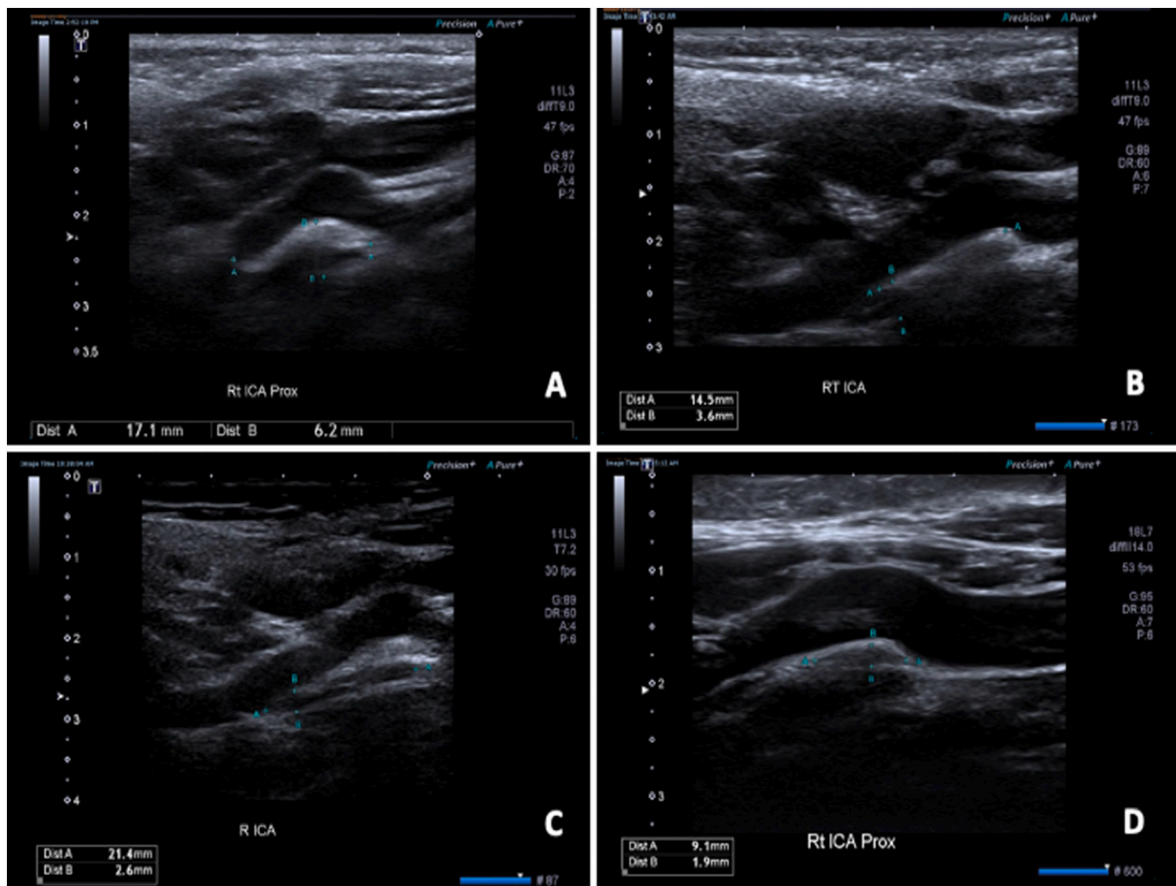


Fig. 4. Serial B-mode ultrasound performed at 6 (A), 12 (B), 24 (C) and 48 (D) months demonstrating progressive arterial remodelling.

2. This results in higher sensitivity in detecting BCVI in paediatric population where neurological symptoms were not prominent on admission. However, the use of McGovern screening score in our patient would also not have resulted in imaging [10].

Follow up imaging is recommended and is essential given that BCVI is a dynamic pathology [11]. In our case, patient had a grade 2 injury (dissection or intramural haematoma with >25% luminal narrowing) which demonstrated uncomplicated arterial remodelling in subsequent imaging. The grading of the injury is clinically relevant to assist clinicians in prognostication. In a retrospective review of 117 low grade (grades 1 and 2) BCVIs in adult patients, only 14% showed radiographical worsening on repeat CT imaging in 6 months' time whilst 64% showed complete resolution and the rest was either improving or stable at repeat imaging at about mean 60 days [12].

Available literature mainly described remodelling via recanalization post carotid dissection however none has described or able to demonstrate sonographically the gradual integration of intimal flap into the arterial wall [13]. In this case study, follow up imaging at 3, 6, and 12 months following the injury showed persistent dissection flap at the proximal ICA whilst patient remained clinically unchanged. However, given the persistent sonographic findings, a further duplex ultrasound was performed 26 months from the initial injury that showed that the dissection flap has now adhered to the arterial wall and integrated into the proximal ICA.

CTA has been recommended for screening for BCVI in adult population however there is valid concern regarding the risk of radiation relating with the use of CTA in paediatric population. MRA has been recommended as a first line imaging for the paediatric population as it is non-invasive with no radiation risk and allows neuroimaging at the same time. However, the quality and sensitivity of MRA is very dependent on the subject's ability to minimise movement artefacts which may require sedation or general anaesthesia. Ultrasound is also commonly used as it has been reported that the use of brightness-mode (B mode) with doppler has higher sensitivity in detecting carotid dissection when compared with other static vessel imaging [14].

Conclusion

This case study demonstrated successful conservative management of an asymptomatic BCVI following intraoral trauma with subsequent arterial remodelling. Our case study is the only case study that we are aware of that have demonstrated sonographic progression of carotid artery remodelling in a paediatric patient following BCVI due to intraoral blunt trauma. There remains a significant knowledge gap in the evidence-based management of paediatric BCVI, and the consequence of an undiagnosed BCVI following seemingly innocuous trauma in the paediatric population may have disastrous outcomes. Therefore, prompt diagnosis and

management based on clinical suspicion is essential, with the duration of follow-up in conservatively managed cases remaining largely individually based. The use of arterial duplex ultrasound in this population should be encouraged as it is a valid and non-invasive, non-radiation-based tool.

Author contributions

Kay Hon: writing - original draft; visualisation.

Joseph Dawson: Conceptualisation, methodology, writing – review and editing, supervision.

Denise Roach: Resources, writing – review and editing,

References

- [1] M.C. Dewan, V.M. Ravindra, S. Gannon, et al., Treatment practices and outcomes after blunt cerebrovascular injury in children, *Neurosurgery* 79 (6) (2016) 872–878.
- [2] R.B. Chamoun, M.E. Mawad, W.E. Whitehead, T.G. Luerssen, A. Jea, Extracranial traumatic carotid artery dissections in children: a review of current diagnosis and treatment options, *J. Neurosurg. Pediatr.* 2 (2) (2008) 101–108.
- [3] S. Pierrot, D. Bernardeschi, M.P. Morrisseau-Durand, Y. Manach, V. Couloigner, Dissection of the internal carotid artery following trauma of the soft palate in children, *Ann. Otol. Rhinol. Laryngol.* 115 (5) (2006) 323–329.
- [4] C. Bent, P. Shen, B. Dahlin, K. Coulter, Blunt intraoral trauma resulting in internal carotid artery dissection and infarction in a child, *Pediatr. Emerg. Care* 32 (8) (2016) 534–535.
- [5] M. Lubarsky, R. Helmer, C. Knight, M.E. Mullins, Internal carotid artery dissection following wooden arrow injury to the posterior pharynx. Case report, *J. Neurosurg. Pediatr.* 1 (4) (2008) 334–336.
- [6] J.M. Moriarty, C. Lukas, L. Rossler, C. Thiels, R. Drescher, Carotid artery dissection following a minor household accident in a 10-month-old child, *Ir. J. Med. Sci.* 178 (4) (2009) 535–539.
- [7] A.S. Hengerer, T.R. DeGroot, R.J. Rivers Jr., D.S. Pettee, Internal carotid artery thrombosis following soft palate injuries: a case report and review of 16 cases, *Laryngoscope* 94 (12 Pt 1) (1984) 1571–1575.
- [8] N. Azaraksh, S. Grimes, D.M. Notrica, et al., Blunt cerebrovascular injury in children: underreported or underrecognized?: A multicenter ATOMAC study, *J Trauma Acute Care Surg.* 75 (6) (2013) 1006–1011, discussion 11–2.
- [9] M.U. Mallicote, M.A. Isani, J. Golden, et al., Screening for blunt cerebrovascular injuries in pediatric trauma patients, *J. Pediatr. Surg.* 54 (9) (2019) 1861–1865.
- [10] J.P. Herbert, S.S. Venkataraman, A.H. Turkmani, et al., Pediatric blunt cerebrovascular injury: the McGovern screening score, *J Neurosurg Pediatr.* 21 (6) (2018) 639–649.
- [11] N. Hejrati, F. Ebel, R. Guzman, J. Soleman, Posttraumatic cerebrovascular injuries in children. A systematic review, *Child's Nervous System* 36 (2) (2020) 251–262.
- [12] W.W. Scott, S. Sharp, S.A. Figueroa, et al., Clinical and radiographic outcomes following traumatic grade 3 and 4 carotid artery injuries: a 10-year retrospective analysis from a level 1 trauma center. The parkland carotid and vertebral artery injury survey, *J. Neurosurg.* 122 (3) (2015) 610–615.
- [13] K. Nedeltchev, S. Bickel, M. Arnold, et al., Recanalization of spontaneous carotid artery dissection, *Stroke* 40 (2) (2009) 499–504.
- [14] C. Boßelmann, S. Poli, Sonographic features of carotid artery dissection due to extension of aortic dissection: a case report, *Ultrasound J.* 11 (1) (2019) 32.