

Aspirin provides adequate VTE prophylaxis for patients undergoing hip preservation surgery, including periacetabular osteotomy

Ibrahim Azboy^{1,2*}, Michael M. Kheir¹, Ronald Huang¹ and Javad Parvizi¹

¹Rothman Institute at Thomas, Jefferson University Hospital, Sheridan Building, Suite 1000 125 South 9th Street, Philadelphia, PA 19107, USA and

²Department of Orthopaedics and Traumatology, Istanbul Medipol University, Kavacak Mah. Ekinçiler Cad. No.19 Kavacak Kavşağ - Beykoz 34810, Turkey, Istanbul

*Correspondence to: I. Azboy. E-mail: ibrahimazboy@gmail.com

Submitted 5 July 2017; revised version accepted 16 March 2018

ABSTRACT

There are no clear guidelines regarding optimal venous thromboembolism (VTE) prophylaxis for patients undergoing hip preservation surgery (HPS), in particular pelvic osteotomy, which is considered to be a major orthopaedic procedure. The aim of this study was to determine the efficacy of aspirin for VTE prophylaxis in a large cohort of patients undergoing femoroacetabular osteoplasty (FAO) and periacetabular osteotomy (PAO). This was a retrospective study of prospectively collected data on patients undergoing HPS. A total of 603 patients (643 cases) underwent FAO and 80 patients (87 cases) underwent PAO between 2003 and 2016. The mean age of patients was 34.3 years (range 14.3–68.1 years). The type of VTE prophylaxis administered changed over time with earlier patients receiving warfarin (44 cases), followed by aspirin at 325 mg twice daily (448 cases), and most recently aspirin 81 mg twice daily (238 cases). The complications of symptomatic pulmonary embolism (PE), deep venous thrombosis (DVT) and major bleeding events within 90 days of surgery were documented. There were zero patients that developed major bleeding events or required evacuation of a hematoma. One patient who underwent FAO and received aspirin 325 mg, developed post-operative symptomatic DVT. One patient who underwent PAO and received aspirin 325 mg developed DVT and PE. This study demonstrates that the incidence of VTE following joint preservation procedure is acceptably low. Administration of aspirin to patients undergoing FAO or PAO appears to be adequate in reducing the risk of VTE. Only two patients in this cohort developed VTE following HPS.

INTRODUCTION

Venous thromboembolism (VTE) is considered a serious complication after any surgical procedures including hip preservation surgery (HPS) [1–6]. The optimal VTE prophylaxis regimen after HPS, including femoroacetabular osteoplasty (FAO) and periacetabular osteotomy (PAO), remains unclear [2–5]. VTE prophylaxis recommendations are mainly derived from total joint arthroplasty (TJA) literature [6, 7]. These recommendations have evolved in recent years. The American College of Chest Physicians (ACCP) and the American Academy of Orthopaedic Surgeons (AAOS) accept aspirin (ASA) as an effective modality for VTE prophylaxis following TJA [1, 8]. Patients undergoing HPS surgery are relatively young,

healthy and active, which places them at a lower risk for morbidity post-operatively, including VTE, compared with more elderly patients requiring joint arthroplasty [9]. In addition, recent improvements in perioperative protocols including spinal anesthesia and early mobilization may have reduced the rate of VTE regardless of prophylaxis method [10, 11]. Thus, an evidence-based recommendation for VTE prophylaxis regimen after HPS is warranted alongside these recent advances.

The initial AAOS guideline in 2007 has recommended ASA 325 mg bis in die (BID) following TJA [12]. However, studies originating from both trauma and arthroplasty literature have demonstrated that lower doses of ASA are effective for VTE prevention as higher doses

Table I. Demographic data of patients

	<i>FAO group</i>	<i>PAO group</i>
Number of patient (cases)	603 (643)	80 (87)
Gender male/female	307/296	70/10
Age (years)	34.4 (15.3–68.1)	31.3 (14.3–47.8)
Body mass index (kg/m ²)	26.9 (17.4–41.2)	25.9 (18.9–42.6)
Charlson comorbidity index (%)		
0	89.4	91.2
1	11.4	8.8
3	0.2	

FAO, femoroacetabular osteoplasty; PAO: periacetabular osteotomy.

of ASA [13]. As the gastrointestinal (GI) adverse effects of aspirin is dose dependent, the administration of low dose aspirin is believed to positively impact the rate of GI-related issues [14, 15].

In the early years of our study, we utilized warfarin as the main modality for VTE prevention following joint arthroplasty and HPS. With the publication of the AAOS guidelines for prevention of VTE [8, 12] and later by the ACCP [1], endorsing aspirin as an effective chemoprophylactic drug for VTE following joint arthroplasty, we felt that aspirin could be administered to patients undergoing HPS, including those undergoing PAO. Thus, in 2005 we made a switch from the use of warfarin to aspirin. Initially higher doses of aspirin were being administered to patients undergoing HPS. The dose of aspirin was later lowered.

Currently there are no VTE prophylaxis recommendations for patients undergoing HPS. In this study, we aimed to evaluate the outcomes of different VTE prophylaxis regimens in a large cohort of patients undergoing HPS, including FAO and PAO.

MATERIALS AND METHODS

This retrospective study consists of 645 patients (675 cases) undergoing FAO and 88 patients (96 cases) undergoing PAO between 2003 and 2016. All cases were performed by a single surgeon. Patients were followed prospectively to identify 90-day post-operative complications. The VTE prophylaxis data were available for 603 FAO patients (643 cases) and 80 PAO patients (87 cases) (Table I). The mean age of this cohort was 34.3 years (range 14.3–68.1 years).

The type of VTE prophylaxis administered was based on surgeon preference and mirrored VTE prophylaxis protocols in TJA at our institution (Table II). Earlier patients

Table II. The distribution of venous thromboembolism prophylaxis agent in the cohort

	<i>FAO group</i> (n = 643)	<i>PAO group</i> (n = 87)	<i>Total</i>
325-mg Aspirin	415	33	448
81-mg Aspirin	207	31	238
Warfarin	21	23	44
Total	643	87	730

FAO, femoroacetabular osteoplasty; PAO, periacetabular osteotomy.

received warfarin (44 cases), followed by aspirin at 325 mg twice daily (448 cases), and most recently aspirin 81 mg twice daily (238 cases; see Figs 1 and 2). Cases were not routinely screened for post-operative VTE. The presence of symptomatic pulmonary embolism (PE), deep venous thrombosis (DVT) and major bleeding events within 90 days of surgery were documented.

The indication for FAO was the presence of a cam or pincer deformity, labral tear and the presence of persistent hip pain in the absence of advanced arthritis. The indication for PAO was hip pain in the presence of acetabular dysplasia and the absence of advanced osteoarthritis. All patients received conservative management including non-steroidal anti-inflammatory drugs and/or physical therapy or intra-articular injections prior to surgical intervention. The surgical technique for FAO consisted of a mini-open muscle-sparing anterior approach using the modified Smith–Petersen approach [16]. Bony impingement at the femoral head–neck junction and/or acetabular rim were addressed, and the labral and chondral lesions were treated accordingly [9].

Surgical exposure for PAO was achieved using the muscle-sparing modified Smith–Petersen approach, with a 10- to 12-cm anterior incision and dissection through the plane of the tensor fascia lata and sartorius [17]. The medial aspect of the ilium was exposed, extending to the sciatic notch, and the psoas was retracted medially for exposure of the pubis. The three osteotomies, starting at the anteromedial ischium and progressing to the pubis and ilium, were performed indirectly under fluoroscopy to mobilize and reorient the acetabulum. Fully threaded 4.5 mm cortical screws were used for fixation of the osteotomy fragment. The posterior column was left intact, allowing for immediate rehabilitation without casting or a brace.

As thromboprophylaxis, patients received warfarin, ASA 325 mg BID or ASA 81 mg BID for 4 weeks post-operatively, beginning on the day of surgery along with compression mechanical prophylaxis for the length of the hospital stay. The average hospital stay was 1.6 days (range

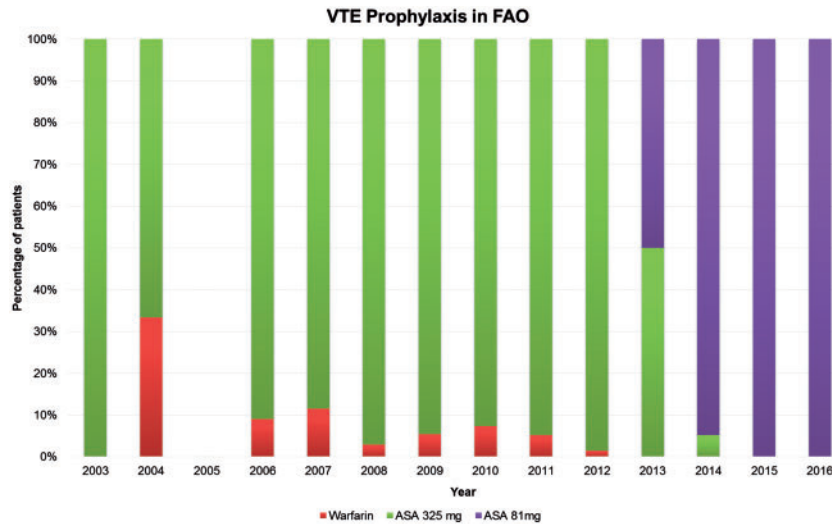


Fig. 1. VTE: Venous thromboembolism, FAO: Femoroacetabular osteoplasty

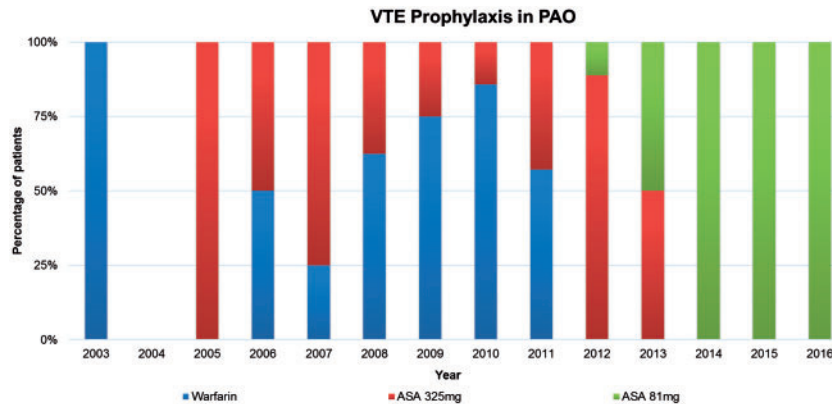


Fig. 2. VTE: Venous thromboembolism, PAO: Periacetabular osteotomy

1–5 days). The post-operative weightbearing protocol for FAO patients was 6 weeks of partial weight bearing. Post-operative partial weightbearing with crutches for 6 weeks was allowed for patients undergoing PAO. All patients were trained to start circumduction exercises at home. Patients were instructed to return for their first post-operative visit between weeks 4 and 6. Return to full activity, including high-impact sports was allowed after 3 months post-operatively.

Post-operative complications occurring within 90 days after surgery were recorded, including symptomatic DVT and PE, GI complications including bleeding or ulceration, acute superficial or deep infection, and mortality. Symptomatic DVTs were detected using lower extremity ultrasound and PEs were diagnosed using chest computed tomography (CT), or ventilation perfusion (V/Q) scans. Patients were not routinely screened for VTE. Lower

extremity ultrasound and chest CT/VQ scans were only performed in cases of suspected symptomatic VTE. GI complications were defined as upper GI bleeding or ulceration confirmed by endoscopy. We used only major bleeding as a clinically relevant complication related to thromboprophylaxis. Major bleeding events included fatal bleeding, bleeding into a critical organ (e.g. retroperitoneal, intracranial, intraocular, or intraspinal), clinically overt bleeding (e.g. GI) or requiring ≥ 3 units of blood transfusion after surgery, and bleeding leading to reoperation [1]. Statistical analyses were performed with SPSS 18.0 statistical software (SPSS Inc., Chicago, IL, USA). A *P* values less than 0.05 was considered as statistically significant.

RESULTS

The overall incidence of a VTE complication 90 days following FAO was one per 643 cases (0.16%). The overall

Table III. The overall 90 day post-operative venous thromboembolism following hip preservation surgery

	<i>Prophylaxis agent</i>	<i>Number of cases</i>	<i>VTE event (n)</i>	<i>VTE rate (%)</i>
FAO group (<i>n</i> =643)	325-mg Aspirin	415	1	0.16
	81-mg Aspirin	207	0	
	Warfarin	21	0	
PAO group (<i>n</i> =87)	325-mg Aspirin	33	1	1.1
	81-mg Aspirin	31	0	
	Warfarin	23	0	
HPS cohort (<i>n</i> =730)		730	2	0.28

VTE, venous thromboembolism; HPS, hip preservation surgery; FAO, femoroacetabular osteoplasty; PAO, periacetabular osteotomy.

Table IV. Comparison of venous thromboembolism events between the prophylaxis agents

	<i>325-mg Aspirin</i>	<i>81-mg Aspirin</i>	<i>Warfarin</i>	<i>P value</i>
FAO group ^a	1 (415)	0 (207)	0 (21)	0.667 ^b and 0.954 ^c
PAO group ^a	1 (33)	0 (31)	0 (23)	0.516 ^b and 0.589 ^c
HPS cohort ^a	2 (448)	0 (238)	0 (44)	0.653 ^b and 0.911 ^c

^aThe values are given as the number of VTE event, with the number of cases in parentheses.

^bA 325-mg Aspirin versus 81-mg Aspirin.

^cA 325-mg Aspirin versus Warfarin.

VTE, venous thromboembolism; HPS, hip preservation surgery; FAO, femoroacetabular osteoplasty; PAO, periacetabular osteotomy.

incidence of VTE complication after PAO was one per 87 cases (1.1%) (Table III). No major bleeding events developed in patient undergoing FAO or PAO.

There was no difference between ASA 325 mg and ASA 81 mg in regards to the VTE rate after HPS ($P = 0.653$). Also, there was no difference between ASA 325 mg and warfarin in regard to VTE rate after HPS (0.911). No difference in VTE rate was observed between ASA 325 mg and ASA 81 mg after FAO ($P = 0.667$). Furthermore, no difference in VTE rate was observed between ASA 325 mg and ASA 81 mg after PAO ($P = 0.516$) (Table IV).

One 42-year-old female patient developed a DVT and PE after PAO. The patient was discharged on aspirin 325 mg BID. She developed episodic transient stabbing pain in the popliteal fossa and intermittent episodes of chest pain, palpitation, diaphoresis and shortness of breath 5 days post-operatively. Her symptoms progressed, and she was admitted to the emergency room on post-operative day 17. A chest X-ray was obtained which demonstrated a prominent right pulmonary trunk. A CT scan of the thorax was obtained which demonstrated a filling defect in the anterior and superior branches of the right upper lobe pulmonary artery, consistent with PE. Ultrasound of the leg

was positive for acute thrombus of the left posterior tibial and peroneal veins. She received intravenous heparin on admission and was transitioned to injectable low-molecular weight heparin. The patient was discharged home on enoxaparin 80 mg BID for 5 days, and warfarin 10 mg daily. The patient received warfarin for 3 months with resolution of symptoms. She was doing well at her two year follow-up with no further complications.

One 44-year-old male patient had symptomatic DVT after an FAO. The patient was discharged on aspirin 325 mg BID. He developed pain and swelling in his lower extremity. The DVT was diagnosed with lower extremity ultrasound and the patient was treated with warfarin for 3 months with resolution of symptoms and no further complications.

DISCUSSION

HPS is a popular and effective surgical procedure for the management of young patients with minimal arthritis and symptomatic hip pathology [18]. The most effective mode of prevention of VTE following HPS remains unknown with little published on this subject matter [2–5, 9]. Recommendations for VTE prophylaxis are mainly

based on the TJA literature [1, 6–8, 12, 13]. This is important as the demographics in the HPS population are different from that of the TJA population, with patients undergoing HPS more likely to be younger, more active, and healthier [9].

Zaltz *et al.* analysed the type of prophylaxis and incidence of clinically symptomatic VTE after utilizing different methods of prophylaxis for a total of 1067 periacetabular osteotomies [2]. They reported an overall incidence of VTE to be 0.94%. Polkowski *et al.* studied the frequency of thromboembolic disease in adult patients undergoing PAO and receiving aspirin twice daily as well as mechanical prophylaxis by assessing an ultrasound at 1 week post-operatively [3]. They found a 1.3% rate of DVT on routine screening of 136 hips, with a mean patient age of 30 years (range 18–60 years). They concluded that routine post-operative screening did not detect any patients with an asymptomatic DVT. Bryan *et al.* reported a thromboembolic disease rate of 2 out of 75 (2.67%) patients receiving ASA 325 mg twice daily as well as mechanical prophylaxis after undergoing a Bernese PAO [11]. Another study by Thawrani *et al.* reported on 83 PAO cases ($n = 76$ patients) in whom no prophylaxis was administered and found no cases of symptomatic VTE in that small cohort [4]. The symptomatic VTE rate in our study is 0.16% and 1.1% after FAO and PAO surgery, respectively, consistent with rates reported previously in the literature.

Aspirin has been shown to be a safe and effective drug for VTE prophylaxis following TJA, and is supported by the most recent AAOS and ACCP guidelines [6, 19, 20]. In recent studies, aspirin, when compared with more potent anticoagulants, was found to reduce the rate of hematoma formation and subsequent wound complications, including infection, while providing similar efficacy in prevention of VTE [19–22]. Similarly, in our study, there was no significant difference in symptomatic VTE rates following HPS in patients receiving warfarin, ASA 325 mg or ASA 81 mg.

This study has several limitations. First, although the number of cases are considerable for ASA 325 mg ($n = 448$) and ASA 81 mg ($n = 238$), the sample size is smaller for those that received warfarin ($n = 44$). Therefore, this study was underpowered to detect a difference between VTE rates in patients receiving warfarin compared with aspirin. However, to our knowledge this is the largest cohort comparing VTE prophylaxis using different modalities in patients undergoing HPS. Second, a higher dose of ASA has been thought to increase the risk of GI complications [15]. However, in our study, no major GI bleeding or ulcer complications were recorded. Minor

gastrointestinal problems were not evaluated in this study and may be better evaluated in a prospective randomized study. Lastly, a confounding variable in our study is that recent advances in perioperative protocols including the use of spinal anesthesia and early mobilization protocols may have reduced the rate of VTE events regardless of the prophylaxis regimen [10, 11]; this is difficult to account for due to the retrospective nature of the study, however we still demonstrate a very low event rate of VTE in this population (only two events in this study).

In conclusion, this study suggests that aspirin is a safe and an effective modality in minimizing the risk of VTE in patients undergoing HPS including PAO.

CONFLICT OF INTEREST STATEMENT

None declared.

REFERENCES

1. Falck-Ytter Y, Francis CW, Johanson NA *et al.* Prevention of VTE in orthopedic surgery patients: antithrombotic therapy and prevention of thrombosis: American College of Chest Physicians evidence-based clinical practice guidelines. *CHEST* 2012; **141**: e278S–325S.
2. Zaltz I, Beaulé P, Clohisy JC *et al.* Incidence of deep vein thrombosis and pulmonary embolus following periacetabular osteotomy. *J Bone Joint Surg Am* 2011; **93**: 62–5.
3. Polkowski GG, Duncan S, Bloemke A *et al.* Screening for deep vein thrombosis after periacetabular osteotomy in adult patients: is it necessary? *Clin Orthop Relat Res* 2014; **472**: 2500–5.
4. Thawrani D, Sucato D, Podeszwa D, DeLaRocha A. Complications associated with the Bernese periacetabular osteotomy for hip dysplasia in adolescents. *J Bone Joint Surg Am* 2010; **92**: 1707–14.
5. Tischler EH, Ponzio DY, Diaz-Ledezma C, Parvizi J. Prevention of venous thromboembolic events following femoroacetabular osteoplasty: aspirin is enough for most. *Hip Int* 2014; **24**: 77–80.
6. Huang RC, Parvizi J, Hozack WJ *et al.* Aspirin is as effective as and safer than Warfarin for patients at higher risk of venous thromboembolism undergoing total joint arthroplasty. *J Arthroplasty* 2016; **31**: 83–6.
7. Radzak KN, Wages JJ, Hall KE, Nakasone CK. Rate of Transfusions after total knee arthroplasty in patients receiving lovenox or high-dose aspirin. *J Arthroplasty* 2016; **1**: 2447–51.
8. Mont MA, Jacobs JJ. AAOS clinical practice guideline: preventing venous thromboembolic disease in patients undergoing elective hip and knee arthroplasty. *J Am Acad Orthop Surg* 2011; **19**: 777–8.
9. Cohen SB, Huang R, Ciccotti MG *et al.* Treatment of femoroacetabular impingement in athletes using a mini-direct anterior approach. *Am J Sports Med* 2012; **40**: 1620–7.
10. Atwal NS, Bedi G, Lankester BJ *et al.* Management of blood loss in periacetabular osteotomy. *Hip Int* 2008; **18**: 95–100.

11. Bryan AJ, Sanders TL, Trousdale RT, Sierra RJ. Intravenous tranexamic acid decreases allogeneic transfusion requirements in periacetabular osteotomy. *Orthopedics* 2016; **39**: 44–8.
12. Johanson NA, Lachiewicz PF, Lieberman JR *et al.* Prevention of symptomatic pulmonary embolism in patients undergoing total hip or knee arthroplasty. *J Am Acad Orthop Surg* 2009; **17**: 183–96.
13. Prevention of pulmonary embolism and deep vein thrombosis with low dose aspirin: pulmonary Embolism Prevention (PEP) trial. *Lancet* 2000; **355**: 1295–302.
14. de Abajo FJ, Garcia Rodriguez LA. Risk of upper gastrointestinal bleeding and perforation associated with low-dose aspirin as plain and enteric-coated formulations. *BMC Clin Pharmacol* 2001; **1**: 1.
15. Dutch TIA, Trial Study Group. Van Gjin J, Algra A, Kapelle J *et al.* A comparison of two doses of aspirin (30 mg vs. 283 mg a day) in patients after a transient ischemic attack or minor ischemic stroke. *N Engl J Med* 1991; **325**: 1261–6.
16. Bender B, Nogler M, Hozack WJ. Direct anterior approach for total hip arthroplasty. *Orthop Clin North Am* 2009; **40**: 321–8.
17. Troelsen A, Elmengaard B, Soballe K. A new minimally invasive transarticular approach for periacetabular osteotomy. *J Bone Joint Surg Am* 2008; **90**: 493–8.
18. Leunig M, Beaulé PE, Ganz R. The concept of femoroacetabular impingement: current status and future perspectives. *Clin Orthop Relat Res* 2009; **467**: 616–22.
19. Mostafavi Tabatabaee R, Rasouli MR, Maltenfort MG *et al.* Cost-effective prophylaxis against venous thromboembolism after total joint arthroplasty: warfarin versus aspirin. *J Arthroplasty* 2015; **30**: 159–64.
20. Ogonda L, Hill J, Doran E *et al.* Aspirin for thromboprophylaxis after primary lower limb arthroplasty: early thromboembolic events and 90 day mortality in 11, 459 patients. *Bone Joint J* 2016; **98-B**: 341–8.
21. An VV, Phan K, Levy YD, Bruce WJ. Aspirin as thromboprophylaxis in hip and knee arthroplasty: a systematic review and meta-analysis. *J Arthroplasty* 2016; **31**: 2608–16.
22. Huang R, Buckley PS, Scott B *et al.* Administration of aspirin as a prophylaxis agent against venous thromboembolism results in lower incidence of periprosthetic joint infection. *J Arthroplasty* 2015; **30**: 39–41.