

Protective effect of crocin on liver toxicity induced by morphine

Mohammad Reza Salahshoor¹, Mojtaba khashiadeh², Shiva Roshankhah¹,
Seyran Kakabaraei³, and Cyrus Jalili^{1,*}

¹Department of Anatomical Sciences, Medical School, Kermanshah University of Medical Sciences, Kermanshah, I.R. Iran.

²Students research committee, Kermanshah university of Medical Sciences. Daneshgah Ave, Taghbostan, Kermanshah, I.R. Iran.

³Anatomy Department, Kermanshah University of Medical Sciences, Kermanshah, I.R. Iran.

Abstract

Crocin, a bioactive molecule of saffron can be purely isolated from the saffron extract. It has different pharmacological effects such as antioxidant and anticancer activities. Morphine is an opioid analgesic drug. It is mainly metabolized in liver and causes devastating effects. It can increase the generation of free radicals. This study was designed to evaluate the protective role of crocin against morphine-induced toxicity in the mouse liver. In this study, various doses of crocin (12.5, 25 and 50 mg/kg) and crocin plus morphine were administered interaperitoneally once daily to 48 male mice for 20 consecutive days. These mice were randomly assigned to 8 groups of 6 each. The liver weight and histology, aspartate amino transferase, alanine aminotransferase, alkaline phosphatase (ALP) and serum nitric oxide levels were studied. The results indicated that morphine administration significantly decreased liver weight and increased the mean diameter of hepatocyte, central hepatic vein diameters, liver enzyme levels, and blood serum nitric oxide level compared to saline group ($P<0.05$). However, crocin administration significantly boosted liver weight and decreased the mean diameter of hepatocyte, central hepatic vein, liver enzymes and nitric oxide levels in all groups compared to the group received morphine alone ($P<0.05$). It seems that crocin administration could protect the liver damage induced by morphine. The antioxidant effect of crocin may be a major reason for its positive impact on liver parameters.

Keywords: Crocin; Liver toxicity; Morphine; Mice

INTRODUCTION

Medicinal plants are used throughout the world either for the health care, treatment or preventing a variety of diseases (1). Crocin, a bioactive molecule of saffron can be isolated and crystallized from saffron extract as a pure entity (2). Crocin, has attracted scientist attention and found a special place in pharmaceutical science due to its anti-tumor activity (3). Crocin has shown various pharmacological activities such as antioxidant, anticancer, radical scavenging, and genoprotective (4,5). At pharmacological and high doses, crocin did not exhibit marked damages to major organs of body and no mortality was seen by crocin in mice (6). Opium consumption in young people has been increased. Opioids have oxidative properties

and therefore increase apoptosis in many cells by producing free radicals (7). Morphine is an opioid analgesic drug which is the main psychoactive chemical in opium. Morphine has a high potential for addiction, tolerance, and psychological dependence (8). Morphine increases apoptosis in neurons, glial, hepatocytes, cells of immune systems, and epithelial cells (9). Morphine can increase free radicals generation by acting as a lipid peroxidation. Lipid peroxidation is increased following blocking of anti-oxidant enzyme. This process leads to free radical formation or reactive oxygen species (ROS). These free radicals or ROS cause damage to the cell membrane and DNA fragmentation (10). Liver is considered as a major site of morphine biotransformation where morphine exerts a number of adverse physiological effects (11).

*Corresponding author: C. Jalili
Tel: 0098 9188317220, Fax: 0098 83 34276477
Email: cjalili@yahoo.com

Morphine is rapidly metabolized in the liver which induces three major adverse effects on the liver: direct or indirect toxic effects, immunological effects, and oncogenic effects (12). Morphine causes liver cell injury and exerts genotoxic effect in rat liver (13). It has been recognized that morphine results in oxidative stress by inducing the generation of ROS which in turn are capable of initiating and promoting oxidative damage in the form of lipid peroxidation (14). Lipid peroxidation is known to cause cellular injury by inactivation of membrane enzymes and receptors (15). A major pathway of morphine metabolism is co-oxidation to cotinine, which is catalyzed by CYP2A6 in liver (16). Therefore, the present study is conducted to analyze protective effect of crocin on damage induced by morphine by measuring liver parameters in male mice.

MATERIALS AND METHODS

Chemicals

In this experimental study, crocin (digentiobiosyl 8, 8'-diapocarotene-8, 8'-oate; C₄₄H₆₄O₂₄) powder and morphine was supplied by Merk company (Germany). They were dissolved and diluted in saline (0.9%) for administration (17).

Experimental animals

In this study, forty eight Balb/c male mice purchased from Tehran Razi Institute weighting 25 ± 2.2 g were used. All the animals were housed in plastic cages in a room at 22 ± 2 °C, under controlled environmental conditions, 12/12 h light/dark cycle having free access to water and food. All experimentation was conducted in conformity with ethical and humane principles of research and approval of Ethics Committee of Kermanshah University of Medical Sciences (18).

Experimental design and treatments

Mice were randomly divided into 8 groups of 6 each. Group 1, saline group, received 1 ml normal saline daily. Group 2, morphine group, was treated with morphine while groups 3 to 5 (crocin groups) were given 12.5, 25, 50 mg/kg

crocin respectively; Groups 6 to 8, crocin+morphine groups), were treated with fixed dose of morphine plus 12.5, 25 and 50 mg/kg crocin. In group 2, morphine was injected intraperitoneally at 20 mg/kg once a day for the first 5 days, twice a day for the next 5 days and 30 mg /kg twice per day for the last 10 days of the experiment (19). In groups 3 to 5 crocin was injected interaperitoneally once a day for 20 consecutive days (20). Mice in groups 6-8, received crocin daily for 20 consecutive days and morphine in the same manner as conducted in groups 2 (19,20). The same volume of saline was injected in group 1.

Collection of blood serum and liver weight

All animals were anaesthetized with ketamine (75 mg/kg). Midline laparotomy was performed. Blood samples were drawn by cardiac puncture. Serum was separated and stored at -80 °C for nitric oxide measurement. Livers were removed and weighed on a microbalance sensitive to 0.001 mg (Precisa 125A, Switzerland) (21).

Morphometric measurements

For each hepatocyte, the total cellular area was measured. The outline of each hepatocyte was measured after taking an image with a 40× objective. The longest and shortest axis were measured in the drawing of each hepatocyte in order to estimate the mean diameter (mean axis). At least 50 hepatocytes from each zone (total 100) were measured in each liver. A separate measurement for central hepatic vein was performed, using the same methodology (22).

Histopatological examinations

The specimens (lower one centimeter long part of the right lobe of the liver) were fixed in 10% formalin at room temperature for 72 h. After fixing the tissue, it was thoroughly washed under running water and standard dehydration (dehydrated in ascending concentration ethanol, cleared in xylene). Also, paraffin-wax embedding procedures were used. Sections of 5 mm were cut in a microtome (Leica RM 2125, Leica Microsystems Nussloch GmbH, Germany) and

adhered to glass slides with polylysine. Hematoxylin and eosin-stained slides were prepared by standard methods and were evaluated by light microscopy (Olympus BX-51T-32E01 research microscope connected to a DP12 Camera with 3.34-million pixel resolution and Olysia Bio software (Olympus Optical Co. LTD, Tokyo-Japan) (23).

Griess assay

Nitric oxide was measured based on Griess colorimetric assay. Accordingly, N-1-naphthylethylenediamine (NEED) solution sulfonamide solutions, and nitrite standards were purchased from Sigma (USA) and prepared. To measure nitrite concentration in serum, serum samples were defrosted, 100 μ l of the serum sample was deproteinized by zinc sulfate and transferred to the wells. 100 μ l chloride vanadium, 50 μ l sulfonamide, and 50 μ l NEED solutions were added afterwards. The samples were incubated at 30 °C in darkness. Samples' optical density (OD) was measured by enzyme linked immuno-sorbent assay (ELISA) reader (Hyperion, Germany) at 540 nm (24).

Liver function tests

Finally liver was minced and homogenized (10 % w/ v) in ice-cold 0.1 M sodium phosphate buffer at pH 7.4. The homogenate was centrifuged twice at 10,000 rpm for 15-20

min at 4 °C. The resultant supernatant was used for various biochemical assays. The activities of aspartate aminotransferase (AST) and alanine aminotransferase (ALT) were assayed by the method of Reitman and coworkers (25). Activities of alkaline phosphatase (ALP) were determined according to the protocol described in laboratory practical manual (26).

Statistical calculations

Statistical analyses were performed by analysis of variance (ANOVA) followed by LSD post-hoc test to determine statistical significance between different groups using SPSS software package 16.0. Data was presented as mean \pm SEM and $P < 0.05$ was considered statistically significant.

RESULTS

Liver weight

In the present study, morphine administration caused a significant decrease in the liver weight of the mice compared to the saline group ($P < 0.05$). Moreover, liver weight was significantly increased in treated animals with crocin and crocin plus morphine in all doses in comparison with morphine group ($P < 0.05$) (Fig. 1).

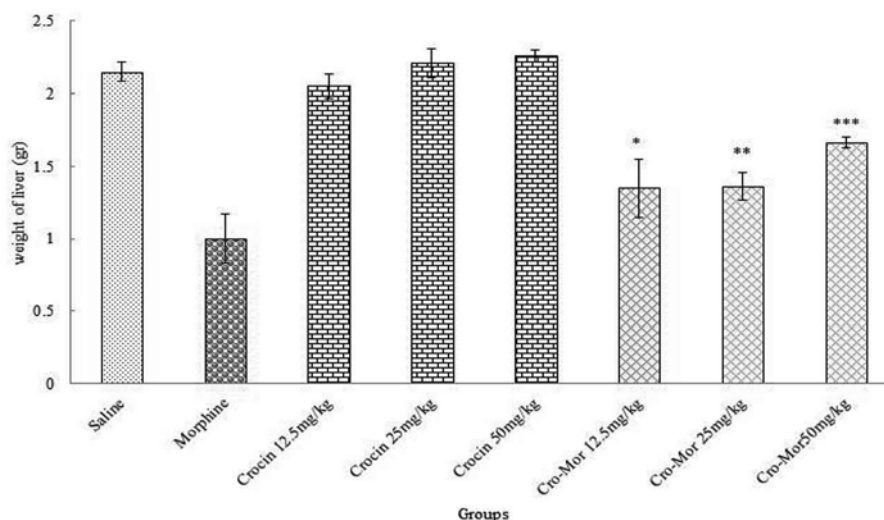


Fig. 1. Effects of crocin, morphine and crocin plus morphine on the liver weight of various groups of Balb/c male mice. *Significant increase in crocin+morphine group (12.5 mg/kg) compared to morphine group ($P < 0.05$). **Significant increase in crocin+morphine group (25 mg/kg) compared to morphine group ($P < 0.05$). ***Significant increase in crocin+morphine group (50 mg/kg) compared to morphine group ($P < 0.05$)

Morphometric measurements

The mean diameter of hepatocytes and central hepatic vein, were significantly increased in morphine group in comparison with saline group ($P<0.05$).

Further, crocin and crocin plus morphine caused a significant decrease in the mean diameter of hepatocytes and central hepatic vein in all treated groups in comparison with group treated with morphine ($P<0.05$) (Figs. 2 and 3).

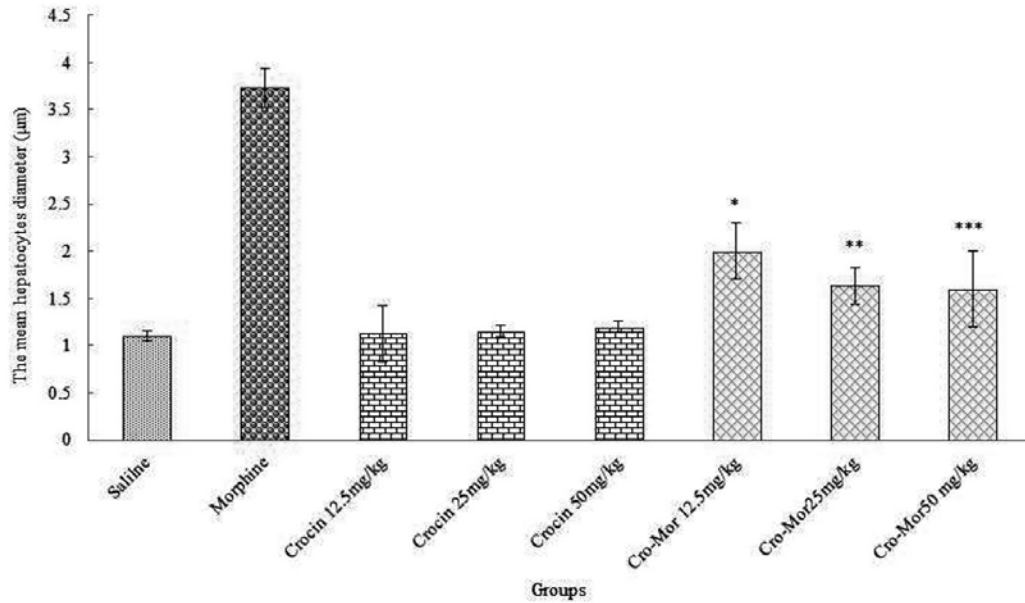


Fig. 2. Effects of crocin, morphine and crocin plus morphine on the mean hepatocytes diameter various groups of Balb/c male mice. *Significant decrease in crocin+morphine group (12.5 mg/kg) compared to morphine group ($P<0.05$). **Significant decrease in crocin+morphine group (25 mg/kg) compared to morphine group ($P<0.05$). ***Significant decrease in crocin+morphine group (50 mg/kg) compared to morphine group ($P<0.05$).

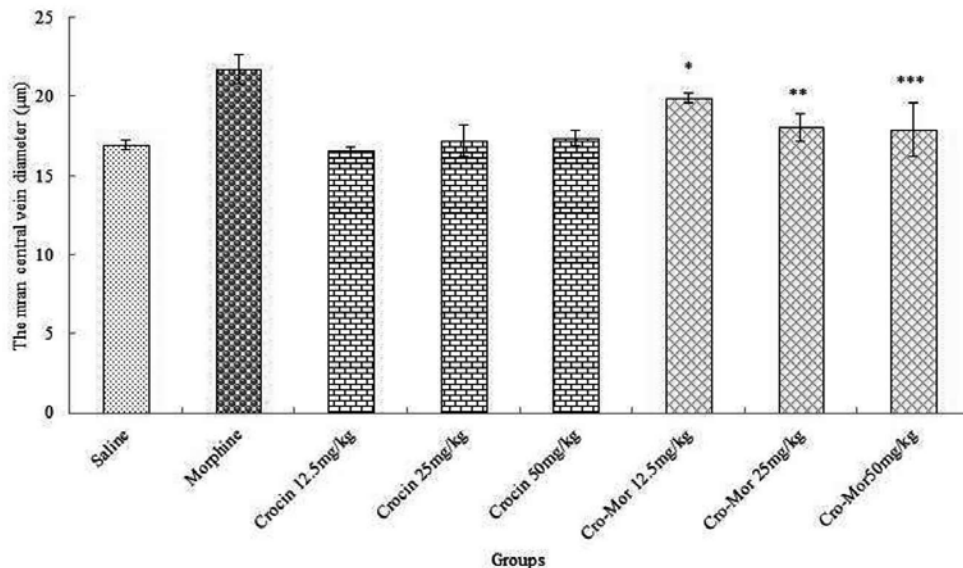


Fig. 3. Effects of crocin, morphine and crocin plus morphine on the mean central hepatic vein diameter of various groups of Balb/c male mice. *Significant decrease of the mean central hepatic vein diameter in crocin+morphine group (12.5 mg/kg) compared to morphine group ($P<0.05$). **Significant decrease in crocin+morphine group (25 mg/kg) compared to morphine group ($P<0.05$). ***Significant decrease in crocin+morphine group (50 mg/kg) compared to morphine group ($P<0.05$).

Histopathological observations

Examination of hematoxylin and eosin-stained sections of liver in the saline group showed normal liver structure. After 20 days treatment with morphine, the liver section appeared with variable changes and marked injury. These changes were evidenced by disruption of tissue architecture, more distributed Kupffer cells around central vein and enlargement of central hepatic vein compared to saline stage. After 20 days treatment with crocin (50 mg/kg), liver section indicated normal histology and architecture. After treatment with morphine plus crocin (50 mg/kg) it was recognized that crocin reduced liver injury caused by morphine toxicity and largely suppressed lymphocytic infiltration (Fig. 4).

Nitric oxide

The mean nitric oxide levels in blood serum increased significantly in morphine group compared to saline group ($P<0.05$). Also, serum nitric oxide levels decreased significantly in crocin and crocin+morphine groups compared to morphine group (Fig. 5).

Biochemical analysis

Morphine caused a significant increase in ALT, AST and ALP enzymes compared to saline group ($P<0.05$). In addition, the mean ALT, AST and ALP enzymes decreased significantly in crocin and crocin+morphine groups compared to morphine group ($P<0.05$) (Fig. 6).

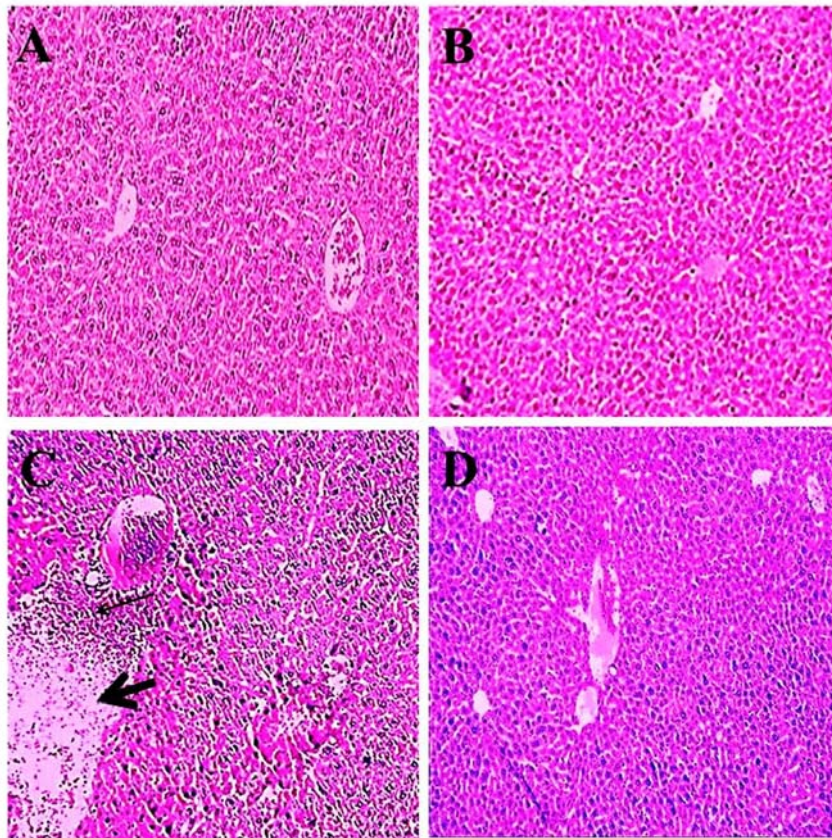


Fig. 4. Histological changes of liver hematoxylin-eosin staining (magnification 100 \times). A; Micrograph of liver section of mice in saline group showing a normal liver structure. B; Micrograph of liver section treated with crocin (50 mg/kg) showing a normal liver structure. C; Micrograph of liver section treated with morphine showing more distributed Kupffer cells around central vein (thin arrow) and enlargement of central hepatic vein (thick arrow). D; Micrograph of liver section treated with crocin plus morphine showing normal liver structure.

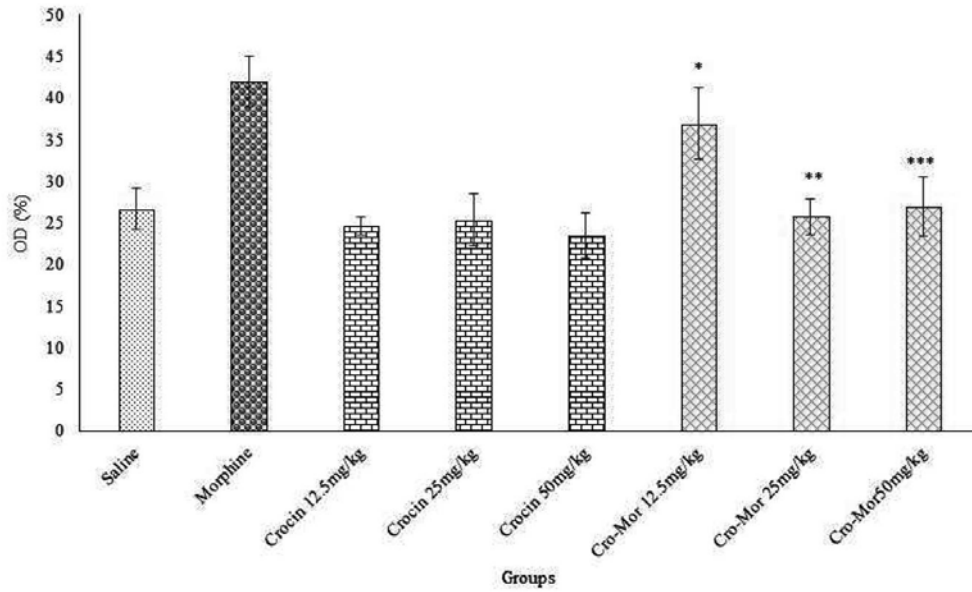


Fig. 5. Effects of crocin, morphine and crocin plus morphine on the mean nitric oxide levels of various groups of Balb/c male mice. *Significant decrease of nitric oxide in group of crocin+morphine group (12.5 mg/kg) compared to morphine group ($P<0.05$). **Significant decrease in crocin+morphine group (25 mg/kg) compared to morphine group ($P<0.05$). ***Significant decrease in crocin+morphine group (50 mg/kg) administration compared to morphine group ($P<0.05$).

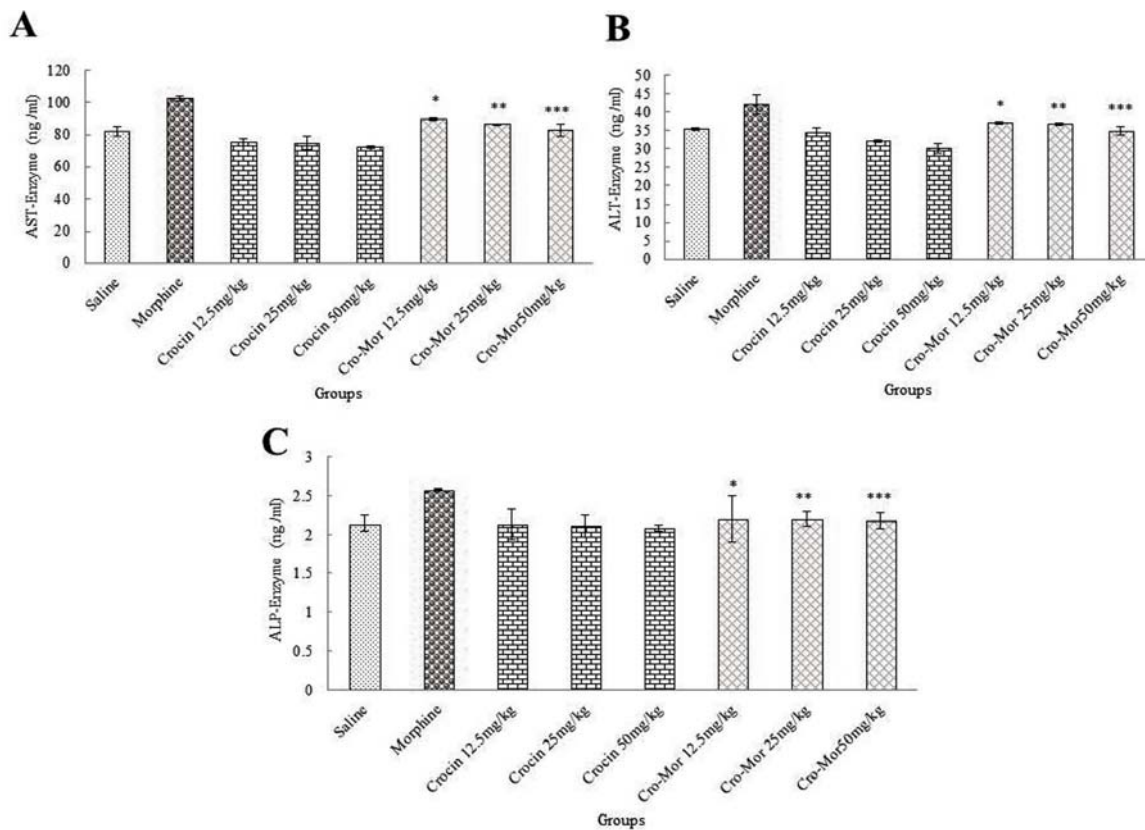


Fig. 6. Effect of morphine, crocin and crocin plus morphine administration on liver enzymes of various groups of Balb/c male mice. A; AST enzyme, B; ALT enzyme and C; ALD enzyme. *Significant decrease in crocin+morphine group (12.5 mg/kg) compared to morphine groups ($P<0.05$). **Significant decrease in crocin+morphine group (25 mg/kg) compared to morphine groups ($P<0.05$). ***Significant decrease in crocin+morphine group (50 mg/kg) administration compared to morphine groups ($P<0.05$).

DISCUSSION

In the current study, the changes occurred in liver parenchyma following morphine administration and the protective effects of crocin on these alterations were investigated. Liver is the primary site for transformation of morphine and other opioids, and metabolism of morphine in liver reduces hepatic glutathione (27).

Results obtained from analysis of liver enzymes indicated a significant rise in ALT, AST and ALP enzymes in morphine-treated group compared with saline group, which was stabilized to a large extent by crocin treatment. The increasing activity of enzymatic markers of liver function is an indicative of liver cell impairments (28). Necrosis or impairment of the liver cell membrane would release the enzymes into the blood circulation (29). Morphine increases dopamine and xanthine oxidation and, consequently, can increase ROS. Morphine has also been reported to metabolize free radicals and significantly increase lipid peroxidation in morphine consumers (30,31). The antioxidant property of crocin seems to be responsible for its different pharmacological effects. Therefore, it seems that crocin, due to its antioxidant properties, could protect the liver cells from the damage caused by oxidative stress (32,33).

Crocine has various pharmacologic effects including preventing tumor cell proliferation and preserving the nervous system and hepatocytes. The findings of the present study were in line with those of El-Maraghy and colleagues who showed that crocin has protective effects against biochemical changes resulting from the effect of high doses of iron in liver cells (34). According to the findings of the current research, the reduced weight of liver can be linked to the damage of liver cells and dysfunctions in the real metabolism of the mice due to morphine administration (35). Todaka and coworkers showed morphine caused a decrease in the liver weight in human, which was in agreement with the results of present study (36). The increased appetite due to crocin can be considered as a factor that neutralizes the effects of morphine on weight reduction in the current study (37).

This is in agreement with the results of the study conducted by Razavi and colleagues, who reported that crocin increased body weight (38). The results of this study indicated the increasing diameter of hepatocytes and the central vein of liver due to morphine administration in the study groups. Apparently, the change in the size of hepatic cells and liver's central vein can be the result of an increase in the metabolic activity of cells to excrete toxin from the body during detoxification process (39). The free radicals induced by morphine metabolism caused lipid peroxidation, reaction with DNA and membrane proteins and consequently cell damage through various pathways (40). Antioxidant compounds such as crocin may exert inhibitory effect on cytochrome P450, preventing further morphine metabolism and reducing the production of free radicals, consequently (41). The findings of the present study are in line with the results of the study carried out by Salahshoor and coworkers in which they showed curcumin administration resulted in the increasing diameter of hepatocytes (42). In the present research, the findings obtained from the measurement of serum nitric oxide levels revealed a significant increase between the group receiving morphine and saline group while crocin administration decreased nitric oxide levels.

The results of this study revealed destructive changes of morphine in liver tissue, increase central vein diameter and accumulation of Kupffer cells (macrophages) around the central vein. Macrophages are activated in response to tissue damage and release toxic mediators such as tumor necrosis factor alpha (TNF- α), interleukin-1 and nitric acid. Accumulation of these cells and secretion of toxic mediators in non-necrotic regions play a major role in liver toxicity induction and can induce liver necrosis (43,44). Production of free radicals and oxidative stress can be the most important reasons for liver cells' death (45). Results of current study were in agreement with findings of Mohajeri and colleagues showing that treatment with crocin significantly reduced serum markers of liver functions (46). Administration of crocin extract to the groups receiving morphine

caused a significant reduction in degenerative changes and necrotic effects, which confirmed biochemical results. The results obtained from crocin administration seem to be associated with antioxidant properties and reduced oxidative stress of this substance (47).

The hydroxyl radicals produced by nitric oxide and superoxidation interfere with pathogenesis process and liver toxicity (48). Morphine causes an increase in nitric oxide production by regulating the intracellular calcium through activation of calcium-calmodulin-dependent nitric oxide synthase and increasing expression of nitric oxide via naloxone-sensitive receptors (49). It seems that antioxidants, including crocin are able to reduce nitric oxide production (50). The results of the study conducted by Jalili and colleagues showed that *P. Crispum* administration significantly increased serum nitric oxide (24) which is in contrast with the findings obtained in this study.

CONCLUSION

The present study supported contention that crocin can protect some of liver damages in mice. The results also suggest protective potential of crocin against toxic effects of morphine in morphine-treated male mice. Therefore, crocin could protect liver in individuals who are exposed to or consumed morphine. Antioxidant effect of crocin may be a major reason for its positive impact on liver parameters. However, further studies are required for a better understanding of interaction between crocin and morphine mechanism leading to preventing liver damage.

ACKNOWLEDGMENTS

The authors gratefully acknowledge the Research Council of Kermanshah University of Medical Sciences (Grant Number: 94332) for the financial support of this project. This work was performed in partial fulfillment of the requirements for MD degree of Mojtaba Khashiadeh at faculty of medicine in Kermanshah University of Medical Sciences, Kermanshah, I.R. Iran.

REFERENCES

1. De Medeiros PM, Pinto BLS, Do Nascimento VT. Can organoleptic properties explain the differential use of medicinal plants? Evidence from North eastern Brazil. *J. Ethnopharmacol.* 2015;159:43-48.
2. Altinoz E, Oner Z, Elbe H, Cigremis Y, Turkoz Y. Protective effects of saffron (its active constituent, crocin) on nephropathy in streptozotocin-induced diabetic rats. *Hum Exp Toxicol.* 2015;34:127-134.
3. Amin A, Bajbouj K, Koch A, Gandesiri M, Schneider-Stock R. Defective autophagosome formation in p53-null colorectal cancer reinforces crocin-induced apoptosis. *Int J Mol Sci.* 2015;16:1544-1561.
4. Hosseinzadeh H, Shamsaie F, Mehri S. Antioxidant activity of aqueous and ethanolic extracts of *Crocus sativus* L. stigma and its bioactive constituent, Crocin and Safranal. *Pharmacog Mag.* 2009;5:419-424.
5. Hosseinzadeh H, Abootorabi A, Sadeghnia HR. Protective effect of *Crocus sativus* stigma extract and crocin (trans-crocin 4) on methyl methanesulfonate-induced DNA damage in mice organs. *DNA Cell Biol.* 2008;27:657-664.
6. Hosseinzadeh H, Shariaty MV, Sameni AK, Vahabzadeh M. Acute and sub-acute toxicity of crocin, a constituent of *Crocus sativus* L. (saffron), in mice and rats. *Pharmacologyonline.* 2010;2:943-951.
7. Seiri L, Mokri A, Dezhakam H, Noroozi A. Using tincture of opium for treatment of opiate abusers in Iran. *Drug Alcohol Depend.* 2014;140:e200.
8. Stoops WW, Hatton KW, Lofwall MR, Nuzzo PA, Walsh SL. Intravenous oxycodone, hydrocodone, and morphine in recreational opioid users: abuse potential and relative potencies. *Psychopharmacology (Berl).* 2010;212:193-203.
9. Asadi E, Shabani R, Ghafari S, Golalipour MJ. Preventing effect of vitamin E on oocytes apoptosis in morphine-treated mice. *Int J Morphol.* 2013;31:533-538.
10. Lan X, Rai P, Chandel N, Cheng K, Lederman R, Saleem MA, *et al.* Morphine induces albuminuria by compromising podocyte integrity. *PloS one.* 2013;8:e55748.
11. Mohammadi N, Bayati V, Nejatbakhsh R, Heidari MH, Dadpay M, Tavassol A. Effect of oral morphine on the liver of Wistar rat fetuses in the second week of development: a histopathological study. *RJMS.* 2015;21:1-9.
12. Mikus G, Klimas R. Relative contribution of morphine and morphine-6-glucuronide to the analgesic effect after morphine administration. *Br J Anaesth.* 2015;114:1007.
13. Samarghandian S, AfshariR, Farkhondeh T. Effect of long-term treatment of morphine on enzymes, oxidative stress indices and antioxidant status in male rat liver. *Int J Clin Exp Med.* 2014;7:1449-1453.
14. Eslami H, Sharifi AM. Effect of carnosine on the prevention of high-dose morphine-induced apoptosis of PC12 Cells. *J Med Bio.* 2014;3:175-178.

15. Liu Y, Yang L, Tao K, Vizcaychipi M, Lloyd D, Sun X, *et al.* Protective effects of hydrogen enriched saline on liver ischemia reperfusion injury by reducing oxidative stress and HMGB1 release. *BMC Gastroenterol.* 2014;14:12.
16. Chau N, Elliot DJ, Lewis BC, Burns K, Johnston MR, Mackenzie PI, *et al.* Morphine glucuronidation and glucosidation represent complementary metabolic pathways that are both catalyzed by UDP-glucuronosyl transferase 2B7: kinetic, inhibition, and molecular modeling studies. *J Pharm Exp Ther.* 2014;349:126-137.
17. Šlamberová R, Riley MA, Vathy I. Cross-generational effect of prenatal morphine exposure on neurobehavioral development of rat pups. *Physiol Res.* 2005;54:655-660.
18. Jalili C, Salahshoor MR, Pourmotabbed A, Moradi S, Motaghi M, Roshankhah SH, *et al.* The Effects of Aqueous Extract of *Boswellia Serrata* on Hippocampal Region CA1 and learning deficit in kindled Rats. *Res Pharm Sci.* 2014;9:351-358.
19. Zhang YT, Zheng QS, Pan J, Zheng RL. Oxidative damage of biomolecules in mouse liver induced by morphine and protected by antioxidants. *Basic Clin Pharma Toxicol.* 2004;95:53-58.
20. Lari P, Abnous K, Imenshahidi M, Rashedinia M, Razavi M, Hosseinzadeh H. Evaluation of diazinon-induced hepatotoxicity and protective effects of crocin. *Toxicol. Ind. Health* 2015;31: 367-376.
21. Basu S, Haldar N, Bhattacharya S, Biswas S, Biswas M. Hepatoprotective activity of *Litchi chinensis* leaf against paracetamol-induced liver damage in rats. *Middlr East J Sci Res.* 2014;20:292-296.
22. Zaitoun A, Apelqvist G, Al-Mardini H, Gray T, Bengtsson F, Record C. Quantitative studies of liver atrophy after portacaval shunt in the rat. *J Surg Res.* 2006;131:225-232.
23. Hematólogico E. Action of trivalent chromium on rat liver structure. *Histometric and haematological studies.* *Int J Morphol.* 2006;24:197-203.
24. Jalili C, Salahshoor MR, Naderi T. The effect of hydroalcoholic extract of *P. crispum* on sperm parameters, testis tissue and serum nitric oxide levels in mice. *Adv Biomed Res.* 2015;4:40.
25. Reitman S, Frankel A. A colorimetric method for the determination of serum Glutamic oxaloacetic and Glutamic pyruvic transaminase. *Am J Clin Path.* 1957;28:56-63.
26. Sadashivam S, Manickam A. *Biochemical methods.* 2nd ed. Wiley Eastern Limited, New Delhi; 1996. p. 121-124.
27. Chen Y, Zhang H, Tian X, Zhao C, Cai L, Liu Y, *et al.* Antioxidant potential of crocins and ethanol extracts of *Gardenia jasminoides* ELLIS and *Crocus sativus* L: A relationship investigation between antioxidant activity and crocin contents. *Food Chem.* 2008;109:484-492.
28. Wang JQ, Zou YH, Cheng WM, Lu C, Zhang L. Preventive effects of total flavonoids of *Litsea coreana* leve on hepatic steatosis in rats fed with high fat diet. *J Ethnopharmacol.* 2009;121:54-60.
29. Drotman R, Lawhorn GT. Serum enzymes are indications of chemical induced liver damage. *Drug Chem Toxicol.* 1978;1:163-171.
30. Singh SP, Janecki AJ, Srivastava SK, Awasthi S, Awasthi YC, Xia SJ, *et al.* Mem-brane association of glutathione S-transferase mGSTA4-4, an enzyme that metabolizes lipid peroxidation products. *J Biol Chem.* 2002;277:4232-4239.
31. Samarghandian S, Afshari R, Farkhondeh T. Effect of long-term treatment of morphine on enzymes, oxidative stress indices and antioxidant status in male rat liver. *Int J Clin Exp Med.* 2014;7:1449-1453.
32. He SY, Tang FT, Wen N, Xu GL, Sheng L. Effect of crocin on experimental atherosclerosis in quails and its mechanisms. *Life Sci.* 2005;77:907-921.
33. Xiang M, Zhou CH, Liu J, Li WN. Crocetin inhibits leukocyte adherence to vascular endothelial cells induced by AGEs. *J Ethnopharmacol.* 2006;107: 25-31.
34. El-Maraghy SA, El-Sawalhi MM. Hepatoprotective potential of crocin and curcumin against iron overload-induced biochemical alterations in rat. *Afr J Biochem Res.* 2009;3:215-221.
35. Bekheet SH. Morphine sulphate induced histopathological and histochemical changes in the rat liver. *Tissue Cell.* 2010;42:266-272.
36. Todaka T, Ishida T, Kita H, Narimatsu S, Yamano S. Bioactivation of morphine in human liver: isolation and identification of morphinone, a toxic metabolite. *Biol Pharm Bull.* 2005;28:1275-1280.
37. Khayatnouri M, Safavi SE, Safarmashaei S, Babazadeh D, Mi-kailpourardabili B. The effect of saffron orally administration on spermatogenesis index in rat. *Adv Environ Biol.* 2011;5:1514-1521.
38. Razavi M, Hosseinzadeh H, Abnous K, Motamedshariaty V, Imenshahidi M. Crocin restores hypotensive effect of subchronic administration of diazinon in rats. *Iran J Basic Med Sci.* 2013;16: 64-72.
39. Khorsandi LS, Taherimobarakeh M, Kalantari H. The protective effect of turmeric (*curcuma longa*) extract on acetaminophen induced liver damage in mice. *J Zanjan Univ Med Sci.* 2006;14:23-29.
40. Amouoghli Tabrizi B, Mohajeri D. Protective effect of edible turmeric powder on early hepatic injury in diabetic rats. *J Kashan Univ Med Sci.* 2010;14: 190-199.
41. Larrauri JA, Sánchez-Moreno C, Rupérez P, Saura-Calixto F. Free radical scavenging capacity in the aging of selected red Spanish wines. *J Agric Food Chem.* 1999;47:1603-1606.
42. Salahshoor M, Mohamadian S, Kakabaraei S, Roshankhah S, Jalili C. Curcumin improves liver damage in male mice exposed to nicotine. *J Tradit Complement Med.* 2015, In Press.
43. Hosseinzadeh H, Ziaee T, Danaee A. Protective effect of aqueous saffron extract (*Crocus sativus* L.) and crocin, its active constituent, on renal ischemia-reperfusion-induced oxidative damage in rats. *J Pharm Pharm Sci.* 2005;8:387-393.

44. Sakr SA. Ameliorative effect of Ginger (*Zingiberofficinale*) on mancozeb fungicide induced liver injury in albino rats. *Aust J Basic Appl Sci.* 2007;1:650-656.
45. Cordova C, Siqueira IR, Netto CA, Yunes RA, Volpato AM, Cechinel Filho V. Protective properties of butanolic extract of the *Calendula officinalis* L. against lipid peroxidation of rat liver microsomes and action as free radical scavenger. *Redox Rep.* 2002;7:95-102.
46. Mohajeri D, Doustar Y, Rezaei A, Mesgari-Abbasi M. Hepatoprotective effect of ethanolic extract of *Crocus sativus* L. (Saffron) stigma in comparison with silymarin against rifampin induced hepatotoxicity in rats. *Zahedan J Res Med Sci.* 2010;12:53-59.
47. Zaragoza A, Andrés D, Sarrión D, Cascales M. Potentiation of hioacetamide hepatotoxicity by phenobarbita retreatment in rats, inducibility of FAD monooxygenase system and age effect. *Chem Biol Interact.* 2000;124:87-101.
48. Hon W Lee KH, Khoo HE. Nitric oxide in liver diseases : friend, foe, or just passerby? *Ann NY Acad Sci.* 2002;962:275-295.
49. Zarrindast MR, Javadi-Paydar M, Delphi L, Vousooghi N. Morphine-induced nitric oxide production in PC12 Cells. *Arch Iran Med.* 2012;15:404-408.
50. Muller T, SchepersG. Evidence for peroxynitrite as an oxidative stress-inducing compound of aqueous cigarette smoke fraction. *Carcinogenesis.* 1997;18:295-301.