

Clinical Article

Neurolysis for Meralgia Paresthetica

Byung-Chul Son, M.D., Ph.D., Deok-Ryeong Kim, M.D., Il-Sup Kim, M.D., Jae-Taek Hong, M.D., Jae-Hoon Sung, M.D., Sang-Won Lee, M.D.
Department of Neurosurgery, St. Vincent's Hospital, College of Medicine, The Catholic University of Korea, Suwon, Korea

Objective : Meralgia paresthetica (MP) is a syndrome of pain and/or dysesthesia in the anterolateral thigh that is caused by an entrapment of the lateral femoral cutaneous nerve (LFCN) at its pelvic exit. Despite early accounts of MP, there is still no consensus concerning the effectiveness of neurolysis or transaction treatments in the long-term relief for medically refractory patients with MP. We retrospectively analyzed available long-term results of LFCN neurolysis for medically refractory MP in an effort to clarify this issue.

Methods : During the last 7 years, 11 patients who had neurolysis for MP were enrolled in this study. Nerve entrapment was confirmed preoperatively by electrophysiological studies or a positive response to local anesthetic injection. Decompression of the LFCN was performed at the level of the iliac fascia, inguinal ligament, and fascia of the thigh distally. The outcome of surgery was assessed 8 weeks after the procedure followed at regular intervals if symptoms persisted.

Results : Twelve decompression procedures were performed in 11 patients over a 7-year period. The average duration of symptoms was 8.5 months (range, 4-15 months). The average follow-up period was 33 months (range, 12-60 months). Complete and partial symptom improvement were noted in nine (81.8%) and two (18.2%) cases, respectively. No recurrence was reported.

Conclusion : Neurolysis of the LFCN can provide adequate pain relief with minimal complications for medically refractory MP. To achieve a good outcome in neurolysis for MP, an accurate diagnosis with careful examination and repeated blocks of the LFCN, along with electrodiagnosis seems to be essential. Possible variation in the course of the LFCN and thorough decompression along the course of the LFCN should be kept in mind in planning decompression surgery for MP.

Key Words : Entrapment neuropathy · Lateral femoral cutaneous nerve · Meralgia paresthetica · Neurolysis.

INTRODUCTION

Meralgia paresthetica (MP) is a mononeuropathy resulting from the compression of the lateral femoral cutaneous nerve (LFCN) as it crosses between the anterior superior iliac spine (ASIS) and the inguinal ligament to enter the thigh^{20,28}. The nerve receives sensory input from the skin of the anterolateral thigh (Fig. 1A). Affected patients consequently experience a very prominent painful dysesthesia and, less commonly, vasomotor disturbance in the cutaneous distribution of the nerve. The term MP was first coined by Roth²¹ in 1895. However, despite its long-term recognition, very few studies have been published on the surgical management and outcome of this condition^{10,17,18,23,26}.

Two types of operative techniques, decompression with neurolysis and transection of LFCN, have been proposed to be effective for MP^{23,27}. Transection of the nerve at its exit from the

pelvis is a simple and effective procedure provided the nerve can be found^{14,26,28}. However, such a procedure results in anesthesia over the lateral thigh²³. Symptomatic relief expected of neurolysis has not been consistently reported in the literature^{3,14,17,18,23}. In an effort to provide clarification, we report long-term results of neurolysis for MP from our collected series of 11 cases.

MATERIALS AND METHODS

Selection criteria

Over an 8-year period (2003-2010), all patients who underwent neurolysis for MP were included in this study. These patients were referred by general physicians with distressing symptoms notwithstanding conservative management for some weeks to months. The diagnosis of MP was typically delayed until patient visit to our outpatient department. Most patients diagnosed as MP were treated successfully without surgery.

• Received : August 30, 2011 • Revised : April 9, 2012 • Accepted : June 13, 2012

• Address for reprints : Byung-Chul Son, M.D., Ph.D.

Department of Neurosurgery, St. Vincent's Hospital, The Catholic University of Korea, 93 Jungbu-daero, Paldal-gu, Suwon 442-723, Korea
Tel : +82-31-249-8206, Fax : +82-31-245-5208, E-mail : sbc@catholic.ac.kr

• This is an Open Access article distributed under the terms of the Creative Commons Attribution Non-Commercial License (<http://creativecommons.org/licenses/by-nc/3.0>) which permits unrestricted non-commercial use, distribution, and reproduction in any medium, provided the original work is properly cited.

These non-operative measures included usage of nonsteroidal anti-inflammatory drugs (NSAIDs), injection of steroid and local anesthetics, advice on weight loss, and avoidance of local physical constricting factors. Neurolysis was performed when adequate symptomatic relief could be achieved by at least 3 months of non-operative treatment.

Diagnosis of MP

The diagnosis of MP was confirmed with at least three repeated blocks of the LFCN. In four of 11 patients, electrodiagnosis was conducted and a decrease in the amplitude of the sensory nerve action potential (SNAP) was detected with side-to-side amplitude difference.

Neurolysis

Under general anesthesia, a transverse incision was made 1 cm below the ASIS along the skin crease. Dissection was carried out down to the fascia lata to expose the nerve under loupe magnification. Particular attention was paid to its anatomic variability. The subfascial plane was exposed carefully to identify the nerve. The nerve was followed proximally to the inguinal ligament, and a blunt probe was used to demonstrate the tunnel between ASIS, inguinal ligament, and origin of Sartorius (Fig. 1B). The inferior leaf of the inguinal ligament was lifted, divided, and splayed. This decompressed the nerve anteromedially. The nerve was then mobilized and the fascial ridge between the ASIS and Sartorius origin, over which the nerve bridges, was divided, decompressing the nerve posterolaterally (Fig. 1C). Complete lysis was achieved by freeing the nerve at three levels²³: 1) the tendinous arc from the iliac fascia, 2) the inguinal ligament anteriorly and a sling of fascia posteriorly, and 3) distally at the deep fascia of the thigh along each division. A probe was then introduced parallel to the nerve distally to identify any constricting distal aponeuroticofascial tunnels. With hemostasis obtained, the wound was closed in two layers. No drains were left. The patient was discharged home on postoperative day 3.

Outcome and statistics

The outcome of surgery was assessed at follow-up visits 3 months after the procedure. Results were graded according to a three-tiered ranking (complete, partial, or no relief) as adopted

in other series^{10,17,18,23,26}. Complete relief was defined as complete resolution of the chief complaints. Partial relief was defined as partial resolution of the symptoms or complete resolution of some symptoms with persistence of others. No relief was defined as no change or worsening in the symptoms. Patients not achieving complete relief were scheduled for follow-up visits at an interval of 3-months for further assessment. A chi-square test was used to assess the relationship between obesity, sex and outcome. Unless noted, results are presented as (mean±standard deviation). Significant values represented $p \leq 0.05$.

RESULTS

Demographics

Table 1 summarizes the demographics and outcome of neurolysis in our series. The mean age of the patients was 57.7±8.4 years. Five of the 11 patients were male. The mean duration of pain before operation was 8.5±3.8 months, and mean preoperative visual analogue scale (VAS) was 6.1±1.1. The mean duration of follow-up was 33 months (range, 12-60 months).

Outcome

Nine of the 11 patients (81.8%) treated by neurolysis had complete relief of symptoms and two patients (18.2%) had partial relief in the long-term follow-up. Even the patients with partial relief were capable of independent management with intermittent medication involving NSAIDs. Repeated blocks of the LFCN were not needed in patients with partial relief. There was no complication related to surgery. There was no correlation between gender and obesity with surgical outcome ($p=0.182$ and $p=0.887$, respectively). There was no significant difference in age, duration of symptoms and preoperative VAS between patients with complete relief and partial relief ($p=0.266$, $p=0.690$, and $p=0.445$, respectively).

DISCUSSION

The syndrome involving a burning, tingling, and numb sensation in the anterolateral area of the thigh, with variable reduction of sensation in the distribution of the lateral femoral cutaneous nerve, was first described by Bernhardt⁴ in 1895 and named me-

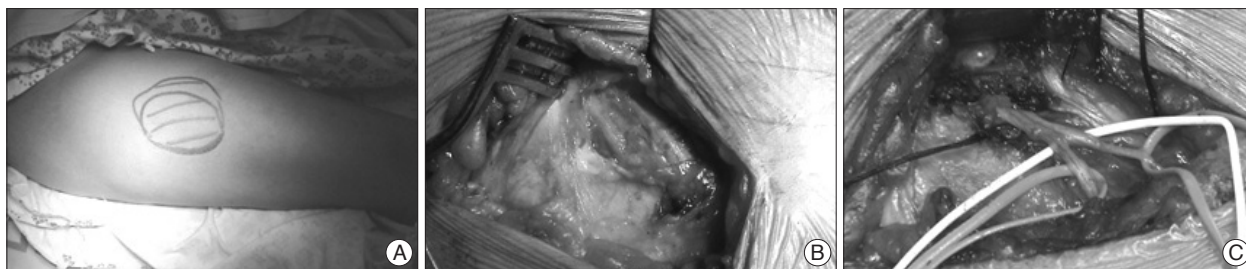


Fig. 1. Operative findings of decompression with neurolysis. A : A clinical photo showing the maximal painful dysesthetic area of right lateral thigh. B : Initial exposure of the course of lateral femoral cutaneous nerve. Note two branches, anterior and posterior branches of lateral femoral cutaneous nerve. C : Final operative photograph showing complete decompression along the course of lateral femoral cutaneous nerve. Decompression of the nerve was performed at the level of the iliac fascia, the inguinal ligament, and the fascia of the thigh distally.

ralgia paresthetica (MP; derived from the Greek word meros meaning thigh and algos, meaning pain) by Roth²⁰ in the same year. MP has at least 80 etiologies and can be categorized as spontaneous or iatrogenic^{1,5,7,9,12,13}. Spontaneous causes include mechanical factors such as obesity, pregnancy, and other conditions associated with increased intraabdominal pressure²⁸. The wearing of belts, corsets, and tight trousers can also result in direct pressure on the LFCN⁶, and pelvic benign masses such as uterine fibroids as presenting as MP have been reported^{24,25}. Other causes of spontaneous MP include radiologically degenerative pubis symphysis, limb length discrepancy, and osteoid sarcoma in more than one-third of pediatric patients following treatment¹³.

In the classic form of MP, the symptoms are fairly stereotypical and the diagnosis should be fairly straightforward for the astute clinician^{9,19}. However, diagnosis of MP is not always straightforward in clinical practice¹⁹. This condition can be confused with, and in a small group of patients it can coexist with, lumbosacral radicular pain^{11,19,23}. In our cases, the diagnosis of MP was fairly delayed and was not diagnosed until interviews conducted in our outpatient clinic. We speculate that this delay in diagnosis of MP in our country may have been related to poor understanding of this entity by some of the attending primary physicians and orthopedic and neurosurgical professionals. When there is doubt about the diagnosis following history-taking and physical examination, electrodiagnostic testing can be used. Side-to-side amplitude difference of the SNAP of the LFCN is a more sensitive predictor of MP than the absolute amplitude of the SNAP. In fact, a side-to-side amplitude ratio exceeding 2.3 combined with a SNAP <3 microvolts yields a specificity >of 98 %²¹.

In patients where a clinical diagnosis of MP has been made, a diagnostic block may be made with 8 mL of 0.25% bupivacaine^{7,22}. All patients who underwent neurolysis in our series responded temporarily with repeated blocks of LFCN, and we performed differential blockade of LFCN at least three times before making a decision to decompress the LFCN.

Surgical techniques for MP include neurolysis of the constricting tissue, neurolysis and transposition of the LFCN, and transection with excision of a portion of the LFCN. Each has its own advantage and disadvantages. Neurolysis is a physiologic procedure that seeks to preserve the integrity of the LFCN. However, reported results of neurolysis vary from 60% to 95% due to presence of neuroma and anatomical variations in the course of the LFCN^{3,16,17,23}. Only two reports have described neurolysis combined with transposition^{2,14} and this approach has not been tested in a clinical trial¹². Transection is another effective means to produce good results²⁸. However, sectioning of the LFCN can produce a permanent anesthetic area in the anterolateral

Table 1. Demographics and results of patients with meralgia paresthetica underwent neurolysis

Serial no.	Age	Sex	Duration of pain (months)	VAS	Obesity (BMI>30)	Follow-up (months)	Result (CR,PR, NR)	Recurrence
1	48	F	14	7	Y	36	CR	-
2	56	M	5	6	-	24	CR	-
3	64	F	4	6	Y	34	CR	-
4	51	M	6	8	Y	44	CR	-
5	66	M	10	6	-	26	CR	-
6	47	F	12	5	-	18	CR	-
7	66	F	6	4	Y	60	PR	-
8	49	M	5	5	-	40	CR	-
9	71	F	8	6	-	12	CR	-
10	62	M	9	7	Y	27	PR	-
11	55	F	15	7	-	43	CR	-

VAS : visual analogue scale, BMI : body mass index, CR : complete relief, PR : partial relief, NR : no relief

thigh and there is a risk of neuroma formation.

Regarding neurolysis for MP, conflicting results with failure rates as high as 40% and success rates of 90% to 95% have been reported^{3,17,18,23,27}. Why surgery works for entrapment of other peripheral nerves such as the median and ulnar nerve, but may not work for LFCN is unresolving and intriguing. This dichotomy may be due to the difficulty in establishing a correct diagnosis of MP¹⁷, inability to locate LFCN due to its anatomical variability³, and inadequate decompression². In this regard, several measures have been advocated²³. Because the presentation of MP can be confused with other conditions, such as facet joint syndrome and trochanteric bursitis, electrodiagnostic studies and diagnostic block of LFCN should be performed for confirmation of diagnosis. The high variability of the location of LFCN needs to be particularly borne in mind during nerve exploration. Complete neurolysis of LFCN should be ensured with proximal and distal extension of decompressive maneuvers. In particular, the iliac fascia is to be divided when appropriate tension bands are often noted in compressing the nerve in its pelvic course. In addition, a sling of fascia posterior to the nerve in the region of inguinal ligament has been sought²³.

Siu and Chadran²³ reported the biggest series of neurolysis (45 cases) in MP surgery. In their 45 neurolysis procedures, 42 cases with follow-up of 4.1 years displayed complete and partial symptom improvements were noted in 33 (73%) and nine (20%) cases, respectively. No recurrence was noted. Analysis of clinical variables demonstrated that the duration of symptoms preoperatively did not affect the rate of complete symptom relief, but obese patients (body mass index >30) was six-times more likely to have incomplete surgery at the long-term follow-up.

The presence of a neuroma and the frequency of anatomical variation in the course of LFCN may render neurolysis difficult. Therefore, transection of the LFCN is another effective means of treating refractory MP. Williams and Trzil²⁸ reported excellent relief in 23 of 24 cases of transection. They stressed that sectioning of the LFCN offers uniformly good results and should

be easily reproducible once adequate identification of the nerve is accomplished, and patients are willing to accept permanent anesthesia on an area of the anterolateral thigh in exchange for relief of their symptoms. Ivins¹⁴⁾, in another series of 14 adult patients with a follow-up over 3-6 years, reported the effectiveness of transection in case of recurrence of MP after initial relief by neurolysis. With these favorable results of transection, they advocated primary transection in adult patients experiencing symptoms for more than 1 year and patients who have persistent or recurrent symptoms. van Eerton et al.²⁶⁾ evaluated transection and neurolysis in 21 refractory MP patients and found that transection (complete relief of symptoms in nine of 12 patients) was superior to neurolysis (complete relief of symptoms in three of 10 patients).

In our series, neurolysis was effective in relieving medically refractory MP. Neurolysis provided complete relief in nine patients (81.8%) and partial relief (18.2%) in two patients. There was no failure and recurrence in our series. Although previous authors stressed the relationship between obesity and recurrence of symptom, we could not find any correlation. With limited numbers of our series we cannot explain this finding. Since most papers dealing with surgeries for MP involved studies with Caucasians, a racial difference might be the reason. In a Korean report dealing with the surgical result of MP¹⁶⁾, the authors investigated the effectiveness of surgery in nine cases of neurolysis and two cases of transaction in iatrogenic MP caused by iliac bone graft harvesting for spinal surgery. Even in iatrogenic MP, transection and neurolysis was effective in relieving painful symptoms of MP in 10 out of 11 patients¹⁶⁾. Among the nine cases of neurolysis, complete relief was achieved in three patients, and partial relief was accomplished in four patients. Our results with neurolysis seems superior to this report, however, there was a difference in the characteristics of the enrolled patients. Our study deals MP patients with spontaneous cause, whereas the earliest study¹⁵⁾ dealt with iatrogenic MP following surgery. However, even in iatrogenic MP following surgery, it seems that neurolysis could bring adequate relief of symptoms of MP.

CONCLUSION

Neurolysis can be an effective means of treating medically refractory MP. To achieve a good outcome in neurolysis for MP, an accurate diagnosis with careful examination and repeated blocks of the LFCN, along with electrodiagnosis is essential. Possible variation in the course of the LFCN and thorough decompression along the course of the LFCN should be kept in mind in planning the decompression surgery for MP.

References

1. Abarbanel JM, Berginer VM, Osimani A, Solomon H, Charuzi I : Neurologic complications after gastric restriction surgery for morbid obesity. *Neurology* 37 : 196-200, 1987
2. Aldrich EF, van den Heever CM : Suprainguinal ligament approach for

- surgical treatment of meralgia paresthetica. Technical note. *J Neurosurg* 70 : 492-494, 1989
3. Aszmann OC, Dellon ES, Dellon AL : Anatomical course of the lateral femoral cutaneous nerve and its susceptibility to compression and injury. *Plast Reconstr Surg* 100 : 600-604, 1997
4. Bernhardt M : [Ueber isolirt im Gebiete des N. cutaneous femoris externus vorkommende Parästhesien]. *Neurol Centralbl* 14 : 242-244, 1895
5. Bierma-Zeinstra S, Ginai A, Prins A, Geleijnse M, van den Berge H, Bernsen R, et al. : Meralgia paresthetica is related to degenerative pubic symphysis. *J Rheumatol* 27 : 2242-2245, 2000
6. Boyce JR : Meralgia paresthetica and tight trousers. *JAMA* 251 : 1553, 1984
7. Dureja GP, Gulaya V, Jayalakshmi TS, Mandal P : Management of meralgia paresthetica : a multimodality regimen. *Anesth Analg* 80 : 1060-1061, 1995
8. Ecker A, Woltmann HW : Meralgia paresthetica : A report of one hundred and fifty cases. *JAMA* 110 : 1650-1652, 1938
9. Ecker AD : Diagnosis of meralgia paresthetica. *JAMA* 253 : 976, 1985
10. Edelson R, Stevens P : Meralgia paresthetica in children. *J Bone Joint Surg Am* 76 : 993-999, 1994
11. Franzini A, Broggi G, Osenbach RK, Benzel EC : A novel approach to the diagnosis and management of meralgia paresthetica in commons. *Neurosurg* 60 : 700, 2007
12. Grossman MG, Ducey SA, Nadler SS, Levy AS : Meralgia paresthetica: diagnosis and treatment. *J Am Acad Orthop Surg* 9 : 336-344, 2001
13. Harney D, Patijn J : Meralgia paresthetica : diagnosis and management strategies. *Pain Med* 8 : 669-677, 2007
14. Ivins GK : Meralgia paresthetica, the elusive diagnosis : clinical experience with 14 adult patients. *Ann Surg* 232 : 281-286, 2000
15. Keegan JJ, Holyoke EA : Meralgia paresthetica. An anatomical and surgical study. *J Neurosurg* 19 : 341-345, 1962
16. Kim CG, Kim C : Surgical results of meralgia paresthetica. *J Korean Neurosurg Soc* 35 : 188-191, 2004
17. Macnicol MF, Thompson WJ : Idiopathic meralgia paresthetica. *Clin Orthop Relat Res* : 270-274, 1990
18. Nahabedian MY, Dellon AL : Meralgia paresthetica: etiology, diagnosis, and outcome of surgical decompression. *Ann Plast Surg* 35 : 590-594, 1995
19. Nouraei SA, Anand B, Spink G, O'Neill KS : A novel approach to the diagnosis and management of meralgia paresthetica. *Neurosurgery* 60 : 696-700; discussion 700, 2007
20. Roth VK : Meralgia paresthetica. *Med Obozr* 43 : 678, 1895
21. Seror P, Seror R : Meralgia paresthetica : clinical and electrophysiological diagnosis in 120 cases. *Muscle Nerve* 33 : 650-654, 2006
22. Shannon J, Lang SA, Yip RW, Gerard M : Lateral femoral cutaneous nerve block revisited. A nerve stimulator technique. *Reg Anesth* 20 : 100-104, 1995
23. Siu TL, Chandran KN : Neurolysis for meralgia paresthetica : an operative series of 45 cases. *Surg Neurol* 63 : 19-23; discussion 23, 2005
24. Suber DA, Massey EW : Pelvic mass presenting as meralgia paresthetica. *Obstet Gynecol* 53 : 257-258, 1979
25. Tharion G, Bhattacharji S : Malignant secondary deposit in the iliac crest masquerading as meralgia paresthetica. *Arch Phys Med Rehabil* 78 : 1010-1011, 1997
26. van Eerten PV, Polder TW, Broere CA : Operative treatment of meralgia paresthetica : transection versus neurolysis. *Neurosurgery* 37 : 63-65, 1995
27. van Slobbe AM, Bohnen AM, Bernsen RM, Koes BW, Bierma-Zeinstra SM : Incidence rates and determinants in meralgia paresthetica in general practice. *J Neurol* 251 : 294-297, 2004
28. Williams PH, Trzil KP : Management of meralgia paresthetica. *J Neurosurg* 74 : 76-80, 1991