

A Case of Arteriovenous Fistula after Renal Biopsy in an IgA Nephropathy Patient with Macroscopic Hematuria

Satoshi Horikoshi^a Akiko Takahata^a Akihiko Shiraishi^b
Hiromitsu Fukuda^a Isao Ohsawa^a Ryohei Kuwatsuru^b
Yasuhiko Tomino^a

^aDivision of Nephrology, Department of Internal Medicine, and ^bDivision of Radiology, Juntendo University Faculty of Medicine, Tokyo, Japan

Key Words

Complication · Recurrent macroscopic hematuria · Ultrasonography · Renal biopsy

Abstract

Macroscopic hematuria is a common symptom in IgA nephropathy and is also one of the most frequent complications after a percutaneous renal biopsy. Here, we describe a patient with IgA nephropathy and recurrent macroscopic hematuria who developed an arteriovenous fistula after renal biopsy.

Introduction

Observation of renal morphologic changes is essential in the diagnosis and evaluation of disease activity. It is very important to perform a renal biopsy without any complications. However, hematuria and hematoma frequently occur after a biopsy. Therefore, real-time guidance and postbiopsy examination by ultrasonography are usually performed for general safety. On the other hand, macroscopic hematuria is also a common symptom of IgA nephropathy. We report herein a case of IgA nephropathy in a patient who had recurrent macroscopic hematuria both before and 3 months after renal biopsy due to an arteriovenous fistula diagnosed by renal ultrasonography.

Yasuhiko Tomino, MD, PhD
Division of Nephrology, Department of Internal Medicine
Juntendo University Faculty of Medicine, 2-1-1 Hongo
Bunkyo-ku, Tokyo 113-8421 (Japan)
E-Mail yasu@juntendo.ac.jp

Case Report

A 27-year-old woman had a renal biopsy because of intermittent macroscopic hematuria and proteinuria after tonsillitis. When she was 24 years old, the first episode of macroscopic hematuria and proteinuria (1.0 g/g Cr) occurred just 1 day after tonsillitis with a high fever. After treatment with antibiotics, all symptoms disappeared except for microscopic hematuria. Because such episodes recurred several times and there was continued microscopic hematuria without proteinuria, the patient underwent tonsillectomy when she was 26 years old. However, even after tonsillectomy, microscopic hematuria persisted, and she repeatedly had episodes of macroscopic hematuria and proteinuria following pharyngitis with a high fever. She had a renal biopsy under real-time ultrasonographic guidance with a 16-gauge automated biopsy device and was diagnosed with IgA nephropathy. The histology showed crescent formations in 2 out of 16 glomeruli, but she refused steroid therapy. Before being discharged from our hospital, evidence of only slight renal subcapsular bleeding in the left kidney could be found on routine ultrasonography. Three months after the renal biopsy, she had sudden macroscopic hematuria without any symptoms, which lasted for 3 days. After that, the macroscopic hematuria disappeared but the amount of microscopic hematuria was clearly increased as compared to before her renal biopsy. In the urinary sediment, red blood casts were always present and comprised of 20–40% dysmorphic red blood cells. Since an enlarged left renal pelvis was newly recognized on ultrasonography, enhanced computed tomography (CT) was performed and she was diagnosed with an arteriovenous fistula (AVF) in the lower pole of her left kidney (fig. 1a). As the amount of microscopic hematuria had decreased again, she chose not to receive therapy. When she was 34 years old, our patient got married and was concerned about her future fertility. Since repeated ultrasonography showed an increased dilatation of the left renal vein (fig. 1b), she decided to undergo treatment with percutaneous intervention. An arteriogram confirmed an AVF with an enlarged draining vein and aneurysmal dilatation (fig. 2a, b). Selective embolization of the feeding arterial branch closed the AVF with 8 detachable coils (fig. 2c, d). Follow-up magnetic resonance imaging (MRI) performed 3 months after the intervention did not show any abnormalities, including the dilatation of the renal vein (fig. 3). Microscopic hematuria disappeared within another 3 months and complete remission of IgA nephropathy had been achieved.

Discussion

It has been reported that in approximately 40–50% of IgA nephropathy cases there is at least 1 episode or even recurrent episodes of macroscopic hematuria, usually following an upper respiratory infection [1, 2]. As our patient also experienced repeated tonsillitis coinciding with a high fever and macroscopic hematuria, she underwent tonsillectomy before her IgA nephropathy diagnosis. However, she had similar episodes following pharyngitis, even after the tonsillectomy. Her macroscopic hematuria, with proteinuria of about 1 g/g Cr, had disappeared within several days after recovering from pharyngitis but microscopic hematuria remained. Although there have been several reports that tonsillectomy had an effect on IgA nephropathy by removing the focus of infection, the tonsils should not be the only focus in the upper respiratory tract [3, 4].

A nationwide registry-based study of renal biopsy complications in Norway was recently published [5]. The authors reported that macroscopic hematuria, which was the most frequent complication, appeared in 1.9% of 9,288 renal biopsies. They found that only a

small clinical center (<30 biopsies performed per year) and low GFR (<30 ml/min/1.73 m²) were associated with complications, and that the frequency of complications may reflect the use of systematic safety routines including postbiopsy ultrasound examination. In our hospital, nephrologists perform 50–70 renal biopsies every year; a renal ultrasonographic examination is performed the day following the biopsy and again 1 week later in order to detect the most frequent complication – subcapsular hematoma [6, 7]. However, in the present case, except for a small subcapsular hematoma, no gross abnormalities could be found; she presented with macroscopic hematuria 3 months after renal biopsy. In relapsing macrohematuric episodes without any other symptoms, the most important differential diagnosis is renal tumors. Magyarlaki et al. [8] reported that immunohistochemical analysis revealed IgA nephropathy in the resected kidneys of 11 (18%) out of 60 renal cell carcinoma patients. Therefore, we performed ultrasonography and CT to rule out renal tumors and made the diagnosis of AVF at the time of macroscopic hematuria.

Bilge et al. [9] reported that bleeding requiring clinical intervention, such as a transfusion, occurs in 1–6% of cases after renal biopsy. AVF is also a major complication of renal biopsy, as the incidence rate is reported to range from 1 to 18%, although complication rates have decreased as improvements have been made in automated devices for renal biopsy [9]. Since 80–95% of postbiopsy AVFs disappear spontaneously within 2–31 months, it has been reported that the incidence of symptomatic postbiopsy AVF is between 0.3 and 4% [9–11]. The symptoms of AVFs are microscopic hematuria, continuous abdominal bruit, palpable thrill, high output cardiac failure, thromboembolic phenomena, reduced renal function and severe hypertension. It appears that bruit or thrill are found more easily in allografts than in native kidneys, suggesting that postbiopsy AVF, like other postbiopsy complications, occurs with a higher incidence in allografts than in native kidneys (3 vs. 7%) [9, 12, 13]. Since macroscopic hematuria was the only symptom in the present case, our patient thought this episode was similar to her previous ones. No upper respiratory tract infection symptoms and the reduced red cell deformation ratio supported a diagnosis of extraglomerular bleeding. The gauge of the needle, number of needle passages and depth of the biopsy have been reported as risk factors [8, 10], but we attempted to use a 16-gauge needle twice and confirmed that the biopsy specimen consisted of renal cortex. Since AVFs are formed from the recovery of tissue in renal biopsies, when damage to the walls of contiguous arteries and veins results in a single communication between the vessels and the shunting of blood from the glomerular capillaries, they may be an inevitable complication. Progressive loss of renal function has been reported in such cases [13, 14], and transcatheter embolization has been established as a safe and effective method for the treatment of AVF and aneurysmal dilatation [11, 13, 15, 16]. Therefore, we may have to add ultrasonic Doppler as a routine echography for early diagnosis [17, 18] and intervention.

References

- 1 Donadio JV, Grande JP: IgA nephropathy. *N Engl J Med* 2002;347:738–748.
- 2 Tomino Y: Immunoglobulin A nephropathy and chronic kidney disease. *Nephrology* 2010;15(suppl 2):23–26.
- 3 Wang Y, Chen J, Wang Y, Chen Y, Wang L, Lv Y: A meta-analysis of the clinical remission rate and long-term efficacy of tonsillectomy in patients with IgA nephropathy. *Nephrol Dial Transplant* 2011;26:1923–1931.
- 4 Sato D, Suzuki Y, Kano T, Suzuki H, Matsuoka J, Yokoi H, Horikoshi S, Ikeda K, Tomino Y: Tonsillar TLR9 expression and efficacy of tonsillectomy with steroid pulse therapy in IgA nephropathy patients. *Nephrol Dial Transplant* 2012;27:1090–1097.
- 5 Tøndel C, Vikse BE, Bostad L, Svarstad E: Safety and complications of percutaneous kidney biopsies in 715 children and 8,573 adults in Norway 1988–2010. *Clin J Am Soc Nephrol* 2012;7:1591–1597.

Horikoshi et al.: A Case of Arteriovenous Fistula after Renal Biopsy in an IgA Nephropathy Patient with Macroscopic Hematuria

- 6 Parrish AE: Complications of percutaneous renal biopsy: a review of 37 years' experience. *Clin Nephrol* 1992;38:135–141.
- 7 Corapi KM, Chen JLT, Balk EM, Gordon CE: Bleeding complications of native kidney biopsy: a systematic review and meta-analysis. *Am J Kidney Dis* 2012;60:62–73.
- 8 Magyarlaki T, Kiss B, Buzogány I, Fazekas A, Sükösd F, Nagy J: Renal cell carcinoma and paraneoplastic IgA nephropathy. *Nephron* 1999;82:127–130.
- 9 Bilge I, Rozanes I, Acunas B, Minareci O, Nayir A, Oktem F, Tonguç E, Kozok Y, Emre S, Ander H, Sirin A, Poyanli A: Endovascular treatment of arteriovenous fistulas complicating percutaneous renal biopsy in three paediatric cases. *Nephrol Dial Transplant* 1999;14:2726–2730.
- 10 Omoloja AA, Racadio JM, McEnery PT: Post-biopsy renal arteriovenous fistula. *Pediatr Transplantation* 2002;6:82–85.
- 11 Rütth EM, Dittrich K, Jüngert J, Uder M, Rascher W, Dötsch J: Successful interventional treatment of arteriovenous fistula after kidney biopsy in paediatric patients – a report of three cases. *Nephrol Dial Transplant* 2008;23:3215–3218.
- 12 Matsell DG, Jones DP, Boulden TE, Burton EM, Baum SL, Tonkin ILD: Arteriovenous fistula after biopsy of renal transplant kidney: diagnosis and treatment. *Pediatr Nephrol* 1992;6:562–564.
- 13 Lorenzen J, Schneider A, Körner K, Regier M, Adam G, Nolte-Ernsting C: Post-biopsy arteriovenous fistula in transplant kidney: treatment with superselective transcatheter embolization. *Eur J Radiol* 2012;81:e721–e726.
- 14 Lang EK, Earhart V, Atug F, Thomas R, Macchia R: Slow progressive loss of renal function due to arteriovenous fistula caused by renal biopsy. *J Urol* 2007;177:735.
- 15 Benchetrit S, Bernheim J, Griton I, Verner M, Kots E, Korzets Z: Successful percutaneous embolization of a renal arteriovenous fistula following renal biopsy. *Isr Med Assoc J* 2005;7:277.
- 16 Jiang WX, Wang HF, Ma J, Han HJ: Arteriovenous fistula and pseudoaneurysm as complications of renal biopsy treated with percutaneous intervention. *Chin Med J* 2010;123:2736–2738.
- 17 Gainza FJ, Minguela I, Lopez-Vidaur I, Ruiz LM, Lampreabe I: Evaluation of complications due to percutaneous renal biopsy in allografts and native kidneys with color-coded Doppler sonography. *Clin Nephrol* 1995;43:303–308.
- 18 Yang CY, Lai MY, Lu CL, Tseng HS, Chiou HJ, Yang WC, Ng YY: Timing of Doppler examination for the detection of arteriovenous fistula after percutaneous renal biopsy. *J Clin Ultrasound* 2008;36:377–380.

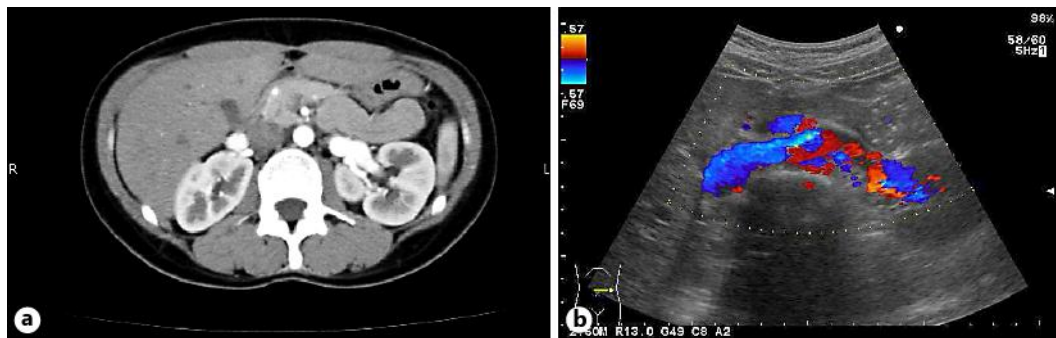


Fig. 1. **a** Contrast-enhanced abdominal CT. Early filling of a dilated renal vein in the arterial phase, which is consistent with AVF. **b** Color-coded Doppler sonography showing AVF. Increased color saturation toward blue can be seen on the surface of the kidney.

Horikoshi et al.: A Case of Arteriovenous Fistula after Renal Biopsy in an IgA Nephropathy Patient with Macroscopic Hematuria

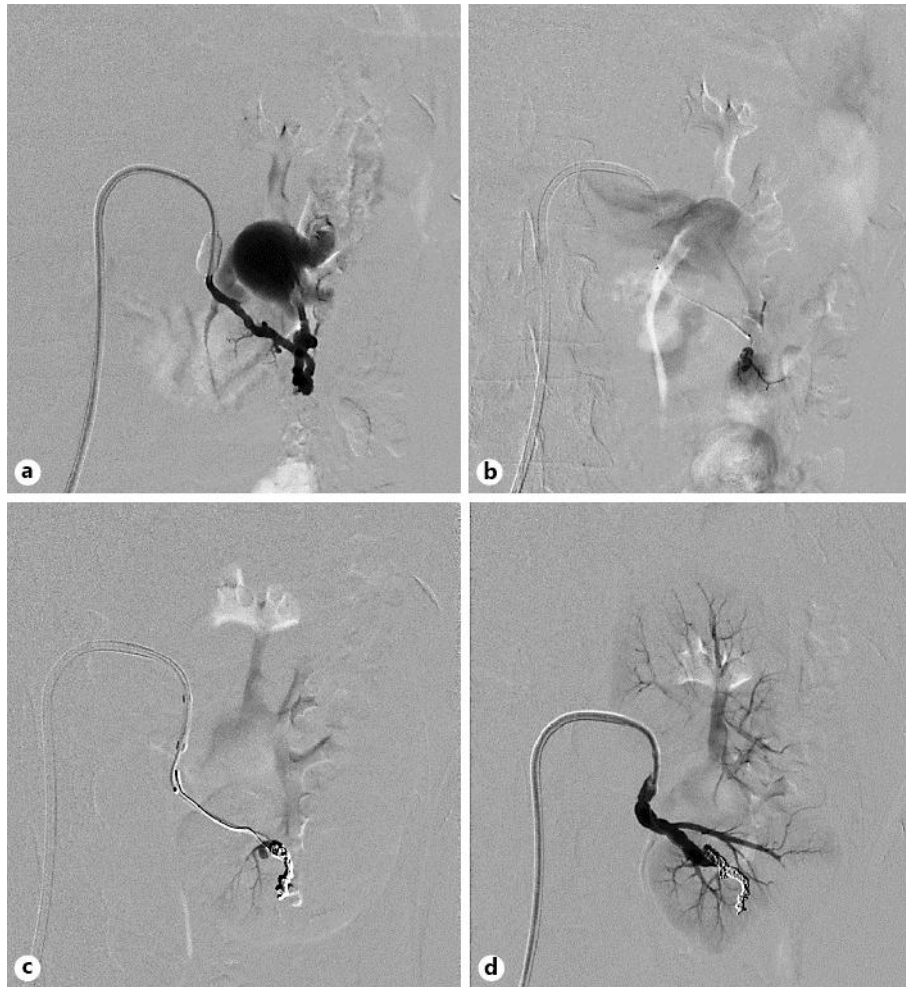

Fig. 2. **a** Left renal arteriography confirmed an AVF with aneurysmal dilatation and an enlarged draining vein. **b** Superselective catheterization before embolization. **c** Occlusion of an AVF and aneurysmal dilatation after embolization. **d** Confirmation of no additional detection of perfusion after the procedure.

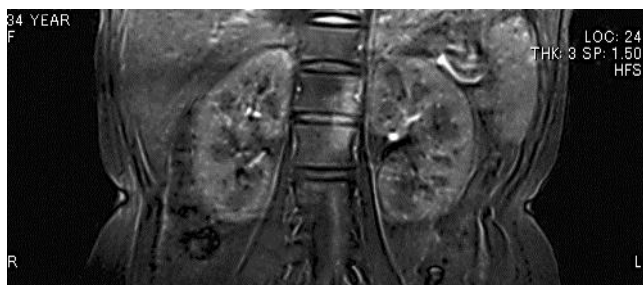

Fig. 3. Follow-up MRI taken 3 months after the intervention. No abnormalities, including the dilatation of the renal vein, can be seen.