

Malignant paratesticular mesothelioma

Leonardo Gomes da Fonseca^a, Daniel Fernandes Marques^a, Tiago Kenji Takahashi^a,
Fernando Nalesso Aguiar^a, Juliana Naves Ravanini^b, Daniel Fernandes Saragiotto^a

Fonseca LG, Marques DF, Takahashi TK, Aguiar FN, Ravanini JN, Saragiotto DF. Malignant paratesticular mesothelioma. Autopsy Case Rep [Internet]. 2014; 4(1): 45-51. <http://dx.doi.org/10.4322/acr.2014.007>

ABSTRACT

Mesothelioma of the tunica vaginalis testis (MTVT) is a rare tumor that usually affects patients after the sixth decade of life. Exposure to asbestos is a known risk factor. Enlargement of the scrotal volume is the most common initial clinical manifestation, and about 15% of cases present metastasis at diagnosis. The treatment relies on surgical resection while the role of adjuvant chemotherapy and radiotherapy remains unclear. The prognosis for patients is generally poor, with a lethal outcome in 30% over a 24-month period. The authors report a case of a 62-year-old patient with the diagnosis of MTVT without a history of asbestos exposure. After surgical treatment, metastatic disease ensued. Chemotherapy was initiated, but could not be continued due to marked and fast clinical deterioration. The authors call attention to the difficulty of early diagnosis of MTVT due to a nonspecific clinical picture, the lack of action by the patient when the scrotal enlargement was first noticed, and the lack of tumor markers. Delayed diagnosis is definitely related to unfavorable prognosis.

Keywords: Mesothelioma; Chemotherapy, Adjuvant; Spermatic cord; Orchiectomy.

CASE REPORT

A 62-year-old man sought the Urology Department complaining of progressive enlargement of the left testicle during the last 12 months associated with 5 kg of weight loss (7.3% of total body weight). He denied fever, testicular pain, or other local inflammatory sign. His past medical history included hypertension and diabetes mellitus. He had been a smoker of 20 packs/year but was abstinent for years. There was no reported history of cancer in his family; neither was there an occupation related to asbestos exposure.

The physical examination was normal except for thickening of the scrotal skin accompanied

by left testicle enlargement. Neither hernias nor lymphadenopathy were present bilaterally in the inguinal region.

An ultrasonogram revealed a mild hydrocele on the right scrotal sac, and a heterogeneous testicular mass interspersed with some cystic areas on the left. The tumor measured 11.6 × 9.5 × 6.8 cm (Figure 1).

Serum chorionic gonadotropin was <3 IU/L (reference value [RV] for men <3 IU/L), alpha-fetoprotein was 2.5 ng/mL (RV: <10 ng/mL) and lactic

^a Department of Oncology – Instituto do Câncer do Estado de São Paulo, São Paulo/SP – Brazil.

^b Department of Pathology – Instituto do Câncer do Estado de São Paulo, São Paulo/SP – Brazil.

dehydrogenase was 310 U/L (RV: 240-480 U/L). Complementary laboratory workup was normal. Abdominal computed tomography (CT) showed a single periaortic lymph node, which measured 2.8 cm at its longest axis.

An uneventful inguinal left orchiectomy was performed 10 days after the first visit. The left testicle and part of the scrotal sac, weighting 430 g and measuring 13,5 × 8,5 × 7,0 cm constituted the surgical specimen. At cut surface, a tumoral mass, of firm consistency, predominantly paratesticular involved the testicle and the spermatic cord, displacing them inferiorly. The epididymis was non-identified (Figure 2).

The morphological features (Figure 3), associated to the Immunohistochemical panel (Table 1) were compatible with the diagnosis of biphasic (epithelioid and sarcomatoid) malignant paratesticular mesothelioma with desmoplastic

areas. The tumoral infiltration spread to testicular parenchyma, rete testis, epididymis, tunica vaginalis and albuginea and spermatic cord. Angiolymphatic infiltration was present as well as intratumoral necrosis.

Table 1 – Immunohistochemical panel

Antigen	Result	Antigen	Result
Calretinin	Positive	P53	Positive
Vimentin	Positive	P63	Negative
Citokeratin 5	Positive	BerEp4	Negative
WT-1	Positive	CEA	Negative
CA125	Positive	MOC-31	Negative
D2-40	Positive	P16	Negative
Ki 67	High index	CD138	Negative

CA125 = cancer antigen 125; CEA = carcinoembryonic antigen; WT-1 = Wilms tumor protein

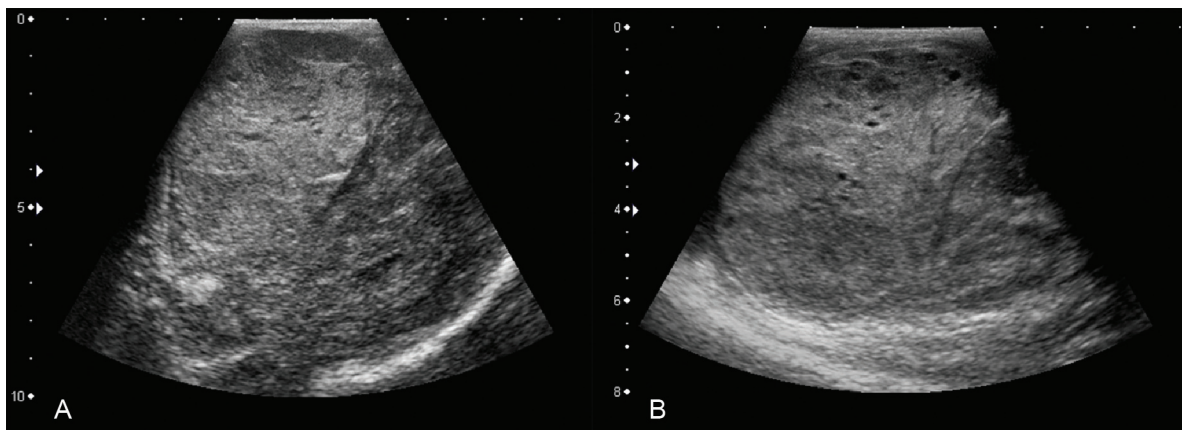


Figure 1 – A and B – Ultrasonography of the left scrotal sac showing a heterogeneous mass with some scattered cystic areas (notably in B).

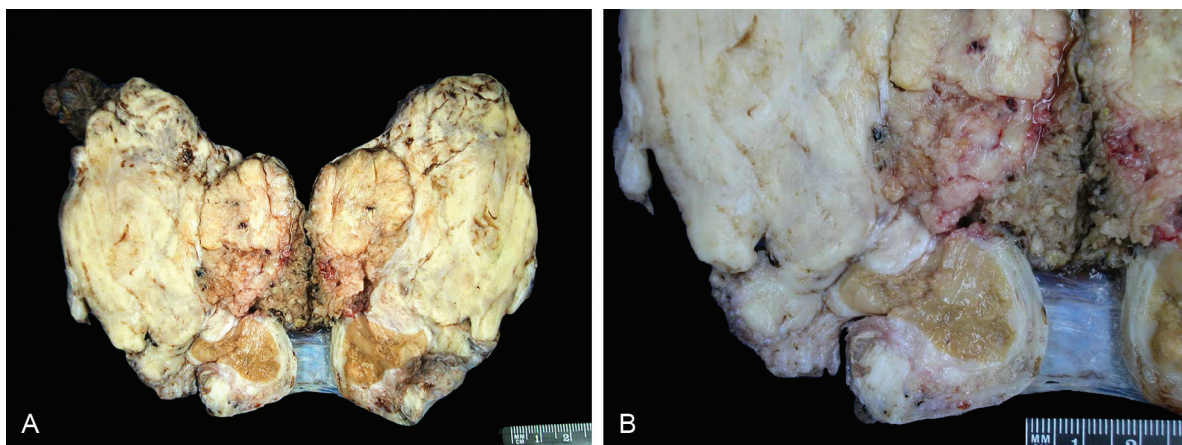


Figure 2 – Gross view of the surgical specimen showing in: A – longitudinal section of left testicle and scrotal sac showing paratesticular tumor involving the testicle with fascicular areas, and in B – in detail, infiltration of testicular parenchyma in an area of discontinuity of the tunica albuginea.

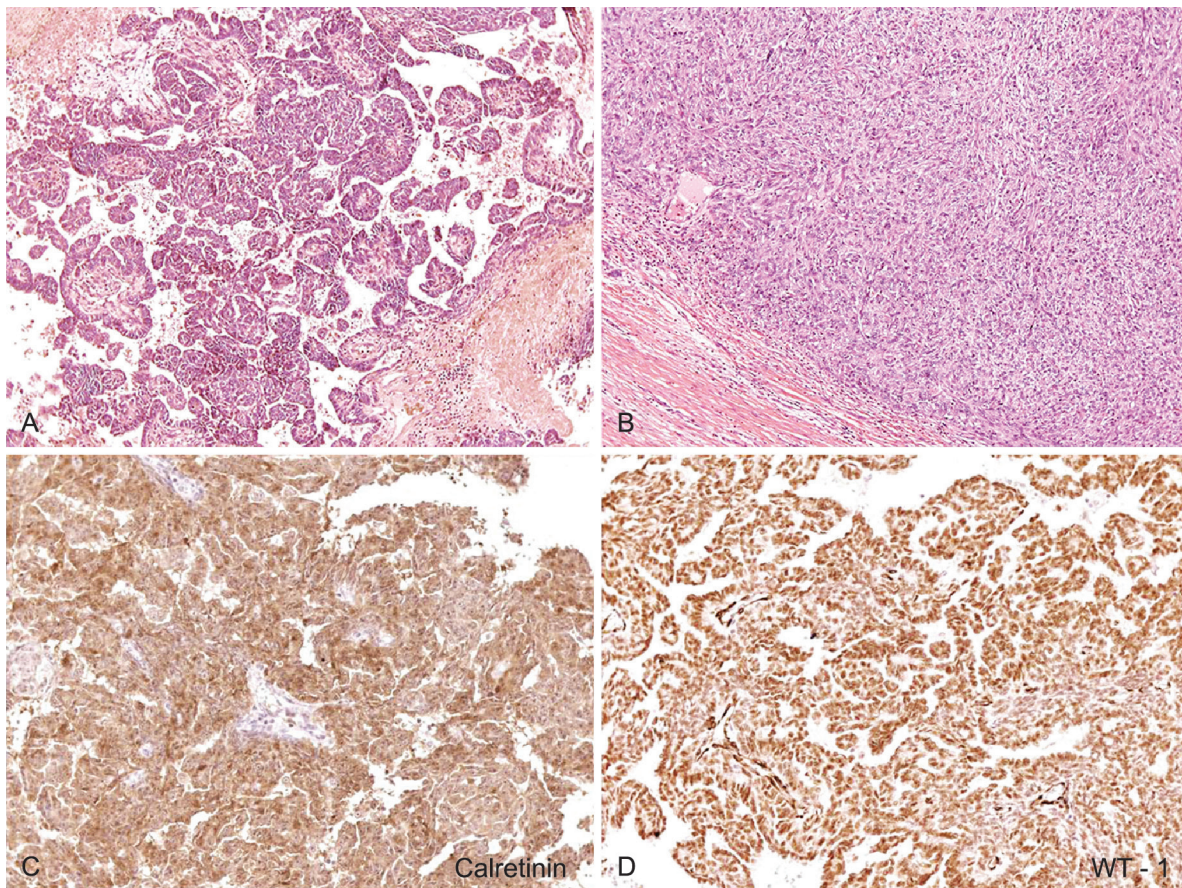


Figure 3 – Photomicrography of the surgical specimen (paratesticular tumor) showing: in **A** – stromal infiltration by solid tumor with epithelioid pattern (HE, 200X); **B** – infiltration by sarcomatoid spindle cells (HE,200X); **C** – immunohistochemical positive reaction for calretinin (400X); **D** – immunohistochemical positive reaction for WT-1 (400X).

The patient was referred to the clinical oncology department for post-surgery follow-up. After 3 months, he complained of pain and bulging in the left groin. A physical examination revealed an enlarged inguinal lymph node measuring 8 × 4 cm. Abdominal, thoracic, and pelvic CT showed multiple and confluent enlarged lymph nodes in the posterior mediastinum, retrocrural space, periaortic, along the left gonadal vein, iliac chains, and in the left groin. The largest lymph node measured 10 × 6.4 cm. An impairment of concentration and elimination of intravenous contrast by the left kidney accompanied by moderate hydronephrosis were found, as well as a few non-calcified pulmonary nodules scattered bilaterally with up to 1.1 cm in the superior segment of the right lower lobe (Figure 4).

The patient received two cycles of chemotherapy, which included pemetrexed and cisplatin. After 20 days, he returned with a marked decline in performance status, complaining of weakness and intense abdominal pain due to the progression of the disease. Considering this scenario, he was referred to exclusive palliative care and died after 24 days.

DISCUSSION

Malignant mesotheliomas are uncommon tumors, mostly involving the pleura, peritoneum, or pericardium, but rarely originating from the tunica vaginalis testis.¹ In 1957, Barbera and Rubino² described the first case of mesothelioma of the tunica vaginalis testis (MTVT), and since then, fewer than 230 cases have been reported.^{1,3} However, the first description of MTVT associated with asbestos was held by Fligiel and Kaneko in 1976.⁴ MTVT might be considered to be a variation of peritoneal mesothelioma, since the peritoneal lining extends into the scrotal sac.^{3,5} Since the description of Fligiel and Kaneko⁴ the association of MTVT and asbestos exposure has been widely reported.⁶⁻¹¹ This association was noted to occur between 34% and 42% of the cases,^{8,9} although this is considered to be underestimated because of insufficient clinical information. The failure of a patient to report a history of asbestos exposure does not necessarily mean that no exposure occurred as many individuals may not know that they have been exposed in the workplace or in the community.³ According to some studies, family exposure to asbestos increases the

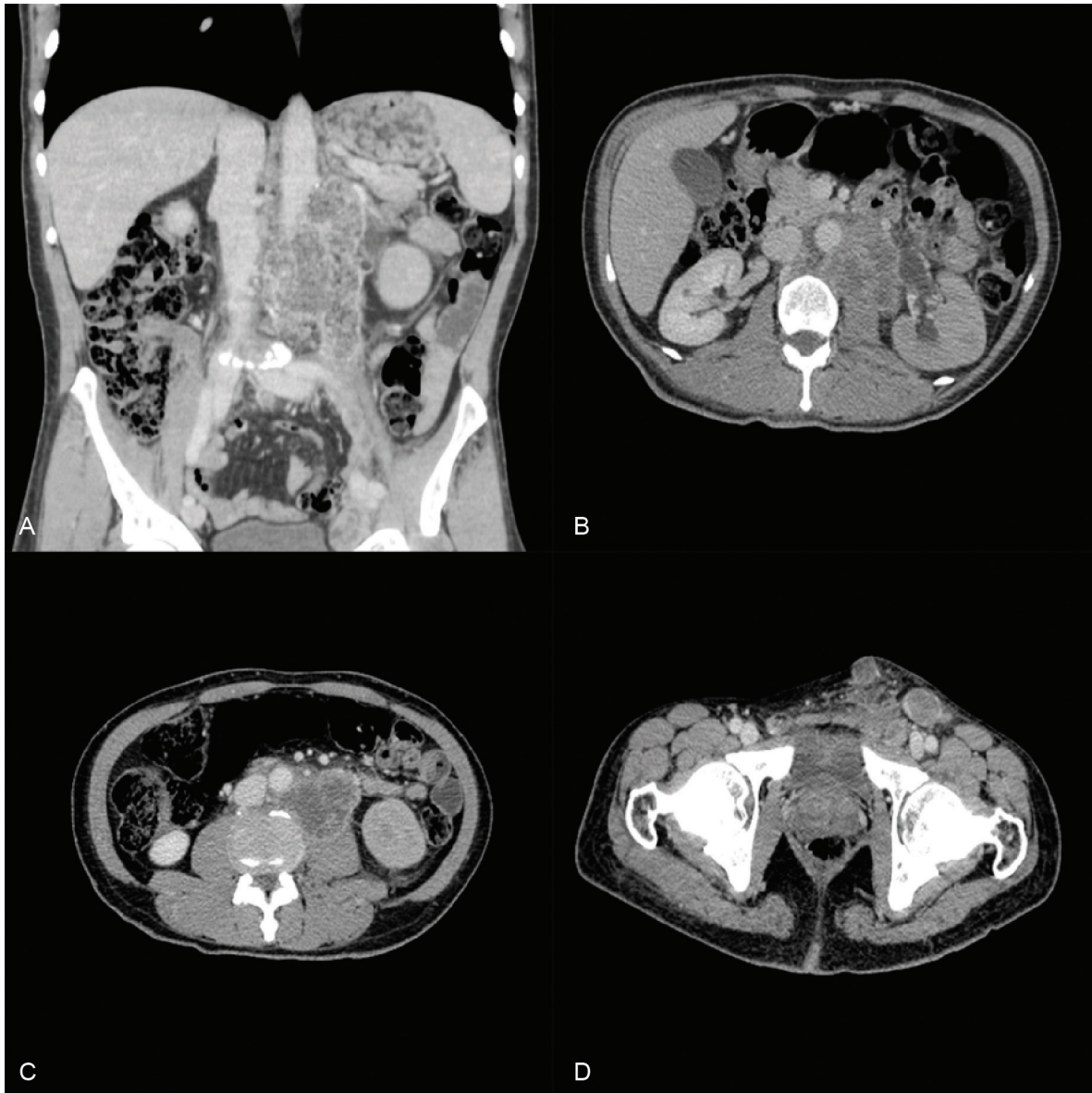


Figure 4 – Abdominal CT. **A** – Coronal reformation showing a heterogeneous mass involving the aorta and left iliac artery; **B** – Axial plane showing periaortic lymph nodes, delayed concentration/excretion of the contrast, and slight hydronephrosis; **C** – Axial plane showing lymph nodes conglomerate with signs of central necrosis along the left iliac artery; **D** – axial plane – multiple bilateral enlarged inguinal lymph nodes.

risk of pleural mesothelioma by 10 times.¹² The frequency of exposure to asbestos among patients with MTVT is comparable to patients with pleural mesothelioma.⁸ Although asbestos exposure or contact with asbestos-containing material remain the only plausible risk factor, other studies suggest that hydrocele and trauma may also be risk factors for the development of MTVT.⁵ It is well known that there is a high coincidence rate between mesothelioma and hydrocele; some investigators consider it debatable whether hydrocele plays a role in the development of mesothelioma or vice versa.⁵ Radiation or radiotherapy, viral infections, and chromosomal abnormalities are also speculative

hypotheses implicated in the oncogenesis of mesothelioma.¹³⁻¹⁵

Contrary to the usual pleural and peritoneal sites, the paratesticular disease is rare, and corresponds to 0.3-1.4% of all cases of malignant mesothelioma.¹ Simultaneous involvement of other serosas has already been reported.¹⁶⁻¹⁸

MTVT may occur in a wide range of ages. Although 10% of cases occur in patients under 25 years old, including children,^{9,19} the higher incidence mostly affects patients between the sixth and eighth decades of life.¹

The most frequent clinical manifestation of MTVT is a rapidly-growing hydrocele (56.3%) and a paratesticular mass (32.8%).¹ Both signs may present concomitantly, but that is not the rule.¹ The testis of both sides are equally affected, and bilateral tunical involvement is exceptional.²⁰ When the hydrocele is the presenting sign, the paratesticular tumor is frequently overlooked. The lack of specific clinical features, as well as tumor markers, is responsible for the delayed definitive diagnosis, which constitutes the paramount problem of malignant MTVT. The diagnosis is usually raised during surgical resection by the intraoperative finding of hemorrhagic hydrocele and the presence of small nodules in the tunica vaginalis, but confirmation is only achieved with the histology.¹ Clinical staging is usually performed with thoracic and abdominal CT. Positron emission tomography (PET) can be used, based on its reasonable accuracy to detect extra thoracic involvement in pleural mesothelioma.^{21,22}

Morphologically, paratesticular mesotheliomas are identical to mesotheliomas arising at other body parts and is comprised of three histological subtypes, namely: epithelial, which corresponds to about 70% of cases; biphasic, 27% of cases; and sarcomatous, 3% of cases.²³ Three different architectural patterns can be observed. Papillary or tubulo-papillary are the two most common. Well-differentiated patterns present a favorable prognosis and resemble a tumor arising from the intra-abdominal peritoneum of young females. Besides, the absence of stromal infiltration and necrosis are also favorable morphology features.²⁴ The third, and least frequent pattern, is multicystic mesothelioma, which shows a well-differentiated morphology. Multicystic mesothelioma is associated with large masses and is characterized as a favorable pattern in terms of prognosis.²⁵

The immunohistochemical profile of this neoplasm includes positivity for cytokeratin 7 and 5/6, calretinin, EMA, D2-40, and thrombomodulin, and negativity for cytokeratin 20, BerEP4, B72.3, MOC-31, and Leu-M1.^{26,27} More recently it has been shown that tunical mesothelioma express positivity for WT1 and CD138;²⁸ it is well known that the former is expressed by mesotheliomas of other sites, and the latter—although not routinely studied—is potentially helpful in target therapy.¹ Vimentin varies from negative to diffusely positive according to its sarcomatous component.¹ Positivity for calretinin differentiates mesothelioma from adenocarcinoma, and the negativity for BerEP4 stands for mesothelioma versus adenocarcinoma.²⁹

MTVT is locally invasive in 40% of cases while 15% present as metastatic disease at diagnosis.¹ Metastases occur via lymphatics—most commonly to the inguinal and periaortic lymph nodes, while the liver and lungs are frequently involved via hematogenous metastatic dissemination.¹ The presence of lymph node involvement at diagnosis relates to the worst prognosis. Advanced age at diagnosis also represents a significantly worse prognosis and is related to the aggressive course of the disease.^{9,30,31} Tumor recurrence occurs in more than 60% of cases over the first 2 years from diagnosis and in more than 90% of cases over the first 5 years from diagnosis.³⁰ The final lethal course is observed in 30% of cases after a median survival of 24 months.¹

A clinical examination and CT scan should be performed every 3 months for 2 years as the recommended strategy for routine clinical care after curative treatment.³²

Treatment of MTVT is based on inguinal radical orchiectomy concomitantly with inguinal or periaortic lymphadenectomy.¹ In the cases where surgical access violates the scrotal skin, radiotherapy is recommended after surgery. In metastatic or advanced disease, palliative chemotherapy may reduce tumor volume and seems to play a role in the survival of patients for up to 10 months.³²

Due to the scarcity of cases, treatment protocols rely on small series or case reports. Chemotherapy regimens are analogous to that used in pleural mesothelioma.³³ Plas et al.⁹ showed a better response in patients with metastatic disease using radiotherapy combined with chemotherapy when compared with chemotherapy alone. Radiotherapy should be considered in patients with local disease after tumor-free margin extensive resection and patients with disseminated disease with a good clinical condition.³⁴ In general, younger patients and early diagnosis are related to better prognosis.⁹ The role of adjuvant chemotherapy and radiotherapy is still controversial and requires further studies. Sebbag et al.³⁵ reported two cases of MTVT. One was a disseminated intra-abdominal disease, which underwent tumor resection plus peritonectomy and intraperitoneal chemotherapy with cisplatin, obtaining a disease-free survival of 5 years. The other case referred to a local disease treated with adjuvant chemotherapy with doxorubicin, obtaining a survival of 24 months.

CONCLUSION

In the case reported herein, we could not evidence exposure to known risk factors, but the age and clinical presentation fit the reported MTVT clinical features. The long time between the onset of symptoms and the demand for medical attention is noteworthy, as well as the progressive and fast metastatic spreading after surgical treatment of an apparent local disease. Despite the rare occurrence, this tumor should be considered a differential diagnosis of mass or increase of scrotal volume, even if the first diagnosis is a hydrocele, regardless of a history of asbestos exposure or history of cancer in the family. Early diagnosis is of great importance for successful treatment and improved survival.

REFERENCES

- Bisceglia M, Bem Dor D, Carosi I, Vario M, Pasquinelli G. Paratesticular mesothelioma. Report of a case with comprehensive review of literature. *Adv Anat Pathol.* 2010;17:53-70.
- Barbera V, Rubino M. Papillary mesothelioma of the túnica vaginalis. *Cancer.* 1957;10:183-9. [http://dx.doi.org/10.1002/1097-0142\(195701/02\)10:1<183::AID-CNCR2820100127>3.0.CO;2-1](http://dx.doi.org/10.1002/1097-0142(195701/02)10:1<183::AID-CNCR2820100127>3.0.CO;2-1)
- Meisenkothen C, Finkelstein MM. Asbestos exposure and malignant mesothelioma of the tunica vaginalis testis: Case series and review of the literature. *OA Case Reports.* 2013;2:17.
- Fligiel Z, Kaneko M. Malignant mesothelioma of the tunica vaginalis propria testis in a patient with asbestos exposure. *Cancer.* 1976;37:1478-84. [http://dx.doi.org/10.1002/1097-0142\(197603\)37:3<1478::AID-CNCR2820370333>3.0.CO;2-G](http://dx.doi.org/10.1002/1097-0142(197603)37:3<1478::AID-CNCR2820370333>3.0.CO;2-G)
- Gurdal M, Erol A. Malignant mesothelioma of tunica vaginalis testis associated with long-lasting hydrocele: could hydrocele be an etiological factor? *Int Urol Nephrol.* 2001;32:687-9. <http://dx.doi.org/10.1023/A:1014433203297>
- Karunaharan T. Malignant mesothelioma of the tunica vaginalis in an asbestos worker. *J R Coll Surg Edinb.* 1986;31:253-4.
- Huncharek M, Klassen M, Christiani D. Mesothelioma of the tunica vaginalis testis with possible occupational asbestos exposure. *Br J Urol.* 1995;75:679-80. <http://dx.doi.org/10.1111/j.1464-410X.1995.tb07437.x>
- Jones MA, Young RH, Scully RE. Malignant mesothelioma of the tunica vaginalis. Clinicopathologic analysis of 11 cases with review of the literature. *Am J Surg Pathol.* 1995;19:815-25. <http://dx.doi.org/10.1097/00000478-199507000-00010>
- Plas E, Riedl CR, Pfluger H. Malignant mesothelioma of the tunica vaginalis testis. Review of the literature and assessment of prognostic parameters. *Cancer.* 1998;83:2437-46. [http://dx.doi.org/10.1002/\(SICI\)1097-0142\(19981215\)83:12<2437::AID-CNCR6>3.0.CO;2-G](http://dx.doi.org/10.1002/(SICI)1097-0142(19981215)83:12<2437::AID-CNCR6>3.0.CO;2-G)
- Attanoos RL, Gibbs AR. Primary malignant gonadal mesotheliomas and asbestos. *Histopathology.* 2000; 37:150-9. <http://dx.doi.org/10.1046/j.1365-2559.2000.00942.x>
- Perez-Ordóñez B, Srigley JR. Mesothelial lesions of the paratesticular region. *Semin Diagn Pathol.* 2000;17:294-306.
- Begin R. Asbestos exposure and pleuropulmonary cancer. *Rev Mal Respir.* 1998;15:723-30.
- Peterson JT, Greenberg SD, Buffler PA. Non-asbestos-related malignant mesothelioma. *Cancer.* 1984;54:951-60. [http://dx.doi.org/10.1002/1097-0142\(19840901\)54:5<951::AID-CNCR2820540536>3.0.CO;2-A](http://dx.doi.org/10.1002/1097-0142(19840901)54:5<951::AID-CNCR2820540536>3.0.CO;2-A)
- Taguchi T, Jhanwar S, Siegfried J, Keller SM, Testa JR. Recurrent deletions of specific chromosomal sites in 1p, 3q, 6q and 9q in human malignant mesothelioma. *Cancer.* 1993;53:4349-55.
- Stenton SC. Asbestos, Simian virus 40 and malignant mesothelioma. *Thorax.* 1996;51:1074-6.
- Ascoli V, Facciolo F, Rahimi S, Scalzo CC, Nardi F. Concomitant malignant mesothelioma of the pleura, peritoneum, and tunica vaginalis testis. *Diagn Cytopathol.* 1996;14:243-8. [http://dx.doi.org/10.1002/\(SICI\)1097-0339\(199604\)14:3<243::AID-DC9>3.0.CO;2-I](http://dx.doi.org/10.1002/(SICI)1097-0339(199604)14:3<243::AID-DC9>3.0.CO;2-I)
- Poggi A, Longo F, Mansueto G, et al. A case of mesothelioma of the tunica vaginalis testis, with involvement of the pleura and-peritoneum. *Tumori.* 2000;86:256-7.
- Müller M, Stöckle M, Pecqueux JC, et al. Coincident manifestation of mesotheliomas of the tunica vaginalis and pleura. Case report and literature overview. *Urologe A.* 2008; 47:200-4. <http://dx.doi.org/10.1007/s00120-007-1576-2>
- Antman K, Cohen S, Dimitrov NV, Green M, Muggia F. Malignant mesothelioma of the tunica vaginalis testis. *J Clin Oncol.* 1984;2:447-51.
- Pelzer A, Akkad T, Herwig R, et al. Synchronous bilateral malignant mesothelioma of tunica vaginalis testis: early diagnosis. *Urology.* 2004;64:1031. <http://dx.doi.org/10.1016/j.urology.2004.06.003>
- Sørensen JB, Ravn J, Loft A, Brenøe J, Berthelsen AK; Nordic Mesothelioma Group. Preoperative staging of mesothelioma by 18F-fluoro-2-deoxy-D-glucose positron emission tomography/computed tomography fused imaging and mediastinoscopy compared to pathological findings after extrapleural pneumonectomy. *Eur J Cardiothorac Surg.* 2008; 34:1090-6. <http://dx.doi.org/10.1016/j.ejcts.2008.07.050>
- Wilcox BE, Subramaniam RM, Peller PJ, et al. Utility of integrated computed tomography-positron emission

- tomography for selection of operable malignant pleural mesothelioma. *Clin Lung Cancer*. 2009;10:244-8. <http://dx.doi.org/10.3816/CLC.2009.n.033>
23. Magoha GA. Testicular cancers in Nigerians. *East Afr Med J*. 1995;72:554-6.
24. Churg A. Paratesticular mesothelial proliferations. *Semin Diagn Pathol*. 2003;20:272-8. <http://dx.doi.org/10.1053/j.semdp.2003.08.003>
25. Amin MB. Selected other problematic testicular and paratesticular lesions: rete testis neoplasms and pseudotumors, mesothelial lesions and secondary tumors. *Mod Pathol*. 2005;18:S131-S145. <http://dx.doi.org/10.1038/modpathol.3800314>
26. Ordóñez NG. The diagnostic utility of immunohistochemistry and electron microscopy in distinguishing between peritoneal mesotheliomas and serous carcinomas: a comparative study. *Mod Pathol*. 2006;19:34-48. <http://dx.doi.org/10.1038/modpathol.3800471>
27. Suster S, Moran CA. Applications and limitations of immunohistochemistry in the diagnosis of malignant mesothelioma. *Adv Anat Pathol*. 2006;13:316-29. <http://dx.doi.org/10.1097/01.pap.0000213064.05005.64>
28. Al-Salam S, Hammad FT, Salman MA, AlAshari M. Expression of Wilms tumor-1 protein and CD 138 in malignant mesothelioma of the tunica vaginalis. *Pathol Res Pract*. 2009;205:797-800. <http://dx.doi.org/10.1016/j.prp.2009.01.012>
29. Sheibani K, Shin SS, Kezirian J, Weiss LM. Ber-EP4 antibody as a discriminant in the differential diagnosis of malignant mesothelioma versus adenocarcinoma. *Am J Surg Pathol*. 1991;15:779-84. <http://dx.doi.org/10.1097/0000478-199108000-00008>
30. García de Jalon A, Gil P, Azua-Romeo J, Borque A, Sancho C, Rioja LA. Malignant mesothelioma of the tunica vaginalis. Report of a case without risk factors and review of the literature. *Int Urol Nephrol*. 2003;35:59-62. <http://dx.doi.org/10.1023/A:1025952129438>
31. Hassan R, Alexander R. Nonpleural mesotheliomas: mesothelioma of the peritoneum, tunica vaginalis, and pericardium. *Hematol Oncol Clin North Am*. 2005;19:1067-87. <http://dx.doi.org/10.1016/j.hoc.2005.09.005>
32. Eden CG, Bettocchi C, Coker CB, Yates-Bell AJ, Pryor JP. Malignant mesothelioma of the tunica vaginalis. *J Urol*. 1995;153:1053-4. [http://dx.doi.org/10.1016/S0022-5347\(01\)67638-9](http://dx.doi.org/10.1016/S0022-5347(01)67638-9)
33. Vogelzang NJ, Rusthoven JJ, Symanowski J, et al. Phase III study of pemetrexed in combination with cisplatin versus cisplatin alone in patients with malignant pleural mesothelioma. *J Clin Oncol*. 2003; 21:2636-44. <http://dx.doi.org/10.1200/JCO.2003.11.136>
34. Lee JD, Perez S, Wang HJ, Figlin RA, Holmes EC. Intrapleural chemotherapy for patients with incompletely resected malignant mesothelioma: the UCLA experience. *J Surg Oncol*. 1995;60:262-7. <http://dx.doi.org/10.1002/jso.2930600410>
35. Sebbag J, Yan H, Shmookler B, Suggarbaker P. Malignant mesothelioma of the male genital tract: report of two cases. *Urol Oncol*. 2001;6:261-4. [http://dx.doi.org/10.1016/S1078-1439\(01\)00123-5](http://dx.doi.org/10.1016/S1078-1439(01)00123-5)

Conflict of interest: None

Submitted on: 3rd January 2014

Accept on: 19th March 2014

Correspondence: Departamento de Oncologia
Instituto do Câncer do Estado de São Paulo
Av. Dr. Arnaldo, 251 – Pacaembu – São Paulo/SP – Brazil
CEP: 01246-000 – Phone: +55 (11) 3893-2686
E-mail: leogfonseca@hotmail.com