

## Radial Arteriovenous Fistula Developed Late after Coronary Angiography: A Case Report

Kwon Joong Na, M.D.<sup>1</sup>, Myung A Kim, M.D.<sup>2</sup>, Hyeon Jong Moon, M.D.<sup>1</sup>,  
Jeong Sang Lee, M.D.<sup>1</sup>, Jae-Sung Choi, M.D.<sup>1</sup>

Transradial access is a widely accepted method for percutaneous coronary diagnostic and interventional procedures, and it has dramatically reduced access site vascular complications compared to transfemoral access. Arteriovenous fistula formation at the access site is an especially rare complication in transradial access. We report an extremely rare case of delayed radial arteriovenous fistula that developed one year after transradial coronary angiography, which was successfully treated by surgical repair.

Key words: 1. Cardiac catheterization  
2. Arteriovenous fistula  
3. Angiography  
4. Vascular disease

### CASE REPORT

A 61-year-old woman was referred to department of thoracic and cardiovascular surgery with thrill on the right wrist. Two years earlier, she had visited the emergency department of SMG-SNU Boramae Hospital with a recently aggravated chest pain. She underwent emergency coronary angiography (CAG) via the right femoral artery, and percutaneous coronary intervention for the proximal right coronary artery, which was successfully completed. One year after the intervention, she underwent diagnostic CAG via the right radial artery, and was discharged one day after the procedure. About 11 months after the day of the diagnostic CAG, she complained of palpable thrill on the right wrist at the outpatient clinic. She also presented dilated superficial veins on

the right forearm, which was very close to the previous puncture site for the diagnostic coronary angiography (Fig. 1).

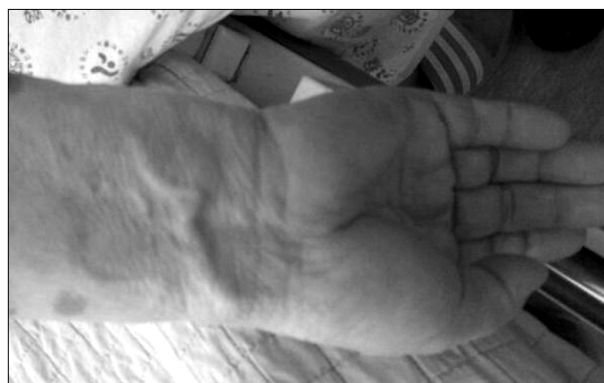

Fig. 1. Dilated superficial veins over right wrist.

<sup>1</sup>Department of Thoracic and Cardiovascular Surgery, <sup>2</sup>Division of Cardiology, Department of Internal Medicine, SMG-SNU Boramae Medical Center

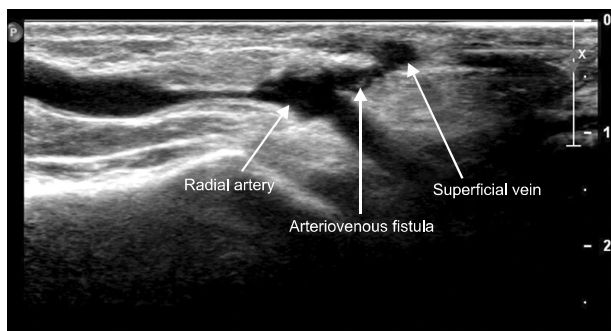
Received: July 9, 2012, Revised: August 23, 2012, Accepted: August 24, 2012

Corresponding author: Jae-Sung Choi, Department of Thoracic and Cardiovascular Surgery, SMG-SNU Boramae Medical Center, 20 Boramae-ro 5-gil, Dongjak-gu, Seoul 156-707, Korea

(Tel) 82-2-870-2293 (Fax) 82-2-870-3866 (E-mail) truejsreal@hanmail.net

© The Korean Society for Thoracic and Cardiovascular Surgery. 2012. All right reserved.

© This is an open access article distributed under the terms of the Creative Commons Attribution Non-Commercial License (<http://creativecommons.org/licenses/by-nc/3.0>) which permits unrestricted non-commercial use, distribution, and reproduction in any medium, provided the original work is properly cited.



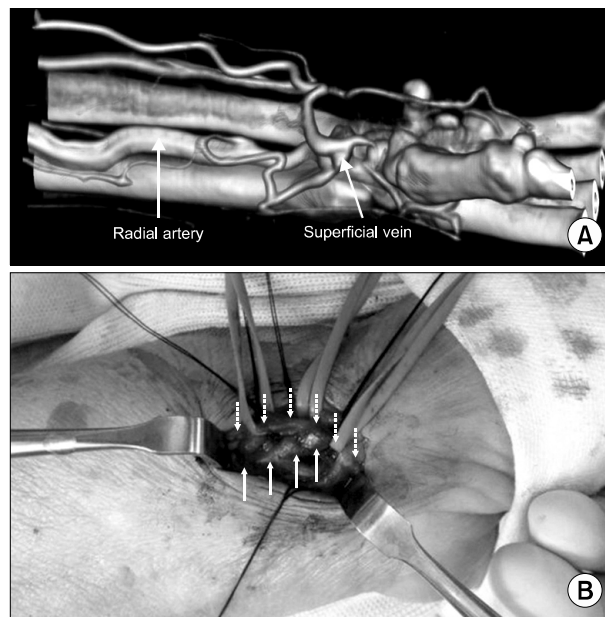
**Fig. 2.** A vascular ultrasound scan for radial artery. It revealed connection between radial artery and superficial vein which suggested arteriovenous fistula.

Suspecting radial arteriovenous fistula (AVF) formation, local compressive dressing and elastic bands were applied on the right wrist, with the expectation of spontaneous closure, but there was no effect. After all of that, we planned surgical ligation of the radial AVF.

A vascular ultrasound scan revealed a tract between the right radial artery and adjacent subcutaneous vein, which suggested radial arteriovenous fistula (Fig. 2). Computed tomography (CT) angiography of the upper extremity was performed, and it showed early visualization of dilated deep and superficial veins of the right forearm in the arterial phase. In addition, the right cephalic, brachial and axillary veins were visualized by contrast media in the arterial phase (Fig. 3A). The patient underwent fistulectomy under local anesthesia. The fistula tract between the radial artery and vein was ligated, and the arterial side fistula opening was closed primarily (Fig. 3B). She was discharged on postoperative day one without any complications.

## DISCUSSION

Transfemoral access is a widespread method for coronary diagnostic and interventional procedures, and it is rarely associated with access site vascular complications. The possible complications are major hematoma, AVF, pseudoaneurysm, and arterial dissection, and surgical correction for these complications is very commonly recommended. Transradial access for coronary procedures had become an increasingly popular technique since it was first introduced by Campeau in 1989



**Fig. 3.** (A) Computed tomographic angiography of upper extremities. Superficial veins are visualized by contrast media in arterial phase. (B) Intraoperative finding of arteriovenous fistula. There is a fistulous tract between radial artery (solid line arrows) and superficial veins (dotted line arrows).

because it significantly reduces access site vascular complications compared to transfemoral access [1,2]. In particular, AVFs after transradial access are an extremely rare complication (0.08%) because of the absence of large veins near the radial artery [3].

Kelm et al. [4] reported that there were several factors predisposing patients to iatrogenic femoral AVFs: age over 60, female gender, arterial hypertension, prolonged coumadin therapy, and high heparin dosage during the procedure. Most of the predisposing factors were associated with delayed healing of the access sites of the punctured arteries. In this case, there was atheromatous plaque in the fistulous portion of the right radial artery, which might have resulted in a poor healing process around the puncture site of the radial artery, and this, in turn, might have contributed to the formation of radial AVF.

The clinical presentation of iatrogenic AVF is various: a pulsatile mass, thrill, pain, edema, and dilated and varicose veins can occur. However, radial AVF is usually asymptomatic and manifests as a thrill or bruit over the wrist. The ia-

trogenic radial AVFs usually have smaller shunt volumes than other large fistulae, such as hemodialysis fistula, so that significant hemodynamic change is not frequent.

Several diagnostic tools, such as duplex ultrasonography, computed tomography, magnetic resonance imaging, and conventional angiography, can be used if there is clinical suspicion of iatrogenic AVF. Duplex ultrasonography has become the routine screening test for patients with suspected AVFs, but the use of a CT scan has gradually increased because CT is minimally invasive, rapid, and operator independent. In addition, 3-dimensional CT angiography shows the exact spatial relationship between the radial artery, superficial veins, and adjacent structures around the AVF, which was the reason we performed additional CT angiography after the ultrasonographic diagnosis of the AVF in this case.

Three different therapeutic strategies have been reported so far for treating iatrogenic radial AVF: conservative management, endovascular treatment, and surgical treatment. About one-third of iatrogenic AVFs close spontaneously; for this reason, conservative management is usually considered to be the first line of treatment [5]. Some have reported successful implantation of stents in radial AVFs, and surgical repair also has frequently been recommended [5]. In this case, we had applied local compression and elastic bands for a week, anticipating spontaneous closure of the radial AVF. However, there was no effect; thus, we performed surgical repair of AVF for the patient. We report an extremely rare case of de-

layed radial arteriovenous fistula formation, one year after CAG, using transradial access, which was treated successfully with surgical repair.

## CONFLICT OF INTEREST

No potential conflict of interest relevant to this article was reported.

## REFERENCES

1. Agostoni P, Biondi-Zoccai GG, de Benedictis ML, et al. *Radial versus femoral approach for percutaneous coronary diagnostic and interventional procedures: systematic overview and meta-analysis of randomized trials.* J Am Coll Cardiol 2004;44:349-56.
2. Brueck M, Bandorski D, Kramer W, Wieczorek M, Holtgen R, Tillmanns H. *A randomized comparison of transradial versus transfemoral approach for coronary angiography and angioplasty.* JACC Cardiovasc Interv 2009;2:1047-54.
3. Burzotta F, Trani C, Mazzari MA, et al. *Vascular complications and access crossover in 10,676 transradial percutaneous coronary procedures.* Am Heart J 2012;163:230-8.
4. Kelm M, Perings SM, Jax T, et al. *Incidence and clinical outcome of iatrogenic femoral arteriovenous fistulas: implications for risk stratification and treatment.* J Am Coll Cardiol 2002;40:291-7.
5. Summaria F, Romagnoli E, Preziosi P. *Percutaneous antegrade transarterial treatment of iatrogenic radial arteriovenous fistula.* J Cardiovasc Med (Hagerstown) 2012;13:50-2.