

Optic disc morphology in primary open-angle glaucoma versus primary angle-closure glaucoma in South India

Rajul Parikh, Naris Kitnarong¹, Jost B Jonas¹, Shefali R Parikh, Ravi Thomas^{2,3}

Purpose: The aim of this study was to investigate the optic disc morphology in primary angle-closure glaucoma (PACG) versus primary open-angle glaucoma (POAG) in South Indians. **Methods:** A total of 60 patients (60 eyes) with PACG and 52 patients (52 eyes) with POAG were included in a cross-sectional observational study. The glaucoma diagnosis was based on a glaucomatous appearance of the optic disc correlating with visual field defects. The glaucoma was graded as early, moderate, or severe, depending upon perimetric loss. All patients underwent an ophthalmic evaluation, including visual field examination and planimetric analysis of 30° stereoscopic color optic disc photographs. **Results:** The POAG and PACG groups did not differ significantly in a disc or rim area, rim width, and frequencies of disc hemorrhages or rim notches. However, early POAG group ($n = 15$) had a significantly deeper cup depth ($P = 0.01$), larger beta zone ($P = 0.01$), and a higher frequency of localized retinal nerve fiber layer (RNFL) defects ($P = 0.02$) than early PACG ($n = 20$). **Conclusion:** In the early stage of the disease, POAG compared to PACG may be characterized by deeper disc cupping, a larger beta zone of peripapillary atrophy, and a higher frequency of localized RNFL defects. Such differences in early glaucoma may suggest differences in pathophysiology in POAG and PACG.

Key words: Neuroretinal rim, optic cup, primary angle-closure glaucoma, primary open-angle glaucoma, retinal nerve fiber layer

Recent epidemiological studies have emphasized the importance of primary angle-closure glaucoma, particularly in Asian populations.^[1-4] Primary open-angle glaucoma (POAG) and primary angle-closure glaucoma (PACG) can show differences in their symptomatology, the height of intraocular pressure (IOP), age of detection, type of visual field defects and ocular dimensions, and other ocular measures.^[5-11] Using confocal laser scanning tomography and fluorescein angiography of optic nerve head, Sihota and colleagues reported diffuse neuroretinal rim loss in POAG. At the same time, those patients with PACG had a more sectoral abnormality, particularly in the superior temporal quadrant and the inferior temporal quadrant.^[9,10] Uchida and coworkers reported that the prevalence of peripapillary atrophy was more and that the peripapillary atrophy-to-disc area ratio was significantly larger in POAG versus PACG.^[2] Uchida and colleagues also suggested that differences in the pathophysiologic process of glaucomatous optic neuropathy between the two groups may account for their findings of a different appearance of the optic nerve head.^[12] Differences in the pattern of visual field defects between POAG and PACG have been reported.^[5,13] Most of the studies mentioned did not include intra or peripapillary parameters and did not differentiate between glaucoma stages.

We conducted this exploratory study to examine differences in the intrapapillary and peripapillary optic disc appearance between POAG and PACG in a South Indian population.

Methods

The study included patients who consecutively attended our Ophthalmology department's outpatient services for one year and fulfilled the inclusion and exclusion criteria. According to the institute's ethics committee, the methods applied in the study adhered to the tenets of the declaration of Helsinki for the use of human subjects in biomedical research. Two groups of patients, POAG and PACG, were enrolled. All underwent a complete ophthalmic examination, including determination of best-corrected visual acuity, Goldmann applanation tonometry, keratometry (Nidek Co., Gamagori, Japan), slit-lamp biomicroscopy, gonioscopy with a Susmann 4 mirror lens, indirect ophthalmoscopy, optic disc, and RNFL evaluation with a 78 diopters or 60 diopters lens, automated perimetry with Humphrey visual field analyzer (SITA standard 30-2 program), and stereoscopic color optic disc photographs.

To be included, patients had to have a best-corrected visual acuity of $\geq 20/40$, a refractive error within $\pm 5.0D$

Access this article online

Website:

www.ijo.in

DOI:

10.4103/ijo.IJO_2442_20

Quick Response Code:



Shreeji Eye Clinic & Palak's Glaucoma Care Centre, Mumbai, Maharashtra, India, ¹Department of Ophthalmology, Medical Faculty Mannheim of the Ruprecht-Karls-University Heidelberg, Germany, ²Queensland Eye Institute, Queensland, Australia, ³Department of Ophthalmology, University of Brisbane, Australia

Correspondence to: Dr. Rajul S Parikh, Shreeji Eye Clinic & Palak's Glaucoma Care Centre, Samrat Bldg, M Vasanji Road, Andheri East, Mumbai - 400 069, Maharashtra, India. E-mail: drparikhs@gmail.com

Received: 28-Jul-2020

Revision: 10-Dec-2020

Accepted: 31-Jan-2021

Published: 18-Jun-2021

This is an open access journal, and articles are distributed under the terms of the Creative Commons Attribution-NonCommercial-ShareAlike 4.0 License, which allows others to remix, tweak, and build upon the work non-commercially, as long as appropriate credit is given and the new creations are licensed under the identical terms.

For reprints contact: WKHLRPMedknow_reprints@wolterskluwer.com

Cite this article as: Parikh R, Kitnarong N, Jonas JB, Parikh SR, Thomas R. Optic disc morphology in primary open-angle glaucoma versus primary angle-closure glaucoma in South India. Indian J Ophthalmol 2021;69:1833-8

spherical refractive error and $\pm 3.0\text{D}$ cylindrical refractive error, an age of 40+ years, and clear ocular media (lens nuclear opalescence, nuclear color and lens cortical changes up to grade 3 on the Lens Opacities Classification System III (LOCS III)).^[14] Patients were diagnosed as glaucoma based on a combination of optic disc changes (rim notch, cup/disc diameter ratio $>0.7:1$ (in medium-sized optic discs), disc hemorrhages, rim saucerization, and wedge-shaped or diffuse RNFL defects corresponding to the visual field defect which satisfied at least 2 of Anderson's and Patella's criteria.^[15] The visual field examinations were performed twice to confirm the field defect. Based on the field defects, patients in both groups were further classified into mild, moderate, and severe glaucoma using Hoddap, Parrish, and Anderson's classification system.^[16] POAG or PACG were classified on gonioscopic findings.^[17] POAG patients had to have open angles on gonioscopy performed under specific testing conditions by one of two examiners.^[18] PACG patients had to have angle closure (appositional closure or synechial closure) on gonioscopy under the specified conditions using modified ISGEO classification.^[19] Intraocular pressure was not an inclusion criterion for the glaucoma groups.

Subjects were excluded if they had a history or evidence of intraocular surgery or laser within the past six months, retinal or macular pathology, systemic diseases or neurological disorders which could lead to visual field defects, failure to perform reliable perimetric examinations, subjectively assessed the poor quality of photographs, or unwillingness or inability to participate in the study. Patients with a history or evidence of secondary glaucomas such as pseudoexfoliation of the lens ("pseudoexfoliative glaucoma"), pigmentary glaucoma, steroid-induced glaucoma, angle recession glaucoma, lens-induced glaucoma, or patients with evidence of secondary angle-closure glaucoma like uveitic or neovascular glaucoma were excluded. Patients giving a history of the acute angle-closure attack were also excluded.

For all eyes, 30° color optic disc transparencies were taken using a Zeiss fundus camera (FF450; Zeiss, Oberkochen, Germany). The disc slides were projected on a scale of one to fifteen. The one expert examiner masked to the clinical findings, including diagnosis, performed all planimetry analysis. The outlines of the optic cup, optic disc, peripapillary scleral ring, and alpha zone and beta zone of peripapillary atrophy were plotted on paper and morphometrically analyzed using a technique published by one of the authors. [Fig. 1]^[20-22] To obtain values in absolute size units, i.e., millimeter or square millimeter, the ocular and photographic magnification were corrected using Littmann's method.^[23] Peripapillary atrophy was differentiated into a peripheral alpha zone with irregular pigmentation and a central beta zone at the optic disc border with the visible sclera and visible large choroidal vessels. The optic cup depth was scaled into degrees ranging from "0" for no cupping to "5" for very deep cupping. The coefficient of variation of this assessment method of the optic cup depth determined in a previous study was 2.0% and 8.9% for two examiners.^[24] The coefficient of variation (intra-observer and inter-observer reproducibility) for various optic disc parameters has been reported as good.^[25,26]

One eye was randomly selected for analysis for subjects in whom both eyes fulfilled the inclusion and exclusion criteria.

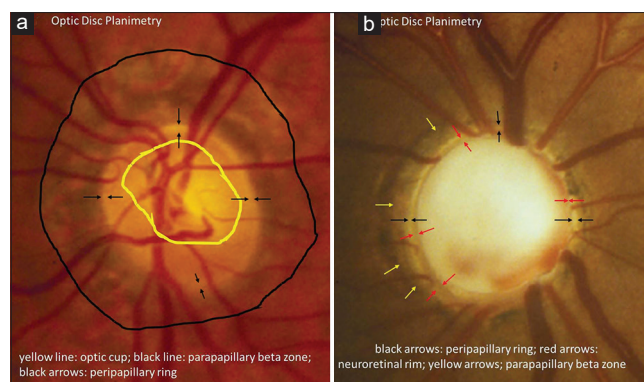


Figure 1: (a) shows the outlines of the optic cup, optic disc, peripapillary scleral ring, and alpha zone and beta zone of peripapillary atrophy for planimetry measurements. (b) the shows marking of optic disc marking; optic disc margin is marked on both images by delineating the peripapillary disc ring (black double arrows), with the inner border of the disc ring being the outer border of the neuroretinal rim

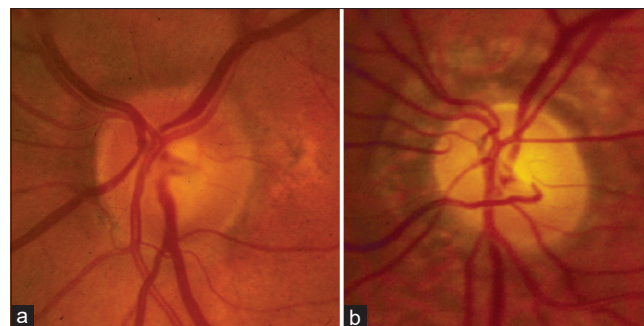

Figure 2: (a) shows optic disc in early PACG and (b) shows changes in optic disc in early POAG. Both patients had -5.0 dB MD on visual field. The optic disc of POAG eye shows larger beta zone and cup depth

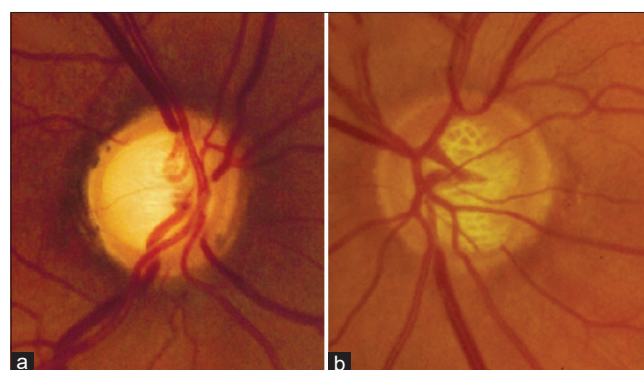


Figure 3: (a) shows optic disc in moderate PACG and (b) shows changes in optic disc in moderate POAG. Both patients had -8.5 dB MD on visual field. The optic disc of POAG eye shows more cup depth than PACG eye

Statistical analyses were performed using a commercially available statistical software package (SPSS for Windows, version 12, SPSS, Chicago, IL, USA). Optic disc parameters between the POAG and PACG groups were tested using the non-parametric Mann-Whitney-test for unpaired samples. The differences in frequencies were assessed using the Chi-Square-test. Separate comparisons of optic disc parameters between the early POAG and early PACG groups were also

performed. The level of significance was 0.05 (two-sided) in all statistical testing. Bonferroni's correction was applied to correct for multiple statistical comparisons.

Results

This clinical observational comparative study included 77 eyes (77 patients) with PACG and 70 eyes (70 patients) with POAG. Eighteen patients in the POAG group and 17 patients in the PACG group were excluded due to poor quality images. A total of 60 eyes (60 subjects) of PACG and 52 eyes (52 subjects) of POAG were analyzed. Twenty (33%) of 60 eyes with PACG and 15 (29%) of 52 eyes with POAG were classified as early glaucoma. As a result of matching, the severity of visual field defect in both groups was statistically similar ($P = 0.97$).

Table 1 shows the demography of POAG and PACG groups. The POAG group, compared with the PACG group, was significantly more myopic ($P = 0.01$).

Table 2 compares the optic disc parameters between POAG and PACG groups. Most of the optic disc parameters (optic disc area, neuroretinal rim area, rim width in all twelve-clock hour positions, frequency of detected disc hemorrhages, presence of a neuroretinal rim notch, optic cup area, the depth of the optic cup, and the frequency of beta zone of peripapillary atrophy) did not differ between the two groups. The prevalence of RNFL defects was significantly ($P = 0.04$) higher in the POAG group than in the PACG group (23/52 or 44.2% (95% confidence intervals (CI): 30.5%-57.9%) versus 19/60 or 31.7% (95% CI: 19.9%- 43.5%).

Table 1: Demographic data of patients with primary open-angle glaucoma (POAG) or primary angle-closure glaucoma (PACG)

Parameter	POAG	PACG	P
Number	52 eyes	60 eyes	
Age	58.6±8.2	59.1±10.1	0.41
Male: Female	26: 26	31: 29	0.32
Right eye: Left eye	27: 25	32: 28	0.46
Keratometry (Diopter)	44.4±1.6	43.75±1.6	0.12
Refractive error	-1.55±1.96	-0.12±1.31	0.01
Mean deviation (dB)	-8.3±6.5	- 8.25±6.	0.35
Pattern standard deviation (dB2)	5.6±2.8	5.6±2.7	0.44
Axial Length (mm)	23.24 (0.84)	22.89 (0.64)	0.09
IOP (mm Hg) at the time of photography, on Rx	16.9±3.1	17.3±3.3	0.83
Mean deviation (dB) in early glaucoma	-3.4±1.3	- 3.5±1.4	0.8
Pattern standard deviation (dB ²) in early glaucoma	2.7±0.8	2.67±0.7	0.6

IOP: intraocular pressure, dB: decibel

Table 2: Comparison of optic disc parameters between patients with POAG and PACG

Parameters	POAG (S.D. with 95% C.I.)	PACG (S.D. with 95% C.I.)	P
Number of eyes	52	60	
Disc area (Sq. mm)	3.06 (0.45), 2.937-3.182	3.00 (0.32), 2.92-3.08	0.01
Cup area (Sq. mm)	2.34 (0.50), 2.204-2.475	2.23 (0.38), 2.159-2.30	0.001
Rim area (Sq. mm)	0.73 (0.25), 0.662-0.797	0.77 (0.26), 0.742-0.835	0.001
Horizontal Disc diameter	1.93 (0.26), 1.859-2.007	1.91 (0.25), 1.846-1.973	0.01
Vertical Disc diameter	2.02 (0.26), 1.949-2.097	2.00 (0.28), 1.93-2.07	0.01
Horizontal/Vertical Disc diameter	1.05 (0.04), 1.039-1.06	1.04 (0.05), 1.027-1.052	0.73
Alpha zone	1.15 (0.12), 0.767-0.833	1.1 (0.15), 0.772-0.848	0.03
Beta zone	1.86 (0.75), 1.006-1.413	1.46 (0.71), 0.84-1.197	0.001
VCDR	0.75 (0.10), 0.722-0.777	0.74 (0.11), 0.712-0.768	0.003
HCDR	0.78 (0.09), 0.755-0.804	0.75 (0.09), 0.727-0.772	0.002
Rim Width (mm)			
Temporal superior	0.27 (0.06), 0.253-0.286	0.27 (0.06), 0.254-0.285	0.02
Temporal inferior	0.26 (0.07), 0.241-0.279	0.26 (0.06), 0.244-0.275	0.02
Temporal	0.25 (0.06), 0.233-0.266	0.26 (0.05), 0.247-0.272	0.01
Nasal	0.21 (0.05), 0.196-0.223	0.22 (0.06), 0.204-0.235	0.07
Frequency of RNFLD	23/52	19/60	0.0001
Frequency of Notch	13/52	10/60.	0.0001
Frequency of Disc Hemorrhage	3/52.	2/60.	0.01
Cup to disc area ratio	0.76 (0.09), 0.735-0.784	0.74 (0.09), 0.717-0.762	0.001

Sq mm: Square millimeter, VCDR: Vertical cup to disc ratio, HCDR: Horizontal cup to disc ratio, POAG: Primary Open Angle Glaucoma, PACG: Primary Angle Closure Glaucoma, S.D.: Standard Deviation, RNFLD: RNFL Defect, C.I.: Confidence Interval

Table 3 shows the comparison of optic disc parameters between early POAG and early PACG. Early POAG compared to the early PACG had a significantly deeper cup depth ($P = 0.03$), larger beta zone ($P = 0.03$), and a higher frequency of localized RNFL defects ($P = 0.02$) [Figs. 2 and 3]. Both groups did not vary significantly in the optic cup area, rim area, rim width in all 12-clock hour positions, disc area, and beta zone frequency.

If only eyes with moderate to advanced glaucomatous optic neuropathy were analyzed, the differences between the POAG and PACG groups were not statistically significant. Table 4 shows the comparison of optic disc parameters between moderate & severe stages of POAG and PACG.

Discussion

Glaucoma leads to changes in the optic disc and peripapillary region of the optic nerve head. These changes can affect the size and shape of the neuroretinal rim, depth of the optic cup, presence (and location) of splinter-shaped hemorrhages,

occurrence, size, configuration, and location of peripapillary chorioretinal atrophy, decrease in the diameter of the retinal arterioles, and visibility of the RNFL.^[27] Evaluating the differences in these morphological features of the optic disc between POAG and PACG may help to elucidate the pathophysiology of the glaucomatous optic neuropathy.

The frequency of optic disc hemorrhages was not significantly different between both glaucoma groups. While the number of patients in each study group may have been too small to detect a small difference, this suggests that at least some aspects of the pathophysiology of disc damage are common in the two groups. In clinic based data, Gazzard *et al.* found a prevalence of disc hemorrhage in Singaporean glaucoma patients of 2.99% and discovered that it was more common in POAG than in PACG; however, the difference was not significant.^[28] The prevalence of disc hemorrhages in the current report is lower than in previous population-based samples but similar to clinic-based reports. In population-based studies from Australia (The Blue Mountains Eye Study) and from China (The Beijing Eye Study), the frequency of disc hemorrhages in the

Table 3: Comparison of optic disc parameters between early POAG, PACG

Parameters	Early POAG (Mean, SD), Range	Early PACG (Mean, SD), Range	P
Number of Eyes	15	17	
Disc area (Sq. mm)	3.04 (0.42), 2.21-4.38	2.97 (0.35), 2.1-3.92	0.51
Cup area (Sq. mm)	2.19 (0.47), 1.04-2.95	2.09 (0.37), 1.14-3.00	0.64
Rim area (Sq. mm)	0.85 (0.31), 0.34-1.26	0.88 (0.22), 0.40-1.34	0.73
Alpha zone	1.05 (0.4), 0.35-2	0.81 (0.15), 0.64-1.35	0.22
Beta zone	1.68 (0.5), 1.5-3.31	1.2 (0.7), 0.772-1.628	0.03
VCDR	0.68 (0.10), 0.44-0.9	0.70 (0.11), 0.47-0.87	0.65
HCDR	0.73 (0.09), 0.50-0.91	0.73 (0.09), 0.60-0.86	0.94
Presence of RNFLD Frequency (%)	5/15 (33.3%)	3/20 (15%)	0.01
Presence of Notch Frequency (%)	4/15 (26.7%)	4/20 (20%)	0.14
Presence of Disc Haemorrhage Frequency (%)	1/15 (6.7%)	1/20 (5%)	0.43
Cup Depth	2.87 (0.76)	2.3 (0.67)	0.03

Sq mm: Square millimeter, VCDR: Vertical cup to disc ratio, HCDR: Horizontal cup to disc ratio, POAG: Primary Open Angle Glaucoma, PACG: Primary Angle Closure Glaucoma, S.D.: Standard Deviation, RNFLD: RNFL Defect

Table 4: Comparison of optic disc parameters between moderate & severe POAG, PACG

Parameters	Moderate/severe POAG (Mean, SD), Range	Moderate/Severe PACG (Mean, SD), Range	P
Number of Eyes	37	40	
Disc area (Sq. mm)	3.06 (0.43), 2.27-4.49	3.01 (0.33), 1.99-4.1	0.51
Cup area (Sq. mm)	2.38 (0.47), 1.64-3.94	2.29 (0.37), 1.64-3.37	0.64
Rim area (Sq. mm)	0.63 (0.31), 0.22-0.9	0.665 (0.22), 0.20-0.94	0.73
Alpha zone	1.19 (0.45), 0.35-2.77	1.11 (0.15), 0.64-1.45	0.22
Beta zone	1.94 (1.0), 1.4-3.61	1.49 (0.92), 1.23-3.11	0.07
VCDR	0.8 (0.10), 0.54-0.95	0.77 (0.11), 0.53-0.97	0.65
HCDR	0.78 (0.09), 0.58-0.97	0.76 (0.09), 0.57-0.94	0.94
Presence of RNFLD Frequency (%)	18/37 (48.65%)	16/40 (40%)	0.22
Presence of Notch Frequency (%)	9/37 (24.32%)	6/40 (15%)	0.4
Presence of Disc Haemorrhage Frequency (%)	2/37 (5.40%)	1/40 (2.5%)	0.4
Cup Depth	4.09 (0.76) 2.66-4.62	4.01 (0.67), 3.6-4.44	0.09

Sq mm: Square millimeter, VCDR: Vertical cup to disc ratio, HCDR: Horizontal cup to disc ratio, POAG: Primary Open Angle Glaucoma, PACG: Primary Angle Closure Glaucoma, S.D.: Standard Deviation, RNFLD: RNFL Defect

whole glaucoma population was 14% and 8.8%.^[29,30] One among other reasons for the discrepancy in the frequency of detected disc hemorrhages between population-based studies and hospital-based investigations may be that in population-based investigations, not all glaucoma patients are under treatment; in contrast, to most patients included in hospital-based studies. Since disc hemorrhages in glaucomatous eyes may indicate a progression of glaucoma, the lack of treatment for some participants in population-based investigations may, therefore, lead to a higher rate of progression and a higher frequency of detected disc hemorrhages.

With both glaucoma groups matched for visual field loss, the total neuroretinal rim width in all twelve-clock hours was similar.

Using confocal laser scanning tomography to assess the optic nerve head topography and fluorescein angiography, Sihota *et al.* compared the optic nerve head and choroidal circulation in 30 patients each of chronic PACG, POAG, and normals.^[9] They reported diffuse damage with significant rim loss in patients with POAG and marked sectoral abnormalities (superotemporal and the inferior-temporal) in patients with chronic PACG. They hypothesized that this might be due to sectoral ischemia occurring in patients with chronic PACG due to a sudden rise of intraocular pressure. In the present study, this finding could not be confirmed. On the contrary, our early POAG group showed a higher frequency of localized RNFL defects indicating a more localized pattern of glaucomatous optic nerve damage. In Sihota's study, the POAG group had a slightly higher mean visual field defect than the chronic PACG group indicating more severe disease. Even in the present study, both the glaucoma group showed a diffuse loss in moderate to an advanced stage. The more advanced the glaucomatous damage, the more difficult it gets to detect localized signs of damage.

Differences in the optic nerve head's morphology between early POAG and early PACG have also been reported in previous studies using the techniques of confocal laser scanning tomography and optical coherence tomography.^[10-12] The difference in cup depth between both glaucoma groups, as found in the present study, supports a previous investigation in which a difference in cup shape measure with a steeper cup in the eyes with POAG was reported.^[1] Similar finding has been reported using optical coherence tomography.^[10] In a similar manner, that study also reported a steeper surface contour in eyes with POAG than in eyes with PACG. Nouri-Mahdavi K *et al.* compared patterns of damage in 32 eyes of Chronic PACG to POAG patients using Heidelberg Retina Tomograph (HRT) images and stereoscopic disc photographs. POAG eyes were matched for demography and severity of field loss (± 1 dB). Eyes with PACG had smaller cup areas, cup volume, and mean cup depth and larger rim/disc area ratio, which persisted after adjusting for disc size, age, refractive error, and IOP. They concluded that patterns of glaucomatous damage seem to be different in CACG compared with POAG. This difference in damage patterns may adversely affect the detection of early disease or its progression in PACG. Our data also shows less cup volume in the PACG group.^[31] In our previous study comparing POAG and PACG using HRT parameters, we have reported higher sensitivity of FSM discriminant function, cup shape measure the Moorfield regression analysis for early POAG compared

to early PACG indicating a difference in pathophysiology in the early stage of the disease.^[11]

The prevalence of peripapillary atrophy has been reported to be higher, and the ratio of peripapillary atrophy to disc area has been reported to be significantly larger in POAG than in PACG.^[12] Correspondingly, in eyes after acute primary angle-closure glaucoma, peripapillary atrophy did not markedly enlarge.^[32] In a similar manner, the beta zone of parapapillary atrophy was smaller in the early PACG group than in the POAG group in the present study.

Our study was exploratory. Analysis of the entire group showed no significant differences while analysis of the early damage groups did. If the early glaucoma groups' findings are confirmed, they may point towards differences in pathophysiology between the two types of chronic glaucoma. It is also possible that in acute angle-closure, due to sudden increase in IOP, morphologic changes in ONH are expected to be different from those subjected to a chronic or intermittent elevation of IOP. For this reason, acute PAC and patients with a history suggestive of acute PAC were excluded from the study.

There are several limitations to the study. The refractive error differed significantly between the POAG group and the PACG groups, with the PACG being significantly more hyperopic and POAG group myopic. This difference may, however, just reflect the characteristics of PACG being more common in hyperopic subjects. Myopia leads to a decreasing depth of the optic cup; the differences in refractive error between the two glaucoma groups may, however, only serve to underline the finding that the POAG had a more deep optic cup than the PACG group.^[31] We had to exclude nearly 25% of photographs due to poor quality images; this has been a problem in other studies, too.^[31,33] Additionally, color photographs instead of red-free fundus photographs were analyzed, which may have led to an under detection of RNFL defects. However, as the 'detectability' of RNFL changes depends on the background pigmentation, the assessment of RNFL in Indians is easier than in Caucasian patients. The Bonferroni correction for multiple comparisons required that we used a *P* value of 0.002 (0.05/26) for statistical significance. Applying this value, all differences between the glaucoma groups become statistically insignificant; one may also argue the Bonferroni correction's limitations.^[34]

Conclusion

In conclusion, the optic nerve head's appearance did not markedly differ between eyes with POAG and eyes with PACG in the moderate and advanced stages of the diseases. It suggests that the optic disc morphology features may not be very useful in the clinical differentiation of both entities. In the early stage of glaucomatous optic neuropathy, the eyes with POAG had larger parapapillary atrophy (beta zone), a deeper disc cupping, and a higher frequency of localized RNFL defects. This was an exploratory study, and future investigations may evaluate whether these morphological differences between both glaucoma types may be due to differences in the intraocular pressure profiles or other aspects of the pathogenesis of glaucomatous optic nerve damage.

Financial support and sponsorship

Nil.

Conflicts of interest

There are no conflicts of interest.

References

- Jacob A, Thomas R, Koshi SP, Braganza A, Muliyl J. Prevalence of primary glaucoma in an urban south Indian population. *Indian J Ophthalmol* 1998;46:81-6.
- Foster PJ, Johnson GJ. Glaucoma in China: How big is the problem? *Br J Ophthalmol* 2001;85:1277-82.
- Dandona L, Dandona R, Mandal P, Srinivas M, John RK, McCarty CA, *et al.* Angle-closure glaucoma in an urban population in southern India. The Andhra Pradesh eye disease study. *Ophthalmology* 2000;107:1710-6.
- Vijaya L, George R, Arvind H, Baskaran M, Paul PG, Ramesh SV, *et al.* Prevalence of angle-closure disease in a rural southern Indian population. *Arch Ophthalmol* 2006;124:403-9.
- Gazzard G, Foster PJ, Viswanathan AC, Devereux JG, Oen FT, Chew PT, *et al.* The severity and spatial distribution of visual field defects in primary glaucoma: A comparison of primary open-angle glaucoma and primary angle-closure glaucoma. *Arch Ophthalmol* 2002;120:1636-43.
- Wang JC, Gazzard G, Foster PJ, Devereux JG, Oen FT, Chew PT, *et al.* Interocular asymmetry of visual field defects in primary open angle glaucoma and primary angle-closure glaucoma. *Eye* 2004;18:365-8.
- George R, Paul PG, Baskaran M, Ramesh SV, Raju P, Arvind H, *et al.* Ocular biometry in occludable angles and angle closure glaucoma: A population-based survey. *Br J Ophthalmol* 2003;87:399-402.
- Marchini G, Pagliarusco A, Toscano A, Tosi R, Brunelli C, Bonomi L. Ultrasound biomicroscopic and conventional ultrasonographic study of ocular dimensions in primary angle closure glaucoma. *Ophthalmology* 1998;105:2091-8.
- Sihota R, Saxena R, Taneja N, Venkatesh P, Sinha A. Topography and fluorescein angiography of the optic nerve head in primary open-angle and chronic primary angle closure glaucoma. *Optom Vis Sci* 2006;83:520-6.
- Sihota R, Sony P, Gupta V, Dada T, Singh R. Comparing glaucomatous optic neuropathy in primary open angle and chronic primary angle closure glaucoma eyes by optical coherence tomography. *Ophthalm Physiol Opt* 2005;25:408-15.
- Thomas R, Muliyl J, Simha RA, Parikh RS. Heidelberg Retinal Tomograph (HRT II) parameters in primary open angle glaucoma and primary angle-closure glaucoma: A comparative study in an Indian population. *Ophthalmic Epidemiol* 2006;13:343-50.
- Uchida H, Yamamoto T, Tomita G, Kitazawa Y. Peripapillary atrophy in the primary angle closure glaucoma: A comparative study with primary open angle glaucoma. *Am J Ophthalmol* 1999;127:121-8.
- Rhee R, Kim YY, Nam DH, Jung HR. Comparison of visual field defects between primary open angle glaucoma and chronic primary angle closure glaucoma in the mild or moderate stage of the disease. *Korean J Ophthalmol* 2001;15:27-31.
- Chylack LT Jr, Wolfe JK, Singer DM, Leske MC, Bullimore MA, Bailey IL, *et al.* The Lens Opacities Classification System III. The Longitudinal Study of Cataract Study Group. *Arch Ophthalmol* 1993;111:831-6.
- Anderson DR, Patella VM. Automated Static Perimetry. 2nd ed. St. Louis, MO: Mosby; 1999. p. 121-36.
- Hodapp E, Parrish II RK, Anderson DR. Clinical Decisions in Glaucoma. St Louis: Mosby & Co.; 1993. p. 63-92.
- Foster PJ, Buhrmann R, Quigley HA, Johnson GJ. The definition and classification of glaucoma in prevalence surveys. *Br J Ophthalmol* 2002;86:238-42.
- Thomas R, Thomas S, Chandrashekar G. Gonioscopy. *Indian J Ophthalmol* 1998;46:255-61.
- Thomas R, Parikh R, Muliyl J, Kumar RS. Five-year risk of progression of primary angle closure to primary angle closure glaucoma: A population-based study. *Acta Ophthalmol Scand* 2003;81:480-5.
- Jonas JB, Gusek GC, Naumann GO. Optic disc morphometry in chronic primary open-angle glaucoma. I. Morphometric intrapapillary characteristics. *Graefes Arch Clin Exp Ophthalmol* 1988;226:522-30.
- Jonas JB, Nguyen XN, Gusek GC, Naumann GO. Parapapillary chorioretinal atrophy in normal and glaucoma eyes. I. Morphometric data. *Invest Ophthalmol Vis Sci* 1989;30:908-18.
- Jonas JB, Budde WM, Lang PJ. Parapapillary atrophy in the chronic open-angle glaucomas. *Graefes Arch Clin Exp Ophthalmol* 1999;237:793-9.
- Littmann H. Zur Bestimmung der wahren Größe eines Objektes auf dem Hintergrund des lebenden Auges. *Klin Monatsbl Augenheilkd* 1982;180:286-9.
- Jonas JB, Gründler AE. Optic disc morphology in "age-related atrophic glaucoma". *Graefes Arch Clin Exp Ophthalmol* 1996;234:744-9.
- Kono Y, Jonas JB, Zangwill L, Berry CC, Weinreb RN. Agreement of measurement of parapapillary atrophy with confocal scanning laser ophthalmoscopy and planimetry of photographs. *J Glaucoma* 1999;8:105-10.
- Tuulonen A, Jonas JB, Välimäki S, Alanko HI, Airaksinen PJ. Interobserver variation in the measurements of peripapillary atrophy in glaucoma. *Ophthalmology* 1996;103:535-41.
- Jonas JB, Budde WM, Panda-Jonas S. Ophthalmoscopic evaluation of the optic nerve head. *Surv Ophthalmol* 1999;43:293-320.
- Healey PR, Mitchell P, Smith W, Wang JJ. Optic disc hemorrhages in a population with and without signs of glaucoma. *Ophthalmology* 1998;105:216-23.
- Wang Y, Xu L, Hu L, Wang Y, Yang H, Jonas JB. Frequency of optic disc hemorrhages in adult Chinese in rural and urban China. The Beijing Eye Study. *Am J Ophthalmol* 2006;142:241-6.
- Lee K, Rensch F, Aung T, Lim LS, Husain R, Gazzard G, *et al.* Peripapillary atrophy after acute primary angle-closure glaucoma attack. *Br J Ophthalmol* 2007;91:1059-61.
- Nouri-Mahdavi K, Supawavej C, Bitrian E, Giaconi JA, Law SK, Coleman AL, *et al.* Patterns of damage in chronic angle-closure glaucoma compared to primary open-angle glaucoma. *Am J Ophthalmol* 2011;152:74-80.
- Varma R, Tielsch JM, Quigley HA, Hilton SC, Katz J, Spaeth GL, *et al.* Race-, age-, gender-, and refractive error-related differences in the normal optic disc. *Arch Ophthalmol* 1994;112:1068-76.
- Jonas JB, Thomas R, George R, Berenshtein E, Muliyl J. Optic disc morphology in south India: The Vellore eye study. *Br J Ophthalmol* 2003;87:189-96.
- Bland JM, Altman DG. Multiple significance tests: The Bonferroni method. *BMJ* 1995;310:170.