

Successful Myomectomy in the Second Trimester of Pregnancy

Abstract

The prevalence of uterine myomas during pregnancy is estimated to be small. However, a significant fraction of these could lead to pregnancy complications. Myomectomy is rarely performed during pregnancy because of fear of miscarriage and the risk of uncontrolled hemorrhage necessitating hysterectomy. This article reports on a case of myomectomy of subserous leiomyoma that was causing septic necrosis, leukocytosis, rise of inflammatory markers (erythrocyte sedimentation rate and C-reactive protein), and pressure symptom on the liver. Myomectomy was performed at 20 weeks of gestation. The pregnancy continued with no further problems, and at 39 weeks and 1 day of gestation, vaginal delivery resulted in a healthy baby. It is postulated that when myomectomy is performed in carefully selected patients, it prevents sepsis due to myoma torsion and necrosis and also protects surrounding organs against damage.

Keywords: *Leiomyoma, live birth, myomectomy, pregnancy*

Introduction

Myomectomy during pregnancy has been discussed since over a 100 years ago.^[1] There have been studies over a range of variables including the age of patients (e.g., young to elderly), size of myoma (e.g., small treatable with laparotomy to very large), location of myoma and its shape, patient's race, and geographical locations. The surgery is occasionally necessary multiple times.^[1,2]

According to the previous study, the surgery may not be needed unless torsion of pedunculated fibroid or necrosis results in inflammatory peritoneal reaction. In rare cases, surgical interventions including myomectomy become necessary.^[3] The main concerns that discourage surgery include miscarriage and risk of uncontrollable hemorrhage that may necessitate hysterectomy.^[2]

When removal of myoma becomes critical, laparoscopy, laparotomy, and minilaparotomy are discussed, with each having advantages and disadvantages.^[4] Laparoscopy is preferred to other procedures, being associated with reduction of pain, fast recovery, shorter hospital stay, and absence of large and unaesthetic scars. However, this and alternative surgeries including

minilaparotomy have potential short- and long-term complications, especially for women with symptomatic uterine myomas. Alternative surgeries are opted when the size of myoma is large.^[5,6]

The incidence of myoma in women has been the focus of numerous studies. A recent report on laparotomic myomectomy cites fraction of women developing benign uterine myomas as high as 20%–40%.^[7] However, this fraction is estimated to drop down to 0.1%–0.39% when it comes to myomas occurring during pregnancy.^[5] A higher estimation is provided by Domenici *et al.* who stated that about 0.3%–2.6% of pregnancies are associated with the presence of uterine myomas.^[2] Of these, only 10% cause complications including pain, bleeding, pregnancy loss, and late sporadic miscarriage, premature rupture of membranes, placental abruption, placenta previa, preeclampsia, presence of prelabour rupture of the membranes (PPROM), and fetal growth retardation. Specifically, uterine myomas do not show symptoms but may lead to obstetrical complications depending on their size, location, and number. Many obstetricians and gynecologists prefer postponing myomectomy until after delivery.^[8,9] However, in cases where complications associated with myomas are severe, the interruption of pregnancy is advocated.

This is an open access journal, and articles are distributed under the terms of the Creative Commons Attribution-NonCommercial-ShareAlike 4.0 License, which allows others to remix, tweak, and build upon the work non-commercially, as long as appropriate credit is given and the new creations are licensed under the identical terms.

For reprints contact: reprints@medknow.com

How to cite this article: Allameh Z, Allameh T. Successful myomectomy in the second trimester of pregnancy. *Adv Biomed Res* 2019;8:60.

Received: December, 2018. **Accepted:** June, 2019.

**Zahra Allameh,
Tajossadat Allameh**

*From the Department of
Obstetrics and Gynecology,
Faculty of Medicine, Isfahan
University of Medical Sciences,
Isfahan, Iran*

Address for correspondence:

*Prof. Tajossadat Allameh,
Department of Obstetrics
and Gynecology, Faculty of
Medicine, Isfahan University of
Medical Sciences, Isfahan, Iran.
E-mail: t_allameh@med.mui.
ac.ir*

Access this article online

Website: www.advbiores.net

DOI: 10.4103/abr.abr_236_18

Quick Response Code:



Due to fear of loss of fetus or massive hemorrhage and eventual hysterectomy, myomectomy is not recommended during pregnancy.^[8] Nevertheless, it was deemed necessary for the case of a 26-year-old nulliparous woman who visited in the clinics on October 20, 2015, for preconception counseling. Untreated myomas could potentially bleed leading to more acute conditions such as hemoperitoneum reported by Kasum.^[10] Furthermore, complications caused by untreated myomas are discussed in more details by Exacourstos and Rosati.^[11]

Case Report

The patient described above underwent ultrasonography which confirmed two myomas as follows: one on the left lateral wall of uterine measuring 98 mm × 78 mm × 72 mm, and the other, a peripheral one measuring 11 mm in size. Observed with internal echo, there was also an ovarian cyst sized 49 mm × 34 mm in the left ovary. After 7 months of attempting fertility, ultrasonography showed an intrauterine viable fetus of 6-week gestation.

At 11-week gestational age, the size of myomas had increased (i.e., they grew to 20 mm × 22 mm and 160 mm × 120 mm), but the patient did not have any remarkable symptoms. At 20-week gestational age, the patient was hospitalized because of right upper quadrant pain. Obstetrical examination showed that the uterus had become larger. The height of her uterus was found to be comparable to those of 28-week gestational age. Fetal heart rate was normal. Ultrasonography showed an intrauterine viable fetus of 20-week and 5-day gestation. A subserosal myoma measuring 170 mm × 160 mm × 120 mm with 1700 cc volume and minimum vascularity and without torsion was found in the right side of the uterus. Adnexa were not visible. The liver and biliary tract were normal. The corresponding laboratory data are presented in Table 1.

The patient's conditions initially improved with conservative treatment, and the patient was discharged after surgery counseling. Myomectomy was not planned at this point; nevertheless, the possibility of degenerated fibroid was considered. Based on the results of ultrasonography, the possibility of ovarian torsion and cholecystitis was

also ruled out. Nine days later, the laboratory test was repeated [Table 1].

Because of abdominal pain, leukocytosis, rise of inflammatory markers (erythrocyte sedimentation rate [ESR] and C-reactive protein [CRP]), and liver enzymes that checked serial, the patient's conditions were followed by subsequent ultrasonography. It showed a myoma tissue measuring 170 mm × 150 mm × 117 mm without vascularity. Again, it did not exhibit torsion or vascular occlusion. Creatinine level was normal in all durations of pregnancy. It was after myoma torsion, and due to fear of septic necrosis, the investigators had to consider exploratory laparotomy.

The patient presented with an explanation of her conditions including all possible outcomes of her pregnancy along with the descriptions of the myomas. She gave her informed consent to undergo exploratory laparotomy. Laparotomic incision was chosen for performing surgery. A myoma growing in the posterior wall region was found and subsequently removed. It measured about 20 cm in size [Figure 1]. The myoma was necrotic and had minimal hemorrhage. The gall bladder was examined and found to have no problems. Reconstruction of the uterine wall was carried out using a two-layer catgut chromic 1.0 suture.

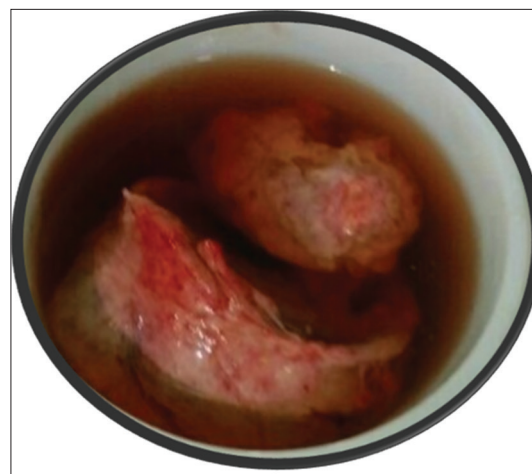


Figure 1: A large myoma removed from a patient in the middle of her pregnancy

Table 1: Patient's laboratory data in 20-week gestation

Variables	First hospitalization	Preoperative	Second postoperative	21 days later	89 days later	Normal range
WBC (×10 ⁹ /L)	11.60	13.12	12.50	14.99	13.32	4-10
Hb (g/dl)	12.6	13.5	10.1	12.0	13.5	12-17
CRP (mg/l)	57.5	43.9	97.1	9.8	-	Up to 6
Creatinine (mg)	0.7	-	0.6	-	0.77	0.6-1.4
ESR (mm/h)	78	83	77	44	-	Up to 20
AST (U/l)	52	63	26	51	15	Up to 31
ALT (U/l)	78	141	84	133	24	Up to 31
ALP (IU/l)	439	452	360	330	323	40-306

WBC: White blood cell, Hb: Hemoglobin, AST: Aspartate aminotransferase, ALT: Alanine aminotransferase, ALP: Alkaline phosphate, ESR: Erythrocyte sedimentation rate, CRP: C-reactive protein

The other small fibroid was observed but not removed. Estimated blood loss during the 60-min operation was estimated to be 200 cc.

Following leiomyoma removal, hemostasis was carefully achieved. Fetal monitoring by ultrasonography was carried out immediately after surgery, and the fetus was found viable. Antibiotics (cefazolin 2 g starting before surgery and then 1 g every 6 h) were administered to the patient. Postoperative period was uneventful, and the patient was given tocolytics for 3 days with uterine relaxants and 17-OH progesterone.^[10,11] This continued till the 36th week. On postoperative day 2, liver function test was carried out.

The patient was discharged on the 4th postoperative day. The operation was followed with ultrasonography every 4 weeks till the 38-week gestational age. Spontaneous labor of the patient at 39 weeks and 1 day led to vaginal delivery of fetus weighing 2.900 kg. Both the patient and her baby were allowed to leave after 48 h. A subsequent postnatal visit turned out to be normal.

Discussion

The performance of myomectomy during pregnancy is very much debated. As an example, surgical removal of uterine leiomyoma is not generally performed before delivery; rather, it is postponed until after labor. There is evidence that mortality and morbidity are slightly higher for myomectomy in the gravid uterus as compared to the nongravid uterus.^[12] Additional to the general risks of myomectomy, the risk of abortion should be considered. It happens in 18%–35% of cases.^[13] Severe endometritis occurs in the case of incomplete abortion. This is especially true when a communication channel to a recently enucleated fibroid bed is present.^[12]

A successful myomectomy in India was reported by Jhalta *et al.*,^[1] in which a woman with a large abdominopelvic mass was operated during early stages of pregnancy. It describes laparotomy performed at the 13 weeks and 2 days of gestation age. It was deemed necessary due to the large size of the abdominopelvic mass. This pregnancy ended in the delivery of a healthy fetus validating the appropriateness of the early myomectomy. There are also reports on late myomectomy. An example is a report from Singapore that signifies the importance of myomectomy during cesarean section.^[14]

A study by Mollica *et al.*^[15] included 106 women with recurrent abdominal pain. Of these, 18 women underwent myomectomy. These had superior outcomes compared with those who were managed conservatively. The authors concluded that gestational age did not matter for these cases. Evidence were presented that indicate higher pregnancy losses (13.6%) in conservatively managed women compared to those who underwent myomectomy. The latter women also did better in terms of premature rupture of membranes, premature labor, and postcesarean hysterectomy.

The performance of myomectomy during cesarean section has recently increased in numbers. However, myomectomy during pregnancy is rare. Surgery is appropriate if the patient is in severe pain and does not respond to conventional medication. In fact, if the pharmacological treatment is not effective in alleviating the symptoms in 72 h, surgical intervention must be considered.^[3,4,9] In the case reported here, the patient had increased the size of myoma and elevated liver pressure symptom; however, her creatinine level was normal during all durations of pregnancy. In patients like the one reported here, emergency surgery is important. There is a need for selecting the best time of gestation for myomectomy. The risk of degeneration and torsion of myoma outweighs the morbidity and mortality associated with the surgery.

In Italy, Domenici *et al.*^[2] reported a patient undergoing myomectomy during pregnancy. The cause was extrinsic compression of the lower part of the ureter with involvement of the initial portion of the ureters. The patient had increased the value of serum creatinine (1.6 mg/dL) and a mild bilateral dilatation of the renal pelvis (2 cm on the right-hand side and 3.5 cm on the left). In comparison, our 26-year-old woman was admitted to our center for fertility and conservative treatment for myomas. Although our patient was asymptomatic at first, other symptoms forced us to conduct laparotomy. These included abdominal pain, leukocytosis, rise of inflammatory markers (ESR and CRP), liver enzymes that checked serial, increasing size of myoma, and possibility of its torsion and septic necrosis.

The results of this study are consistent with the success of myomectomy performed on a 30-year-old primigravida in Nigeria.^[16] The decision to perform the myomectomy, as reported by Umerzurike *et al.*,^[16] was based on the size of the tumor and the condition of the patient. The authors remarked on the safety of the procedure due to the ease of fibroid removal and minimal measures taken to obtain hemostasis. Myomectomies performed during cesarean has been studied for eight women in Oman by Machado *et al.*^[17] They concluded that patient selection is crucial since large fundal intramural fibroids should be avoided. They recommended a few measures to mitigate blood loss including balloon catheters, uterotonic drugs, and uterine artery ligation. A list of ten recommendations is presented by Vilos *et al.*^[18] for the management of uterine leiomyomas.^[18] Like our conclusion, it suggests that the treatment of uterine myomas must be individualized based on symptomatology, size and location of fibroids, and age among many other factors.

Conclusions

Based on the outcomes of this study and the findings of other researchers, it is concluded that when myomectomy is performed in carefully selected patients, it prevents sepsis due to myoma torsion and necrosis and also protects surrounding organs against damage according to the literature.

Declaration of patient consent

The authors certify that they have obtained all appropriate patient consent forms. In the form the patient(s) has/have given his/her/their consent for his/her/their images and other clinical information to be reported in the journal. The patients understand that their names and initials will not be published and due efforts will be made to conceal their identity, but anonymity cannot be guaranteed.

Financial support and sponsorship

Nil.

Conflicts of interest

There are no conflicts of interest.

References

- Jhalla P, Negi SG, Sharma V. Successful myomectomy in early pregnancy for a large asymptomatic uterine myoma: Case report. *Pan Afr Med J* 2016;24:228.
- Domenici L, Di Donato V, Gasparri ML, Lecce F, Caccetta J, Panici PB. Laparotomic myomectomy in the 16th week of pregnancy: A case report. *Case Rep Obstet Gynecol* 2014;2014:154347.
- Lolis DE, Kalantaridou SN, Makrydimas G, Sotiriadis A, Navrozoglou I, Zikopoulos K, *et al.* Successful myomectomy during pregnancy. *Hum Reprod* 2003;18:1699-702.
- Pelissier-Komorek A, Hamm J, Bonneau S, Derniaux E, Hoeffel-Fornes C, Graesslin O, *et al.* Myoma and pregnancy: When medical treatment is not sufficient. *J Gynecol Obstet Biol Reprod (Paris)* 2012;41:307-10.
- Vitale SG, Tropea A, Rossetti D, Carnelli M, Cianci A. Management of uterine leiomyomas in pregnancy: Review of literature. *Updates Surg* 2013;65:179-82.
- Müller Vranjes A, Sijanović S, Vidosavljević D, Kasac Z, Abicic Zuljević K. Surgical treatment of large smooth muscle tumor of uncertain malignant potential during pregnancy. *Med Glas (Zenica)* 2011;8:290-2.
- Basso A, Catalano MR, Loverro G, Nocera S, Di Naro E, Loverro M, *et al.* Uterine fibroid torsion during pregnancy: A case of laparotomic myomectomy at 18 weeks' gestation with systematic review of the literature. *Case Rep Obstet Gynecol* 2017;2017:4970802.
- Suwandinata FS, Gruessner SE, Omwandho CO, Tinneberg HR. Pregnancy-preserving myomectomy: Preliminary report on a new surgical technique. *Eur J Contracept Reprod Health Care* 2008;13:323-6.
- Michalas SP, Oreopoulou FV, Papageorgiou JS. Myomectomy during pregnancy and caesarean section. *Hum Reprod* 1995;10:1869-70.
- Kasum M. Hemoperitoneum caused by a bleeding myoma in pregnancy. *Acta Clin Croat* 2010;49:197-200.
- Exacoustòs C, Rosati P. Ultrasound diagnosis of uterine myomas and complications in pregnancy. *Obstet Gynecol* 1993;82:97-101.
- Myerscough P. Pelvic Tumors; Other Surgical Complications. *Munro Kerr's Operative Obstetrics*. 10th ed.. London: Cassel and Collier Macmillan; 1987. p. 203-11.
- Glavind K, Palvio DH, Lauritsen JG. Uterine myoma in pregnancy. *Acta Obstet Gynecol Scand* 1990;69:617-9.
- Omar SZ, Sivanesaratnam V, Damodaran P. Large lower segment myoma – Myomectomy at lower segment caesarean section – A report of two cases. *Singapore Med J* 1999;40:109-10.
- Mollica G, Pittini L, Minganti E, Perri G, Pansini F. Elective uterine myomectomy in pregnant women. *Clin Exp Obstet Gynecol* 1996;23:168-72.
- Umezurike C, Feyi-Waboso P. Successful myomectomy during pregnancy: A case report. *Reprod Health* 2005;2:6.
- Machado LS, Gowri V, Al-Riyami N, Al-Kharusi L. Caesarean myomectomy: Feasibility and safety. *Sultan Qaboos Univ Med J* 2012;12:190-6.
- Vilos GA, Allaire C, Laberge PY, Leyland N; Special Contributors. The management of uterine leiomyomas. *J Obstet Gynaecol Can* 2015;37:157-78.