



Case report: Aquarium palytoxin induced keratoconjunctivitis

Kathleen M. MacMillan^{a,b}, Vijay Sharma^{d,*}, Nir Shoham-Hazon^{b,c,d}

^a Dalhousie Medicine New Brunswick, 100 Tucker Park Rd. P.O. Box 5050, Saint John, NB, E2L4L5, Canada

^b Dalhousie University, Faculty of Medicine, 5839 University Ave, Halifax, NS, B3H4R2, Canada

^c Memorial University of Newfoundland, Faculty of Medicine, P.O. Box 4200, Saint John's, NL, A1C5S7, Canada

^d Horizon Health Authority, Miramichi Regional Hospital, 500 Water St, Miramichi, NB, E1V 3G5, Canada

ARTICLE INFO

Keywords:

Palytoxin
Coral
Keratoconjunctivitis
Ophthalmology
Treatment

ABSTRACT

Purpose: This case report describes the therapeutic management of a 61-year-old male who experienced aquarium coral keratoconjunctivitis caused by exposure to palytoxin and provides an additional resource to raise awareness and treat patients with ocular exposure to palytoxin.

Observations: A 61-year-old male inadvertently touched his left eye while cleaning an aquarium. Within 24 hours, pain, redness and visual blurring was noted. After 48 hours his best corrected visual acuity was measured at 20/25 on the right eye and 20/200 on the left. A thick mucopurulent discharge was present with associated conjunctival edema. The corneal epithelium was denuded centrally and inferiorly with subepithelial infiltrates peripherally. The patient was treated with topical moxifloxacin (0.5%) drops 6x/day and prednisolone acetate (1%) 4x/day. He was seen for follow up 48 hours later with a significant improvement in discomfort. Vision had improved to 20/60 with resolution of conjunctival edema, partial corneal epithelialization and reduced erythema. Cultures for culture and sensitivity returned as normal. The patient's steroid regime was gradually tapered during reassessments at four and ten days by which time the left eye acuity had returned to 20/25 with no symptoms. Therapy was discontinued with the exception of artificial tears. The patient continued to do well at his 42-day follow-up appointment with persistent corneal epithelialization, absence of infiltrates and a stable visual acuity of 20/25 in the affected eye. His local optometrist confirmed that the acuity was consistent with measurements obtained prior to the insult.

Conclusions: The combination of moxifloxacin eye drops and prednisolone acetate eye drops were effective in treating the patient's aquarium coral keratoconjunctivitis as after being treated the patient regained his baseline visual acuity in the affected eye (best corrected visual acuity of 20/25).

Importance: Currently, there are only a handful of case-reports published on ocular exposure to palytoxin. This case report will add to the literature by providing an additional resource for health care providers, in the treatment of patients with ocular exposure to palytoxin and increasing awareness to this rare condition.

1. Introduction

This case report describes the therapeutic management of a 61-year-old male who experienced aquarium coral keratoconjunctivitis caused by exposure to palytoxin and provides an additional resource to raise awareness and treat patients with ocular exposure to palytoxin. People who own aquariums may also own zoanthids, a type of coral (Fig. 1). However, certain zoanthids produce a potentially lethal neurotoxin known as palytoxin.^{1,2} Palytoxin is a potent vasoconstrictor³ and can cause toxicity through many different routes including via oral, dermal, and ocular exposure.¹ Although ocular and dermal exposure to palytoxin

are non-lethal, they are known to have serious effects including producing symptoms such as angina-like chest pain, asthma-like breathing difficulties, and alterations in the electrocardiogram (elevated T wave) which can result in death.¹ Case reports have shown that ocular exposure to palytoxin can cause a loss of visual acuity,^{4,5} corneal toxicity,⁵ conjunctival hyperemia,⁴ ocular pain,^{4,5} and photophobia⁵ among other problems.

Aquarium coral keratoconjunctivitis occurs when palytoxin infects the eye.⁴ The literature shows that there are very few case-reports published on ocular exposure to palytoxin.

* Corresponding author. Miramichi Regional Hospital, 500 Water St, Miramichi, NB, E1V 3G5, Canada.

E-mail address: vsharm@nbnet.nb.ca (V. Sharma).

<https://doi.org/10.1016/j.ajoc.2022.101326>

Received 8 January 2021; Received in revised form 3 September 2021; Accepted 20 January 2022

Available online 22 January 2022

2451-9936/© 2022 The Authors.

Published by Elsevier Inc.

This is an open access article under the CC BY-NC-ND license

(<http://creativecommons.org/licenses/by-nc-nd/4.0/>).



Fig. 1. Photograph of patient's zoonthid coral which can produce palytoxin.

2. Case report

A 61-year-old male inadvertently touched his left eye while cleaning an aquarium (Fig. 2). Within 24 hours, pain, redness and visual blurring was noted. He presented to his family physician 48 hours later and was promptly referred to ophthalmology for an urgent same day consultation. The acute examination took place in an emergency department setting with inability to take ancillary imaging. Best corrected visual acuity was measured at 20/25 on the right eye and 20/200 on the left. A thick mucopurulent discharge was present with associated conjunctival edema. The corneal epithelium was denuded centrally and inferiorly with subepithelial infiltrates peripherally. The patient was treated with topical moxifloxacin (0.5%) drops 6x/day and prednisolone acetate (1%) 4x/day. He was seen for follow up 48 hours later with a significant improvement in discomfort. Vision had improved to 20/60 with resolution of conjunctival edema, partial corneal epithelialization and reduced erythema. Cultures for culture and sensitivity returned as normal. At four days post treatment, the cornea was fully epithelialized



Fig. 2. Photograph of patient's aquarium that caused palytoxin exposure.

with a very small zone of residual superficial punctate keratitis. The patient's steroid regime was gradually tapered during reassessments at four and ten days by which time the left eye acuity had returned to 20/25 with no symptoms. Therapy was discontinued with the exception of artificial tears. The patient continued to do well at his 42-day follow-up appointment with absence of infiltrates and a stable visual acuity of 20/25 in the affected eye. His local optometrist confirmed that the acuity was consistent with measurements obtained prior to the insult. Images of the affected eye were obtained approximately one year after the initial exposure to palytoxin (Fig. 3).

3. Discussion

There are relatively few case-reports published on ocular exposure to palytoxin. A recent review by Barrett et al. found that only 19 cases of ocular exposure to palytoxin were reported in the literature. Of those cases, 14 were treated with steroids and 17 were treated with antibiotics. The patients had varying outcomes with four having best-corrected visual acuity of 20/100 or worse, and nine having best-corrected visual acuity of 20/25 or better.⁶

Farooq et al. presented an extreme case of palytoxin exposure with an initial visual acuity of 5/200 in the left eye with conjunctival injection and corneal melt. After treatment with antibiotics, steroids, amniotic membrane, doxycycline and an anterior lamellar patch graft the visual acuity of the patient improved to 20/100.⁵ However, the findings from our case are similar to a case of ocular palytoxin exposure described by Moshirfar et al. in which three days after initial exposure, the patient's visual acuity decreased to 20/125 in the left eye. This was treated with moxifloxacin drops, prednisolone drops, fluorometholone ointment, oral doxycycline and oral ascorbic acid after which visual acuity increased to 20/30.⁴

Although the exact mechanism(s) of palytoxin toxicity in humans is unknown, it appears to cause dysregulation of ion pumps, notably the Na⁺,K⁺-ATP pump,⁷ which may result in cell death⁸ with associated keratitis and epithelial edema.⁹ Further, palytoxin may slow the process of epithelial healing.

Macrophages are well known to initiate, maintain, and resolve inflammatory effects. It is suggested that palytoxin activates transcription factor NF- κ B and p38 MAPK, which encode pro-inflammatory proteins in macrophages.¹⁰ The macrophages are then likely to produce many cytokines, chemokines, and arachidonic metabolites which initiate inflammatory responses.¹⁰ Corticosteroids may be successful in the treatment of a palytoxin induced inflammation in the eye, as they can bind and inactivate proinflammatory transcription factors such as NF- κ B.¹¹ The combination of moxifloxacin eye drops and prednisolone acetate eye drops were chosen to treat the patient's aquarium coral keratoconjunctivitis. Moxifloxacin was utilized due to it being a broad spectrum antibiotic, having a preservative free formulation, and its ability to be used prophylactically, while prednisolone acetate was chosen due to its potency and bioavailability despite its effects on epithelial healing. The combination of moxifloxacin and prednisolone acetate were effective in treating the patient's aquarium coral keratoconjunctivitis as after being treated the patient regained his baseline visual acuity in the affected eye (best corrected visual acuity of 20/25). When deciding on the appropriate therapy, consideration was given towards bandage contact lens therapy but given the severity of inflammation and reasonable epithelialization, this treatment was withheld. Further, the use of a topical NSAID instead of prednisolone may be considered for cases with less intense inflammation as prednisolone may prolong epithelial healing.¹² When considering an NSAID, it is important to be aware of the potential for it to cause stromal melting and perforation. Other treatments for moderate and severe cases of ophthalmic palytoxin exposure may include doxycycline, valacyclovir, and ascorbic acid.⁵ Bandage contact lenses have also been used to supplement the treatment of ophthalmic palytoxin exposure,^{2,5} and amniotic membrane transplantation can also be considered.⁵

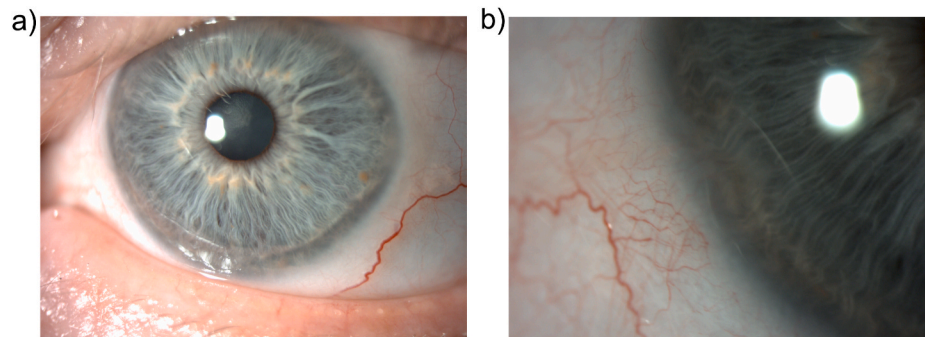


Fig. 3. Photographs of patient's cornea one year after being exposed to palytoxin.

Due to the risk of exposure to palytoxin, it has been previously recommended that patients use personal protective equipment like gloves and goggles when handling corals.⁵ In addition to this, we recommend educating patients to avoid touching their eyes when handling corals to further prevent exposure, and to practice proper handwashing technique after removing their gloves.

4. Conclusions

This case report will add to the literature by providing an additional resource for health care providers, in the treatment of patients with ocular exposure to palytoxin and increasing awareness to this rare condition.

Patient consent

The patient consented to the publication of the case in writing.

Ethics approval

This study received ethics approval from Horizon Health Network's Research Ethics Board (RS#: 2020-2947).

Funding

The Dalhousie Medical Students' Society Student Innovation and Research Award Committee paid the open access journal fees required to publish this article.

Authorship

All authors attest that they meet the current ICMJE criteria for Authorship.

Declaration of competing interest

N. Shoham-Hazon: Membership on advisory boards or speakers' bureaus; Name of for-profit or not-for-profit organization(s); Allergan, Bayer, B&L, Hexiris Pharma, IOptima, Iridex, Novartis.

The following authors have no financial disclosures: K.M. MacMillan, V. Sharma.

Acknowledgements

None.

References

1. Patocka J, Gupta RC, Wu Q, Kuca K. Toxic potential of palytoxin. *J Huazhong Univ Sci Technolog Med Sci.* 2015;35(5):773–780. <https://doi.org/10.1007/s11596-015-1506-3>.
2. Wonnerberger W, Claesson M, Zetterberg M. Corneal perforation due to palytoxin exposure of domestic zoanthid corals. *Acta Ophthalmol.* Published online August 25, 2020:aos.14594. doi:10.1111/aos.14594.
3. Sheridan RE, Deshpande SS, Adler M. Cytotoxic actions of palytoxin on aortic smooth muscle cells in culture. *J Appl Toxicol.* 2005;25(5):365–373. <https://doi.org/10.1002/jat.1080>.
4. Moshirfar M, Khalifa YM, Espandar L, Mifflin MD. Aquarium coral keratoconjunctivitis. *Arch Ophthalmol.* 2010;128(10):3.
5. Farooq AV, Gibbons AG, Council MD, et al. Corneal toxicity associated with aquarium coral palytoxin. *Am J Ophthalmol.* 2017;174:119–125. <https://doi.org/10.1016/j.ajo.2016.10.007>.
6. Barrett RT, Hastings JP, Ronquillo YC, Hoopes PC, Moshirfar M. Coral keratitis: case report and review of mechanisms of action, clinical management and prognosis of ocular exposure to palytoxin. *Clin Ophthalmol.* 2021;15:141–156. <https://doi.org/10.2147/OPTH.S290455>.
7. Rossini GP, Bigiani A. Palytoxin action on the Na⁺,K⁺-ATPase and the disruption of ion equilibria in biological systems. *Toxicol.* 2011;57(3):429–439. <https://doi.org/10.1016/j.toxicol.2010.09.011>.
8. Patocka J, Nepovimova E, Wu Q, Kuca K. Palytoxin congeners. *Arch Toxicol.* 2018;92(1):143–156. <https://doi.org/10.1007/s00204-017-2105-8>.
9. Moshirfar M, Hastings J, Ronquillo Y, Patel BC. Palytoxin keratitis. In: *StatPearls. StatPearls Publishing; 2020.* <http://www.ncbi.nlm.nih.gov/books/NBK553212/>. Accessed December 31, 2020.
10. Crinelli R, Carloni E, Giacomini E, et al. Palytoxin and an osteopsis toxin extract increase the levels of mRNAs encoding inflammation-related proteins in human macrophages via p38 MAPK and NF-κB. de Melo CB. *PLoS One.* 2012;7(6), e38139. <https://doi.org/10.1371/journal.pone.0038139>.
11. Brattsand R, Linden M. Cytokine modulation by glucocorticoids: mechanisms and actions in cellular studies. *Aliment Pharmacol Ther.* Published January 1, 1996. Accessed January 2, 2021. <https://onlinelibrary.wiley.com/doi/abs/10.1046/j.1365-2036.1996.22164025.x>.
12. Petroustos G, Guimaraes R, Giraud JP, Pouliquen Y. Corticosteroids and corneal epithelial wound healing. *Br J Ophthalmol.* 1982;66(11):705–708. <https://doi.org/10.1136/bjo.66.11.705>.