

Research Article

Open Access

Huan Xu, Rongzong Zheng, Jinhe Ying*

Bone tunnel impaction reduced the tibial tunnel enlargement

DOI 10.1515/med-2017-0016

received November 12, 2016; accepted April 6, 2017

Abstract: The purpose of this study was to investigate whether the bone tunnel impaction technique performed by dilators could dwindle the tibial tunnel enlargement after anterior cruciate ligament (ACL) reconstruction with hamstring tendon using both extracortical suspensory fixation devices at femoral and tibial site.

Thirty-one consecutive patients undergoing primary ACL reconstruction with the hamstring autograft were enrolled in this research. Patients were randomly allotted to group A (bone tunnel impaction technique using dilators) or group B (regular extraction bone tunnel drilling).

Results: The average follow-up was 16.2 months. The mean femoral tunnel widening was 1.05 mm and 1.02 mm respectively in group A and B. The mean tibial tunnel widening was 0.61 mm and 1.08 mm respectively in group A and B. There was no statistical difference for tunnel enlargement between the two groups at the femoral site ($P = 0.62$) but significant difference at the tibial site ($P < 0.0001$).

Conclusion: Bone tunnel impaction technique led to a reduction of tibial bone tunnel enlargement after ACL reconstruction with hamstring tendon using both extracortical suspensory fixation devices at femoral and tibial site.

Keywords: Bone tunnel enlargement; Anterior cruciate ligament reconstruction; Bone tunnel impaction

1 Introduction

Bone tunnel enlargement or tunnel widening (TW) following anterior cruciate ligament (ACL) reconstruction with hamstring tendon is a well-recognized phenomenon in the literature [1-3]. In spite of most studies showed no evidence of clinical correlation between this radiological phenomenon and poor clinical outcome [4], and thought that excessive tunnel widening may jeopardize revision surgery such as bone grafting of the tunnel on account of poor bone stock [5], a recent study demonstrated that femoral TW had a negative correlation with IKDC scores [6]. Till now, the aetiology of TW is ambiguous and is supposed to be a multifactorial process [7]. Biomechanical factors including “bungee jump effect”, “windshield-wiper effect” and “redirecting forces of the tendon graft at the tunnel entrance”, and biological factors involving access of synovial fluid with osteolytic cytokines within the bone tunnel play important roles in TW [4, 7].

The prevention of TW is still a dilemma and many surgical techniques have been introduced. Bone tunnel impaction technique, which is drilled with stepped routers or tapped with sequential dilators of incremental diameter, is thought to enhance insertion torque, pullout strength and bone quality of the tunnel walls [8]. Gokce et al. reported a reduced tibial tunnel widening by using compaction drilling technique in ACL reconstruction with gracilis and semitendinosus tendons fixed with transfixation at femoral site and an interference screw and tendon staple at tibial site [9]. In the study of TW after ACL reconstruction, the compaction drilling technique has been described in the literatures, but impaction technique performed by dilators has not been investigated.

Different mechanical fixation techniques can influence TW [10]. Compared with direct fixation, extracortical fixation techniques is more prone to develop TW [11]. In China, many ACL reconstruction still are performed with extracortical fixation techniques such as suspensory fixation technique (miniplate femorally, and mini-button tibially). However, there is no report about TW for bone impaction technique in ACL reconstruction with extracortical fixation techniques.

*Corresponding author: Jinhe Ying, Department of Joint Surgery, Lishui Central Hospital and Fifth Affiliated Hospital of Wenzhou Medical College, Lishui, Zhejiang 323000, P.R. China, E-mail: lszyxyjwkvip.163.com

Huan Xu, Rongzong Zheng, Department of Joint Surgery, Lishui Central Hospital and Fifth Affiliated Hospital of Wenzhou Medical College, Lishui, Zhejiang 323000, P.R. China

Hence, the purpose of this study was to investigate whether the bone tunnel impaction technique performed by dilators could dwindle the tunnel enlargement after ACL reconstruction with hamstring tendon using both extracortical suspensory fixation devices at femoral and tibial site. We designed and produced a set of bone tunnel dilators, and hypothesized that the bone tunnel impaction technique would diminish the TW compared with the conventional extraction drilling technique.

2 Materials and methods

2.1 Patients

31 patients (18 males and 13 females) affected by unilateral ACL rupture of the knee were underwent primary ACL reconstruction with the hamstring autograft by the same surgeon at Lishui Central Hospital and Fifth Affiliated Hospital of Wenzhou Medical College and Dou's Traumatology Hospital of Jinyun County, Zhejiang Province, China, between Jun 2013 and Mar 2015. The mean age of the patients was 31 years (range: 18-50). All patients accessed by medical history and physical examination (Lachman test and the pivot shift test) and magnetic resonance imaging (MRI) scan provided the informed consents before inclusion, and the research was approved by the institutional review board of the hospitals. The inclusion criteria were a unilateral ACL tear regardless of concomitant meniscal injury, a normal heterolateral knee. The exclusion criteria were concomitant posterior cruciate ligament injury or collateral ligament injury, knee dysfunction before injury. Patients were randomly allotted to group A or group B. Bone tunnel impaction technique using dilators was performed in group A, while regular extraction bone tunnel drilling in group B. There was no discrepancy of the demographic parameters in terms of age, gender, side between two groups (Table 1).

Table 1: Demographic parameters

	Group A	Group B
Age	30.5 (19 - 50)	31.4 (18 - 49)
Gender	10 male, 6 female	8 male, 7 female
Side	9 right, 7 left	10 right, 5 left

2.2 Surgical technique

After spinal or epidural anesthesia has been administered, the patient was placed supine, and the upper thigh was applied a tourniquet inflated to 60 Kpa after the extremity was prepared and draped. Routine diagnostic arthroscopy was performed through the anterolateral and anteromedial portals. After arthroscopic identification of the ACL rupture, articular cartilage pathology and meniscus pathology followed by repair or meniscectomy, and notch preparation of removal of the ACL and the femoral insertion site and preservation of the tibial remnant, the pes anserinus insertion was exposed subcutaneously through a 3-cm longitudinal anteromedial tibial incision 1.5 cm medial to the tibial tuberosity. We harvested both the semitendinosus and gracilis tendons as the diameter of the semitendinosus tendon sometimes did not meet the demand. The distal expanding insertions of the semitendinosus and gracilis tendons were separated and peeled off subperiosteally with a strip of 2- to 3-cm-long periosteum flap for the purpose of elongating the tendons. Then the semitendinosus and gracilis tendons were harvested consecutively using a tendon stripper with the knee flexed 90°, and striped off the remaining muscle with a scalpel. Both free ends of the tendons were whip stitched with No. 6 Ethibond sutures. The semitendinosus tendon was made 3-strand and the gracilis tendon was folded in half. Then the tendons were looped over a 1.2 cm-long mini-plate (Aesculap) to form a 5-stranded double-looped hamstring autograft. The length of the graft's loop was the length of the femoral tunnel minus the required length of the tendon in the femoral tunnel. The hamstring autograft was pretensioned under 80 N for at least 10 minutes, and the diameter of the pretensioned hamstring autograft was measured, which commonly varied from 7 to 9 mm. A mark of an absorbable suture was placed on the graft at a point. The interval between the point and the proximal end of the graft was 7 mm longer than the required length of the tendon in the femoral tunnel.

Through the anteromedial portal, the femoral tunnel was created first. A guidewire was placed on the posterior aspect of the intercondylar notch, oriented at the 10:30 position for the right knee and 1:30 for the left, and extended to the outer cortex from inside to outside with the knee flexed 120°. Then, a 4.5-mm-diameter tunnel was drilled along the guide wire, and the length of the tunnel was measured precisely. A femoral socket which depth was 7 mm longer than the required length of the tendon in the femoral tunnel was reamed with a cannulated drill the size of the graft. The established femoral tunnel should be

approximately 3 mm anterior to the posterior wall and 3 mm superior to the articular surface.

The knee extended 90° and the arthroscope was transposed from the anteromedial portal to anterolateral to prepare the tibial tunnel. The tibial aiming device with the angular setting of 55° was placed intraarticularly through the anteromedial portal, and anchored on the point 7 mm anterior to the peak of the medial spine. A tunnel angulated 45° to the long axis of the tibia was drilled by a guidewire, and the inner opening was protected by a clamp. In group A, the tibial tunnel was first reamed over the guidewire with a cannulated drill 2 mm smaller than the diameter of the graft, and then, dilated in sequential steps by increments of 0.5 mm each to the intended diameter by bone tunnel impaction technique using dilators (Figure 1). The bone tunnel dilator was made of medical stainless steel 317L and consists of a distal tapered tip mounted on the distal end of a shaft, a cylindrical shaft and a T-handle (Figure 2). In group B, the tibial tunnel was reamed with a cannulated drill the size of the graft.

A sutured loop was passed through the eyelet of the guidepin on one side, and passed through the femoral sided lead sutures of the graft on the other side, and pulled out the lateral thigh. The graft was pulled up through the tibial tunnel until the mark of the graft reached the inner aperture of the femoral tunnel, and then the miniplate

was flipped and toggled over the lateral cortical aperture. After full range of motion was manipulated by 20 times to precondition of the graft, the tibial sided lead sutures of the graft were passed through a mini-button (Aesculap) toggled over the outer aperture of the tibial tunnel approximately 4 cm beneath the joint line and 1.5 cm medial to the tibial tubercle. The tension and impingement of the graft and anterior drawer test were evaluated under arthroscopy. The wounds were sutured routinely.

2.3 Rehabilitation protocols

Postoperative swelling was controlled by cryotherapy using icepacks. In terms of deep venous thrombosis prophylaxis, low-molecular-weight-heparin (4000 IU, ih, qd,) or rivaroxaban (10 mg, qd, po) was prescribed for 2 weeks. The rehabilitation programs of the both groups were identical. The knee was locked in a full extension by a hinged knee brace with toe touch weight bearing and isometric quadriceps exercise for the first week. Knee flexion exercise and full weight-bearing were allowed since the second week. The range of motion (ROM) of the knee was progressed to 90 degrees at the second week, 120 degrees at 2 to 4 weeks, and >120 degrees after 4 weeks. The brace was locked at 0 degree during ambulation and rest, and removed at 8 weeks. Progressive functional activities such as jogging were scheduled into the

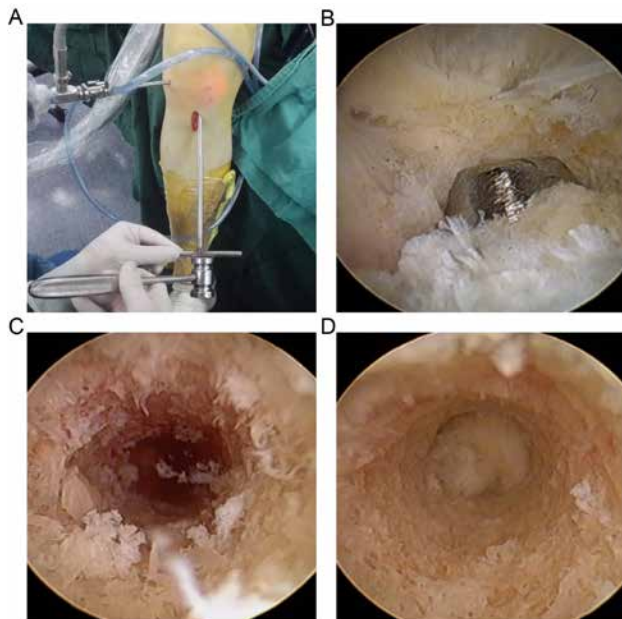


Figure 1: Dilation process. (A): Dilating the tibial tunnel; (B): The dilator passed through the tibial tunnel; (C): The inner tunnel wall was porous and littery before dilation; (D): After a series of expansion, the texture of the tunnel wall was close-grained and consolidated.



Figure 2: The Dilator. The dilator consists of a distal tapered tip mounted on the distal end of a shaft, a cylindrical shaft and a T-handle.

postoperative rehabilitation regime at 4 to 6 months after surgery. After 6 months, patients were allowed to return to sports activities.

2.4 Radiographic evaluation

The radiographic examination was arranged within one week postoperatively and at the final follow-up. Scanning ranged from a level above the femoral tunnel to a level below the tibial tunnel, using a 64-slice spiral CT scanner (Brilliance 64, Philips, Hamburg, Germany) at 120 kV, 220 mA, with a slice thickness of 0.5 mm, with multiplanar reformations in the axial, coronal and sagittal planes. The bone tunnel diameter was gauged by two blinded musculoskeletal radiologists using the ruler of a digitized picture archiving and communication system (PACS; General Electric, Chicago, IL), and assessed by calculating the width in millimeters between the inner rims perpendicular to the long axis of the tunnel. The femoral tunnel diameters were measured respectively on the axial and coronal sections at two points, notch (FA 1; FC 1) and middle (FA 2; FC 2) (Figure 3), and the tibial were on the sagittal and coronal sections at two points, plateau (TS 1; TC 1) and middle (TS 2; TC 2) (Figure 4). The enlargement was the difference of the tunnel width at the final follow-up minus the tunnel width within one week postoperatively.

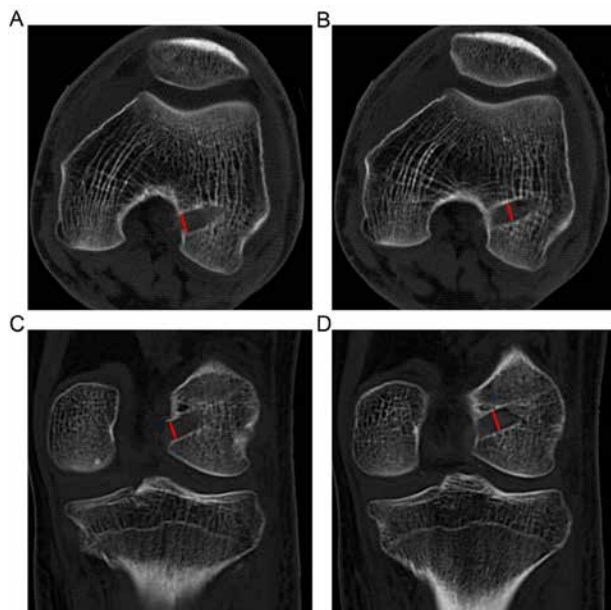


Figure 3: The measurement of the femoral tunnel diameter. (A): Notch on the axial section (FA 1); (B): Middle on the axial section (FA 2); (C): Notch on the coronal section (FC 1); (D): Middle on the coronal section (FC 2).

2.5 Clinical assessment

The clinical assessment consisted of the International Knee Documentation Committee (IKDC) score, the Lysholm score and Tegner activity scale (TAS), Lachman test, and pivot shift test, was performed preoperatively and at follow-up by the same surgeon. Anterior knee laxity was evaluated with Lachman test attributed to that, in China, most hospitals have not equipped with KT-1000, as well as ours.

2.6 Statistical analysis

Statistical analysis was conducted by SPSS 13.0 (SPSS, Chicago, IL) software and $P < 0.05$ was considered statistically significant. The demographic parameters were compared using Chi-Square Test. The amount of tunnel enlargement and clinical scores of two groups were compared through the Student's t test and the Mann-Whitney U test. The relationship between tunnel enlargement and quantitative clinical parameters was assessed by Spearman's rank correlation.

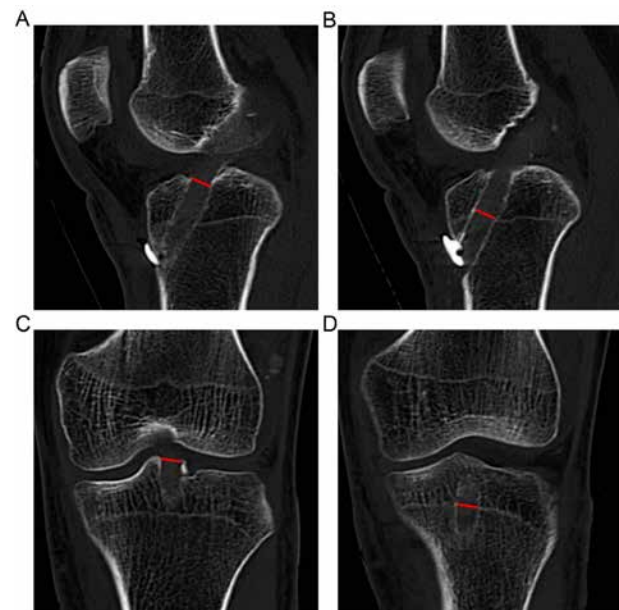


Figure 4: The measurement of the tibial tunnel diameter. (A): Plateau on the sagittal section (TS 1); (B): Middle on the sagittal section (TS 2); (C): Plateau on the coronal section (TC 1); (D): Middle on the coronal section (TC 2).

3 Results

All patients were followed up. The average follow-up was 16.2 months (range, 11 to 32 months) in group A and 16.8 months (range, 10 to 30 months) in group B.

3.1 CT measurement

In group A the average femoral tunnel diameter was increased from 7.89 mm (range 7 - 9.05 mm) to 8.94 mm (range 7.95 - 10.0 mm) ($P < 0.0001$) and the tibial tunnel from 7.88 mm (range 7.03 - 9.0 mm) to 8.49 mm (range 7.48 - 9.65 mm) ($P < 0.0001$) at follow-up compared to within one week postoperatively. In group B the average femoral tunnel diameter was increased from 7.89 mm (range 7.03 - 9.0 mm) to 8.92 mm (range 7.8 - 10.15 mm) ($P < 0.0001$) and the tibial tunnel from 7.9 mm (range 7.0 - 9.03 mm) to 8.99 mm (range 8.0 - 10.2 mm) ($P < 0.0001$) at follow-up compared to within one week postoperatively.

There was no statistical difference for the mean femoral ($P = 0.97$) or tibial ($P = 0.92$) tunnel width within one week postoperatively nor the mean femoral tunnel width at the final follow-up ($P = 0.93$) between the two groups, but significant difference for the mean tibial tunnel width ($P < 0.05$) between the two groups.

The increment of the mean femoral tunnel width was 1.05 mm (range 0.75 - 1.25 mm) and 1.02 mm (range 0.8 - 1.25 mm) respectively in group A and B. The increment of the mean tibial tunnel width was 0.61 mm (range 0.425 - 0.85 mm) and 1.08 mm (range 0.95 - 1.2 mm) respectively in group A and B.

There was no statistical difference for tunnel enlargement between the two groups at the femoral site ($P = 0.62$) but significant difference at the tibial site ($P < 0.0001$) (Figure 5).

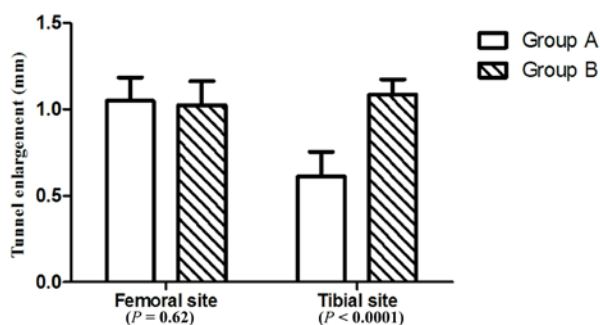


Figure 5: The mean tunnel enlargement (\pm SD). There was no statistical difference for tunnel enlargement between the two groups at the femoral site ($P = 0.62$) but significant difference at the tibial site ($P < 0.0001$).

3.2 Clinical outcomes

The clinical outcomes showed no cases of complications such as deep venous thrombosis, infections, arthrofibrosis, nerve injuries, knee extension limitation and failure of fixation.

All patients showed a negative pivot shift test. In group A and B, 15 and 13 cases had a normal Lachman test respectively, 1 and 2 cases had grade 1 Lachman test respectively. Based on the 2000 IKDC Knee Examination Form, 11 cases were graded as level C and 5 cases level D in group A, and 9 cases level C and 6 cases level D in group B preoperatively; 15 cases level A and 1 case level B in group A, and 13 cases level A and 2 cases level B in group B postoperatively. In group A, the mean IKDC subjective knee evaluation, Lysholm and TAS scores were 49.1 ± 3.74 , 46.75 ± 4.46 , 3.5 ± 0.81 , respectively, before surgery and 92.95 ± 2.84 , 93.75 ± 1.77 , 6.13 ± 0.62 , respectively, at the last follow-up; in group B, 48.58 ± 2.58 , 45.86 ± 3.48 , 3.46 ± 0.74 , respectively, before surgery and 92.49 ± 3.52 , 93.4 ± 2.02 , 6.0 ± 0.75 , respectively, at the last follow-up. In terms of the 2000 IKDC Knee Examination Form, the IKDC subjective knee evaluation, Lysholm and TAS scores, there were no statistical differences between the two groups.

There were no correlations between TW and clinical outcomes.

4 Discussion

The purpose of this study was to investigate the role of the bone tunnel impaction technique in reducing the tunnel enlargement after ACL reconstruction with hamstring tendon using both extracortical suspensory fixation devices at femoral and tibial site. We hypothesized that this technique of which was performed by our self-designed and developed bone tunnel dilators might decrease the TW compared with the conventional extraction drilling technique. The results of our study were confirmed. The tibial TW was significantly minimized in dilation group compared to extraction group, whereas the femoral TW showed no statistically difference between these two groups. As with other reports, no correlations were found between TW and clinical results [12]. The tunnel enlargement at femoral and tibial sites got different outcomes. The bone tunnel impaction technique obtained a good bone tunnel enlargement reduction effect. The femoral site was not dilated, and showed no difference in TW. The different results of the TW between tibial and femoral site

may due to the fact that we just applied dilation to the tibial tunnel.

Our findings were in line with Gokce's that impaction technique could diminish the tibial TW [9]. However, Rainer et al demonstrated that compaction drilling with a stepped router could not reduce TW at both tibial and femoral site after ACL reconstruction with hamstring tendon on the early postoperative period. One possible reason was their short follow-up (range 3.8 to 5 months). Currently there is no consensus about when TW occurs. Weber et al. reported an expansion in tunnel diameter at 6 weeks postoperatively and continued for 24 weeks, followed by a progressive contraction thereafter [13]. Peyrache et al. reported TW occurred at 3 months after surgery, and decreased at 3 years [13]. Buelow et al. demonstrated that the purely extracortical fixation protocol (Endobutton on the femoral side, and two Ethibond sutures on the tibial side) in ACL reconstruction using hamstring tendon significantly increased TW during the first 6 months postoperatively, and decreased it thereafter [11]. Hence, we can extrapolate that TW may transpire in the early postoperative period, and dwindle in Long-term follow-up. As a consequence, we performed a follow-up that averaged more than 1 year.

The fixation protocol plays an important role in TW [10]. Extracortical suspension fixation presented a higher risk than other fixation devices [5, 11, 14]. However, it is a widely used strategy in ACL reconstruction with hamstring tendon in our country, as it is cost-effective and simple. The femoral and tibial sites were fixed with a mini-plate and a mini-button respectively in this study.

We applied CT scanning to the bone tunnels to tease out TW rather than plain X-ray film and MRI scanning, because X-ray film can result in poor visibility and under-rating the tunnel expansion [15, 16], MRI scanning was more costly compared to CT scans.

Bone tunnel impaction technique was to tap a series of dilators with 0.5 mm of incremental diameters tapped into a pilot tunnel sized 2 mm smaller than graft diameter in tandem, thereby circumferentially compacting trabecular bone along the osseous inner wall. Dilation started with 1mm may lead to the fracture of the inlet and outlet of bone tunnel. To avoid this, we began at 0.5 mm and increased dilation by 0.5 mm. The use of dilators in ACL reconstruction is thought to enhance trabecular bone quality in the instantaneous purlieu of the reamed tunnel and increase pull-out strength of graft fixation [17, 18]. However, these effects remain controversial. The disagreement among studies may be multifactor, such as different biomechanical strength test protocols and dissimilar interference screw [18]. Arnoczky et al. showed

that compaction drilling enhanced pullout strength and insertion torque and increased cancellous bone density in the immediate vicinity of the implants located in the compaction dilated holes and a significant initial fixation strength of porous-coated implant in a canine model [8]. Cain et al. conducted a biomechanical cadaver study of which compared the pull-out strength of hamstring tendon in ACL reconstruction between the dilated and conventional reamed tibial tunnel specimens [17]. The dilated tibial tunnel was reamed 2 mm less than desired, followed by serial dilation using cannulated smooth dilators. The mean peak load of graft failure in impaction group was significantly higher than conventional group (616 N versus 453 N, $P = 0.0025$). Sørensen et al. compared the fixation strength of the graft-fixation-device complex using bovine digital extensor tendon anchored with Intrafix tibial fastener between traditional extraction drilling and compaction by serial dilation of the tibial tunnel in a bovine study utilizing hydraulic test machine and evaluated after cyclic loading [19]. They found the difference in slippage ranged from 0 mm at 70-220 N to 0.1 mm at 70-520 N, but no significant difference in slippage after 1,600 cycles. In another biomechanical study using human cadaveric tibiae, Nurmi et al. showed no significant difference between compaction drilling and conventional extraction drilling in trabecular bone mineral density and initial fixation strength of quadrupled hamstring tendon stabilized with bioabsorbable interference screw [20]. Rittmeister et al carried out a biomechanical cadaver study testing the effect of tibial tunnel dilation on the fixation strength of male human gracilis and semitendinosus tendon graft secured by interference screws using a servo-hydraulic mechanical testing machine [18]. The resistance of initial slippage and the failure load in dilated tibial tunnels were 11% and 4%, respectively, greater than undilated controls. They concluded that tibial tunnel dilation failed to significantly reinforce hamstring fixation and the benefits of dilation were related to achieving a preferable match of graft and tibial tunnel size, rather than melioration of bone quality of tunnel walls. While extraction drill removed the trabecula bone, our self-designed and made dilators had tapper tip which can compact and smooth the tunnel wall effectively and avoid the trabecula bone loss during the dilation procedure. The granulate trabecula bone of the inner tunnel wall was porose and littery before dilation (showed in Fig.1). During the process of dilation, the granules between the interface of the dilator and tunnel wall could be packed into any nook and cranny of the inner tunnel wall under the action of extrusion force. After a series of expansion, the texture of the tunnel wall was close-grained and consolidated (showed in Fig.1) and

the interface between the cylindrical graft and the tunnel wall may have a better match which supported the contention of Rittmeister et al.

To date, this is the first report on comparing bone tunnel enlargement after ACL reconstruction with hamstring tendon using both extracortical suspensory fixation devices at femoral and tibial site with bone tunnel impaction technique and the conventional extraction drilling technique in a CT-based analysis. It should be noted that our study is specific and unique for autologous hamstring tendon and this type of purely extracortical fixation, and the results may not be applied to other grafts or fixation devices. However, the bone tunnel impaction technique outlined in this article may have a potential application value in ACL reconstruction with direct fixation as it may make the tunnel wall better match the graft.

There are a few limitations of this study. First, it's important to note that the current study is based on a small sample size which may be a potential source of bias, and further research with larger samples may show a different outcome. However, we applied the identical graft, the same fixation devices, and the equal rehabilitation regimen but the tibial tunnel with different preparation to both groups. Furthermore, this study is a lack of long-term follow-up. Although the timeline for TW is indefinite, a longer follow-up may influence the results. Third, we did not analyze the bone mineral density, trabecular number, and trabecular thickness generated from CT scanning around the bone tunnel. These concerns may need to be addressed in the future studies. Finally, the tibial tunnel was just expanded 2mm in the current study, and there was no comparison among the different degrees of dilation.

To conclude, the present study demonstrated that bone tunnel impaction technique led to a reduction of tibial bone tunnel enlargement after ACL reconstruction with hamstring tendon using both extracortical suspensory fixation devices at femoral and tibial site after an average of over 1-year follow-up.

Acknowledgements; The present study was supported by the Medical and Health Science and Technology Plan Project of Zhejiang Province (grant no. 2014KYA232) and the Science and Technology Plan Project of Lishui City (grant no. 2014zdxk02).

Conflict of interests: No authors report any conflict of interest.

References

- [1] Mermerkaya MU, Atay OA, Kaymaz B, Bekmez S, Karaaslan F, Doral MN, Anterior cruciate ligament reconstruction using a hamstring graft: a retrospective comparison of tunnel widening upon use of two different femoral fixation methods, *Knee Surg Sports Traumatol Arthrosc*, 2015, 23, 2283-2291
- [2] Saygi B, Karaman O, Sirin E, Arslan I, Demir A, Oztermeli A, Comparison of different femoral fixation implants and fit techniques for tunnel widening and clinical outcome in ACL reconstruction using hamstring autograft, *Arch Orthop Trauma Surg*, 2016, 136, 241-247
- [3] Starantzis KA, Mastrokalos D, Koulalis D, Papakonstantinou O, Soucacos PN, Papagelopoulos PJ, The Potentially Positive Role of PRPs in Preventing Femoral Tunnel Widening in ACL Reconstruction Surgery Using Hamstrings: A Clinical Study in 51 Patients, *J Sports Med (Hindawi Publ Corp)*, 2014, 2014, 789317
- [4] Siebold R, Kiss ZS, Morris HG, Effect of compaction drilling during ACL reconstruction with hamstrings on postoperative tunnel widening, *Arch Orthop Trauma Surg*, 2008, 128, 461-468
- [5] Fauno P, Kaalund S, Tunnel widening after hamstring anterior cruciate ligament reconstruction is influenced by the type of graft fixation used: a prospective randomized study, *Arthroscopy*, 2005, 21, 1337-1341
- [6] Biswal UK, Balaji G, Nema S, Poduval M, Menon J, Patro DK, Correlation of tunnel widening and tunnel positioning with short-term functional outcomes in single-bundle anterior cruciate ligament reconstruction using patellar tendon versus hamstring graft: a prospective study, *Eur J Orthop Surg Traumatol*, 2016, 26, 647-655
- [7] Hwang DH, Shetty GM, Kim JI, Kwon JH, Song JK, Munoz M, Does press-fit technique reduce tunnel volume enlargement after anterior cruciate ligament reconstruction with autologous hamstring tendons? A prospective randomized computed tomography study, *Arthroscopy*, 2013, 29, 83-88
- [8] Green JR, Nemzek JA, Arnoczky SP, Johnson LL, Balas MS, The effect of bone compaction on early fixation of porous-coated implants, *J Arthroplasty*, 1999, 14, 91-97
- [9] Gokce A, Beyzadeoglu T, Ozyer F, Bekler H, Erdogan F, Does bone impaction technique reduce tunnel enlargement in ACL reconstruction? *Int Orthop*, 2009, 33, 407-412
- [10] Iorio R, Di Sanzo V, Vadala A, Conteduca J, Mazza D, Redler A, ACL reconstruction with hamstrings: how different technique and fixation devices influence bone tunnel enlargement, *Eur Rev Med Pharmacol Sci*, 2013, 17, 2956-2961
- [11] Buelow JU, Siebold R, Ellermann A, A prospective evaluation of tunnel enlargement in anterior cruciate ligament reconstruction with hamstrings: extracortical versus anatomical fixation, *Knee Surg Sports Traumatol Arthrosc*, 2002, 10, 80-85
- [12] Iorio R, Vadala A, Argento G, Di Sanzo V, Ferretti A, Bone tunnel enlargement after ACL reconstruction using autologous hamstring tendons: a CT study, *Int Orthop*, 2007, 31, 49-55
- [13] Weber AE, Delos D, Oltean HN, Vadasdi K, Cavanaugh J, Potter HG, Tibial and Femoral Tunnel Changes After ACL Reconstruction: A Prospective 2-Year Longitudinal MRI Study, *Am J Sports Med*, 2015, 43, 1147-1156
- [14] Sabat D, Kundu K, Arora S, Kumar V, Tunnel widening after anterior cruciate ligament reconstruction: a prospective randomized computed tomography--based study comparing

- 2 different femoral fixation methods for hamstring graft, *Arthroscopy*, 2011, 27, 776-783
- [15] Meuffels DE, Potters JW, Koning AH, Brown CJ, Verhaar JA, Reijman M, Visualization of postoperative anterior cruciate ligament reconstruction bone tunnels: reliability of standard radiographs, CT scans, and 3D virtual reality images, *Acta Orthop*, 2011, 82, 699-703
- [16] Fink C, Zapp M, Benedetto KP, Hackl W, Hoser C, Rieger M, Tibial tunnel enlargement following anterior cruciate ligament reconstruction with patellar tendon autograft, *Arthroscopy*, 2001, 17, 138-143
- [17] Cain EL, Phillips BB, Charlebois SJ, Azar FM, Effect of tibial tunnel dilation on pullout strength of semitendinosus-gracilis graft in anterior cruciate ligament reconstruction, *Orthopedics*, 2005, 28, 779-783
- [18] Rittmeister ME, Noble PC, Bocell JJ, Alexander JW, Conditt MA, Kohl HR, Interactive effects of tunnel dilation on the mechanical properties of hamstring grafts fixed in the tibia with interference screws, *Knee Surg Sports Traumatol Arthrosc*, 2001, 9, 267-271
- [19] Sorensen OG, Jakobsen BW, Kold S, Hansen TB, Soballe K, Serial dilation versus extraction drilling in anterior cruciate ligament reconstruction: a biomechanical study, *Knee Surg Sports Traumatol Arthrosc*, 2010, 18, 742-746
- [20] Nurmi JT, Kannus P, Sievanen H, Jarvinen M, Jarvinen TL, Compaction drilling does not increase the initial fixation strength of the hamstring tendon graft in anterior cruciate ligament reconstruction in a cadaver model, *Am J Sports Med*, 2003, 31, 353-358