

# Extruded Fracture Dislocation of Talus, A Rare and Devastating Injury. A Series of Five Cases

Tej Pratap Gupta<sup>1</sup>, Sanjay Kumar Rai<sup>2</sup>, Vineet Vij<sup>3</sup>, Arjun Gandotra<sup>4</sup>

## Learning Point of the Article:

The management of extruded fracture dislocation of Talus is time-dependent and involves meticulous planning for favorable outcome.

## Abstract

**Introduction:** Extrusion of the talus with fracture dislocation is a very rare and devastating ankle injury usually caused by high-energy impact. There is no common consensus on the management for this type of injury. We intend to report on our experiences with its management and outcomes.

**Case Report:** We received a total of five cases of extruded fracture dislocation of the talus between March 2016 and April 2020. All fracture talus was Hawkins Type IV fracture. All five patients were male with an age range between 18 and 54 years and have sustained an injury in road traffic accidents. They were managed with wound debridement, talar preservation open reduction, and internal fixation with an application of an external fixator for wound care. All were followed up for 2 years.

**Conclusion:** Extruded fracture dislocation of the talus is a rare and devastating ankle injury. Its management is time-dependent and involves meticulous planning for a favorable outcome.

**Keywords:** Extruded fracture dislocation of talus, devastating ankle injury, open talus fracture dislocation, ankle injury.

## Introduction

Extrusion of the talus with fracture dislocation is a very rare and devastating ankle injury usually caused due to a high-energy impact. The actual incidence of these cases is still not known. However, extrusion of the talus constitutes approximately 0.06% of all dislocations and 2% of all talar injuries [1,2]. There are multiple methods described, dependent on time of presentation since injury and vascular status, immediate fixation or reimplantation of the talus, talar replacement, or tibiocalcaneal arthrodesis. In the present literature, appropriate treatment guidelines are still debatable and controversial. Few authors advocating reimplantation of the extruded talus despite the high

chances of complications, such as post-operative infection, non-union of talus, avascular necrosis (AVN), osteoarthritis, and bone resorption. We did not find concrete evidence in the literature regarding talar reimplantation, which has high complication rates and difficult long-term outcome follow-up.

In the current literature available, the data are scanty regarding its classification, management, and outcomes. The mechanism of injury is excessive plantar flexion of the tibiotalar combined with extreme supination or pronation.

## Case Report

Our index case no 3 and 5 (index case, we called because all

Access this article online

Website:  
[www.jocr.co.in](http://www.jocr.co.in)

DOI:  
<https://doi.org/10.13107/jocr.2024.v14.i01.4126>

## Author's Photo Gallery



Dr. Tej Pratap Gupta



Dr. Sanjay Kumar Rai



Dr. Vineet Vij



Dr. Arjun Gandotra

<sup>1</sup>Department of Orthopaedics, Base Hospital, Guwahati, Assam, India,  
<sup>2</sup>Department of Orthopaedics, Military Hospital, Ambala, Haryana, India,  
<sup>3</sup>Department of Radiodiagnosis, Base Hospital, Guwahati, Assam, India,  
<sup>4</sup>Department of Orthopaedics, Dr. C Lal Hospital, Ambala Cantt, Haryana, India.

### Address of Correspondence:

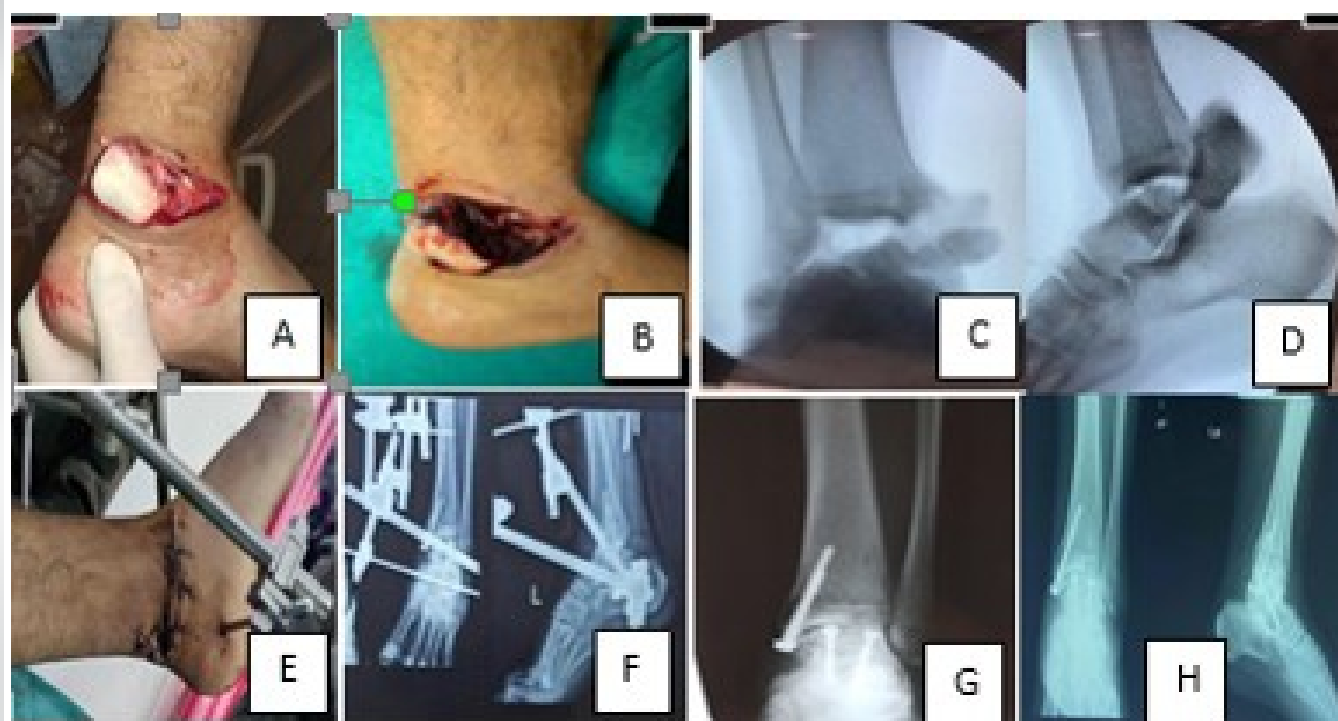Dr. S K Rai,  
Department of Orthopaedics, Military Hospital, Ambala, Haryana, India.  
E-mail: [skrai47@yahoo.com](mailto:skrai47@yahoo.com)

Submitted: 25/10/2023; Review: 12/11/2023; Accepted: December 2023; Published: January 2024

DOI: <https://doi.org/10.13107/jocr.2024.v14.i01.4126>

This is an open access journal, and articles are distributed under the terms of the Creative Commons Attribution-NonCommercial-ShareAlike 4.0 License <https://creativecommons.org/licenses/by-nc-sa/4.0/>, which allows others to remix, tweak, and build upon the work non-commercially, as long as appropriate credit is given and the new creations are licensed under the identical terms





**Figure 1:** Case no 3 – Pre-operative and post-operative pictures. (A and B) Pre-operative wound and extruded talus, (C and D) Pre-operative X-ray of ankle with extruded talus, (E) Post-operative wound closure and external fixator, (F) Post-operative X-ray showing internal and external fixation, (G and H) X-ray after removal of external fixator.

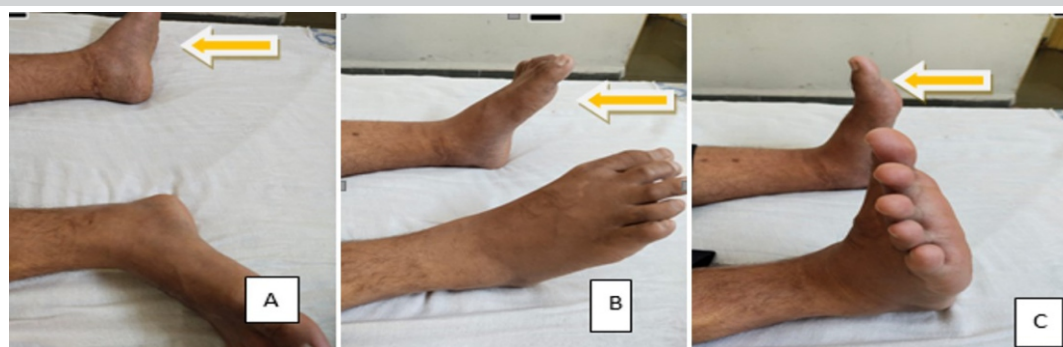
relevant pictures has been shown in this manuscript, whereas only data were included for remaining patients) involves a 39-year-old male patient with no significant medical history, who was presented to the emergency department with polytrauma due to a road traffic accident. He reported an episode of transient loss of consciousness after the accident and indicated feeling pain throughout the body, particularly severe in the right ankle, upper back, and right shoulder.

Physical evaluation revealed full consciousness, and alertness, with stable vitals and without any neurological deficits. Multiple abrasions and hematomas across the chest, shoulders, knees, and abdomen were noted. Over his left ankle, there was a 4 cm × 8 cm deep contaminated laceration wound over the

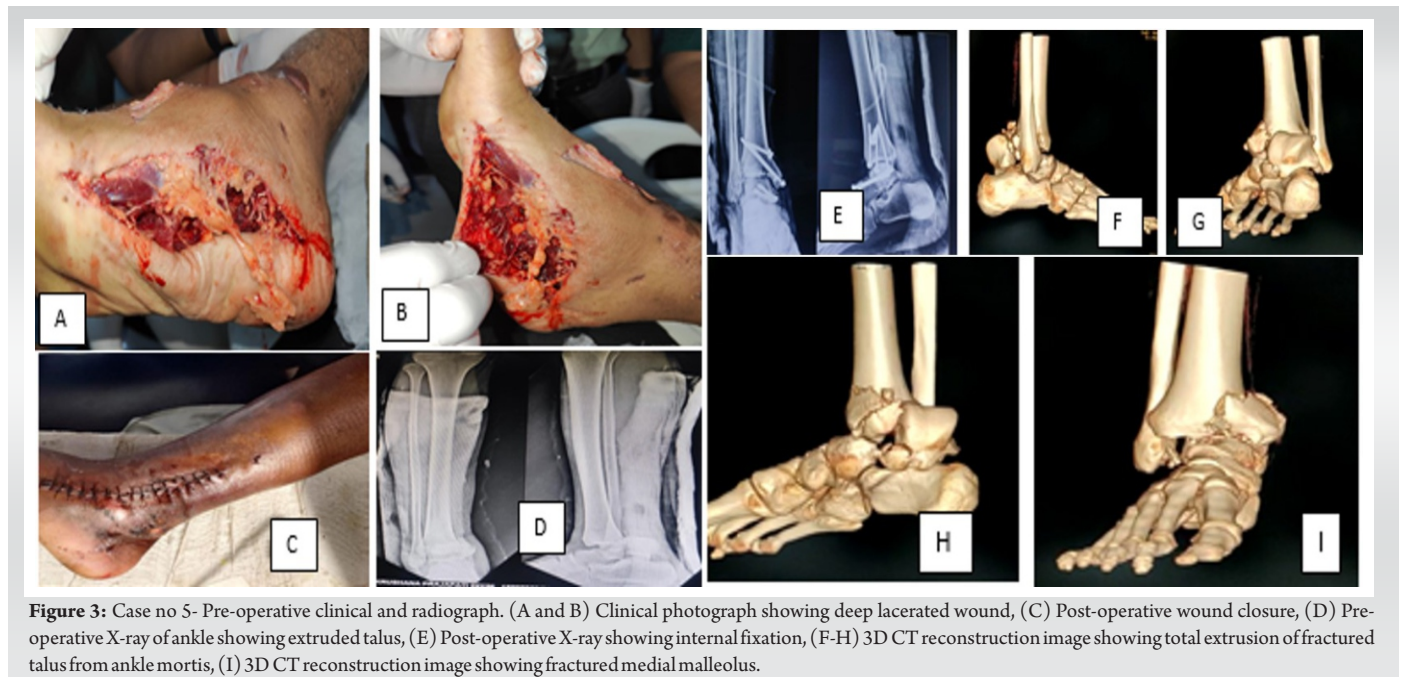
anterolateral aspect of the ankle with oozing blood (Gustilo-Anderson grade 3B wound). Extruded talus was lying outside of the ankle mortise on the lateral aspect of the ankle with a few attached soft tissues. Distal pulsation was present, and no neurological deficit was detected clinically. The wound was washed with a copious amount of saline and broad-spectrum antibiotics were administered. The wound was covered with sterile gauze and a posterior slab was applied.

Multiple radiological studies were performed, which revealed fractures of the right 3, 4, and 5th ribs, minimal haemothorax on the right, no intracranial abnormalities, and subcutaneous swelling throughout the left upper abdomen and right chest. Left ankle radiographs revealed extruded fracture dislocation

talus (Fig. 1). He was immediately admitted into surgery. Under spinal anesthesia debridement, relocation of the talus was performed, fixed with screws and K-wires along with an application of an external fixator for wound care (Fig. 1). The wound was loosely closed and was



**Figure 2:** Case no 3 – 12-month follow-up clinical picture showing range of ankle movement. (A) Healed post-operative wound, (B) Ankle plantar flexion, and (C) Ankle dorsiflexion.



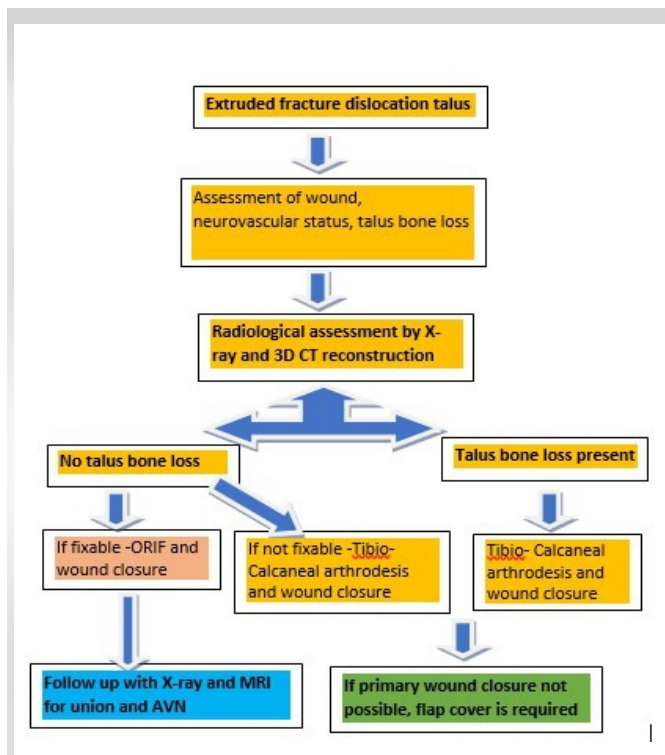
inspected every day. Intravenous antibiotics were administered based on the culture report for 2 weeks. The wound healed in 3 weeks and the external fixator was removed. Physiotherapy was performed thereafter, and the patient was discharged after 6 weeks. The patient was followed up at 6 months, 12 months, and finally at 2 years. On every visit X-ray, and CT scan was taken to record and monitor the talus fracture union and the

range of ankle movement (Fig. 2). Fifth patient (case no 5) of extrude talus was managed in similar way (Fig. 3). Our management algorithm is shown in Fig. 4. This algorithm may not be an ideal because management of this devastating injury depends on surgeon's experience, availability of reconstruction surgeon, vascular surgeon, patient requirements, and availability of various orthopedics implants. The demographical characteristics of all five patients are shown in (Table 1). All cases were able to achieve a satisfactory range of motion at the ankle after 12 months of follow-up (Table 2). Within 6–12 months, four cases achieved the union of fracture talus while case no 5 non-union. Two cases developed osteomyelitis. Painful subtalar joint was recorded in all cases (Table 3).

### Discussion

We have presented a series of cases with extruded fracture dislocation of talus. A review of the literature revealed only a few reports of similar cases attributable to the uncommon nature of the ailment. Isolated closed talar extrusions are rare, and the injury is often associated with medial or lateral malleoli fractures [3].

Open total talus extrusion without associated fractures around the ankle is a rare injury. In the literature search, the largest published series include 18 and 27 ankles [4, 5]. Many authors have reported a time-lapse of 30 min to 8 days between talar exposure and its reimplantation. They also noted that as this time increases, the possibility of wound infection, osteomyelitis, and AVN also increases [6, 7, 8, 9]. It has been noted that the reimplantation that is performed under 3 h has



**Figure 4:** Our management algorithm.



**Table 1: Demographical characteristics of all five patients**

Patient	1	2	3*	4	5**
Age	18	21	39	54	43
Sex	Male	Female	Male	Male	Male
BMI (kg/m <sup>2</sup> )	31.17±5.19	25.254±5.44	27.82±3.55	30.09±7.33	29.65±6.89
Side of involvements	Right	Right	Left	Right	Right
Hb (g%)	13.23	11.7	12.8	13.45	12.33
Type of implant used	Plate, screws and K-wire	Plate, screws and K-wires	Screws only	Screws and K-wires	Screws only
Initial wound swab	Growth present	Growth present	Growth present	Growth present	Growth present

\*Represents case no 3 (Refer to Figs. 1 and 2), \*\*Represents case no 5- (Refer to Fig. 3)

shown a good prognosis but any time after 3 h may lead to a poor outcome. In the case of an injury that has not been treated for over 24 h, it is recommended to consider tibio calcaneal arthrodesis. In a follow-up of 24 months, one patient developed an infection which was treated by repeated wound debridement and lavage and prolonged antibiotics, one patient developed chronic osteomyelitis of the distal tibia with prolonged discharging sinus which was managed by repeated joint lavage removal of implants and ankle joint arthrodesis. Joint stiffness was seen in one patient with a plantar and dorsi flexion was restricted by 10°.

It has been observed that hypoplasia medial malleolar, ligament laxity around the ankle joint, peroneal muscle weakness, repeated ankle sprains, and less soft tissue around the ankle, put talus at the risk for its dislocation [10]. Various types of talar dislocations were described by Fahey and Murphy, that is, anterior, posterior, medial, lateral, upward, and the

joint, followed by talonavicular and finally total talar extrusion [12]. Anterior and posterior tibial vessels provided a major blood supply to the talus along with perforating peroneal vessels [13]. Complete talar dislocation puts the talus in an avascular state and subsequently leads to AVN.

Management of complete talar extrusion is very challenging and complex too. There are no standard guidelines for the management of such a devastating injury in the literature. The literature review suggestions vary from primary talectomy to its reimplantation. In older days, immediate tibio calcaneal arthrodesis was usually considered in place of reimplantation [14-17]. Smith and Nork have supported reimplantation of the talus even if there is a risk of collapse because it can be a useful bone stock for secondary procedures if required [5]. Gerken et al. [17] suggested that ANV can be delayed with immediate reimplantation and follow-up care.

Open total talus extrusion is usually associated with fractures of either medial malleolus, lateral malleolus, or distal tibia fracture. These injuries are usually caused by high-energy impacts, like a motor vehicle accident and a fall from a height. Tibiotalar or subtalar dislocations may be associated with malleolar fractures until the talus is completely extruded laterally [8, 12].

Weston et al. in a systemic review noted favorable outcomes with reimplantation and suggested this method as a first-line treatment [18]. Many authors noted good outcomes with immediate reduction and salvage of the extruded talus. [19-21]. The good outcome was may be due to revascularization of talus noted by AlMaen et al. [20]

Complications such as infection and AVN are usually associated with such types of injury. It is noted that the talus is 60% covered with articular cartilage, without any muscle attachments, thus making the talus vulnerable to dislocation. Mohammad et al. [22] reported in their case report suggested that the prompt detection of extrusion of the talus is key and the outcome is time sensitive. Smrke et al. [23] in their case study on a 16-year-old man with totally extruded and lost talus, along with complex soft tissue injury around the ankle managed by microvascular foot reimplantation, microvascular muscle free flap transfer, temporary fixation, and later treated with tibio-calcaneal arthrodesis. Kasha and Yalamanchili [24] in their case report of talar extrusion with talar bone loss along with calcaneal fracture treated by masquelet technique in which he reconstructed the bony defect, debrided the wound, antibiotic bone cement was used as a spacer and the joints stabilized with K-wires and spanning external fixator was applied. A free flap cover was done to cover the defect and recorded a favorable outcome. Hichem et al. [25] recorded complete revascularization and satisfactory outcomes in a 30-year-old man after talus reimplantation following total talar extrusion. The key to a satisfactory

**Table 2: Summary of type of fracture, implant used, and ROM (ankle)**

Patient	Bone injuries	Implant used	ROM (ankle) after 12 months
1	Total extrusion of talus with fracture body along with medial and lateral malleolus fracture (Hawkins IV talus fracture)	Plate, screws and K-wires	DF: 0-10 PF: 0-40
2	Total extrusion of talus with fracture body along with medial and lateral malleolus fracture (Hawkins IV talus fracture)	Plate, screws and K-wires	DF: 0-10 PF: 0-30
3*	Total extrusion of talus with fracture body along with medial malleolus fracture (Hawkins IV talus fracture)	Screws only	DF: 0-15 PF: 0-30
4	Total extrusion of talus with fracture medial malleolus (Hawkins IV talus fracture))	Screws and K-wires	DF: 0-15 PF: 0-40
5**	Total extrusion of talus with fracture medial malleolus (Hawkins IV talus fracture)	Screws only	DF: 0-10 PF: 0-40

\*Represents case no 3 (Refer to Figs. 1 and 2), \*\*Represents case no 5 (Refer to Fig. 3)

combination [11]. Mechanism dislocation of the talus was described by Leitner first stage: Dislocation of the subtalar

**Table 3: Time of fracture union, and complications in all five patients**

Patients	1	2	3*	4	5**
Talus union achieved in months	9 months	7 months	8 months	8 months	-
Complication					
Infection	-	-	-	-	1
Delayed wound healing	-	-	-	-	-
Implant loosening	-	-	-	-	-
Osteomyelitis	1	-	-	-	1
Non-union	-	-	-	-	1
AVN talus till 2-year follow-up	-	-	-	-	-
Joint stiffness	-	1	-	--	1
Painful subtalar joint	1	1	1	1	1

\*Represents case no 3 (Refer to Figs. 1 and 2), \*\*Represents case no 5 (Refer to Fig. 3)



outcome is thorough wound debridement and fixation. The patient should be explained the risks of long-term complications.

### Limitation of the study

The present case series has few limitations firstly the short follow-up time of 2 years only where avascular necrosis of talus could not be assessed, secondly, the patients could not be recalled for follow-up after 2 years as they moved out or surgeon posted out from the hospital.

### Conclusion

The management of extruded fracture dislocation of the talus poses great challenges for young orthopedic surgeons. Due to the lack of guidelines in the literature, its management and

outcome depend on the availability of implants, and the expertise of the surgeon. Talus management is time-dependent and consists of thorough wound debridement, talar preservation, open reduction, and internal fixation with an external fixator for wound care. The multidisciplinary approach, which involves an orthopedic surgeon, plastic surgeon, radiologist, and sometimes vascular surgeon, is required for a satisfactory outcome.

### Clinical Message

The management of extruded fracture dislocation of talus is time sensitive. Its management consists of wound irrigation, thorough debridement, preservation of talus bone as much as possible, open reduction, and internal fixation with or without an external fixator for wound care. Patients should be well informed regarding the final outcome and associated complications.

**Declaration of patient consent:** The authors certify that they have obtained all appropriate patient consent forms. In the form, the patient has given the consent for his/ her images and other clinical information to be reported in the journal. The patient understands that his/ her names and initials will not be published and due efforts will be made to conceal their identity, but anonymity cannot be guaranteed.

**Conflict of interest:** Nil **Source of support:** None

### References

1. Van Opstal N, Vandeputte G. Traumatic talus extrusion: Case reports and literature review. *Acta Orthop Belg* 2009;75:699-704.
2. Kumar YC, Reddy S, Kumar Golla D, Ganesh N. Closed talar dislocation without associated fracture a very rare injury, a case report. *J Orthop Case Rep* 2014;4:10-2.
3. Hammouda A, El Rayes M, El Kordy S. Posteromedial dislocation of the ankle without fracture. *J Foot Ankle Surg* 2006;12:169-71.
4. Marsh JL, Saltzman CL, Iverson M, Shapiro DS. Major open injuries of the talus. *J Orthop Trauma* 1995;9:371-6.
5. Smith CS, Nork SE, Sangeorzan BJ. The extruded talus: Results of reimplantation. *J Bone Joint Surg Am* 2006;88:2418-24.
6. Montoli C, De Pietri M, Barbieri S, D'Angelo F. Total extrusion of the talus: A case report. *J Foot Ankle Surg* 2004;43:321-6.
7. Palomo-Traver JM, Cruz-Renovell E, Granell-Beltran V, Monzonís-García J. Open total talus dislocation: Case report and review of the literature. *J Orthop Trauma* 1997;11:45-9.
8. Hiraizumi Y, Hara T, Takahashi M, Mayehiyo S. Open total dislocation of the talus with extrusion (missing talus): Report of two cases. *Foot Ankle* 1992;13:473-7.
9. Pradhan A, Najefi A, Patel A, Vris A, Heidari N, Malagelada F, Parker L, Jeyaseelan L. Complications after talus fractures: A trauma centre experience. *Injury*. 2023 Feb 1;54(2):772-7.
10. Moehring HD, Tan RT, Marder RA, Lian G. Ankle dislocation. *J Orthop Trauma* 1994;8:167-72.
11. Fahey JJ, Murphy JL. Dislocations and fractures of the talus. *Surg Clin North Am* 1965;45:79-102.
12. Leitner B. The mechanism of total dislocation of the talus. *J Bone Joint Surg Am* 1955;37-A:89-95.
13. Mulfinger GL, Trueta J. The blood supply of the talus. *J Bone Joint Surg Br* 1970;52:160-7.
14. Dennis MD, Tullos HS. Blair tibiotalar arthrodesis for injuries to the talus. *J BJS*. 1980 Jan 1;62(1):103-7.
15. Canale ST. Fractures of the neck of the talus. *Orthopedics* 1990;13:1105-15.
16. Tezval M, Dumont C, Stürmer KM. Prognostic reliability of the Hawkins sign in fractures of the talus. *J Orthop Trauma* 2007;21:538-43.
17. Gerken N, Yalamanchili R, Yalamanchili S, Penagaluru P,

Milman EM, Cox G. Talar revascularization after a complete talar extrusion. *J Orthop Trauma* 2011;25:e107-10.

18. Weston JT, Liu X, Wandtke ME, Liu J, Ebraheim NE. A systematic review of total dislocation of the talus. *Orthop Surg* 2015;7:97-101.

19. Memisoglu K, Hürmeýdan A. Total extrusion of the talus in an adolescent: A case report. *J Am Podiatr Med Assoc* 2009;99:431-4.

20. AlMaen BN, ElMaghrby IS, AlNour MK, Alrefeidi TA, Abu Adas SM. Complete Revascularization of Reimplanted Talus After Isolated Total Talar Extrusion: A Case Report. *Cureus*. 2020 May 3;12(5):e7947.

21. Kwak, JM., Heo, SK. & Jung, GH. Six-year survival of reimplanted talus after isolated total talar extrusion: a case

report. *J Med Case Reports* 11, 348 (2017).

22. Mohammad HR, A'Court J, Pillai A. Extruded talus treated with reimplantation and primary tibiototalcaneal arthrodesis. *Ann R Coll Surg Engl* 2017;99:e115-7.

23. Smrke DM, Rožman P, Gubina B, Frangež I, Smrke BR, Arnež ZM. An uncommon treatment of totally extruded and lost talus: A case report. *J Med Case Rep* 2014;8:322.

24. Kasha S, Yalamanchili RK. The Masquelet technique in an extruded talus injury after open peri-talar dislocation- a case report. *Trauma Case Rep* 2021;36:100559.

25. Hichem I, Mohammed-Reda F, Hatem A, Mahdi G, Ali M. Outcomes of a reimplanted talus after a total open extrusion. *Cureus* 2020;12:e9678.

**Conflict of Interest:** Nil  
**Source of Support:** Nil

**Consent:** The authors confirm that informed consent was obtained from the patient for publication of this case report

#### How to Cite this Article

Gupta TP, Rai SK, Vij V, Gandotra A. Extruded Fracture Dislocation of Talus, A Rare and Devastating Injury. A Series of Five Cases. *Journal of Orthopaedic Case Reports* 2024 January;14(1): 5-10.