

Surgical treatment for primary premature ejaculation with an inner condom technique

Hai Wang, MD^a, Ming Bai, MD^b, Hai-Lin Zhang, MD^b, Ang Zeng, MD^{b,*}

Abstract

To explore a novel surgical treatment for primary premature ejaculation using an inner condom technique.

A total of 20 males with premature ejaculation, who admitted our andrology clinic from June 2016 to July 2017, were enrolled. By surgery, an inner condom made of acellular dermal matrix (ADM) was transferred to the subcutaneous pocket of the penis. The prolongation of intravaginal ejaculatory latency time (IELT) after the surgery was examined. The perioperative complications were also studied.

The surgical intervention significantly increased the average IELT in patients, from 0.67 to 2.37 min ($P=.009$). No serious perioperative complications and adverse psychosexual effects were seen. Patients could resume sexual activity 6 weeks after the surgery.

The novel inner condom using ADM is an effective and safe surgical treatment for males with premature ejaculation. The efficacy of this new treatment modality warrants further investigation in independent cohorts.

Abbreviations: ADM = acellular dermal matrix, IELT = intravaginal ejaculatory latency time.

Keywords: acellular dermal matrix, inner condom technique, intravaginal ejaculatory latency time (IELT), premature ejaculation

1. Introduction

Premature ejaculation is one of the common male sexual problems, with the reported prevalence rate of 20% to 30% in China.^[1] Subjects with premature ejaculation would have short intravaginal ejaculatory latency time (IELT) of less than 1 min. Personal distress and interpersonal difficulty were often experienced along with ejaculatory dysfunction.^[2] The cause of premature ejaculation could be multi-factorial, both physiologically and psychologically. Penile hypersensitivity was proposed to be 1 of the key pathologic mechanism of premature ejaculation.^[3] Reducing the sensitivity of skin and mucous membrane of penis is therefore believed to prolong the IELT in males with premature ejaculation.

In this study, we examined the efficacy of the penile implantation of acellular dermal matrix (ADM) in prolonging IELT. The findings would provide novel insights into the management of premature ejaculation.

Editor: Giuseppe Lucarelli.

The authors have no conflicts of interest to disclose.

^a Department of Urologic Surgery, ^b Department of Plastic and Reconstructive Surgery, Peking Union Medical College Hospital, Chinese Academy of Medical Sciences and Peking Union Medical College, Beijing 100730, People's Republic of China.

* Correspondence: Ang Zeng, Department of Plastic and Reconstructive Surgery, Peking Union Medical College Hospital, Chinese Academy of Medical Sciences and Peking Union Medical College, No. 41 Damucang Hutong, Xicheng District, Beijing 100730, People's Republic of China (e-mail: 13683507962@qq.com).

Copyright © 2019 the Author(s). Published by Wolters Kluwer Health, Inc. This is an open access article distributed under the terms of the Creative Commons Attribution-Non Commercial-No Derivatives License 4.0 (CCBY-NC-ND), where it is permissible to download and share the work provided it is properly cited. The work cannot be changed in any way or used commercially without permission from the journal.

Medicine (2019) 98:3(e14109)

Received: 10 August 2018 / Received in final form: 28 November 2018 /

Accepted: 18 December 2018

<http://dx.doi.org/10.1097/MD.00000000000014109>

2. Patients and methods

2.1. Patient characteristics

The present study recruited 20 males with premature ejaculation who admitted to our clinic between June 2016 and January 2017. All cases were diagnosed as primary (premature ejaculation occurred upon first sexual activity), and were refractory to conventional treatment administered by specialist clinics. Primary premature ejaculation was defined as the premature ejaculation occurred upon first sexual activity. Conventional therapy, serotonin reuptake inhibitors (eg, sertraline, Prozac, etc.), was used for more than a month in these patients and was ineffective. All patients showed no abnormalities at external genitals, testis, epididymis, and spermatic cord. The urine and prostatic fluid tests of all patients were normal. Blood tests were performed to assess various blood hormone levels (eg, luteinizing hormone, follicle-stimulating hormone, estradiol, testosterone, prolactin, etc.). Patients with disorders in endocrine system (eg, thyroid or hypothalamus disorder), prostatitis, unstable psychological state, or mental illness like depression were excluded. Patients with chronic disease or erectile dysfunctions were also excluded.

The intravaginal ejaculation latency time (IELT) of all patients before and after the surgical treatment were recorded using stopwatch. Generally, the initiation of sexual activity was recommended 8 weeks after surgery, but the condition of the fusion of acellular allogeneic dermis and self-tissue would also be considered to determine the time.

Perioperative parameters were also collected for analysis. Written informed consents were obtained from all participants, with the study design and protocol approved by the ethic committee of Peking Union Medical College Hospital.

2.2. Surgical treatment

Surgery was performed under local anesthesia with 2% Lidocaine. After the incision area was marked, a 2 cm transverse

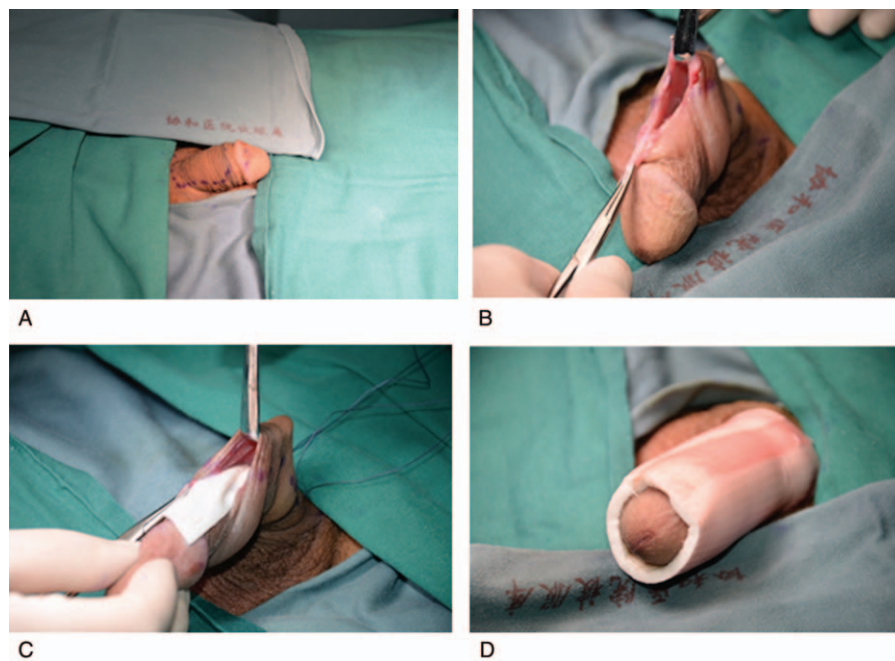


Figure 1. The original surgery implanting ADM as an inner condom for treatment of premature ejaculation is depicted. (A) The incision region on the penis was marked. (B) A 2 cm incision was made 1.5 cm proximal to the coronal sulcus, through which a sharp dissection was then carried out under the Buck fascia. (C) ADM was implanted into the subcutaneous pocket. (D) After the completion of the surgery the penis was immobilized with elastic bandage. ADM = acellular dermal matrix.

incision was made 1.5 cm proximal to the coronal sulcus, through which a sharp dissection was then carried out under the Buck fascia (Fig. 1A&B). To form the inner condom, a sheet of type J-1 ADM (4 × 6 cm) (Jayyalife Biological Technology, Beijing, China), was transferred to the subcutaneous pocket and fixed with vicryl sutures (Fig. 1C). The penis was immobilized with an elastic bandage for 7 days, with the sutures subsequently removed after 10 days (Fig. 1D).

2.3. Statistical analyses

The IELT before and after the surgical treatment was compared using student *t* test, with the significant difference indicated by a *P* value <.05.

3. Results

3.1. Patient enrolment

A total of 20 males diagnosed with primary premature ejaculation was recruited. The average age of the cohort was 33 years old (ranging 18–52 years), with an average course of disease of 12 years (ranging 1–32 years). Four males received circumcision.

3.2. Outcomes of the treatment

The average follow-up length was 6 months (ranging 2–12 months). Penile edema was observed at the first 2 to 4 weeks post-surgery. Except that, all males presented no other complications like abnormal incision healing, exposure of the implant, infection, hematoma, and seroma.

The surgical treatment significantly increased the IELT of the patients (*P* = .009). The IELT before and after the treatment was

0.67 min (ranging 0.18–1.1 min) and 2.37 min (ranging 0.82–8.4 min), respectively.

4. Discussion

The present study demonstrated for the first time the penile implantation of ADM could significantly prolong the IELT in males with clinically-diagnosed premature ejaculation. Patients did not show any serious perioperative complications and could resume sexual activity in a limited period as short as 6 weeks.

The etiology of premature ejaculation is multi-factorial, involving psychological factors, genetics, endocrinological and neuromodulating etiology.^[4,5] Among the different factors, the penile hypersensitivity is a key mechanism.^[3] As such, both pharmacological and surgical interventions originally aimed to make the glans penis less sensitive during intercourse have emerged as potential treatment modalities. For pharmacological intervention, topical anesthetic is the oldest known one with well-documented efficacy in prolonging the latency time of ejaculation. Despite its efficacy, the use of topical anesthetics was associated with penile hypoesthesia and transvaginal absorption, leading to vaginal numbness and female anorgasmia.^[6,7] For surgical intervention, selective resection of dorsal nerves of penis demonstrated an efficacy rate of 90%, and compared to pharmacologic agents, the effect of a single surgery was more long-lasting.^[8,9] Disappointedly, perioperative complications such as paraesthesia on the glans penis and erectile dysfunction were reported.^[10,11] Furthermore, given that the procedure is invasive and irreversible, and because the safety of this treatment modality remains to be determined, the International Society of Sexual Medicine's Guidelines for the Diagnosis and Treatment of Premature Ejaculation did not recommend the resection of dorsal nerves in premature ejaculation treatment.^[12] New treatments for premature ejaculation are urgently needed.

To fulfill the unmet medical needs, we developed the penile implantation of ADM as a promising approach to delay premature ejaculation. We utilized ADM because it is a human skin-derived biomaterial that shows a higher degree of biocompatibility than heterologous materials. The basement membrane complex of ADM also facilitates the attachment of fibroblasts and endothelial cells for vascular ingrowth, allowing excellent graft integration in the recipient tissue and neodermis formation. Furthermore, ADM elicits no immune responses because it does not express any major histocompatibility antigens, either class I or II. With these advantages, ADM is widely used in breast reconstruction,^[13] hernia repair, plastic surgery, such as rhinoplasty^[14] and lip augmentation,^[15] and penile surgery. Phalloplasty with ADM resulted in satisfactory penile augmentation with minimal morbidity.^[16] In another study consisting of 69 males, the penile girth enlargement with ADM demonstrated advantages in the elimination of donor site morbidity and a significantly reduction in operation time.^[17]

The surgical technique of the present study shared some similarities with circumcision in the site of incision and layer separation. Despite this, the delayed ejaculation was apparently not resulted from circumcision. A systematic meta-analysis showed that circumcision had no effect on premature ejaculation.^[18] We, therefore, believed it was the implanted ADM that reduced the cutaneous sensation of penis, preventing the hypersensitivity and so premature ejaculation.

The key advantage of our surgery is that it involved only the loose connective tissue of the superficial layer of tunica albuginea. Unlike dorsal nerve neurectomy, the process caused nearly no damages to blood vessel and nerve, eliminating the risk of developing paraesthesia of the glans, and preventing erectile dysfunction.^[19] Our surgery also allowed fast recovery. Males could resume sexual activity in 6 weeks after the surgery. Nevertheless, the long-term treatment outcome of the penile ADM implantation remains to be examined. In addition, the impact of the surgical intervention on the psychological status of males needs to be explored. The detailed underlying mechanism by which the penile ADM implantation prolonged IELT also has to be further studied.^[20]

The present study has several limitations. This was a single-center study, with a relatively small sample size. To validate this technique for application in clinical setting, a further study is needed. Additionally, patient's satisfaction was not evaluated in this study.

To summarize, we present encouraging results suggesting the penile implantation of ADM could significantly prolong the IELT in males clinically diagnosed with premature ejaculation. The surgery was associated with no serious perioperative complications, with patients could resume sexual activity in a short period after surgery. The usefulness of this new surgical intervention will be comprehensively explored in an independent cohort of the larger population.

Author contributions

Conceptualization: Ang Zeng.

Data curation: Hai Wang, Ming Bai, and Hai-Lin Zhang.

Formal analysis: Hai Wang, Ming Bai, and Hai-Lin Zhang.

Writing – original draft: Ang Zeng.

Writing – review & editing: Hai-Lin Zhang.

References

- [1] Gao J, et al. Prevalence and associated factors of premature ejaculation in the anhui male population in China: evidence-based unified definition of lifelong and acquired premature ejaculation. *Sex Med* 2017;5:e37–43.
- [2] Parnham A, Serefoglu EC. Classification and definition of premature ejaculation. *Transl Androl Urol* 2016;5:416–23.
- [3] Xin ZC, et al. Penile sensitivity in patients with primary premature ejaculation. *J Urol* 1996;156:979–81.
- [4] Zhang B, et al. Functional insights into aberrant brain responses and integration in patients with lifelong premature ejaculation. *Sci Rep* 2017;7:460.
- [5] Ventus D, et al. No evidence for long-term causal associations between symptoms of premature ejaculation and symptoms of anxiety, depression, and sexual distress in a large, population-based longitudinal sample. *J Sex Res* 2017;54:264–72.
- [6] Martyn-St James M, et al. Topical anaesthetics for premature ejaculation: a systematic review and meta-analysis. *Sex Health* 2016;13:114–23.
- [7] Hisasue S. The drug treatment of premature ejaculation. *Transl Androl Urol* 2016;5:482–6.
- [8] Zhang GX, et al. Selective resection of dorsal nerves of penis for premature ejaculation. *Int J Androl* 2012;35:873–9.
- [9] Yang DY, et al. Urologist's practice patterns including surgical treatment in the management of premature ejaculation: a Korean Nationwide Survey. *World J Mens Health* 2013;31:226–31.
- [10] Park HJ, et al. Penile traumatic neuroma: a late complication of penile dorsal neurotomy to treat premature ejaculation. *Sex Med* 2016;4:e221–4.
- [11] Martin C, et al. Current and emerging therapies in premature ejaculation: where we are coming from, where we are going. *Int J Urol* 2017;24:40–50.
- [12] Althof SE, et al. An update of the International Society of Sexual Medicine's guidelines for the diagnosis and treatment of premature ejaculation (PE). *J Sex Med* 2014;11:1392–422.
- [13] Maxwell GP, Gabriel A. Acellular dermal matrix for reoperative breast augmentation. *Plast Reconstr Surg* 2014;134:932–8.
- [14] Suh MK, et al. Augmentation rhinoplasty with silicone implant covered with acellular dermal matrix. *J Craniofac Surg* 2017;28:445–8.
- [15] Brown C, Watson D. Lip augmentation utilizing allogenic acellular dermal graft. *Facial Plast Surg* 2011;27:550–4.
- [16] Zhang JM, et al. Penile augmentation using acellular dermal matrix. *Zhonghua Zheng Xing Wai Ke Za Zhi* 2004;20:418–20.
- [17] Alei G, et al. Original technique for penile girth augmentation through porcine dermal acellular grafts: results in a 69-patient series. *J Sex Med* 2012;9:1945–53.
- [18] Yang Y, et al. Circumcision does not have effect on premature ejaculation: a systematic review and meta-analysis. *Andrologia* 2017;50:e12851.
- [19] Anaissie J, Yafi FA, Hellstrom WJ. Surgery is not indicated for the treatment of premature ejaculation. *Transl Androl Urol* 2016;5:607–12.
- [20] Sidi H, et al. Understanding the pathophysiology of premature ejaculation: bridging the link between pharmacological and psychological interventions. *Curr Drug Targets* 2016;19:856–64.