

Available online at [www.sciencedirect.com](http://www.sciencedirect.com)

ScienceDirect

Biomedical Journal

journal homepage: [www.elsevier.com/locate/bj](http://www.elsevier.com/locate/bj)

## Original Article

# Minimal invasive fixation following with radiotherapy for radiosensitive unstable metastatic spine

Jia-En Chi, Chun-Yee Ho, Ping-Yeh Chiu, Fu-Cheng Kao, Tsung-Ting Tsai\*, Po-Liang Lai, Chi-Chien Niu

Department of Orthopaedic Surgery, Spine Section, Bone and Joint Research Center, Chang Gung Memorial Hospital and Chang Gung University College of Medicine, Taoyuan, Taiwan

## ARTICLE INFO

## Article history:

Received 24 December 2020

Accepted 19 August 2021

Available online 24 August 2021

## Keywords:

Spinal metastasis  
Radiation therapy  
Minimally invasive surgery  
Percutaneous fixation  
Debulking  
Cord compression

## ABSTRACT

**Background:** Minimally invasive surgery (MIS) has become a feasible option for patients with spinal metastasis, but the effectiveness of percutaneous pedicle screw fixation (PPSF) without decompression in patients with severe cord compression remains unknown. We compared PPSF without decompression with debulking surgery in patients with radio-sensitive, unstable, metastatic thoracolumbar spinal cord compression.

**Methods:** A retrospective study of surgically treated spinal metastasis and spinal cord compression patients was conducted between October 2014 and June 2019. Demographic and pre- and postoperative data were collected and compared between patients treated with minimally invasive percutaneous fixation and external beam radiotherapy (EBRT) (the PPSF group) and those treated with debulking surgery (the debulking group).

**Results:** We included 50 patients in this study. The PPSF group had a significantly shorter operative time ( $143.56 \pm 49.44$  min vs.  $181.47 \pm 40.77$  min;  $p < 0.01$ ), significantly lower blood loss ( $116.67 \pm 109.92$  mL vs.  $696.55 \pm 519.43$  mL;  $p < 0.01$ ), and significantly shorter hospital stay ( $11.90 \pm 9.69$  vs.  $25.35 \pm 20.65$ ;  $p < 0.01$ ) than did the debulking group. No significant differences were observed between the groups in age, sex, spinal instability neoplastic score, ESCC, Tomita scores, numeric rating scale scores, American Spinal Injury Association Impairment Scale scores, survival rates, and complication rates. Postoperative neurologic function and decrease in pain were similar between the groups.

**Conclusion:** The PPSF group had a shorter operation time, shorter length of hospital stay, and less blood loss than did the debulking group. PPSF followed by EBRT is pain relieving, relatively safe and appropriate as palliative therapy.

\* Corresponding author. Department of Orthopaedic Surgery, Spine Section, Chang Gung Memorial Hospital, 5, Fusing St., Gueishan Dist., Taoyuan 333, Taiwan.

E-mail address: [tsai1129@gmail.com](mailto:tsai1129@gmail.com) (T.-T. Tsai).

Peer review under responsibility of Chang Gung University.

<https://doi.org/10.1016/j.bj.2021.08.004>

2319-4170/© 2021 Chang Gung University. Publishing services by Elsevier B.V. This is an open access article under the CC BY-NC-ND license (<http://creativecommons.org/licenses/by-nc-nd/4.0/>).

## At a glance commentary

### Scientific background on the subject

Minimally invasive surgery has shown to be useful treatment for patient with symptomatic spinal cord compression. However, no studies have proved that the effectiveness of percutaneous pedicle screw fixation without decompression or with mini-decompression in patients with unstable metastatic spinal cord compression.

### What this study adds to the field

This study shows that minimally invasive percutaneous pedicle screw fixation followed by external beam radiotherapy resulted in better surgical outcomes than debulking surgery in the treatment of metastatic thoracolumbar spinal cord compression, which suggests the proposed method is a pain relieving, relatively safe and appropriate palliative therapy.

Spinal metastasis, which is the major site of bone metastasis, can develop in 40% of patients with cancer [1]. In 10%–20% of patients with spinal metastasis, symptomatic epidural spinal cord compression (ESCC) occurs, which causes severe morbidity and mortality, with a median survival of 10 months [1–5]. Back pain is the earliest and most common symptom in 88%–95% of patients with metastatic spinal cord compression (MSCC) [2,6]. Other neurologic problems, such as motor weakness, numbness, and incontinence, are also noted in 70% of patients after treatment initiation [6].

Although no gold standard treatment exists, incurable spinal metastasis is usually managed palliatively. The primary goals of MSCC treatment are pain alleviation and preservation or restoration of stability and neurologic function [7]. External beam radiotherapy (EBRT) alone was once considered efficacious in relieving pain and improving neurologic function without a high incidence of spinal instability [8,9]. Surgical intervention is necessary only in cases of intractable pain, spinal instability, progressive neurologic deficit, and deformity [10]. Tokunishi et al. [11] developed a scoring system to classify surgical methods on the basis of prognosis. If metastasis is discovered early and considered curable, an *en bloc* procedure should be performed. If the scoring system reveals a poor prognosis, debulking and palliative resection are more suitable. A randomized controlled trial by Patchell et al. [5] demonstrated that direct surgical decompression with or without fixation followed by EBRT led to longer overall survival and better functional and neurologic outcomes in patients with high-grade MSCC. Therefore, a strong recommendation of surgery followed by EBRT was made in a 2011 updated systematic review and clinical practice guideline for the management of malignant metastatic ESCC [12]. The NOMS decision framework, which considers the neurologic,

oncologic, mechanical instability, and systemic disease aspects, incorporates evidence-based medicine and clinical experience with surgery, radiation therapy, interventional radiology, and systemic therapies for spinal metastasis. It helps determine patient prognosis, allows a thorough assessment of the patient, and facilitates decision making regarding treatment plans for patients with MSCC [13].

Because spinal metastases are hypervascular, one of the major sources of morbidity during resection is intraoperative blood loss. Open spinal metastasis resection involves a mean blood loss of 900–1534 mL, thus delaying the initiation of adjuvant therapy [14–16]. Moreover, this blood loss cannot usually be ceased until the tumor is resected [10,17]. Minimally invasive surgery (MIS) has now become a feasible option for patients with spinal metastasis. Percutaneous pedicle screw fixation (PPSF) with or without mini-decompression has a shorter operation time, shorter length of stay, and lower blood loss than open surgery, thereby lowering the risk of intraoperative complications. In addition, direct surgical decompression is increasingly being considered unnecessary. Recent studies have indicated that PPSF without decompression is as effective as conventional open surgery or PPSF with mini-decompression in relieving pain and restoring ambulation time with similar overall survival in patients with metastatic ESCC [16,18–21]. However, whether PPSF without decompression can be performed in patients with severe cord compression remains controversial. Here we compared the outcomes of PPSF without decompression with those of debulking surgery in patients with radiosensitive, unstable, thoracolumbar MSCC.

## Methods

### Patients

We reviewed the data of 160 consecutive patients with ESCC who underwent spinal surgery from October 2014 to June 2019. Inclusion criteria were as follows: (1) ESCC grade >1 with or without myelopathy, (2) Tomita score >5, (3) spinal instability neoplastic score (SINS) > 6, and (4) highly or moderately radiosensitive metastatic spinal tumor. Exclusion criteria were as follows: (1) lesion site around the cervical region, (2) possibility of treatment with vertebroplasty or kyphoplasty, (3) signs of acute neurologic deficits with rapid deterioration of neurologic functions within 2 weeks necessitating emergency surgical treatment, (4) loss to follow-up, (5) any of the following—unmanageable bleeding disorders; severe comorbidities of the heart, liver, kidney, or lung; intolerance to surgery; and decreased will to live. After applying the inclusion and exclusion criteria, 50 patients with MSCC were enrolled; of them, 21 underwent PPSF followed by EBRT (the PPSF group), and 29 underwent debulking surgery (the debulking group). The decision regarding the regimen or necessity of adjuvant therapy and/or EBRT was made by specialists after a thorough postoperative evaluation of the patients. After surgery, the clinical condition and surgical wound of the patient were closely assessed. When the patient's vital signs are stable, each patient was

evaluated by specialists for further medical treatments, and the treatment courses of adjuvant radiation therapy would be arranged by the oncologist and radiologist.

### Surgical intervention

With the patients in the prone position, general anesthesia was administered.

In the PPSF group, an incision was made using a paramedian approach. Percutaneous posterior instrumentation was inserted, followed by fixation with pedicle screws one or two levels above and below the lesion site under fluoroscopic guidance. Rods were then fixed under instrument guidance.

In the debulking group, the median approach was used. Laminectomy was performed at the lesion level, with wide tumor excision through intralaminar piecemeal resection without acquiring an excisional margin. Posterior pedicle screw fixation was then performed at one or two levels above and below the lesion site. After fixation, hemostasis was ensured. The surgical wound was irrigated with normal saline and then closed layer by layer. A Hemovac drain was used in the debulking group but not in the PPSF group.

### Clinical and Radiologic Evaluations

The patients' demographic and pre- and postoperative data, namely sex, age, Tomita score, SNIS, numeric rating scale (NRS) score, American Spinal Injury Association (ASIA) Impairment Scale score, and survival time, were recorded using chart review. Perioperative data collected and analyzed were operative time, number of instrumented segments, blood loss, and length of hospital stay. Follow-up clinical data were collected through outpatient interviews and chart extraction at 1 week, 1 month, 3 months, and 6 months postoperatively. Any complications, including surgical site infection, urinary tract infection, pneumonia, new neurologic deficits, blood transfusion, and stroke, were noted.

### Statistical analysis

Data are presented as the mean  $\pm$  standard deviation. Statistical analysis was performed using Prism version 7 for Windows (GraphPad Software, La Jolla, CA, USA) and SPSS version 22 (IBM, Armonk, NY, USA). The basic characteristics and perioperative data were analyzed using an independent t test

**Table 1 Patients' clinical and demographic characteristics after PPSF with EBRT or debulking.**

	PPSF with EBRT (n = 21)	Debulking (n = 29)	p
Age(y)	66.94 $\pm$ 10.92	61.74 $\pm$ 14.72	0.178
Sex (F:M)	6:15	9:20	0.851
Tomita score	8.00 $\pm$ 1.84	8.25 $\pm$ 1.35	0.126
SNIS	12.00 $\pm$ 2.42	12.19 $\pm$ 2.50	0.804
ESCC scale			0.723
2	2	6	
3	9	22	
Operation time	143.56 $\pm$ 49.44	181.47 $\pm$ 40.77	0.010
Blood loss	116.67 $\pm$ 109.92	696.55 $\pm$ 519.43	<0.001
Length of stay	11.90 $\pm$ 9.69	25.35 $\pm$ 20.65	0.004
Survival time	277.81 $\pm$ 255.33	309.29 $\pm$ 381.43	0.778
Half year survival rate	66.67%	62.07%	0.738
Days to start EBRT	9.09 $\pm$ 5.47	32.13 $\pm$ 25.85	0.003
EBRT dose (cGy)	3306.67 $\pm$ 629.02 (2800–5250)	2720.00 $\pm$ 480.78 (1800–3300)	
EBRT fraction	6–12	3–12	
Days to start Adjuvant chemotherapy	26.50 $\pm$ 9.52	30.00 $\pm$ 20.39	0.612
Level of involvement			
T3	1	1	
T4	2	2	
T5	1	4	
T6	2	3	
T7	1	2	
T8	1	2	
T9	3	4	
T10	2	4	
T11	4	5	
T12	3	5	
L1	2	7	
L2	5	6	
L3	8	4	
L4	4	3	
L5	2	2	

Abbreviations: PPSF: percutaneous pedicle fixation; EBRT: external beam radiotherapy; SNIS: spinal instability neoplastic score; ESCC: epidural spinal cord compression.

or the chi-square test. For NRS in clinical outcomes, repeated measures ANOVA and generalized estimating equations were used for inter- and intragroup comparisons at each time point. Inter- and intragroup comparisons of ASIA were performed using the chi-square test.

## Results

Table 1 presents the demographic data of all the patients. In the PPSF and debulking groups, the preoperative Tomita scores were  $8.00 \pm 1.84$  and  $8.25 \pm 1.35$ , respectively; preoperative SINS values were  $12.0 \pm 2.42$  and  $12.19 \pm 2.50$ , respectively; and preoperative NRS scores were  $3.57 \pm 1.32$  and  $3.45 \pm 2.31$ , respectively. The mean radiation dose in the PPSF group was  $3306.67 \pm 629.02$  cGy (range, 2800–5250 cGy) with 6–12 fractions and  $2720.00 \pm 480.78$  cGy (range, 1800–3300 cGy) in the debulking group. The PPSF group received EBRT sooner than the debulking group ( $9.09 \pm 5.47$  vs.  $32.13 \pm 25.85$  days;  $p < 0.01$ ). No significant intergroup differences were observed in age, sex, SINS, ESCC, Tomita score, time to adjuvant therapy, and preoperative NRS and ASIA scores. The follow-up NRS scores in the PPSF and debulking groups were  $2.24 \pm 0.70$  and  $2.07 \pm 0.92$  at 1 week,  $1.88 \pm 0.99$  and  $1.54 \pm 1.42$  at 1 month,  $1.15 \pm 1.14$  and  $1.35 \pm 1.05$  at 3 months, and  $1.22 \pm 0.97$  and  $1.33 \pm 1.15$  at 6 months, respectively. There was no significant difference neither between two groups in NRS ( $p = 0.557$ ), nor in the interaction between group and time ( $p = 0.809$ ). The differences of change in NRS over time between groups were not significant (preoperative to postoperative 1-week,  $p = 0.903$ ; preoperative to postoperative 1-month,  $p = 0.715$ ; preoperative to postoperative 3-month,  $p = 0.697$ ; preoperative to postoperative 6-month,  $p = 0.857$ ). NRS scores significantly decreased at each time point compared with preoperative NRS scores (Table 2). Intergroup differences in NRS scores at any time point were not significantly different (Fig. 1). No significant differences were observed between the groups in preoperative and postoperative/post-6-month ASIA scores (Fig. 2). Moreover, no significant intragroup differences were noted in ASIA scores at any time point.

The PPSF group had a significantly shorter operative time ( $143.56 \pm 49.44$  min and  $181.47 \pm 40.77$  min, respectively;  $p < 0.01$ ), significantly lower blood loss ( $116.67 \pm 109.92$  mL vs.  $696.55 \pm 519.43$  mL;  $p < 0.01$ ), and significantly shorter hospital stay ( $11.90 \pm 9.69$  vs.  $25.35 \pm 20.65$ ;  $p < 0.01$ ) than did the debulking group. Survival in the PPSF and debulking groups

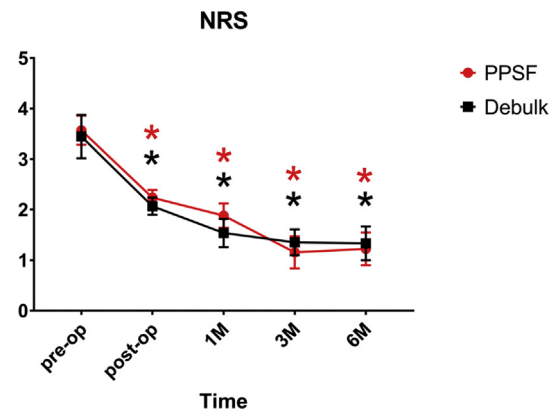


Fig. 1 Evaluation of the numeric rating scale (NRS) score and its comparison between the PPSF group and the debulking group at different time points. NRS scores significantly decreased at each time point compared with the preoperative NRS score. No significant between-group differences were observed pre- or postoperatively.

was  $277.81 \pm 253.31$  days and  $309.29 \pm 381.43$  days ( $p = 0.78$ ), respectively, with survival rates of 66.67% and 62.07% ( $p = 0.74$ ), respectively.

Table 3 shows the demographic data of primary site of tumor. Specifically, for other cancers, one patient in the PPSF group suffered from carcinoma of the buccal mucosa, and five patients in the debulking group were lymphoma, nasopharyngeal carcinoma, laryngeal carcinoma, pancreatic neuroendocrine tumor and testicular sex cord stromal tumor. Lymphoma and nasopharyngeal carcinoma are radiosensitive; laryngeal carcinoma and pancreatic neuroendocrine tumor show response to radiotherapy [22,23]. Although the radiosensitivity of testicular sex cord stromal tumor metastases is relatively radioresistant, it is reported to have a partial response to supraclavicular metastases for pain relief after palliative radiotherapy [24].

A 63-year-old woman with gastric adenocarcinoma and lymph node and lung metastasis underwent subtotal gastrectomy with Billroth-II reconstruction in 2008 and adjuvant therapy with complete remission. She presented with midline back pain radiating to the right lower leg. Lateral view T2-weighted magnetic resonance imaging (MRI) revealed L2-3 spinal metastasis with pathologic fracture and L3 MSCC (Fig. 3A). Transverse view T2-weighted MRI indicated severe cord compression with ESCC score 3 at the L3 level (Fig. 3B).

Table 2 Comparison of change in NRS over time between PPSF with EBRT and debulking surgery.

Parameter		PPSF with EBRT n = 21	$p^{\dagger}$	debulking n = 29	$p^*$ 0.557	$p^{\dagger}$
NRS	Preoperative	$3.57 \pm 1.32$		$3.45 \pm 2.31$	0.808	
	1 week	$2.24 \pm 0.70$	<0.001	$2.07 \pm 0.92$	0.484	<0.001
	1 month	$1.88 \pm 0.99$	<0.001	$1.54 \pm 1.42$	0.391	<0.001
	3 months	$1.15 \pm 1.14$	<0.001	$1.35 \pm 1.05$	0.626	0.001
	6 months	$1.22 \pm 0.97$	<0.001	$1.33 \pm 1.15$	0.818	0.001

Abbreviations: PPSF: percutaneous pedicle fixation; EBRT: external beam radiotherapy; NRS: numeric rating scale; \*comparison of NRS at different time point between groups;  $\dagger$ comparison of NRS between preoperative and each time point within groups.

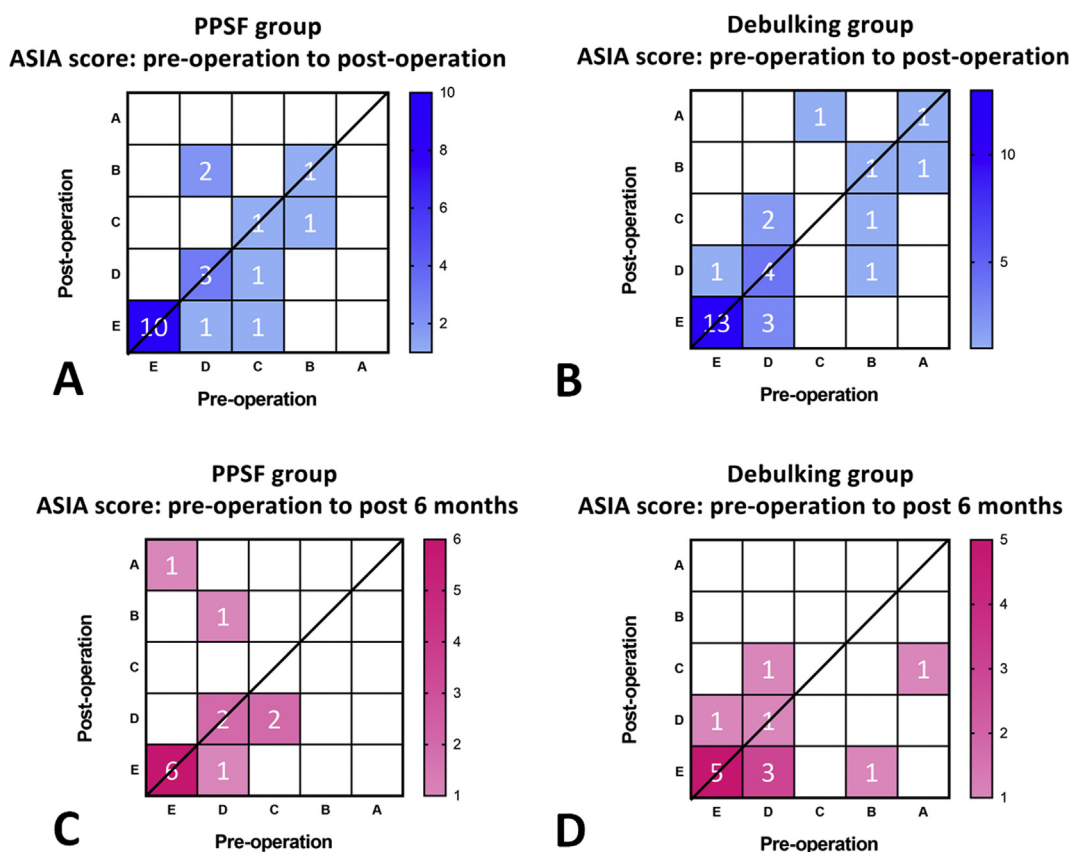


Fig. 2 Comparison of the pre- and postoperative/post-6-month American Spinal Injury Association (ASIA) Impairment Scale scores and between the PPSF and debulking groups. The numbers shown in the chart represent the number of patients with specific preoperative ASIA scores corresponding to their postoperative/post-6-month ASIA scores. Thus, the numbers of patients beneath the slash represent an improvement in ASIA score after the operation; numbers on the slash represent no change; numbers above the slash represent a deterioration of ASIA scores. No significant between-group differences were noted in pre- and postoperative/post-6-month ASIA scores.

Table 3 Primary tumor sites in patients who underwent PPSF with EBRT or debulking surgery.		
	PPSF with EBRT (n = 21)	Debulking (n = 29)
Metastatic tumor diagnosis (n%)		
Liver	19(4)	21(6)
Lung	33(7)	31(9)
Prostate	10(2)	7(2)
Thyroid	10(2)	3(1)
Kidney	0	3(1)
Breast	0	10(3)
Gastrointestinal	24(5)	7(2)
Others	5(1)	17(5)

Abbreviations: PPSF: percutaneous pedicle fixation; EBRT: external beam radiotherapy.

She underwent PPSF one level above and below the lesion site, with minimal soft tissue damage (Fig. 4), followed by radiotherapy and adjuvant therapy. Follow-up T2-weighted MRI indicated remission from ESCC (Fig. 5). However, approximately six months after surgery, she suffered from diplegia with sensory deficit, urine and stool retention. Magnetic resonance imaging revealed new onset of T12 metastatic

spinal cord compression. The patient underwent emergency revision of T10-L4 posterior fusion with pedicle screws and left T12 laminectomy with spinal cord decompression the next day; due to postoperative hematoma, tumor debulking with removal of hematoma was indicated on the following day. Consequently, muscle power did not restore after revision surgery. She started rehabilitation program afterwards.

No significant difference was observed in complication rates between the PPSF and debulking groups (4.7% vs. 17.2%  $p = 0.38$ ). Four patients in the debulking group had surgical site infection, which was managed by wound irrigation, debridement, and sequestrectomy, followed by a mean 1-month intravenous antibiotic administration. One 74-year-old man had left upper lung adenocarcinoma with mediastinal and left pulmonary artery invasion, lung-to-lung metastasis, left hilar and mediastinal lymphadenopathy, and L1–L2 metastasis. He underwent debulking surgery. Two weeks later, a bulging mass over the back wound was noticed, accompanied by left monoplegia. Aspiration revealed 200 mL of dark red blood. MRI and computed tomographic angiography revealed paraspinous intramuscular fluid accumulation, indicating vertebral body oozing. Wound debridement with sequestrectomy following vancomycin and ceftriaxone intravenous administration was performed, yet the wound healed poorly. Wound culture

revealed *Bacillus cereus* and *Staphylococcus epidermidis*. The patient's medical condition rapidly deteriorated, and he

eventually died due to septic shock. In the PPSF group, an 85-year-old man with prostate cancer experienced diplegia the

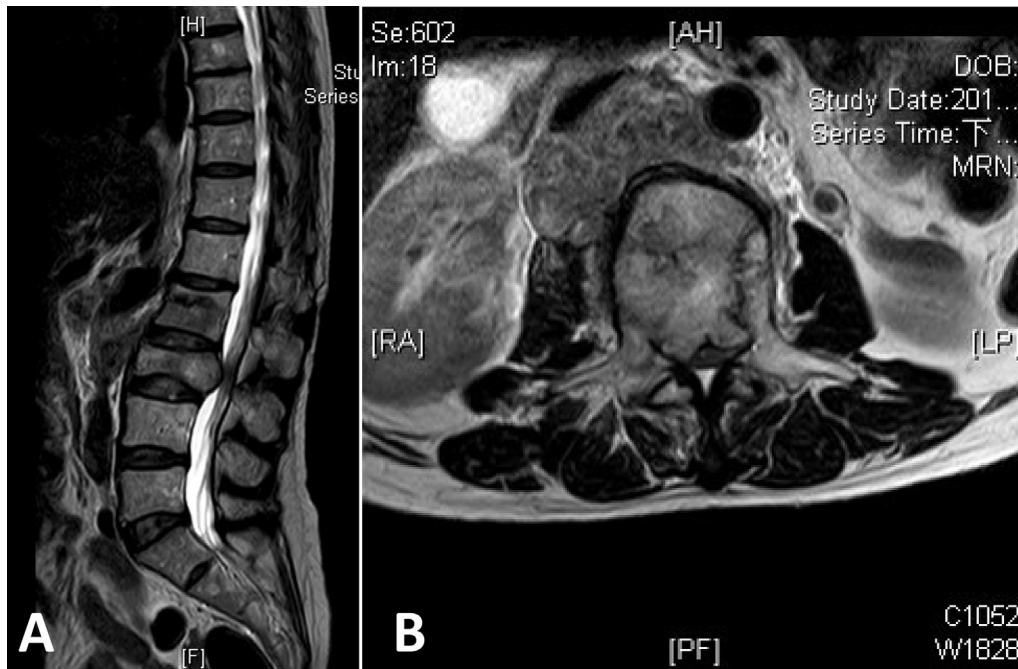


Fig. 3 A 63-year-old woman had gastric adenocarcinoma with symptomatic L2-L3 spinal metastasis. Lateral view T2-weighted magnetic resonance imaging (MRI) revealed L3 metastatic spinal cord compression (A). Transverse view T2-weighted MRI indicated severe cord compression with epidural spinal cord compression score 3 at L3 level (B).

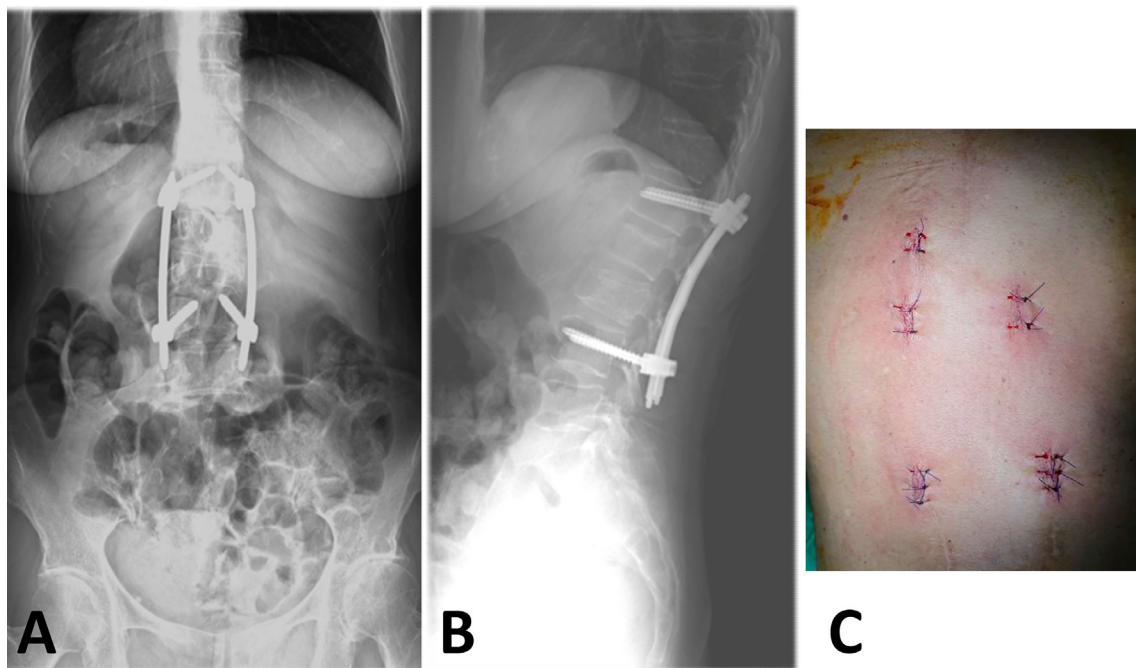


Fig. 4 Postoperative noncontrast anteroposterior (A) and lateral views (B) of the patient shown in Fig. 1 with percutaneous pedicle screw fixation (PPSF) one level above and below the lesion site. Five small incision wounds were used for equipment insertion during PPSF (C).

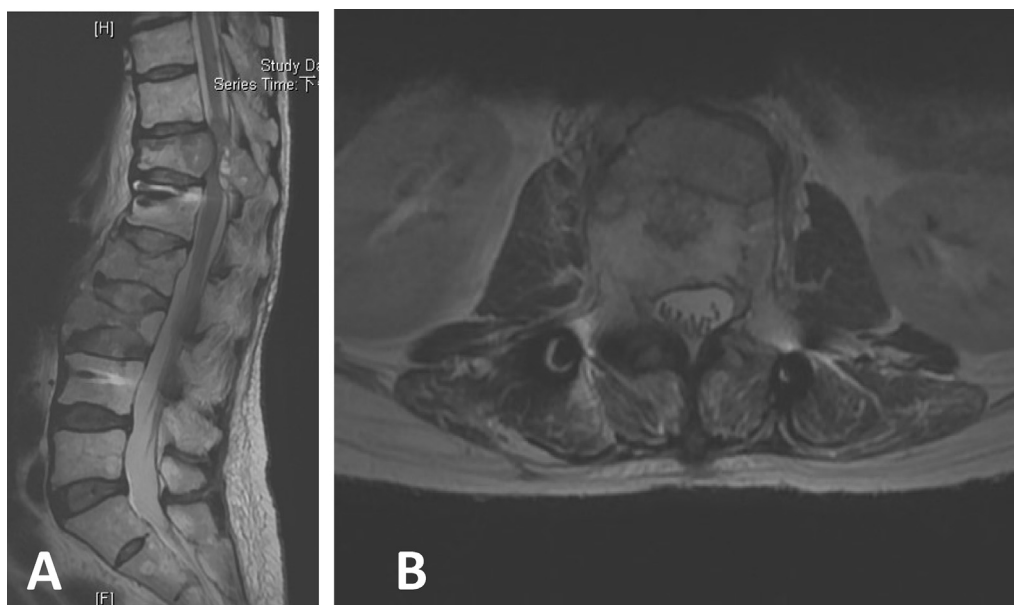


Fig. 5 Follow-up T2-weighted magnetic resonance imaging (MRI)—lateral (A) and sagittal views (B). The spinal cord compressed at L3 by tumor metastasis (shown in Fig. 1) was in remission after radiotherapy and adjuvant therapy.

night after the operation. Immediate open laminectomy with tumor excision was arranged the next day. His muscle power was restored after surgery, and no further neurologic deficits were noted after revision surgery during the admission. However, as a result of tumor progression, muscle power of his left leg dropped in a few months. After discussion with the patient and his family, they refused further chemotherapy and invasive intervention.

## Discussion

Patients with spinal metastasis who have a poor prognosis are usually managed palliatively, with pain alleviation and preservation or restoration of stability or neurological function [7]. EBRT alone was once considered efficacious as laminectomy for relieving pain and improving neurologic function without a high incidence of spinal instability [8,9]. With a better understanding of spinal biomechanics, development of surgical approaches, and stabilization techniques and devices, the safety and efficacy of surgical treatment improved in patients with metastatic spinal disease. Subsequently, studies evaluated the combination of surgical decompression with or without stabilization followed by radiotherapy and found it to substantially alleviate neurologic symptoms [25,26]. Then, Patchell et al. provided strong evidence in their randomized trial [5] of patients with symptomatic metastatic ESCC undergoing radiotherapy alone or surgery followed by radiotherapy. Better ambulatory status, higher ambulatory rates (57% vs. 84%), better recovery (19% vs. 63%), and longer ambulation duration (median, 13 vs. 122 days) were observed in the surgical group. In addition, the surgical group tended to use fewer opioid analgesics and corticosteroids and tended to survive longer. In fact, the trial had to be terminated early because of safety concerns and the evident superiority of the surgical group to the EBRT-only group. This trial was criticized

for its lack of technical surgical standardization and inherent patient selection bias favoring surgery [27–30]. Moreover, Rades et al. [27] claimed no significant difference in motor function improvement between patients receiving radiotherapy alone and those receiving surgery plus radiotherapy. However, for MSCC of unfavorable primary tumors, a 2015 meta-analysis showed better therapeutic efficacy with surgery than with radiotherapy alone with regard to pain relief, improvement of ambulation, and life expectancy without additional complications [31].

Advancements in surgical technique and technology have made MIS a feasible option for patients with spinal metastasis. Highly invasive conventional palliative surgery may aggravate the general condition of the patient and may delay or even exclude the opportunity of administering adjuvant therapy. In the present study, MIS could relieve pain within several days after surgery. This may be related to the mechanism of pain in patients with MSCC [32]. Percutaneous stabilization with pedicle screws stabilized the spine and alleviated the surrounding muscle spasm. Pain is also caused by the stimulation of nerve fibers by tumor invasion and nerve root compression; disruption of the physiological equilibrium between osteoclasts and osteoblasts could be diminished only by EBRT in the PPSF group [33]. EBRT administration significantly reduced pain comparable to that achieved in the debulking group. Neurologic function was also not significantly different between groups. Though it was not found in our study population, due to the fragile texture of metastatic bone, rates of screw loosening, pull-out and pseudarthrosis were concerning. One of the ways to handle risk is to utilize cement-augmented percutaneous pedicle screws which help retaining good screw stability. Moussazadeh et al. [34] performed 44 cases of percutaneous pedicle screw fixation with cement augmentation in patients with tumor-induced spinal instability and resulted in only one asymptomatic screw pullout. In the study of Afathi et al. [35], no pullout of screws was found in patients who had pathological

fracture and treated with fenestrated cemented percutaneous pedicle screws.

PPSF can be superior to conventional open surgery in terms of operative time, blood loss, length of hospital stay, and risk of intraoperative complications, all of which were significantly lower in the PPSF group in our study. Additionally, PPSF was associated with better cost effectiveness. Intraoperative blood loss in PPSF ranges from 92 to 184 mL, whereas that in conventional open surgery is significantly higher at 900–1534 mL [14–16], even after adjustment for other confounding factors that increased the risk of immediate postoperative morbidities or delayed the initiation of adjuvant therapy [14]. Blood loss is also relatively high when decompression is used, even with a minimally invasive approach [18–20]. Hamad et al. [19] prospectively evaluated patients who underwent surgery with or without additional mini-decompression and reported no statically significant difference in blood loss (92 mL vs. 222 mL). However, in their study, one patient had massive intraoperative hemorrhage (2000 mL) during mini-open decompression and was excluded from the blood loss analysis for subjective reasons.

The necessity of direct surgical decompression has gained attention. Compared with those who had open surgery, patients with hepatocellular carcinoma metastatic to the spine who underwent MIS stabilization without decompression had less pain, longer ambulation time, and longer survival time [16]. Maseda et al. [21] observed that 13.3% and 16.7% of patients with ESCC grade  $\geq 1b$  after posterior stabilization and after posterior decompression and stabilization, respectively, experienced paralysis. The clinical outcomes were similar even compared with MIS decompression and stabilization [18–20]. In patients with severe spinal cord compression, whether PPSF can be performed without decompression remains controversial. Although many surgeons have considered PPSF to be contraindicated and decompression to be necessary for patients with severe nerve paralysis, lower Tokuhashi score, higher SINS, higher ESCC grade, and expected long-term survival [16,20,21], our data indicated that MIS without decompression followed by EBRT can help control pain and maintain neurologic function, particularly in patients with radiosensitive tumors. Further research is therefore needed to verify whether PPSF or surgical decompression, or a combination of the two, is beneficial in metastatic ESCC.

Surgical site infection leading to wound dehiscence is the most common reason for reoperation. Although complication rates were comparable between the two groups in our study, patients often displayed poor general condition because of their primary disease process and adjuvant therapy. The incidence of surgical site infection and wound dehiscence is 4%–20% [36] in patients with metastatic spine tumors and rises to 32% with neoadjuvant radiotherapy. A lower extent of physiologic insult to the skin and tissue would reduce postoperative recovery time and morbidity [18]. Other risk factors include the numbers of resected spines, posterior surgical approach, preoperative corticosteroid administration, nutritional deficiency, previous spine surgeries, diabetes mellitus, and length of hospital stay [36].

In PPSF without surgical decompression, radiosensitive metastatic tumors were indirectly decompressed through

EBRT. The radiation dose in palliative therapy is typically 20–40 Gy, with 2–4 Gy per fraction [37]. The optimized course of radiotherapy is still under investigation. Compared with multifraction radiotherapy, single-fraction radiotherapy was found to be associated with more frequent local recurrence [38]. In the latest noninferiority randomized phase 3 trial, a single 10-Gy fraction was noninferior to a 20-Gy dose over five fractions in patients with symptomatic ESCC. In an earlier study, Rades et al. [39] preferred a longer course of radiotherapy because of the high risk of local failure in short-course radiotherapy. Nevertheless, in their new trial, randomized patients who received <30 Gy in 10 fractions or <20 Gy in 5 fractions had similar neurologic function improvement and local progression-free survival at 6 months [40]. Even if the primary tumor is radioresistant, stereotactic body radiation therapy (SBRT) can still be administered. A 98% local control rate has been reported after high-dose single-fraction SBRT, providing safe and durable local control independent of tumor histology [41]. Taken together, these findings indicate that the treatment strategy has evolved over the past decade. The NOMS decision framework combines the promising results of radiotherapy and targeted therapies and the advantages of open surgery or PPSF and provides a foundation for the integration of concurrent technologies [1,13]. This multidisciplinary approach can lead to optimal patient outcomes.

This study has some limitations. Since this is a retrospective, single-center study, with a relatively small sample size and a short follow-up duration of 6 months, selection bias may be introduced. The selection criteria of surgical procedures varied among surgeons in this study. Therefore, a long-term, prospective, multicenter study enrolling a large sample size with a favorable follow-up rate is warranted.

---

## Conclusion

Patients with radiosensitive unstable severe MSSC who underwent the minimally invasive procedure of PPSF without decompression followed by EBRT had a shorter operation time, shorter length of stay, and less blood loss than those who underwent debulking surgery. A significant reduction in postoperative pain was observed in both groups. Pain, neurologic function, overall survival, and complication rates were not significantly different between the PPSF and debulking groups. Taken together, the findings suggest that PPSF followed by EBRT is relative safe and appropriate as a palliative therapy.

---

## Funding

This research did not receive any specific grant from funding agencies in the public, commercial, or not-for-profit sectors.

---

## Conflicts of interest

The authors have no financial or ethical conflicts of interest to report.



## Acknowledgments

We would like to thank Wallace Academic Editing for editing this manuscript. We also thank the staff members of the orthopedic department at our hospital for their help.

## REFERENCES

- [1] Barzilai O, Laufer I, Yamada Y, Higginson DS, Schmitt AM, Lis E, et al. Integrating evidence-based medicine for treatment of spinal metastases into a decision framework: neurologic, oncologic, mechanical stability, and systemic disease. *J Clin Oncol* 2017;35:2419–27.
- [2] Yao A, Sarkiss CA, Ladner TR, Jenkins AL 3rd. Contemporary spinal oncology treatment paradigms and outcomes for metastatic tumors to the spine: a systematic review of breast, prostate, renal, and lung metastases. *J Clin Neurosci* 2017;41:11–23.
- [3] Kaloostian PE, Yurter A, Zadnik PL, Sciubba DM, Gokaslan ZL. Current paradigms for metastatic spinal disease: an evidence-based review. *Ann Surg Oncol* 2014;21:248–62.
- [4] Ryken TC, Eichholz KM, Gerszten PC, Welch WC, Gokaslan ZL, Resnick DK. Evidence-based review of the surgical management of vertebral column metastatic disease. *Neurosurg Focus* 2003;15:E11.
- [5] Patchell RA, Tibbs PA, Regine WF, Payne R, Saris S, Kryscio RJ, et al. Direct decompressive surgical resection in the treatment of spinal cord compression caused by metastatic cancer: a randomised trial. *Lancet* 2005;366:643–8.
- [6] Loblaw DA, Perry J, Chambers A, Laperriere NJ. Systematic review of the diagnosis and management of malignant extradural spinal cord compression: the cancer care ontario practice guidelines initiative's neuro-oncology disease site group. *J Clin Oncol* 2005;23:2028–37.
- [7] Patil CG, Lad SP, Santarelli J, Boakye M. National inpatient complications and outcomes after surgery for spinal metastasis from 1993–2002. *Cancer* 2007;110:625–30.
- [8] Young RF, Post EM, King GA. Treatment of spinal epidural metastases. Randomized prospective comparison of laminectomy and radiotherapy. *J Neurosurg* 1980;53:741–8.
- [9] Findlay GF. The role of vertebral body collapse in the management of malignant spinal cord compression. *J Neuro Neurosurg Psychiatry* 1987;50:151–4.
- [10] Lee BH, Kim TH, Chong HS, Moon ES, Park JO, Kim HS, et al. Prognostic factor analysis in patients with metastatic spine disease depending on surgery and conservative treatment: review of 577 cases. *Ann Surg Oncol* 2013;20:40–6.
- [11] Tokuhashi Y, Ajiro Y, Umezawa N. Outcome of treatment for spinal metastases using scoring system for preoperative evaluation of prognosis. *Spine* 2009;34:69–73.
- [12] Loblaw DA, Mitera G, Ford M, Laperriere NJ. A 2011 Updated systematic review and clinical practice guideline for the management of malignant extradural spinal cord compression. *Int J Radiat Oncol Biol Phys* 2012;84:312–7.
- [13] Laufer I, Rubin DG, Lis E, Cox BW, Stubblefield MD, Yamada Y, et al. The NOMS framework: approach to the treatment of spinal metastatic tumors. *Oncol* 2013;18:744–51.
- [14] Kumar N, Malhotra R, Maharajan K, Zaw AS, Wu PH, Makandura MC, et al. Metastatic spine tumor surgery: a comparative study of minimally invasive approach using percutaneous pedicle screws fixation versus open approach. *Clin Spine Surg* 2017;30:E1015–21.
- [15] Miscusi M, Polli FM, Forcato S, Ricciardi L, Frati A, Cimatti M, et al. Comparison of minimally invasive surgery with standard open surgery for vertebral thoracic metastases causing acute myelopathy in patients with short- or mid-term life expectancy: surgical technique and early clinical results. *J Neurosurg Spine* 2015;22:518–25.
- [16] Jung JM, Chung CK, Kim CH, Yang SH. Minimally invasive surgery without decompression for hepatocellular carcinoma spinal metastasis with epidural spinal cord compression grade 2. *J Korean Neurosurg Soc* 2019;62:467–75.
- [17] Galgano M, Fridley J, Oyelese A, Telfian A, Kosztowski T, Choi D, et al. Surgical management of spinal metastases. *Expert Rev Anticancer Ther* 2018;18:463–72.
- [18] Kwan MK, Lee CK, Chan CY. Minimally invasive spinal stabilization using fluoroscopic-guided percutaneous screws as a form of palliative surgery in patients with spinal metastasis. *Asian Spine J* 2016;10:99–110.
- [19] Hamad A, Vachtsevanos L, Cattell A, Ockendon M, Balain B. Minimally invasive spinal surgery for the management of symptomatic spinal metastasis. *Br J Neurosurg* 2017;31:526–30.
- [20] Uei H, Tokuhashi Y, Maseda M, Nakahashi M, Sawada H, Nakayama E, et al. Comparison between minimally invasive spine stabilization with and without posterior decompression for the management of spinal metastases: a retrospective cohort study. *J Orthop Surg Res* 2018;13:87.
- [21] Maseda M, Uei H, Nakahashi M, Sawada H, Tokuhashi Y. Neurological outcome of treatment for patients with impending paralysis due to epidural spinal cord compression by metastatic spinal tumor. *J Orthop Surg Res* 2019;14:291.
- [22] Contessa JN, Griffith KA, Wolff E, Ensminger W, Zalupski M, Lawrence TS, et al. Radiotherapy for pancreatic neuroendocrine tumors. *Int J Radiat Oncol Biol Phys* 2009;75:1196–200.
- [23] Giri G, Thejaswini B, Nanda R, Aradhana K. Prediction of outcome in buccal cancers treated with radical radiotherapy based on the early tumor response. *J Cancer Res Therapeut* 2015;11:364–8.
- [24] Grem JL, Robins HI, Wilson KS, Gilchrist K, Trump DL. Metastatic leydig cell tumor of the testis report of three cases and review of the literature. *Cancer* 1986;58:2116–9.
- [25] Landmann C, Hunig R, Gratzl O. The role of laminectomy in the combined treatment of metastatic spinal cord compression. *Int J Radiat Oncol Biol Phys* 1992;24:627–31.
- [26] Akeyson EW, McCutcheon IE. Single-stage posterior vertebrectomy and replacement combined with posterior instrumentation for spinal metastasis. *J Neurosurg* 1996;85:211–20.
- [27] Rades D, Huttenlocher S, Bajrovic A, Karstens JH, Adamietz IA, Kazic N, et al. Surgery followed by radiotherapy versus radiotherapy alone for metastatic spinal cord compression from unfavorable tumors. *Int J Radiat Oncol Biol Phys* 2011;81:e861–8.
- [28] Nater A, Sahgal A, Fehlings M. Management - spinal metastases. *Handb Clin Neurol* 2018;149:239–55.
- [29] Iida K, Matsumoto Y, Setsu N, Harimaya K, Kawaguchi K, Hayashida M, et al. The neurological outcome of radiotherapy versus surgery in patients with metastatic spinal cord compression presenting with myelopathy. *Arch Orthop Trauma Surg* 2018;138:7–12.
- [30] Suppl MH. Approaches to radiotherapy in metastatic spinal cord compression. *Dan Med J* 2018;65:B5451.
- [31] Chen B, Xiao S, Tong X, Xu S, Lin X. Comparison of the therapeutic efficacy of surgery with or without adjuvant radiotherapy versus radiotherapy alone for metastatic spinal cord compression: a meta-analysis. *World Neurosurg* 2015;83:1066–73.
- [32] De Felice F, Piccioli A, Musio D, Tombolini V. The role of radiation therapy in bone metastases management. *Oncotarget* 2017;8:25691–9.

- [33] Goblirsch MJ, Zwolak PP, Clohisy DR. Biology of bone cancer pain. *Clin Cancer Res* 2006;12:6231s-5s.
- [34] Moussazadeh N, Rubin DG, McLaughlin L, Lis E, Bilsky MH, Laufer I. Short-segment percutaneous pedicle screw fixation with cement augmentation for tumor-induced spinal instability. *Spine J : official journal of the North American Spine Society* 2015;15:1609–17.
- [35] Afathi M, Mansouri N, Farah K, Benichoux V, Blondel B, Fuentes S. Use of cement-augmented percutaneous pedicular screws in the management of multifocal tumoral spinal fractures. *Asian Spine J* 2019;13:305–12.
- [36] Carl HM, Ahmed AK, Abu-Bonsrah N, De la Garza Ramos R, Sankey EW, Pennington Z, et al. Risk factors for wound-related reoperations in patients with metastatic spine tumor. *J Neurosurg Spine* 2018;28:663–8.
- [37] Blakaj DM, Guiou M, Weicker M, Mendel E. The evolving treatment paradigm for metastatic spine disease. *World Neurosurg* 2015;84:6–8.
- [38] Rades D, Stalpers LJ, Veninga T, Schulte R, Hoskin PJ, Obralic N, et al. Evaluation of five radiation schedules and prognostic factors for metastatic spinal cord compression. *J Clin Oncol* 2005;23:3366–75.
- [39] Rades D, Lange M, Veninga T, Stalpers LJ, Bajrovic A, Adamietz IA, et al. Final results of a prospective study comparing the local control of short-course and long-course radiotherapy for metastatic spinal cord compression. *Int J Radiat Oncol Biol Phys* 2011;79:524–30.
- [40] Rades D, Šegedin B, Conde-Moreno AJ, Garcia R, Perpar A, Metz M, et al. Radiotherapy with 4 Gy x 5 versus 3 Gy x 10 for metastatic epidural spinal cord compression: final results of the SCORE-2 trial (ARO 2009/01). *J Clin Oncol* 2016;34:597–602.
- [41] Laufer I, Bilsky MH. Advances in the treatment of metastatic spine tumors: the future is not what it used to be. *J Neurosurg Spine* 2019;30:299–307.