

Discrepancies in determining electron energy for lumpectomy boost treatment

Aime M Gloi, Robert Buchanan¹

St Vincent Hospital Green Bay WI, ¹Department of Radiation Oncology, DABR Southeast Alabama Medical Center, USA

Received on: 03.02.2012 Review completed on: 19.04.2012 Accepted on: 30.04.2012

ABSTRACT

The aim of this study was to compare lumpectomy cavity depth measurements obtained through ultrasound (U/S) and retrospective computed tomography (CT). Twenty-five patients with stage T1-2 invasive breast cancer formed the cohort of this study. Their U/S and CT measurements were converted into electron energy and compared. The mean U/S depth was 3.6 ± 1.3 cm, while the mean CT depth was 4.9 ± 1.9 cm; the listed error ranges are one standard deviation. Electron energies for treatment ranged from 6 MeV to 12 MeV based on the U/S determination. There was no significant correlation between cavity depths measured by U/S and CT ($R^2 = 0.459$, $P < 0.002$). Furthermore, only 20% of CT-based electron energy determinations matched the corresponding U/S determinations. This ratio increased to 40% when taking into account an upper limit based on the depth of organs at risk below the cavity. The study shows that there is a significant discrepancy between cavity depths determined by U/S and CT. It also supports the concept that post-lumpectomy radiotherapy boosts should be tailored according to the needs and comfort of individual practices and institutions.

Key words: Breast boost, cavity depth, lumpectomy

Introduction

Cancer of the breast is one of the most devastating malignancies in women between the ages of 40 and 50 in the USA.^[1] A combination of lumpectomy and radiotherapy remains the most common option for women in stage I or stage II.^[2-7] The standard technique is to treat the whole breast via tangential fields, up to a total dose of 45–50 Gy. In most cases, this treatment is followed by a 10–15 Gy electron boost to the tumor bed to reduce the likelihood of recurrence.^[8,9] The tumor bed volume is estimated post-surgery from clinical and radiological information and is then used to determine the appropriate electron energy.

Accurate delineation of the target volume is essential when delivering external beam radiotherapy to the tumor bed. Electron boost plans are often set up with a margin of 2–3 cm, which, according to several reports,^[10,11] results in some geographical misses and unintended outcomes. Different institutions use various techniques for target delineation, e.g. ultrasound (U/S), computed tomography (CT), surgical clips, and scars. U/S is mainly employed for cavity size and depth determination when radiation has not been significantly delayed after surgery.^[12] Combining the information from surgical clips with CT scans has also been shown to properly determine the tumor bed.

The main advantages of a CT scan are better visualization of the post-operative state and lower risk to normal breast tissues in as many as 50% of the cases.^[13] Its main difficulties are differentiating glandular breast tissues from surrounding anatomy and combining cavity images from different window settings. For these reasons, it is widely believed that U/S is a more accurate method of defining boost fields and prescribing an appropriate depth.

Unlike CT images, U/S can differentiate fluid-filled cavity (which is the lumpectomy cavity) from the surrounding tissue with high specificity because of excellent soft tissue imaging characteristics.^[14] This helps to identify the tumor bed volume more accurately and has an improved inter-

Address for correspondence:

Dr. Aime M Gloi,
ST Vincent Hospital 830 South Van Buren Street Green Bay,
WI 54307, USA.
E-mail: agloi@stvgb.org

Access this article online

Quick Response Code:



Website:

www.jmp.org.in

DOI:

10.4103/0971-6203.99234

observer consistency. Magnetic resonance imaging (MRI) combines better definition of the breast and surrounding tissues with accurate localization of the target volume and organs at risk, but is also expensive and impractical. It has been shown that relying on surgical scars as an alternate means of defining the electron beam trajectory may lead to a partial geographic miss of the lumpectomy cavity in more than 50% of the cases.^[10,11]

Localization of lumpectomy cavity for boost irradiation can be accomplished using U/S, MRI, CT, surgical clips, other methods or a combination of techniques. Various reports indicated difficulties in contouring the boost volume in CT images because of poor seroma clarity from the surrounding tissue, specifically in patients with dense breast parenchyma.^[15] This results in high inter-observer variability. To ensure appropriate coverage and to limit normal tissue exposure during boost irradiation in patients, a 1.5 cm margin was added around the tumor to palliate at any geographical misses. It was also shown in previous studies that a margin of 1.5–2 cm to the tumor bed will cover all subclinical disease.^[16]

In this study, the CT scans were performed 3 days before the start of whole breast irradiation after post-op and post-chemo. U/S was performed 2 days before the completion of whole breast irradiation. Oh *et al.*^[10] showed that the volume of the lumpectomy cavity reduced significantly after whole breast radiation therapy (WBRT) and demonstrated a strong correlation between the presence of seroma and the reduced volume. Therefore, large volume reduction of the lumpectomy cavity may lead to excessive normal breast tissue irradiation, and may also have an impact on the accuracy of boost irradiation planning, leading to significant effects on dose homogeneity in the treatment volume.

The aim of this study is to analyze cavity depths and subsequent electron energies derived from U/S and retrospective CT measurements. The electron energy is determined by taking into consideration the minimum depth of organs at risk as well as the maximum cavity depth.

Materials and Methods

CT

Twenty-five patients having undergone radiotherapy for early-stage breast cancer after breast-conserving surgery were included in this study. A plan for electron boost treatment was computed for each patient from tomographic (CT) scans in the treatment position. Before the CT scans, skin marks were placed to locate the boost volume isocenter and enable patient repositioning during treatment. Radiopaque wires and markers were placed to locate palpable breasts scars and skin marks on the CT images.

All CT data were transferred to Eclipse (Varian Medical

Systems Inc., Palo Alto, CA, USA), a 3D treatment planning system.

U/S

Two days before completion of the treatment, the same breast cancer patients underwent diagnostic U/S in the radiation treatment position. The localization and determination of depth of the lumpectomy cavity was performed by the X-ray tech on duty with the radiation oncologist on-site to finalize decisions as to the skin markings outlines the boost site. Under the guidance of the radiation oncologist, the tumor bed volume is identified more accurately thereby reducing inter-operator variability. The dimensions of the cavity-based U/S included transverse (medial to lateral), longitudinal (superior–inferior) and depth (skin to posterior portion of the cavity) measurement. These examinations were performed with a standard U/S device (HDI 5000; Philips Andover, MA, USA) using a broadband curved array transducer working at 2–5 MHz and a broadband linear array working at 4–7 MHz. Imaging errors can be kept to a minimum by using the linear array for most measurements. However, the curved array provides better penetration depth. The site was marked on the skin before measurement. The target depth is defined as the deepest aspect of the cavity plus a 1.5 cm margin. Treatment fields were prescribed with a 1.5 cm margin on the cavity, and electron energy (E_1) was chosen to cover the target depth.

ACT measurement of maximum cavity depth was obtained and electron energy boost was determined. The electron energy is prescribed such that the 90% isodose surface meets the deepest edge of the cavity defined by CT. We derived tumor bed volumes using the treatment planning Eclipse tools and potential electron energies (E_2) for the patients, whose cavities varied in shape and size. For an organ such as breast with deformable cavity, several challenges need to be overcome for a successful treatment. CT overestimates the true tumor bed volume compared with U/S images. Wong *et al.*^[17] reported that the average difference of the tumor bed volume between U/S and CT was 55% because the seroma or fluid cavity was well visualized in U/S but not as well visualized in CT. The isodose contour may not encompass the entire target, and its physiologic complexity (multiple edges and curvatures) make dose uniformity difficult to achieve. In some areas, the depth and dose varied considerably. All these problems affect the uniformity of electron beam energy. In addition, we determine the minimum depth of organs at risk depending on the location of the breast. For example, in soft tissue, the depths vary significantly with density; consequently, a uniform beam may underdose the tumor bed or overdose the underlying normal tissue. We therefore selected the beam energy (E_3) within a range dependent on the depth of the organs at risk (R_{od}) and the cavity depth (R_{cav}) in water:

$$2 \times R_{oa} \leq E_3 \leq 3.3 \times R_{cav} \quad \dots(1)$$

where R_{oa} and R_{cav} are in cm and E_3 in Mev. The energy E_3 is chosen among the closest energies (6,9,12,16, 20 Mev) from our linear accelerator (21 EX Varian Medical Systems Inc., Palo Alto, CA, USA) electron energies. The advantages and disadvantage of various methods for breast delineation in electron boost therapy are summarized in Table 1.

Statistical analysis

Descriptive statistics were calculated for the various cavity depth measurements of all 25 patients. The differences observed between the U/S and the CT mean values and standard deviations were deemed significant using the paired *t*-test. A scatter plot of U/S and CT cavity depth measurements is shown in Figure 1, and a regression line was fit to the data. Note that additional factors such as organs at risk and breast volume are associated with the cavity depth.

The level of agreement between the two tests was assessed using two statistical methods. First, a concordance correlation coefficient (CC) was calculated as $CC = P \times C_b$, and defined as the product of an accuracy measure (in this case the bias correction factor, C_b) and a precision measure (the Pearson correlation coefficient, P).

Second, we apply the Bland-Altman^[18] method of assessing agreement. This approach plots the mean of each data pair against its difference, and defines the 95% limits of agreement as the average difference plus or minus 1.96-times the standard deviation of the difference. All statistical calculations were performed using the statistical package Graphpad Prism (La Jolla, CA, USA). *P*-values less than 0.05 were considered statistically significant.

Results

Various patient and tumor characteristics are shown in Table 2. The median age of the 25 patients was 58 years (range: 41–84 years). Eighteen of the patients were diagnosed with invasive ductal carcinoma, while seven had ductal carcinoma *in situ*. All patients had negative surgical margin. Most of the tumors were located in the outer quadrants, and most lesions (80%) were less than 2 cm in diameter. All 25 patients received a doxorubicin-based chemotherapy regimen before radiotherapy. Twelve underwent an additional hormone regimen (Tamoxifen) before radiotherapy.

Table 3 shows the dosimetric parameters analyzed in this study. Depth cavity estimates from U/S and CT measurements [Figure 1] correlated poorly (Pearson’s correlation coefficient $r = 0.46$, 95% confidence interval [CI] 0.56–1.54, $P < 0.0002$). The CT cavity depths were

Table 1. Lumpectomy depth measurement methods employed in various institutions

Method	Advantages	Disadvantages
Ultrasound	Reproducible images Non-invasive Tumor bed is visible	Requires experienced operator Difficulties in abnormalities and surrounding tissue
CT	Transfer to a planning system Breast well defined Use of measurement tool	Varies with window setting, many slices Glandular tissue not well defined
Surgical clip	Allows lateral border Non-invasive	Operator dependent Also depends on the placement of scar

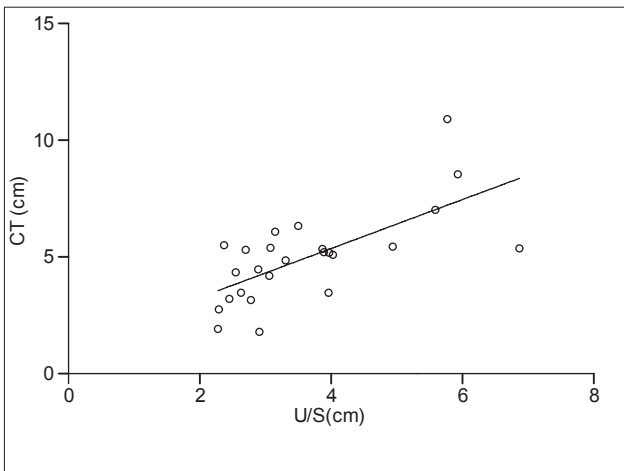


Figure 1: Scatter plot of depth cavity from CT results against U/S for 25 patients. Pearson correlation was $r=0.46$ with $P<0.0002$

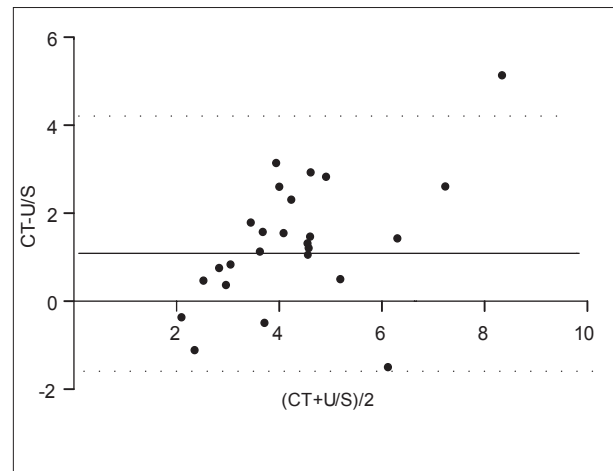


Figure 2: Difference between U/S and CT cavity depth measurements with horizontal lines showing the mean of limits of agreement

consistently larger than the U/S cavity depths [Table 3]. The mean cavity depth through U/S was 3.6 cm (median 3.2), and the mean CT depth was 4.9 cm (median 5.2). In addition, depending on the location of the breast, the mean estimated depth of organs at risk was 11.9 cm (median 10.5). On average, CT depths were 40% greater than U/S depths.

Table 2: Patient and tumor characteristics employed in this study

Characteristics	Data
Age (years)	
Median	58
range	41-84
DCIS	7
IDC	18
Location	
Inner	3
Outer	20
Central	2
Preradiation chemotherapy	
Yes	100%

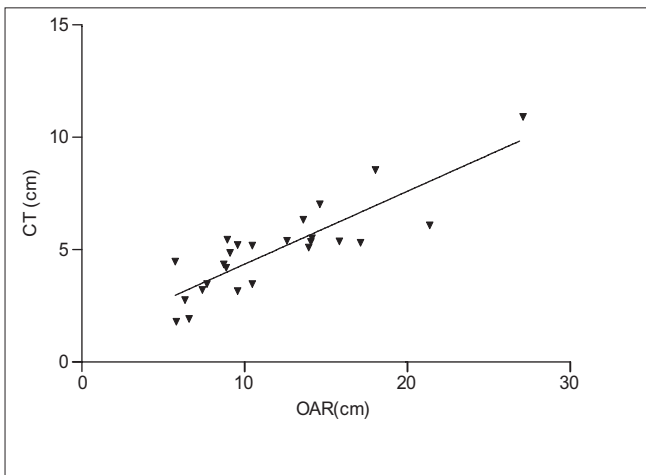


Figure 3: Scatter plot of depth cavity from CT measurement versus OAR for 25 patients. The concordance correlation was estimated at $P = 0.46$

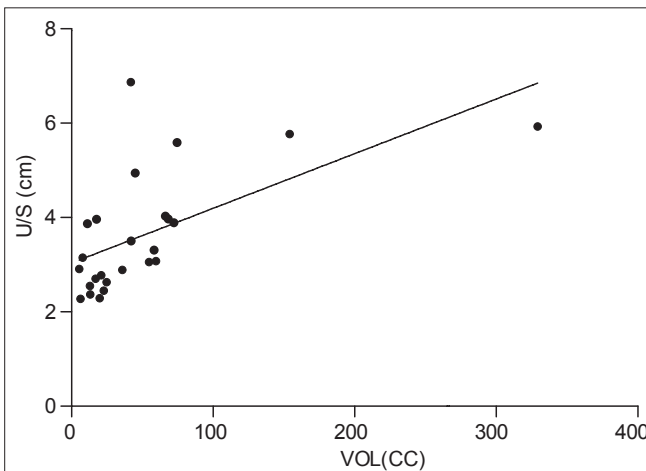


Figure 5: Scatter plot of depth cavity from U/S measurement versus breast volume for 25 patients. The concordance correlation was estimated at $P = 0.7$

The CC was 0.46 (95% CI: 0.22–0.65). This value is based on a correlation coefficient P of 0.68, consistent with moderate precision, and a C_b of 0.68. The latter shows that the best-fit line was not close to the line of perfect agreement. According to the Bland and Altman method [Figure 2], the mean difference between the two tests was 1.3 cm (standard deviation: 1.5); therefore, the 95% limits of agreement are -1.5 and 4.2 cm. In Figure 2, the solid line represents the mean difference and the dashed lines are offset by ± 1.96 standard deviation from the mean.

Table 3: Dosimetric parameters calculated from this study

Dosimetric parameters	Mean \pm St. Dev.
Tumor bed volume (cc)	51.3 \pm 6.5
CT depth (cm)	4.9 \pm 1.9
U/S depth (cm)	3.6 \pm 1.3
OAR depth (cm)	11.9 \pm 5.2
Cavity depth(cm)	5.9 \pm 2.6

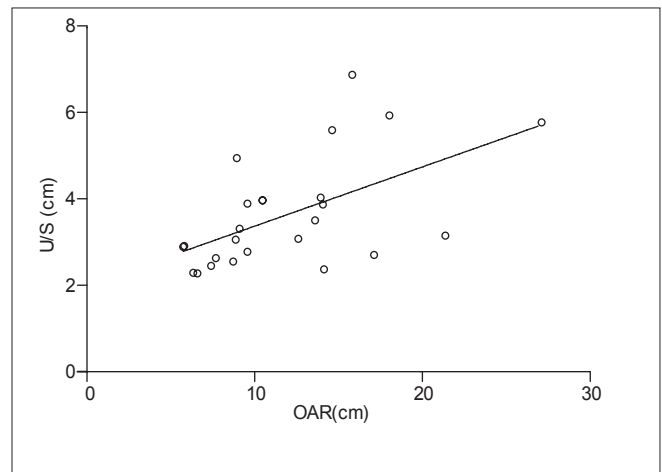


Figure 4: Scatter plot of depth cavity from U/S measurement versus OAR for 25 patients. The concordance correlation was estimated at $P = 0.37$

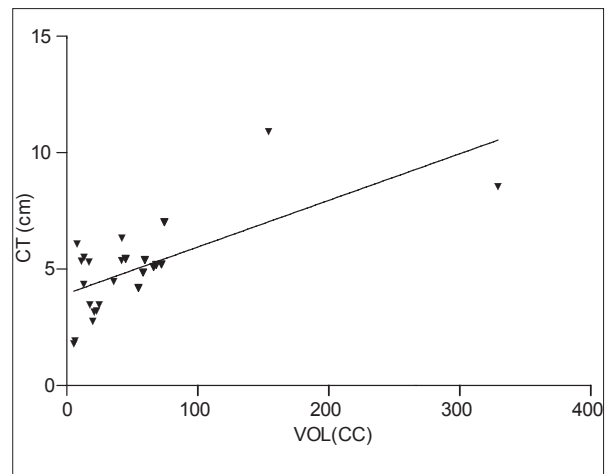


Figure 6: Scatter plot of depth cavity from CT measurement versus breast volume for 25 patients. The concordance correlation was estimated at $P = 0.31$

The tumor bed volume was correlated with the cavity depth in both U/S and CT measurements [Figures 3 and 4]. The CT depths exhibited somewhat stronger correlation ($P = 0.46$) than the U/S depths ($P = 0.37$). The depth of organs at risk (such as lung or heart), which depends on the location of the breast, is plotted against U/S and CT depths in Figures 5 and 6. Again, the CT depths exhibit stronger correlation ($P = 0.73$) than the U/S depths ($P = 0.31$), but, in this case, the difference is much more dramatic.

Discussion

Localization of a lumpectomy cavity for boost radiation can be accomplished using U/S, CT, surgical clips, other methods or a combination of techniques.

Determination of the cavity depth, however, is still not exact. This measurement is based on either U/S or CT. Depending on the location of the lumpectomy scar, boost radiation misses a portion of the cavity in 20–68% of the cases.^[19] Our study has confirmed that electron energies based on cavity depth are different under the U/S and CT measurements. Only 20% of the CT-based depth energies agreed with those determined by U/S.

Considering the increasing gap between surgery and radiotherapy planning and treatment, U/S may well underestimate the tumor bed and its margins.^[20,21] In the majority of cancer centers, a single pre-treatment CT is used for both the initial breast irradiation and the boost, without regard for the biological modifications caused by surgery. Therefore, exact delineation of the target volume is essential for tumor bed electron boost therapy. An accurate determination of cavity depth is instrumental in ensuring adequate coverage of the tumor bed while sparing normal tissue.

In this study, after taking into account the minimum depth of organs at risk and maximum cavity depth, the fraction of patients for whom electron energies determined by U/S and CT are in agreement increases to 40%. A number of techniques for delivering boost irradiation have been described in the literature. Bartelink *et al.*,^[16] in the European Organization for Research and Treatment of Cancer (EORTC) trial, and Polgar *et al.*,^[22] in the Budapest trial, indicate that local failure rates in the whole breast may be due to differences in the method of tumor bed delineation, as the differences in dosimetry were not significant. In this study, U/S is the main avenue used to target the site for boost radiation. The use of U/S for cavity depth determination differences in the method is also advocated by some centers.^[23] U/S measurements are reproducible and can identify the surgical bed up to 6 months after lumpectomy. For these reasons, many centers consider U/S localization of lumpectomy cavity to be synonymous with accurate boost treatments, rather than

relying on individual clinical judgments. CT cavity depth measurements, on the other hand, yield different results for the necessary electron energy. This may be due to the time delay; U/S measurements are typically made approximately two days prior to the completion of external beam therapy, when the wall of the lumpectomy cavity is likely to be more rigid.^[24]

Because therapeutic decisions are frequently based on the size and depth of the cavity, it is important that cavity length measurements be consistent. This criterion should apply to both repeated measurements and those made by different operators. No clinical limits of agreement were provided for this study; thus, our data may suffer from inter-operator and intra-operator variability. To partially address this problem, we calculated the bias between the two U/S and CT measurements using a Bland-Altman^[18] plot. The divergence between U/S and CT depths may also come from variations in the mode of U/S data acquisition: improper probe pressure, an untrained technician or a combination of factors can contribute to the 40% difference in cavity depths obtained by the two methods.

In one study, Helyer *et al.*^[25] reported that the electron energy derived from U/S depth cavity location has to be changed in approximately 60% of the patients when the data are compared with clinical localization. The same concerns were echoed by Birdwell *et al.*^[26] in a similar fashion. The accuracy of site size and depth estimates obtained by other methods has been also investigated in the literature. Macthay *et al.*^[27] reported on 316 cases where the cavity depth and location of the excision were based on surgical scars alone. They showed that inadequate coverage happens in 10–36% of the cases.

Furthermore, Oh *et al.*^[10] demonstrated that CT scans guided by the scar and obtained before the start of the boost do not guarantee success: 53.8% of the cases resulted in geographical misses. A similar observation was made by Regine *et al.*^[11] in a study of 17 patients using CT planning. Only 29% of the patients received adequate treatment; the rest experienced various geographical misses.

While traditional electron beams with cut-outs were used for boost irradiation in the present study, others have reported on the dosimetric results of more innovative methods. Vaidya *et al.*^[28] reported a local recurrence of 2.6% after 5 years when an intra-operative radiotherapy (IORT) boost was followed by external beam radiation therapy. Lemanski *et al.*^[29] also suggest that IORT be given as a boost after breast-conserving surgery, rather than conventional fractionated boost radiation. Reitsamer *et al.*^[30] showed that immediate IORT boost and WBRT yield excellent local control at 5 years. Furthermore, their approach was associated with a significantly lower rate of ipsilateral breast tumor recurrence compared with a similar cohort treated

with WBRT and conventional boost. Luini *et al.*^[31] noted that IORT aids in breast conservation, as reducing the radiation field dramatically reduces the exposure of normal tissues. Furthermore, the patient's quality of life is better because the radiation course is much shorter: one session rather than 5–6 weeks.

There are conflicting reports on the performance of various imaging procedures for cavity depth and localization. Each method has advantages and disadvantages. Compared with U/S measurements, the CT images obtained in our study yield electron energies approximately 40% higher due to the changes in cavity characteristics and size associated with an increased interval between surgery and data collection, as well as the effects of radiation on soft tissues. Because the CT images are presumably poorer, U/S is commonly thought to be a more accurate method of defining boost fields and prescribing the appropriate depth. This study shows that U/S and CT provide different results. Therefore, the need of a third party such as surgical clips is paramount for better depth cavity determination. It is urgent for breast surgeons to place surgical clips in the walls of the lumpectomy cavity to allow CT and U/S to be used interchangeably and also as a combined technique.

References

- Ries LA, Eisner MP, Kosary CL. SEER Cancer Statistics Review, 1973–1997. National Cancer Institute, Bethesda, MD, USA 2000.
- Arriagada R, Le MG, Rochard F. Conservative treatment versus mastectomy in early breast cancer: patterns of failure with 15 years of follow-up data. *J Clin Oncol* 1996;14:1558-64.
- Blichert-Toft M, Rose C, Andersen JA. Danish randomized trial comparing breast conservation therapy with mastectomy: Six years of life-table analysis. *J Natl Cancer Inst Monogr* 1992;11:19-25.
- Fisher B, Anderson S, Redmond CK. Reanalysis and results after 12 years of follow-up in a randomized clinical trial comparing total mastectomy with lumpectomy with or without irradiation in the treatment of breast cancer. *N Engl J Med* 1995;33:1456-61.
- Lichter AS, Lippman ME, Danforth DN. Mastectomy versus breast-conserving therapy in the treatment of stage I and II carcinoma of the breast: A randomized trial at the National Cancer Institute. *J Clin Oncol* 1992;10:976-83.
- Van Dongen JA, Bartelink H, Fentiman IS. Randomized clinical trial to assess the value of breast-conserving therapy in stage I and II breast cancer, EORTC 10801 Trial. *J Natl Cancer Inst Monogr* 1992;11:15-8.
- Veronesi U, Salvadori B, Luini A. Breast conservation is a safe method in patients with small cancer of the breast: Long term results of three randomized trials of 1973 patients. *Eur J Cancer* 1995;31A:1574-9.
- Schnitt SJ, Abner A, Gelman R, Connolly JL, Recht A, Duda RB, *et al.* The relationship between microscopic margins of resection and the risk of local recurrence in patients with breast cancer treated with breast-conserving surgery and radiation therapy. *Cancer* 1994;74:1746-51.
- Fisher ER, Anderson S, Redmond C, Fisher B. Ipsilateral breast tumor recurrence and survival following lumpectomy and irradiation: Pathological findings from NSABP protocol B-06. *Semin Surg Oncol* 1992; 8:161-6.
- Oh KS, Feng MK, Kent AC, Yanke B, Pierce LJ. Planning the breast tumor bed boost: Changes in the excision cavity volume and surgical scar location after breast-conserving surgery and whole breast irradiation. *Int J Radiat Oncol Biol Phys* 2006;66:680-6.
- Regine WF, Ayyangar KM, Komarnicky LT, Bhandare N, Mansfield CM. Computer-CT planning of the electron boost in definitive breast irradiation. *Int J Radiat Oncol Biol Phys* 1991;20:121-5.
- Warszawski A, Baumann R, Karstens JH. Sonographic guidance for electron boost planning after breast-conserving surgery. *J Clin Ultrasound JCU* 2004;32:333-7.
- Goldberg H, Prosnitz RG, Olson JA, Marks LB. Definition of postlumpectomy tumor bed for radiotherapy for radiotherapy boost field planning: CT versus surgical clips. *Int J Radiat Oncol Biol Phys* 2005;63:209-13.
- Smitt MC, Birdwell RL, Goffinet DR. Breast electron boost planning: Comparison of CT and US. *Radiology* 2001;219:203-6.
- Berrang TS, Truong PT, Popescu C, Drever L, Kader HA, Hilts ML, *et al.* 3D ultrasound can contribute to planning CT to define the target for partial breast radiotherapy. *Int J Radiat Oncol Biol Phys* 2009;73:375-83.
- Bartelink H, Horiot JC, Poortmans P, Struikmans H, Van den Bogaert W, Barillot I. Recurrence rates after treatment of breast cancer with standard radiotherapy with or without additional radiation. *N Eng J Med* 2001;345:1378-87.
- Wong P, Heimann R, Hard D, Archambault J, Muanza T, K. Sultanem K: A multi-institutional comparison study evaluating the use of 3D-ultrasound for defining the breast tumor bed for IGRT in chemotherapy versus non-chemotherapy patients. *Int J Radiat Oncol Biol Phys* 2008; 72:S179-80.
- Bland JM, Altman DG. Statistical methods for assessing agreement between two methods of clinical measurement. *Lancet* 1986;1:307- 10.
- Bedwinek J. Breast conserving surgery and irradiation: The importance of demarcating the excision cavity with surgical clips. *Int J Radiat Oncol Biol Phys* 1993;26:675-9.
- Machtay M, Lanciano R, Hoffman J, Hanks GE. Inaccuracies in using the lumpectomy scar for planning electron boosts in primary breast carcinoma. *Int J Radiat Oncol Biol Phys* 1994;30:43-8.
- Kovner F, Agay R, Merimsky O, Stadler J, Klausner J, Inbar M. Clips and scar as the guidelines for breast radiation boost after lumpectomy. *Eur J Surg Oncol* 1999;25:483-6.
- Polgar C, Major T, Fodor J, Nemeth G, Orosz Z, Sulyok Z. High-dose-rate brachytherapy alone versus whole breast radiotherapy with or without tumor bed boost after breast-conserving surgery: Seven-year results of a comparative study. *Int J Radiat Oncol Biol Phys* 2004;60:1173-81.
- Leonard C, Harlow CL, Coffin C. Use of ultrasound to guide radiation boost planning following lumpectomy for carcinoma of the breast. *Int J Radiat Oncol Biol Phys* 1993;27:1193-7.
- Stolier AJ, Fuhrman GM, Scroggins TC, Boyer CI. Postlumpectomy insertion of MammoSite brachytherapy device using the scar entry technique: Initial experience and technical considerations. *Breast J* 2005;11:199-203.
- Helyer SJ, Moskovic E, Ashley S, Hastings L, Yamold JR. A study testing the routine use of ultrasound measurements when selecting the electron energy for breast boost radiotherapy. *Clin Oncol* 1999;11:164-8.
- Birdwell RL, Ikeda DM, Torrey MJ, Goffinet DR. Sonographic tailoring of electron beam boost site after lumpectomy and radiation therapy for breast cancer. *AJR Am J Roentgenol* 1997;168:39-40.
- Machtay M, Lanciano R, Hoffman J, Hank GE. Inaccuracies in using lumpectomy scar for planning electron boosts in primary breast carcinoma. *Int J Radiat Oncol Biol Phys* 1994;30:43-8.
- Vaidya JS, Baum M, Tobias JS, Massarut S, Wenz F, Murphy O, *et al.* Targeted intraoperative radiotherapy (TARGIT) yields very low recurrence rates when given as a boost. *Int J Radiat Oncol Biol Phys* 2006;66:1335-8.
- Lemanski C, Azria D, Thezenas S, Gutowski M, Saint-Aubert B, Rouanet P, *et al.* Intraoperative radiotherapy given as a boost for early breast cancer: Long-term clinical and cosmetic results. *Int J Radiat*

- Oncol Biol Phys 2006;64:1410-5.
30. Reitsamer R, Sedlmayer F, Kopp M, Kametriser G, Menzel C, Deutschmann, *et al.* The Salzburg concept of intraoperative radiotherapy for breast cancer: Results and considerations. *Int J Cancer* 2006;118:2882-7.
31. Luini A, Orecchia R, Gatti G, Intra M, Ciocca M, Galimberti V, *et al.* The pilot trial on intraoperative radiotherapy with electrons

(ELIOT): Update on the results. *Breast Cancer Res Treat* 2005;93:55-9.

How to cite this article: Gloi AM, Buchanan R. Discrepancies in determining electron energy for lumpectomy boost treatment. *J Med Phys* 2012;37:138-44.

Source of Support: Nil, **Conflict of Interest:** None declared.

Author Help: Online submission of the manuscripts

Articles can be submitted online from <http://www.journalonweb.com>. For online submission, the articles should be prepared in two files (first page file and article file). Images should be submitted separately.

1) **First Page File:**

Prepare the title page, covering letter, acknowledgement etc. using a word processor program. All information related to your identity should be included here. Use text/rtf/doc/pdf files. Do not zip the files.

2) **Article File:**

The main text of the article, beginning with the Abstract to References (including tables) should be in this file. Do not include any information (such as acknowledgement, your names in page headers etc.) in this file. Use text/rtf/doc/pdf files. Do not zip the files. Limit the file size to 1024 kb. Do not incorporate images in the file. If file size is large, graphs can be submitted separately as images, without their being incorporated in the article file. This will reduce the size of the file.

3) **Images:**

Submit good quality color images. Each image should be less than **4096 kb (4 MB)** in size. The size of the image can be reduced by decreasing the actual height and width of the images (keep up to about 6 inches and up to about 1800 x 1200 pixels). JPEG is the most suitable file format. The image quality should be good enough to judge the scientific value of the image. For the purpose of printing, always retain a good quality, high resolution image. This high resolution image should be sent to the editorial office at the time of sending a revised article.

4) **Legends:**

Legends for the figures/images should be included at the end of the article file.