

Hemodynamic Changes in Patients with Chronic Internal Carotid Artery Occlusion After Recanalization

Chao Xiao^{1,2,*}, Xiuen Chen^{1,*}, Lizhi Lu³, Ziming Ye², Xiangren Chen², Meiyu Dong⁴, Chao Qin² 

¹Department of Neurology, Liuzhou People's Hospital Affiliated to Guangxi Medical University, Liuzhou, People's Republic of China; ²Department of Neurology, The First Affiliated Hospital of Guangxi Medical University, Nanning, People's Republic of China; ³Department of Neurology, Forsea Life Insurance Nanning Hospital, Nanning, People's Republic of China; ⁴The First Clinical Medical College of Guangxi Medical University, Nanning, People's Republic of China

*These authors contributed equally to this work

Correspondence: Chao Qin, Department of Neurology, First Affiliated Hospital of Guangxi Medical University, No. 6 Shuangyong Road, Nanning, Guangxi, 530021, People's Republic of China, Email mdqc2019@126.com

Objective: This study aimed to investigate the feasibility and clinical efficacy of endovascular recanalization in patients with chronic internal carotid artery occlusion (CICAO) and explore the application value of computed tomography perfusion (CTP) in endovascular recanalization.

Methods: This non-randomized controlled study included 41 patients with CICAO. All patients received active medical treatment. In this study, patients with successful endovascular recanalization and those who refused endovascular recanalization were included in the recanalization and medication groups, respectively. Before and 90 days after treatment, cognitive function was evaluated using the Montreal Cognitive Function Assessment, and neurological function was evaluated using the National Institutes of Health Stroke Scale and modified Rankin scale. For patients with successful endovascular recanalization, brain CTP imaging was performed to evaluate hemodynamic changes in patients with CICAO before and three days after treatment.

Results: Overall, 41 symptomatic patients with CICAO were included, and 20 patients received endovascular recanalization therapy, with a success rate of 60% (12/20). The perioperative complication rate was 15% (3/20); there were no events such as hyperperfusion, distal embolism, vascular rupture, or cerebral hemorrhage, and no stroke-related or death-related events. Patients were divided into a medication group (n=21) and recanalization group (n=12). After 90 days of follow-up, patients in the recanalization group showed greater improvement in overall cognitive and neurological function. In addition, successful endovascular recanalization significantly improved cerebral blood perfusion on the occluded side of patients with CICAO.

Conclusion: Successful recanalization can effectively improve the overall cognitive and neurological functions of patients in the short term. CTP can be used to quantitatively evaluate not only the cerebral hemodynamic changes after internal carotid artery occlusion but also the improvement of cerebral blood perfusion after successful endovascular recanalization, which provides a reliable method for postoperative follow-up.

Keywords: hemodynamics, chronic internal carotid artery occlusion, endovascular recanalization, clinical effect

Introduction

Atherosclerotic stenosis of the internal carotid artery is an important cause of ischemic stroke.^{1,2} Chronic internal carotid artery occlusion (CICAO) is the last stage of atherosclerotic carotid artery stenosis. CICAO is usually considered to have been occluded for more than 4 weeks.³⁻⁷ Even with the best medical treatment, symptomatic patients with CICAO still have an annual stroke recurrence rate of 6-30%.⁸⁻¹⁰ Additionally, patients with CICAO are prone to low perfusion and cognitive dysfunction. Previous studies have shown that the incidence of cognitive impairment in patients with CICAO is approximately 1/2-2/3, which is not limited to specific cognitive impairments.¹¹

After the occlusion of the internal carotid artery, according to the compensation situation, the hemodynamics of the intracranial vessels on the occlusive side can be normal or abnormal, and patients with good blood flow compensation can appear asymptomatic, while those with poor blood flow compensation are prone to events such as transient ischemic attack (TIA), ischemic stroke, chronic ocular ischemia, and cognitive dysfunction.^{12–15} Brain computed tomography perfusion (CTP) imaging, as a cutting-edge technology in the field of CT application, can quantitatively evaluate the perfusion status of brain tissue, and perfusion abnormalities can be found 30 min after the occurrence of cerebral ischemic events.¹⁶ In the clinical studies DIFUSE-III and DAWN, CTP was used to evaluate the core area of infarction and ischemic penumbra, which confirmed that endovascular mechanical thrombectomy is still effective within 6–24 hours of acute cerebral infarction.^{17,18}

In the surgical treatment of patients with CICA0, carotid endarterectomy can not only increase cerebral blood perfusion but also improve cognitive function. The disadvantage is that large trauma can easily lead to infection and treatment is limited to the extracranial vessels.¹⁹ The safety and effectiveness of intracranial bypass grafting are controversial.²⁰ Endovascular recanalization in the treatment of CICA0 has been a research hotspot and difficulty in recent years; there is a lack of large-scale clinical randomized trials, and management opinions continue to be controversial. Therefore, this aimed to assess the feasibility, safety, and short-term clinical efficacy of endovascular recanalization in the treatment of patients with CICA0 and explore the application value of CTP in CICA0 research.

Methods

Study Population

Patients with symptomatic unilateral CICA0 who were hospitalized in the Department of Neurology of the First Affiliated Hospital of Guangxi Medical University between July 2021 and January 2022 were included in the study. CICA0 defined as occlusion of the internal carotid artery beyond the acute phase and at least 4 weeks from the date of initial diagnosis. Inclusion criteria were as follows: age >18 years with complete internal carotid artery occlusion confirmed by digital subtraction angiography (DSA). The exclusion criteria were as follows: ipsilateral middle cerebral artery occlusion or severe stenosis; severe neurological dysfunction (modified Rankin scale [mRS] score ≥ 4); life expectancy <1 year due to other medical conditions; dementia, depression, Parkinson's disease, or multiple sclerosis; arteriovenous malformations or cerebral aneurysms; recent history of intracranial hemorrhage; and use of antiplatelet drugs. The clinical and imaging data of all patients were gathered in detail.

All patients received aggressive medical treatment including dual antiplatelet therapy, intensive lipid-lowering therapy, and risk factor management. Endovascular recanalization was performed after informed consent was obtained from the patient and his family. For patients with successful endovascular recanalization, CTP examination was performed within three days to further evaluate the effect of endovascular recanalization on hemodynamic changes. Patients were divided into two groups: those with successful endovascular recanalization were included in the recanalization group, and those who refused endovascular recanalization therapy were included in the medication group. Prior to the 90-day follow-up, patient carotid patency will be assessed by vascular ultrasound or CTA. This study prospectively followed the changes in global cognitive function and neurological function in the two groups before and 90 days after treatment as an index to evaluate the clinical efficacy of endovascular recanalization on CICA0. This study was conducted in accordance with the Declaration of Helsinki and approved by the First Affiliated Hospital of Guangxi Medical University Ethical Review Committee. Approval Number: 2023-E039-01.

Cognitive Function and Neurological Function Assessment

The Montreal Cognitive Function Assessment (MoCA) scale was used to score cognitive function, including eight cognitive areas: visual space and executive function, naming, memory, attention, language, abstraction, delayed recall, and orientation. The maximum score is 30, and the higher the score, the higher the cognitive function.²¹ Neurological impairment was assessed by using the National Institutes of Health Stroke Scale (NIHSS). The highest possible score is 42, and the higher the score, the more severe the neurological impairment.²² The activities of daily living of the patients were evaluated using the mRS.

Endovascular Recanalization Procedures

All procedures were performed under general anesthesia by two qualified interventional neuroradiologist. After vascular access was achieved, intravenous heparin was administered via a bolus (75 U/kg), followed by half that dose 1 hour later. If the procedure lasted longer than 2 h, a quarter of the initial dose was administered every hour thereafter. The guide catheter was advanced into the internal carotid artery as high as possible by vessel tortuosity. Under roadmap guidance, a 200cm microwire (Synchro-14) was advanced coaxially through the 150cm microcatheter (Excelsior SL-10) to traverse the occluded segment. When there was a large hard vascular plaque at the beginning of the internal carotid artery, which made the microwire and microcatheter unable to pass through, the tail end of the 0.035-inch angiographic guide wire was used to carefully try to penetrate it. The microwire was then withdrawn and the microcatheter was injected with contrast medium to verify that the tip of the microcatheter was located in the true distal lumen. The procedure was terminated if multiple attempts were tried and the microcatheter/microwire system could not cross the occluded segments and enter the true lumen distally.

After steering into the true lumen, the location of the microcatheter/microwire system was directed to the occlusion. Subsequently, an exchange length microwire was placed in the correct anchoring position, followed by the removal of the microcatheter. A balloon angioplasty (Gateway, 1.5–3.5mm, Stryker Neurovascular) was performed over the exchange microwire to across the occlusion. The balloon was selected according to the diameter of the proximal segment adjacent to the lesion and the estimated length of the occluded segment. For safety reasons, the maximum diameter of the predilated balloon was less than 80% of the estimated diameter of the lesion, and the balloon length was as short as possible but at least covering the lesion length. Angiography was performed to evaluate the degree of residual stenosis and antegrade blood flow after balloon dilatation to determine the need for endovascular stent implantation. If stent implantation was required, the stent (Precise, Stryker Neurovascular, Florida, USA; Neuroform EZ, Stryker Neurovascular, Cork, Ireland;) was deployed across the occlusion. Stent size was determined based on the proximal and distal diameters of the lesion, as well as the length of the occluded segment. Postprocedural angiography was performed to confirm patency and to assess residual stenosis and antegrade flow (Figure 1). Technical success was defined as vessel recanalization with modified TIC1 grade 2b or 3 and residual stenosis of <50%.²³

Brian CTP Imaging

Using Siemens SOMATOM Force open-source CT equipment for inspection, the scanning parameters were as follows: voltage=70 kV, current=100 mAs, scanning time=45.45 s, delay time=2 s, layer thickness=5 mm, collimation=192×0.6 mm, and obtain 1050 initial images. During the rapid injection of nonionic iodine contrast medium (50 mL) into the anterior elbow vein, continuous CT scans were performed at the blood supply areas of the bilateral middle cerebral artery (MCA), anterior cerebral artery (ACA), and bilateral cerebellar hemispheres, and the time-density curve of the region of interest was obtained. Finally, post-processing was carried out using the Siemens workstation automatic perfusion software syngo.via (For Force-76159). The deconvolution model was used as the algorithm, and various perfusion parameters were calculated: cerebral blood flow (CBF), cerebral blood volume (CBV), mean transit time (MTT), and time to top (T-Max).

Statistical Analysis

IBM SPSS Statistics 26.0 software was used for statistical analysis. Counting data are presented as rate and percentage (%), and Fisher's test was used to compare between groups. The measurement data were continuous variables, and the continuous data with normal distribution were expressed as mean (X) and standard deviation (s). Paired sample *t*-test or independent sample *t*-test was used for comparison between groups. Continuous data with non-normal distribution are presented as the median (M) and quartile spacing (IQR), and the Mann–Whitney *U*-test was used for inter-group comparisons. Statistical significance was set at $P < 0.05$.

Results

Patient Baseline Features

Forty-one patients with symptomatic unilateral CICA0 from July 2021 to January 2022 were included. 20 patients agreed to undergo cerebrovascular recanalization; 21 patients refused to undergo endovascular recanalization.

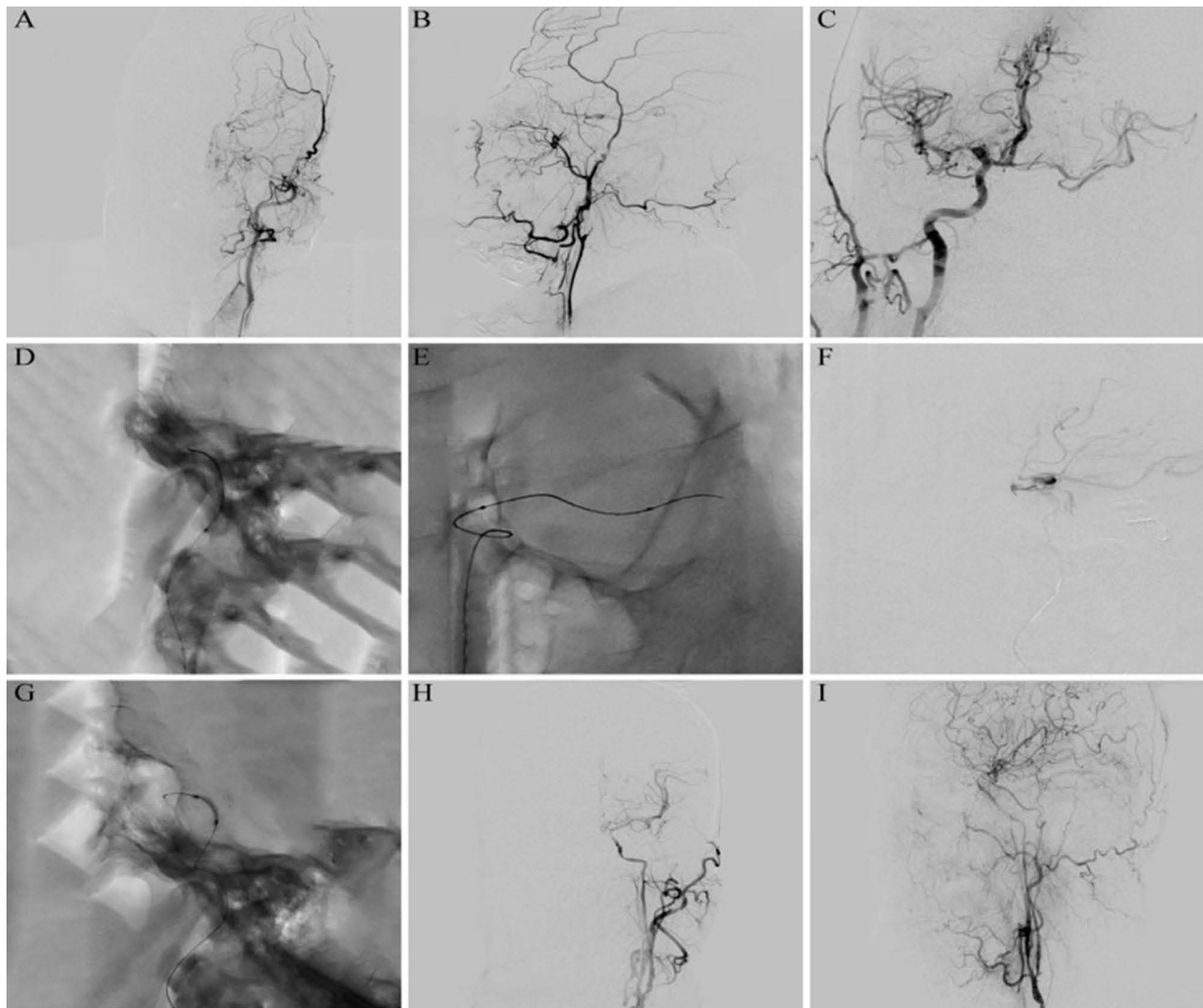


Figure 1 Representative case. Digital subtraction angiography showed occlusion of the left internal carotid artery with a conical stump (**A** and **B**). Digital subtraction angiography indicates the opening of anterior communicating artery (**C**). Microwire and microcatheter passed through the occlusive segment (**D**). Microwire and microcatheter reach M1 segment of left middle cerebral artery (MCA) (**E**). Microcatheter angiography was used to verify that the tip of the microcatheter was located in the real distal cavity (**F**). Balloon dilation procedure (**G**). Digital subtraction angiography indicated the left internal carotid artery was successfully recanalized, achieving a TICl grade of 3 (**H–I**).

The success rate of endovascular recanalization was 60% (12/20), and the incidence of perioperative complications was 15% (3/20) in the recanalization group, including one case of carotid sinus reaction and two cases of cavernous sinus fistula. Patients with cavernous sinus fistula will undergo a second operation to block the fistula. Postoperative neurological function scores in patients with spongy sinus fistula were consistent with preoperative scores. Patients who experienced carotid sinus reactions recovered rapidly to preoperative status. At 90-day follow-up, no patients in the recanalization group experienced re-occlusion.

There were no events such as hyperperfusion, distal embolization, vascular rupture, and cerebral hemorrhage. There were no strokes or death-related events, and there were no significant differences in education level, collateral circulation grade, MoCA score, NIHSS score, mRS, or baseline data between the two groups. The baseline data for all patients are shown in [Table 1](#).

Short-Term Prognosis

The overall cognitive and neurological functions improved after 90 days in the endovascular recanalization and medication groups. However, compared to the medication group, the endovascular recanalization group benefited more from overall cognitive and neurological functions. Compared with the medication group, the recanalization group had

Table 1 Baseline Clinical Variables

Variable	Recanalization Group (n=12)	Medication Group (n=21)	p value
Male (%)	9(75.0)	17(81.0)	0.686
Age (years)	61.3±8.4	62.8±9.3	0.646
Education (years)	10.5(6.8–12.0)	12.0(7.5–14.0)	0.684
Risk factors.			
Hypertension (%)	10(83.3)	15(71.4)	0.678
Diabetes (%)	4(33.3)	4(19.0)	0.420
Coronary Artery Disease (%)	1(8.3)	0(0.0)	0.364
Hyperlipidemia (%)	3(25.0)	1(4.8)	0.125
Hyperuricemia (%)	3(25.0)	2(10.0)	0.338
Smoker (%)	8(66.7)	11(52.4)	0.486
Alcohol user (%)	5(41.7)	9(42.9)	1.000
Left occlusion (%)	7(58.3)	14(66.7)	0.716
Collateral circulation grade	2(1–2)	2(2–3)	0.886
Unilateral Clinical Symptoms			0.125
Ischemic stroke (%)	6(50.0)	16(76.2)	
TIA(%)	2(16.7)	4(19.0)	
Dizziness/Headache (%)	4(33.3)	1(4.8)	
MoCA Before Treatment	22.7±2.4	22.3±2.8	0.728
MoCA 90 days	24.3±2.0	22.5±2.6	0.047
mRS Before Treatment	1.5((1.0–2.0)	2.0(1.0–2.5)	0.628
mRS After 90 days	1(0–1.8)	2(1.0–2.5)	0.026
NIHSS Before Treatment	1(0–3.5)	1(0.5–5.0)	0.345
NIHSS After 90 days	0 (0–1.5)	1(0–5.0)	0.031

Notes: Smoker: individuals who smoked any tobacco in the past 12 months. Alcohol user: current users of any form of alcoholic drinks. Collateral circulation: Evaluation by ASITN/SIR grade.

Abbreviations: TIA, transient ischemic attack; MoCA, Montreal cognitive function assessment; NIHSS, national institutes of health stroke scale; mRS, modified Rankin scale.

a higher MoCA score (24.3±2.0 vs 22.5±2.6, $p<0.05$) and lower mRS (1[0–1.8] vs 2 [1.0–2.5], $p=0.026$) and NHISS scores (0 [0–1.5] vs 1 [0–5.0], $p=0.031$). The details are listed in [Table 1](#).

Changes in Hemodynamics

Of the 12 patients with successful endovascular recanalization, 10 patients completed the CTP examination before and after surgery, and the hemodynamic performance of the blood supply area of the middle cerebral artery (MCA), perfusion delay on the occlusive side before endovascular recanalization, and cerebral blood volume (CBV) did not decrease significantly. Before endovascular recanalization, there was no significant increase in CBV (3.63±0.55 vs 3.48±0.69, $p=0.476$) between the occlusive side and the normal side, while cerebral blood flow (CBF) decreased (54.91±10.20 vs 61.69±15.35, $p=0.037$), mean transit time (MTT) was prolonged (5.04±0.98 vs 3.78 ±0.40, $p=0.001$) and T-Max was prolonged (4.31±1.44 vs 1.68±0.66, $p=0.000$). The details are shown in [Table 2](#) and [Figure 2](#).

After endovascular recanalization, the hemodynamics of the occlusive side were significantly improved. There was no significant difference in CBV (3.63±0.55 vs 4.25±0.84, $p=0.017$), CBF (54.91±10.20 vs 72.00±8.41, $p=0.002$), MTT (5.04±0.98 vs 3.81±0.45, $p=0.006$), or T-Max (4.31±1.44 vs 2.27 ± 1.18, $p=0.002$) between the occlusive side and the normal side after endovascular recanalization, and there was no significant difference in bilateral cerebral blood perfusion ([Table 2](#)). Successful endovascular recanalization can effectively improve delayed perfusion of the MCA on the occluded side and increase cerebral blood perfusion.

Similar to the blood supply area of the MCA before recanalization, the hemodynamics of the blood supply area of the ACA also showed delayed perfusion on the occluded side, and the blood volume did not decrease significantly. Before endovascular recanalization, there was no significant increase in CBV (3.34±0.56 vs 3.27±0.56, $p=0.596$) between the occlusive side and the normal side, while CBF (52.74±6.64 vs 61.01±12.20, $p=0.066$) decreased and MTT (4.68±0.80 vs

Table 2 Perfusion of the Middle Cerebral Artery

Variable	CBV (mL/100g)		CBF (mL/100mL/min)		MTT (s)		T-Max (s)	
	Occlusive Side	Normal Side	Occlusive Side	Normal Side	Occlusive Side	Normal Side	Occlusive Side	Normal Side
Before	3.63±0.55	3.48±0.69	54.91±10.20*	61.69±15.35	5.04±0.98**	3.78±0.40	4.31±1.44**	1.68±0.66
After	4.25±0.84 ^Δ	3.70±0.61	72.00±8.41 ^{ΔΔ}	67.40±14.62	3.81±0.45 ^{ΔΔ}	3.72±0.40	2.27±1.18 ^{ΔΔ}	1.94±0.85

Notes: Comparison between occlusive side and normal side before recanalization: **p<0.01, *p<0.05; Comparison before and after recanalization: ^{ΔΔ}p<0.01, ^Δp<0.05.

Abbreviations: CBV, cerebral blood volume; CBF, cerebral blood flow; MTT, mean transit time; T-Max, time to top.

3.74±0.43, p= 0.004) and T-Max (3.07±1.40 vs 1.78±0.70, p=0.019) were prolonged. After endovascular recanalization, the cerebral hemodynamics on the occlusive side significantly improved. CTP showed no significant difference in CBV, CBF, MTT, or T-Max in the bilateral anterior cerebral arteries after recanalization. Successful endovascular recanalization can effectively improve delayed perfusion of the ACA on the occlusive side and increase cerebral blood perfusion, as shown in Table 3 and Figure 3.

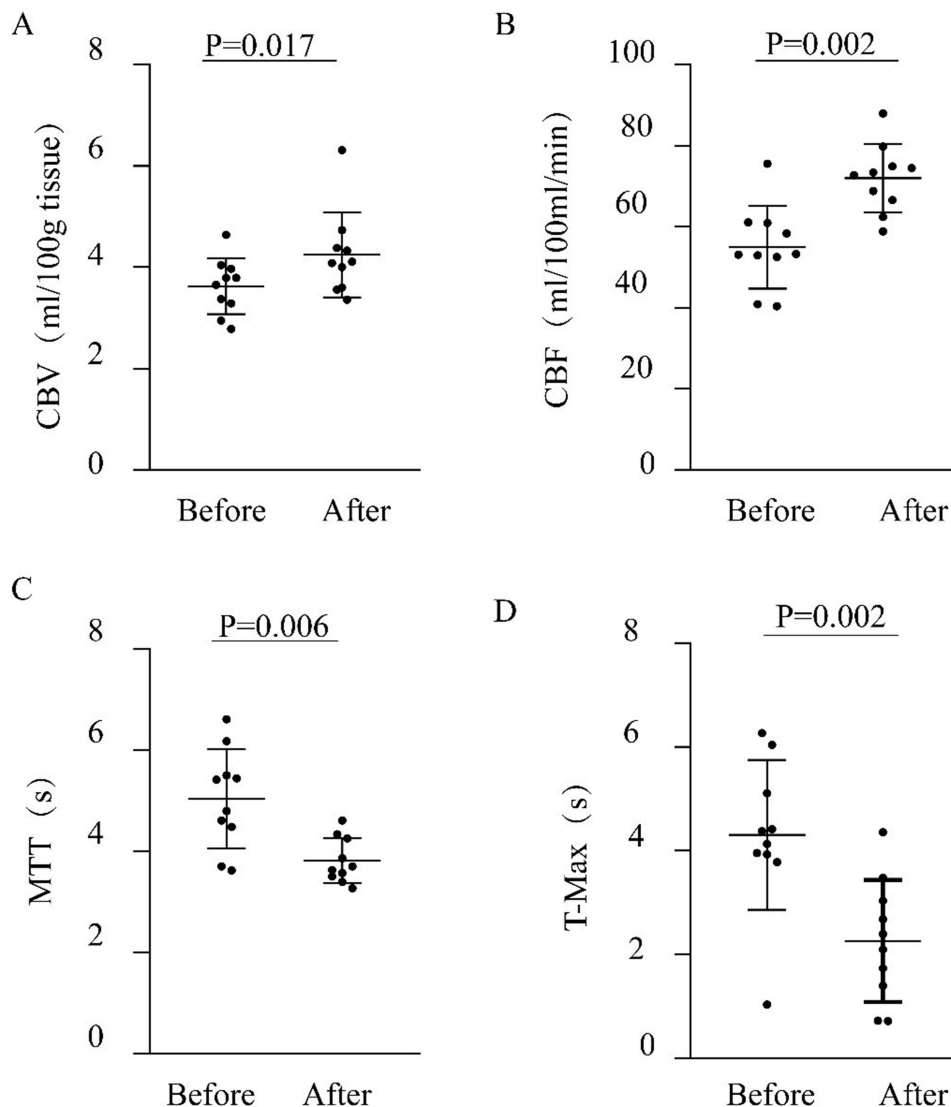


Figure 2 Preoperative and postoperative hemodynamics changes in the blood supply area of the middle cerebral artery (MCA) on the same side of the occlusion. Change in cerebral blood volume (CBV) (A), change in cerebral blood flow (CBF) (B), change in mean transit time (MTT) (C), change in time to top (T-Max) (D).

Table 3 Perfusion of the Anterior Cerebral Artery

Variable	CBV (mL/100g)		CBF (mL/100mL/min)		MTT (s)		T-Max (s)	
	Occlusive Side	Normal Side	Occlusive Side	Normal Side	Occlusive Side	Normal Side	Occlusive Side	Normal Side
Before	3.34±0.56	3.27±0.56	52.74±6.64	61.01±12.20	4.68±0.80**	3.74±0.43	3.07±1.40**	1.78±0.70
After	3.91±0.61	3.58±0.31	68.31±12.23 ^{△△}	65.73±11.45	3.58±0.38 ^{△△}	3.57±0.56	1.62±0.41 ^{△△}	1.77±0.49

Notes: Comparison between occlusive side and normal side before recanalization: ** $p < 0.01$; Comparison before and after recanalization: ^{△△} $p < 0.01$.

Abbreviations: CBV, cerebral blood volume; CBF, cerebral blood flow; MTT, mean transit time; T-Max, time to top.

There was no significant difference in cerebral hemodynamics in the bilateral cerebellar hemispheres before and after the operation, and endovascular recanalization did not affect blood supply to the cerebellar hemispheres. The details are listed in Table 4.

Discussion

This non-randomized, non-double blinded cohort study aimed to explore the feasibility and clinical efficacy of endovascular recanalization in patients with CICA0. The results of this study show that endovascular recanalization is

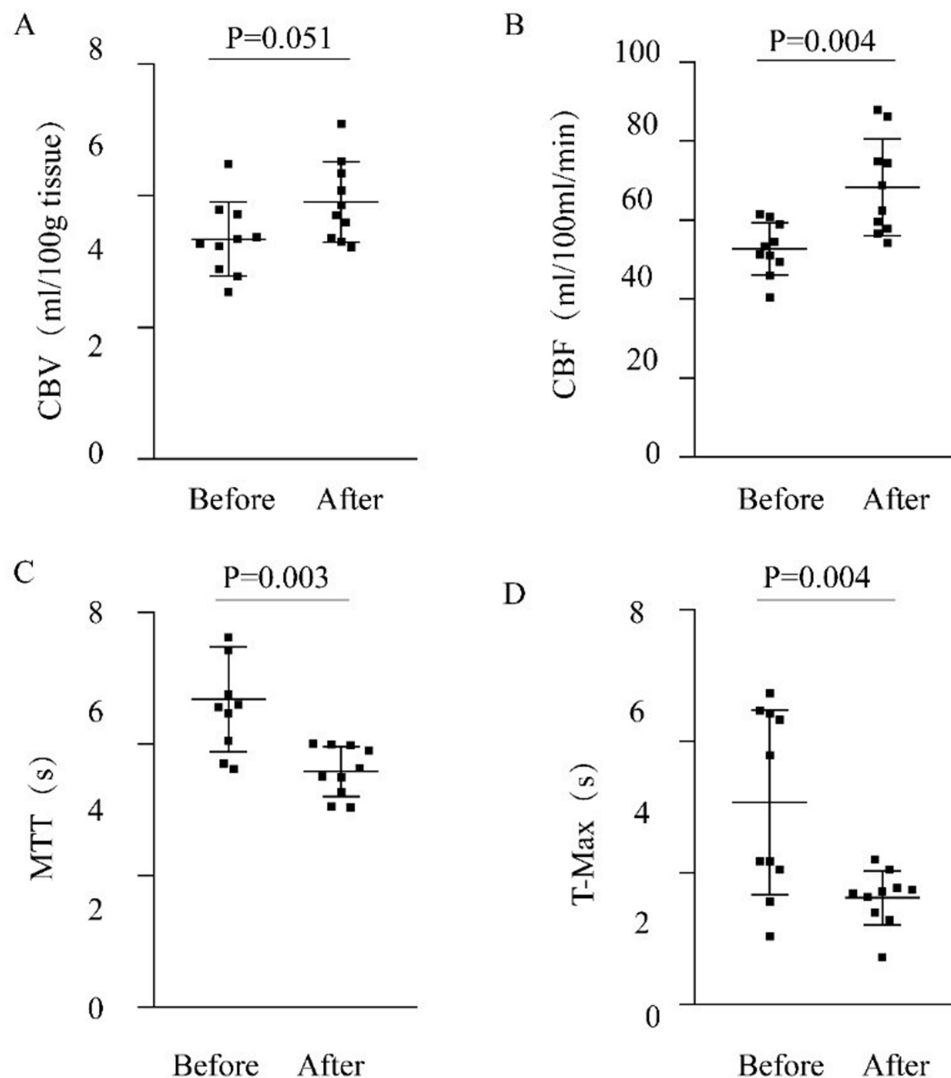


Figure 3 Preoperative and postoperative hemodynamics changes in the blood supply area of the anterior cerebral artery (ACA) on the same side of the occlusion. Change in cerebral blood volume (CBV) (A), change in cerebral blood flow (CBF) (B), change in mean transit time (MTT) (C), change in time to top (T-Max) (D).

Table 4 Perfusion of the Cerebellar Hemisphere

Variable	CBV (mL/100g)		CBF (mL/100mL/min)		MTT (s)		T-Max (s)	
	Left	Right	Left	Right	Left	Right	Left	Right
Before	3.91±0.41	3.77±0.44	55.73±8.23	60.80±5.80	4.08±0.89	4.31±0.78	1.82±0.93	1.98±0.70
After	3.67±0.34	3.56±0.48	58.58±9.09	59.19±8.70	3.58±0.60	3.99±0.55	2.17±0.73	2.11±0.50

Abbreviations: CBV, cerebral blood volume; CBF, cerebral blood flow; MTT, mean transit time; T-Max, time to top.

feasible for patients with symptomatic CICA0 and can improve their short-term overall cognitive and neurological functions. In addition, as a cutting-edge technology in the application of CT, CTP can not only be used to evaluate the perfusion of CICA0 patients, but also to prove the effectiveness of endovascular recanalization and provide more reliable clinical indicators for postoperative follow-up.

According to an epidemiological analysis based on White Americans abroad, the incidence of symptomatic internal carotid artery occlusion (ICAO) is approximately 6 per 100,000 individuals.²⁴ However, the incidence of asymptomatic ICAO remains unclear. Most cases are accidentally found during physical examination, and the prevalence rate is theoretically higher.^{25,26} In a long-term follow-up based on ICAO, it was found that the stroke recurrence rate was 8% at 30 days, 10% at 1 year, and 14% at 5 years.⁹ At present, there is a great controversy about endovascular recanalization in patients with CICA0 at home and abroad; however, recent studies have shown that endovascular recanalization in the treatment of symptomatic CICA0 patients is safe and feasible, although the operation has certain risks and adverse events.^{3,7,27–30} The technical success rate in this study was 60% (12/20). Similar to previous studies, failure to obtain a true ICA true lumen was the main reason for the failure of the technique.⁷ Severe vascular calcification or excessive thrombus load may be the cause of operation failure.³¹ All the patients with successful recanalization achieved good cerebral blood perfusion. The incidence of perioperative complications was 15% (3/20), including one case of carotid sinus reaction and two cases of cavernous fistula. There were no complications such as high perfusion, distal embolization, vascular rupture, stroke events, or death-related events. A meta-analysis published in the International Journal in July 2021 searched the PubMed/MEDLINE and EMBASE databases and included eight cohort studies on CICA0 until January 2, 2020. A total of 276 patients had CICA0; 18.9% were women, with an average age of 64.3 years, a perioperative mortality rate of 1.64%, and an early stroke incidence of 3.3%. The average follow-up period was 23.4 months (0.25–84 months), the late mortality rate was 1.89% (5/265), the stroke incidence rate was 3.4% (9/265), and the procedural success rate was 66.9%.³² The reasons for the significant differences in the success rate of interventional recanalization and the incidence of complications in different centers are complex, including the technical level of the operator, the material technology at that time, the duration of vascular occlusion, and the length of vascular occlusion. It also indicates that each center has different criteria for recanalization. Generally, it is safe and feasible to perform endovascular recanalization of CICA0 at the existing technical level and facilities.

In this study, all patients received aggressive medical treatment, including dual antiplatelet therapy, intensive lipid-lowering therapy, and risk factor management. Patients with successful endovascular recanalization were included in the recanalization group, and patients without surgery were classified into the medication group. There were no significant differences in education level, collateral circulation grade, MoCA score, NIHSS score, mRS score, and baseline data between the two groups. After 90 days, the overall cognitive function and neurological function of both groups improved compared to those at admission, but the benefit was greater in the recanalization group. Technical success rate of this study was similar to that in some related reports. In the study by Fan et al, 40 patients with symptomatic CICA0 were randomly divided into an endovascular recanalization group (n=18) and a drug treatment group (n=22). In this study, the recanalization success rate was 88.9% (16/18 patients). After 3 and 6 months of follow-up, successful carotid artery stent implantation improved nervous system function and overall cognitive function better than the medication group.³ Our results are similar. In the RECON study, the results showed that there were no significant differences in cognitive function between extracranial-intracranial vascular bypass therapy and medical drug therapy during a 2-year follow-up.³³ Zanaty et al suggested that bypass surgery cannot improve the cognitive function of patients with CICA0 because it only improves the cerebral blood perfusion of the blood supply area of the MCA; it cannot provide sufficient blood perfusion to the ipsilateral ACA and the surrounding watershed area, resulting in insufficient perfusion on the medial side of the

cerebral hemisphere, especially the limbic lobe system.⁶ Compared to bypass surgery, endovascular recanalization can improve blood perfusion in the entire cerebral hemisphere, which is an obvious advantage. Although endovascular recanalization can significantly improve the overall cognitive and neurological functions of patients with CICA0 in the near future, larger samples and long-term follow-up studies are needed to confirm this finding.

In our study, 10 of the 12 patients with successful recanalization underwent CTP examination before and after surgery. The results of the preoperative CTP examination showed that the CBV of the occlusive hemisphere did not decrease significantly but was compensated to a certain extent. Good lateral compensation may be an important reason for the absence of symptoms in most patients with CICA0 and is also an important factor for good prognosis in patients with symptomatic CICA0.^{34,35} In our study, delayed cerebral blood flow perfusion was found in all 10 patients before occlusion, which was characterized by decreased CBF and increased MTT and T-Max. After successful recanalization, the perfusion delay on the occlusive side was significantly improved and was similar to that on the healthy side, which indicated that successful endovascular recanalization could effectively improve the hemodynamics on the occlusive side (Figures 4 and 5). Zanaty et al compared the CTP images of 5 patients with successful recanalization of CICA0 before and after operation. The results showed that hypoperfusion on the occlusive side was reversed. Our results are similar.

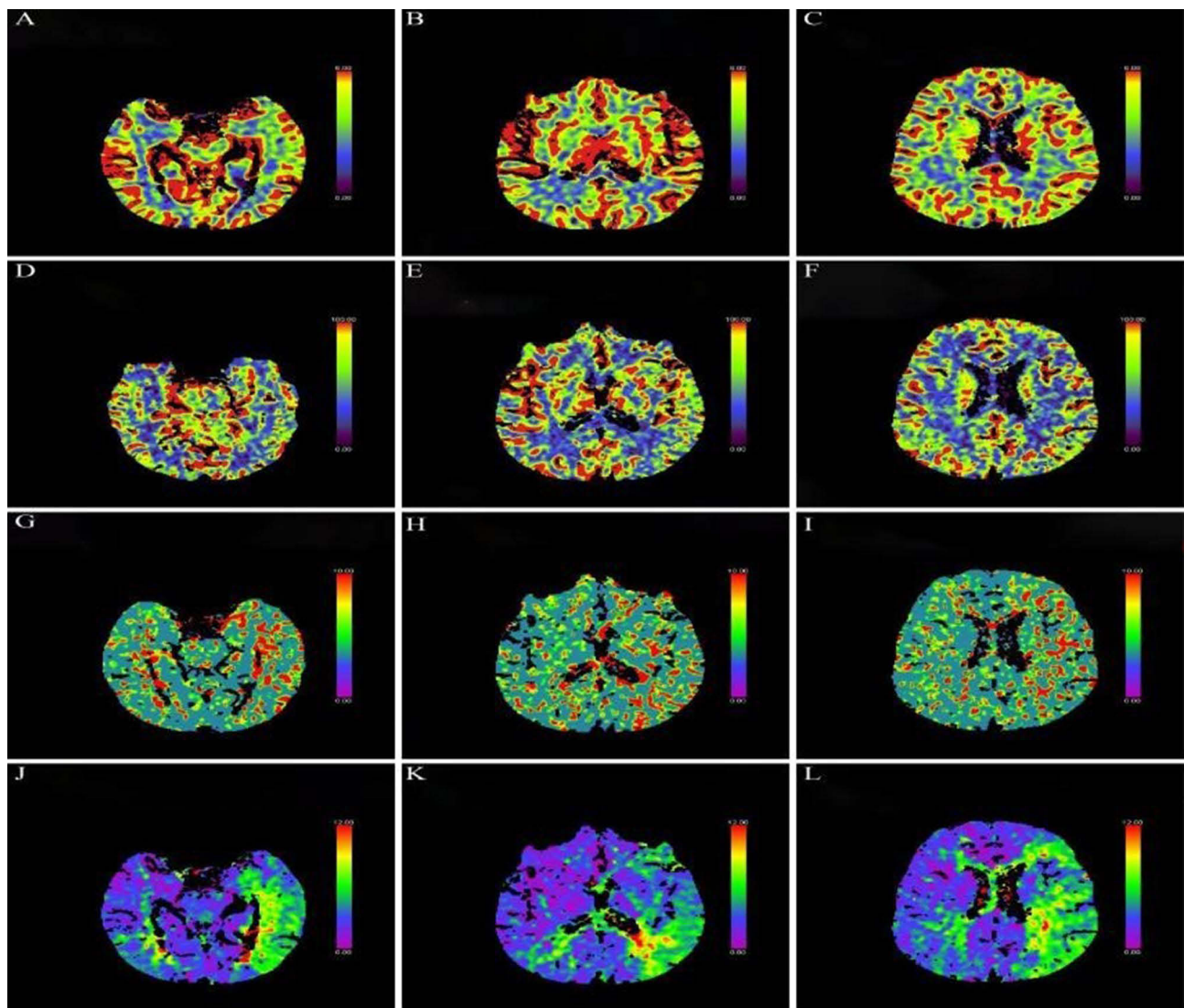


Figure 4 Representative case. Preoperative computed tomography perfusion (CTP) imaging of a 65-year-old male patient with repeated weakness of the right limb for more than 2 months. The cerebral blood volume (CBV) of bilateral cerebral hemispheres is equivalent (A–C), the cerebral blood flow (CBF) of bilateral cerebral hemispheres is equivalent (D–F), the mean transit time (MTT) of the left cerebral hemisphere is longer than that of the right (G–I), and the time to top (T-Max) of the left cerebral hemisphere is longer than that of the right (J–L).

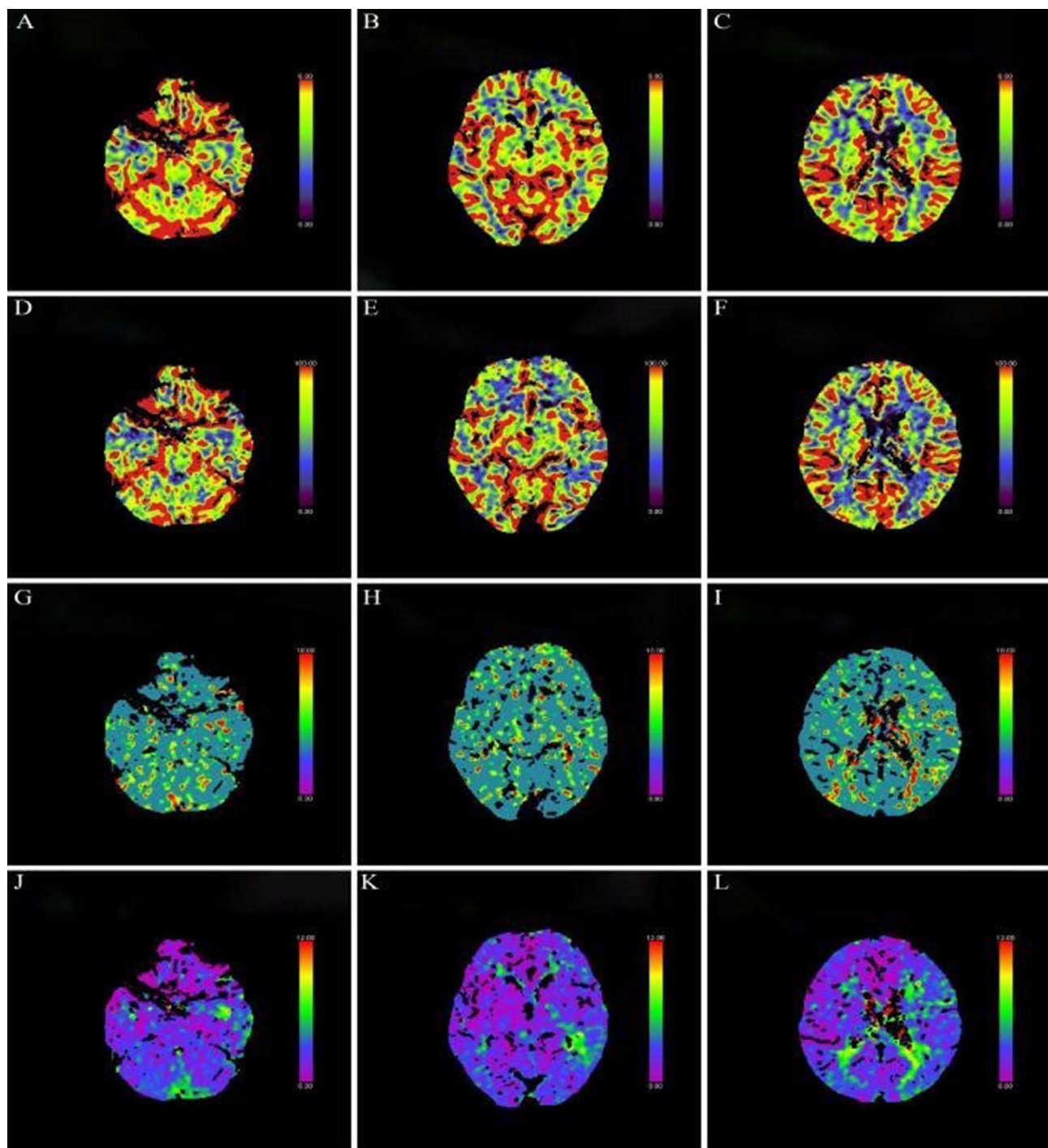


Figure 5 The same patient as Figure 4. Postoperative computed tomography perfusion (CTP) imaging showed that there was no significant difference in bilateral cerebral blood volume (CBV) (A–C), cerebral blood flow (CBF) (D–F), mean transit time (MTT) (G–I) and time to top (T-Max) (J–L).

The results of this study not only compare the perfusion images directly but also measure the specific numerical changes in detail. This is a rare result in previous studies, in which the perfusion of bilateral cerebellar hemispheres was also analyzed, and the results showed that endovascular recanalization did not affect the blood supply of the posterior circulation. This result was expected. After ICAO, the mode of compensation is not limited to compensatory blood supply through the posterior communicating artery, but also to other secondary compensatory modes, especially the anterior communicating artery and ophthalmic artery, as well as the leptomeninges artery, and the establishment of

collateral branches takes some time.^{36–38} Several parameters of CBF, CBV, MTT, and T-Max in CTP images can provide hemodynamic information of ischemic areas in different aspects, but due to different CT equipment and image post-processing methods, there may be great individual differences in perfusion parameters.^{39–41} This study showed that CTP could not only be used to evaluate the perfusion status of patients with CICA0 but also be a reliable imaging evaluation method for the follow-up study of these patients.

This study had several limitations. First, this was a single-center study with a limited sample size of patients, which may result in type II errors. More cases need to be included in the future. Second, our study is not completely random and double-blinded, the follow-up period is too short, the follow-up evaluation depends on the subjectivity of the examiners, and there may be deviations in the follow-up process, all of which may affect the results to a certain extent. Third, without the support of DSA or CT angiography data during the follow-up, we cannot know whether there is restenosis or occlusion of the occluded vessels. Fourth, our hospital has only conducted a small number of cases of endovascular recanalization treatment for CICA0, therefore there may be some lack of experience, but with the accumulation of experience and cases, the foundation has been laid for our in-depth follow-up study.

Conclusions

Although endovascular recanalization has some risks in the treatment of patients with CICA0, it is generally feasible. Successful recanalization can effectively improve the overall cognitive and neurological functions of patients in the short term, but the long-term effects remain to be further investigated. CTP can be used to quantitatively evaluate not only the cerebral hemodynamic changes after ICAO, but also the improvement of cerebral blood perfusion after successful endovascular recanalization, which provides a reliable method for postoperative follow-up.

Acknowledgments

Chao Xiao and Xiuen Chen share first authorship. We would like to thank Editage (www.editage.cn) for English language editing.

Funding

This study was funded by the National Natural Science Foundation of China (Grant No.81960220, No.82260240, No.82060226, No.81860222), Natural Science Foundation of Guangxi Province (Grant No.2019GXNSFAA185029, No.2019GXNSFDA185008), “Medical Excellence Award” Funded by the Creative Research Development Grant from the First Affiliated Hospital of Guangxi Medical University (Grant No.201907), and The Scientific Research Project of Guangxi Health and Family Planning Commission (Grant No. Z20170571).

Disclosure

The authors report no conflicts of interest in this work.

References

1. den Hartog AG, Achterberg S, Moll FL, et al. Asymptomatic carotid artery stenosis and the risk of ischemic stroke according to subtype in patients with clinical manifest arterial disease. *Stroke*. 2013;44(4):1002–1007. doi:10.1161/strokeaha.111.669267
2. Paraskevas KI, Nicolaides AN, Kakkos SK. Asymptomatic Carotid Stenosis and Risk of Stroke (ACSRS) study: what have we learned from it? *Ann Transl Med*. 2020;8(19):1271. doi:10.21037/atm.2020.02.156
3. Fan YL, Wan JQ, Zhou ZW, et al. Neurocognitive improvement after carotid artery stenting in patients with chronic internal carotid artery occlusion: a prospective, controlled, single-center study. *Vasc Endovascular Surg*. 2014;48(4):305–310. doi:10.1177/1538574414525863
4. Liu W. Chinese expert consensus on the treatment of chronic internal carotid artery occlusion recanalization. *Chin Electron J Intervent Radiol*. 2019;7(01):1–6.
5. Yang B, Kang K, Gao F, et al. Association of occlusion time with successful endovascular recanalization in patients with symptomatic chronic intracranial total occlusion. *J Neurosurg*. 2022;1–10. doi:10.3171/2021.12.JNS212337
6. Zanaty M, Howard S, Roa JA, et al. Cognitive and cerebral hemodynamic effects of endovascular recanalization of chronically occluded cervical internal carotid artery: single-center study and review of the literature. *J Neurosurg*. 2019;132(4):1158–1166. doi:10.3171/2019.1.JNS183337
7. Radu RA, Cagnazzo F, Derraz I, et al. Modern endovascular management of chronic total carotid artery occlusion: technical results and procedural challenges. *J Neurointerv Surg*. 2022;neurintsurg-2022-019219. doi:10.1136/jnis-2022-019219
8. Grubb RL, Derdeyn CP, Fritsch SM, et al. Importance of hemodynamic factors in the prognosis of symptomatic carotid occlusion. *JAMA*. 1998;280(12):1055–1060. doi:10.1001/jama.280.12.1055
9. Flaherty ML, Flemming KD, McClelland R, Jorgensen NW, Brown RD. Population-based study of symptomatic internal carotid artery occlusion: incidence and long-term follow-up. *Stroke*. 2004;35(8):e349–52. doi:10.1161/01.STR.0000135024.54608.3f

10. Persoon S, Luitse MJ, de Borst GJ, et al. Symptomatic internal carotid artery occlusion: a long-term follow-up study. *J Neurol Neurosurg Psychiatry*. 2011;82(5):521–526. doi:10.1136/jnnp.2010.208330
11. Oudemans EA, Kappelle LJ, Van den Berg-Vos RM, Weinstein HC, van den Berg E, Klijn CJM. Cognitive functioning in patients with carotid artery occlusion; a systematic review. *J Neurol Sci*. 2018;394:132–137. doi:10.1016/j.jns.2018.09.006
12. Lanari A, Silvestrelli G. Acute and chronic carotid occlusion syndromes. *Front Neurol Neurosci*. 2012;30:185–190. doi:10.1159/000333639
13. Sundaram S, Kanno S, Thomas B, Sarma PS, Sylaja PN. Collateral assessment by CT angiography as a predictor of outcome in symptomatic cervical internal carotid artery occlusion. *Am J Neuroradiol*. 2017;38(1):52–57. doi:10.3174/ajnr.A4957
14. Song LP, Zhang WW, Gu YQ, Ji XM, Zhang J. Cognitive improvement after carotid artery stenting in patients with symptomatic internal carotid artery near-occlusion. *J Neurol Sci*. 2019;404:86–90. doi:10.1016/j.jns.2019.07.023
15. Janko M, Moore R, Kim AH, et al. Carotid occlusion is associated with more frequent neurovascular events than moderately severe carotid stenosis. *J Vasc Surg*. 2017;66(5):1445–1449. doi:10.1016/j.jvs.2017.04.041
16. Eastwood JD, Alexander MJ, Petrella JR, Provenzale JM. Dynamic CT perfusion imaging with Acetazolamide challenge for the preprocedural evaluation of a patient with symptomatic middle cerebral artery occlusive disease. *Am J Neuroradiol*. 2002;23(2):285–287.
17. Nogueira RG, Jadhav AP, Haussen DC, et al. Thrombectomy 6 to 24 hours after stroke with a mismatch between deficit and infarct. *N Engl J Med*. 2018;378(1):11–21. doi:10.1056/NEJMoa1706442
18. Albers GW, Marks MP, Kemp S, et al. Thrombectomy for stroke at 6 to 16 hours with selection by perfusion imaging. *N Engl J Med*. 2018;378(8):708–718. doi:10.1056/NEJMoa1713973
19. Dong H, Jiang X, Zou Y, et al. External carotid artery stenting in patients with ipsilateral internal carotid artery occlusion: peri-operative and 12-month follow-up. *Catheter Cardiovasc Interv*. 2021;97(Suppl 2):982–987. doi:10.1002/ccd.29563
20. Powers WJ, Clarke WR, Grubb RL, Videen TO, Adams HP, Derdeyn CP. Extracranial-intracranial bypass surgery for stroke prevention in hemodynamic cerebral ischemia: the Carotid Occlusion Surgery Study randomized trial. *JAMA*. 2011;306(18):1983–1992. doi:10.1001/jama.2011.1610
21. Gil-Berrozpe GJ, Sánchez-Torres AM, García de Jalón E, et al. Utility of the MoCA for cognitive impairment screening in long-term psychosis patients. *Schizophr Res*. 2020;216:429–434. doi:10.1016/j.schres.2019.10.054
22. Folstein MF, Folstein SE, McHugh PR. “Mini-mental state”. A practical method for grading the cognitive state of patients for the clinician. *J Psychiatr Res*. 1975;12(3):189–198. doi:10.1016/0022-3956(75)90026-6
23. Shiraz Bhurwani MM, Snyder KV, Waqas M, et al. Use of quantitative angiographic methods with a data-driven model to evaluate reperfusion status (mTICI) during thrombectomy. *Neuroradiology*. 2021;63(9):1429–1439. doi:10.1007/s00234-020-02598-3
24. Lichtman JH, Jones MR, Leifheit EC, et al. Carotid endarterectomy and carotid artery stenting in the US medicare population, 1999–2014. *JAMA*. 2017;318(11):1035–1046. doi:10.1001/jama.2017.12882
25. Klijn CJ, Kappelle LJ. Haemodynamic stroke: clinical features, prognosis, and management. *Lancet Neurol*. 2010;9(10):1008–1017. doi:10.1016/S1474-4422(10)70185-x
26. Powers WJ. Management of patients with atherosclerotic carotid occlusion. *Curr Treat Options Neurol*. 2011;13(6):608–615. doi:10.1007/s11940-011-0145-6
27. Yue X, Xu G, Liu W, et al. Angioplasty and stenting for the occluded internal carotid artery. *J Thromb Thrombolysis*. 2011;31(1):64–70. doi:10.1007/s11239-010-0472-6
28. Hasan D, Zanaty M, Starke RM, et al. Feasibility, safety, and changes in systolic blood pressure associated with endovascular revascularization of symptomatic and chronically occluded cervical internal carotid artery using a newly suggested radiographic classification of chronically occluded cervical internal carotid artery: pilot study. *J Neurosurg*. 2018;1–10. doi:10.3171/2018.1.Jns.172858
29. Lin MS, Lin LC, Li HY, et al. Procedural safety and potential vascular complication of endovascular recanalization for chronic cervical internal carotid artery occlusion. *Circ Cardiovasc Interv*. 2008;1(2):119–125. doi:10.1161/circinterventions.108.772350
30. Zhai G, Huang Z, Du H, Xu Y, Xiao G, Cao Y. Endovascular revascularization of symptomatic chronic total occlusions of the internal carotid artery using a proximal balloon protection device. *Sci Prog*. 2021;104(1):36850421998870. doi:10.1177/0036850421998870
31. Tsang AC, Lau KK, Tsang FC, Tse MM, Lee R, Lui WM. Severity of intracranial carotid artery calcification in intracranial atherosclerosis-related occlusion treated with endovascular thrombectomy. *Clin Neurol Neurosurg*. 2018;174:214–216.
32. Myrcha P, Głowiczki P. A systematic review of endovascular treatment for chronic total occlusion of the internal carotid artery. *Ann Transl Med*. 2021;9(14):1203. doi:10.21037/atm-20-6980
33. Marshall RS, Festa JR, Cheung YK, et al. Randomized Evaluation of Carotid Occlusion and Neurocognition (RECON) trial: main results. *Neurology*. 2014;82(9):744–751. doi:10.1212/wnl.0000000000000167
34. Rutgers DR, Klijn CJ, Kappelle LJ, van der Grond J. Recurrent stroke in patients with symptomatic carotid artery occlusion is associated with high-volume flow to the brain and increased collateral circulation. *Stroke*. 2004;35(6):1345–1349. doi:10.1161/01.Str.0000128697.52150.75
35. Zhang P, Wang Z, Yu FX, et al. The clinical presentation and collateral pathway development of congenital absence of the internal carotid artery. *J Vasc Surg*. 2018;68(4):1054–1061. doi:10.1016/j.jvs.2018.01.043
36. van Everdingen KJ, Visser GH, Klijn CJ, Kappelle LJ, van der Grond J. Role of collateral flow on cerebral hemodynamics in patients with unilateral internal carotid artery occlusion. *Ann Neurol*. 1998;44(2):167–176. doi:10.1002/ana.410440206
37. Cheng XQ, Tian JM, Zuo CJ, Liu J, Zhang Q, Lu GM. Quantitative perfusion computed tomography measurements of cerebral hemodynamics: correlation with digital subtraction angiography identified primary and secondary cerebral collaterals in internal carotid artery occlusive disease. *Eur J Radiol*. 2012;81(6):1224–1230. doi:10.1016/j.ejrad.2011.02.046
38. Connolly F, Röhl JE, Lopez-Prieto J, Danyel LA, Schreiber SJ, Valdeza JM. Pattern of activated pathways and quality of collateral status in patients with symptomatic internal carotid artery occlusion. *Cerebrovasc Dis*. 2019;48(3–6):244–250. doi:10.1159/000504663
39. Campbell BC, Mitchell PJ, Kleinig TJ, et al. Endovascular therapy for ischemic stroke with perfusion-imaging selection. *N Engl J Med*. 2015;372(11):1009–1018. doi:10.1056/NEJMoa1414792
40. Vagal A, Wintermark M, Nael K, et al. Automated CT perfusion imaging for acute ischemic stroke: pearls and pitfalls for real-world use. *Neurology*. 2019;93(20):888–898. doi:10.1212/wnl.00000000000008481
41. Adebayo OD, Culpan G. Diagnostic accuracy of computed tomography perfusion in the prediction of haemorrhagic transformation and patient outcome in acute ischaemic stroke: a systematic review and meta-analysis. *Eur Stroke J*. 2020;5(1):4–16. doi:10.1177/2396987319883461

Neuropsychiatric Disease and Treatment

Dovepress

Publish your work in this journal

Neuropsychiatric Disease and Treatment is an international, peer-reviewed journal of clinical therapeutics and pharmacology focusing on concise rapid reporting of clinical or pre-clinical studies on a range of neuropsychiatric and neurological disorders. This journal is indexed on PubMed Central, the 'PsycINFO' database and CAS, and is the official journal of The International Neuropsychiatric Association (INA). The manuscript management system is completely online and includes a very quick and fair peer-review system, which is all easy to use. Visit <http://www.dovepress.com/testimonials.php> to read real quotes from published authors.

Submit your manuscript here: <https://www.dovepress.com/neuropsychiatric-disease-and-treatment-journal>