

Feasibility and Safety of the Clinical Outcomes of TACE Combined with Lenvatinib and PD-1 Blockades in the Treatment of Hepatocellular Carcinoma with Portal Vein Tumor Thrombus: A Retrospective Exploratory Study

Wei Sun^{1,*}, Yun Liu^{2,*}, Li Wang³

¹Department of Oncology, Beijing Ditan Hospital, Capital Medical University, Beijing, 100015, People's Republic of China; ²Department of Medical Oncology, National Cancer Center/National Clinical Research Center for Cancer/Cancer Hospital, Chinese Academy of Medical Sciences and Peking Union Medical College, Beijing, 100021, People's Republic of China; ³Department of Oncology, Beijing Luhe Hospital, Capital Medical University, Beijing, 101149, People's Republic of China

*These authors contributed equally to this work

Correspondence: Li Wang, Department of Oncology, Beijing Luhe Hospital, Capital Medical University, No. 82, Xinhua South Road, Tongzhou District, Beijing, 101149, People's Republic of China, Tel +86 18010279916, Email lhyw@163.com

Objective: This study aimed to investigate the feasibility of the efficacy and safety of TACE combined with Lenvatinib and PD-1 blockade in HCC with portal vein tumor thrombus (PVTT).

Methods: Patients with HCC and PVTT who underwent TACE combined with Lenvatinib and PD-1 blockade as first-line therapy in clinical practice were retrospectively included. All subjects were followed-up regularly to obtain prognostic outcomes. The safety profile observed during the combination therapy was collected and documented. The Log rank test was used for exploratory analysis of prognosis and baseline characteristics and Cox regression analysis was used for multivariate analysis.

Results: A total of 67 HCC patients with PVTT who received TACE combined with Lenvatinib and PD-1 blockade were included in this study. The best therapeutic response during treatment suggested that 4 patients achieved complete response, 30 patients showed partial response, 25 patients were stable disease, 5 patients had disease progression and 3 patients were not available. Objective response rate of this regimen was 50.7% [95% confidence interval (CI): 38.2–63.2%] and disease control rate was 88.1% (95% CI: 77.8–94.7%). The median progression-free survival of 67 HCC patients with PVTT who received TACE combined with Lenvatinib and PD-1 blockades was 9.3 months (95% CI: 5.85–12.75), and the median overall survival was 24.4 months (95% CI: 19.11–29.69). The safety profile highlighted that 65 patients experienced adverse reactions regardless of grade during treatment (97.0%), among whom 34 patients were deemed as grade ≥ 3 adverse reactions (50.7%). The most common adverse reactions were hypertension, fatigue, abnormal liver function, nausea, vomiting, and diarrhea. Overall adverse reactions were acceptable and controllable.

Conclusion: TACE combined with Lenvatinib and PD-1 blockades as first-line therapy for HCC with PVTT demonstrated potential feasibility and encouraging clinical outcomes, providing long-term survival benefits for HCC patients. This conclusion should be confirmed in prospective large-scale clinical trials.

Keywords: hepatocellular carcinoma, portal vein tumor thrombus, TACE, Lenvatinib, PD-1 blockades, efficacy, safety

Introduction

Liver cancer is one of the most common malignant tumors of the digestive system, with a high incidence and the second highest mortality rate worldwide. Globally, there are approximately 900,000 new cases and 830,000 deaths each year.¹ China has a particularly high incidence of liver cancer, with approximately 410,000 new cases and 390,000 deaths

annually, accounting for approximately 46% of the global case.² The majority of liver cancer are hepatocellular carcinoma (HCC), representing about 90% of liver cancer cases, equating to roughly 370,000 new cases of HCC in China each year.³ Over 80% of liver cancer cases in China are related to hepatitis B virus (HBV) infection, which contributes to differences in treatment strategies between China and Western countries.⁴ Most HCC patients are diagnosed at an advanced stage with inoperable disease due to the lack of prominent symptoms, resulting in a poor prognosis. The overall 5-year survival rate for HCC is less than 15% currently.⁵ A significant reason for the poor prognosis of HCC patients is the presence of portal vein tumor thrombus (PVTT) at the time of diagnosis.⁶ Research indicates that approximately 44–62.2% of patients with advanced HCC are accompanied by PVTT.⁷ According to the NCCN and ESMO guidelines, HCC with PVTT is classified as stage C in the Barcelona Clinic Liver Cancer (BCLC) staging system.⁸ Consequently, the prognosis for HCC patients with PVTT is dismal, and the median survival time for these patients is only 2.7 to 4 months without treatment.⁹ Currently, the first-line standard of care treatment for these patients is sorafenib and Lenvatinib.¹⁰ Unfortunately, the prognosis remains poor, necessitating the exploration of more efficacious therapeutic options.¹¹

In recent years, significant progress has been made in systemic therapy for unresectable advanced HCC.¹² Results from the REFLECT trial indicated that Lenvatinib achieved non-inferior efficacy compared to sorafenib, becoming the standard first-line treatment for advanced HCC [median overall survival (OS): 13.6 months compared to 12.3 months, HR=0.92 [95% confidence interval (CI): 0.79–1.06].¹³ Additionally, the IMbrave150 trial established the combination of anti-angiogenesis drugs and immunotherapy, specifically atezolizumab and bevacizumab, as a standard first-line treatment for advanced HCC.¹⁴ Although the LEAP-002 trial failed to achieve its primary endpoint, the combination of Lenvatinib and programmed death 1 (PD-1) blockades still exhibited potential survival benefits for patients with advanced HCC.^{15,16} Consequently, the combination of Lenvatinib and PD-1 blockades has been widely adopted in clinical practice, providing potential survival benefits to patients with HCC.¹⁷

Transarterial chemoembolization (TACE) is a widely used classical local treatment method for patients with intermediate and late-stage HCC, both domestically and internationally.¹⁸ According to the Chinese liver cancer staging system, patients in stages Ib, IIa, IIb, IIIa, and IIIb were all indicated for TACE treatment.¹⁹ For patients with unresectable HCC, the TACTICS trial suggested that TACE combined with systemic treatment might provide preliminary survival benefits.²⁰ Furthermore, TACE facilitated local tumor necrosis and subsequent angiogenesis post-embolization, serving as a synergistic foundation when used with anti-angiogenic medications.²¹ Additionally, the necrotic tumor tissues resulting from TACE might release tumor antigens, enhancing anti-tumor immunity, which underpins the synergistic benefits observed with the concurrent use between TACE and PD-1 blockades.²² Consequently, evidence highlighted that a therapeutic regimen combining TACE, Lenvatinib and PD-1 blockades might provide significant survival benefits for patients with unresectable HCC.^{23,24}

However, research on the potential therapeutic benefits of combining TACE with Lenvatinib and PD-1 blockades in patients with HCC and PVTT remains limited. Therefore, this study aimed to retrospectively assess the feasibility and safety of this combined therapeutic approach in patients with HCC and PVTT.

Materials and Methods

Study Design and Eligibility Criteria

This retrospective study included eligible patients with HCC who were treated at Beijing Ditan Hospital with TACE combined with Lenvatinib and PD-1 blockade for unresectable HCC with PVTT consecutively between December 2018 and November 2023. The inclusion criteria were: (1) pathologically confirmed unresectable HCC or radiologically diagnosed HCC according to the criteria of the American Association for the Study of Liver Diseases; (2) HCC accompanied by PVTT confirmed based on the criteria of the Japan Society of Hepatology;²⁵ (3) age ≥ 18 years; (4) Eastern Cooperative Oncology Group (ECOG) performance status score of 0–2 score; (5) Child-Pugh score of ≤ 7 of the liver function; (6) patients treated with at least one cycle of TACE combined with Lenvatinib and PD-1 blockade in clinical practice; (7) at least one measurable lesion according to the mRECIST criteria. The exclusion criteria were: (1)

presence of another malignancy or concurrent life-threatening severe disease; (2) previous systemic antitumor treatments (local treatments were allowed); (3) insufficient baseline characteristics or clinical treatment data.

A flowchart of this study is shown in [Figure 1](#), which shows that 67 patients with HCC with PVTT met the eligibility criteria and were included in this retrospective analysis. The primary endpoints of this study were progression-free survival (PFS), while the secondary endpoints were overall survival (OS), objective response rate (ORR), disease control rate (DCR), duration of response (DOR) and safety. This study was conducted in accordance with the principles of the Declaration of Helsinki, and the study protocol was approved by the ethics committee of Beijing Ditan Hospital. Given that this was a real-world retrospective study, the requirement for informed consent was waived by the Ethics Committee.

Therapeutic Regimens and Protocol of Efficacy Assessment

The 67 HCC patients with PVTT included in this study were treated with a combination of TACE, Lenvatinib and PD-1 blockades in clinical practice. The initial dosage of lenvatinib was determined based on the patient's body weight: 8 mg daily for those under 60 kg and 12 mg daily for those over 60 kg, administered orally until disease progression or intolerable adverse reactions were observed. The PD-1 blockers used in this study were Tislelizumab, Sintilimab, Camrelizumab and Pembrolizumab, each administered at a standard initial dosage of 200 mg via intravenous infusion over more than half an hour on the first day of a 21-day treatment cycle, until disease progression or intolerable adverse reactions occurred. The duration of PD-1 blockades treatment was no longer than two years.

TACE treatment followed routine clinical practice and mainly involved lipiodol-based therapy. Briefly, using the Seldinger technique, a catheter was selectively introduced into the hepatic artery via the femoral artery and chemotherapeutic embolic agents were implanted through the catheter. The chemotherapeutic emulsion was prepared by mixing the chemotherapy drugs [oxaliplatin (50 mg), doxorubicin (10 mg), and Mitomycin C (10 mg)] with 6–10 mL of lipiodol and an appropriate amount of contrast agent. Details of the specific TACE procedure are described in a previous study by our department.²⁶ TACE was administered on demand and repeat TACE treatments were performed when imaging showed persistent lesions or insufficient lipiodol absorption at intervals of 8–12 weeks. Notably, Lenvatinib and PD-1 blockade were discontinued before TACE and

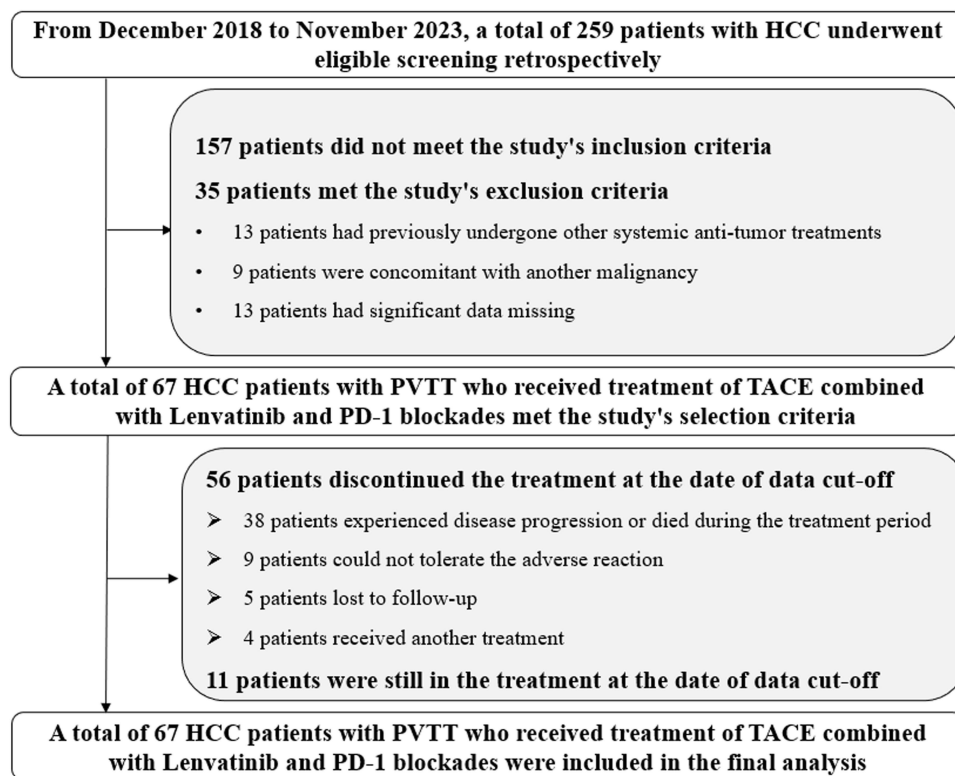


Figure 1 Flowchart of the retrospective study of 67 HCC patients with PVTT who received TACE combined with Lenvatinib and PD-1 blockades.

resumed 3–5 days after TACE. Treatment with medication or TACE was terminated if the patient experienced intolerable adverse reactions.

The efficacy of treatment for patients was assessed using the mRECIST criteria, which are commonly used clinically in HCC.²⁷ Efficacy assessment of the target lesions was performed every two cycles (42 days) using CT or MRI radiologically. Due to the retrospective design of this study, efficacy evaluations for some patients were also acceptable based on actual conditions, such as approximately two months during follow-up. Each patient's imaging was reviewed by a multidisciplinary team to ensure consistent assessment of tumor response according to the mRECIST criteria. ORR and DCR were assessed based on the best response status observed in each patient during the treatment process with TACE combined with Lenvatinib and PD-1 blockade therapy. Additionally, adverse reactions experienced by the patients during combination treatment were evaluated using the Common Terminology Criteria for Adverse Events (CTCAE) version 5.0, documenting the highest level of adverse reactions encountered by each patient during treatment.

Protocol of Follow-Up

Given the retrospective design of this study, baseline demographic and clinical characteristics of each patient were collected through an electronic medical record system during hospitalization. Disease progression was assessed by imaging examinations performed during the treatment process. Adverse reactions to the combination therapy of TACE plus Lenvatinib and PD-1 blockades were evaluated based on patients' responses to medications throughout their treatment. Follow-up at the subsequent stages of this study was primarily conducted via telephone. After patients experienced therapeutic failure with the combination of TACE plus Lenvatinib and PD-1 blockades therapy, monthly follow-up was performed to monitor their subsequent treatment and date of death. The data cut-off date for this study was March 15, 2024.

Statistical Analysis

ORR was defined as the proportion of patients who achieved complete response (CR) and partial response (PR) among those enrolled in the study. DCR was defined as the proportion of patients who achieved CR, PR, or (SD) among the study participants. DOR was the time from the first documentation of a CR or PR to the time of disease progression or death from any cause.²⁸ Statistical analysis required in this study was performed using SPSS (version 25.0). The quantitative and qualitative data were presented as median values (range) and numbers (percentages). Survival data for PFS and OS were obtained according to a previous study.²⁹ Survival curves for PFS, DOR and OS were plotted using Stata (version 14.0). The association between the baseline clinical characteristic subgroups and PFS was analyzed using the Log rank test. Variables showing statistically significant differences in the univariate analysis were included in the multivariate Cox regression analysis to adjust for confounding factors. $P < 0.05$ was considered statistically significant.

Results

Baseline Characteristics

Baseline characteristics of the 67 HCC patients with PVTT included in this study were presented in [Table 1](#). These HCC patients included in our study were of clinically representative, including nine patients who received previous local therapy and 14 patients with extrahepatic metastasis. Among the 10 patients with Child-Pugh score of 7 that were classified as Child-Pugh B, 7 patients were only biochemical abnormalities (total bilirubin, albumin and prothrombin time abnormalities), 3 patients were concomitant with liver decompensation (ascites or hepatic encephalopathy positive).

Among the 57 patients (85.0%) with HBV positive, 53 (92.9%) were receiving nucleotide analogs as antiviral treatment and all the 53 patients achieved virologic suppression (100%) before starting systemic treatment. The antiviral treatments included entecavir and tenofovir, which are recommended first-line therapies for chronic HBV infection. A total of 18 patients were classified as Vp1 and Vp2 involvement, while the remaining 49 patients had Vp3 and Vp4 involvement. The median number of TACE treatments was two (range: 1–5 times). Nineteen patients received 8 mg lenvatinib and 48 patients received 12 mg lenvatinib. Notably, this study involved four types of combined PD-1 blockade: tislelizumab (28 patients), sintilimab (21 patients), camrelizumab (11 patients), and pembrolizumab (7 patients). Due to the retrospective design, esophageal varices of some patients were not available. Among the 67

Table 1 Baseline Characteristics of the 67 HCC Patients with PVTT

Baseline Characteristics	Total (N=67)	Percentage
Age (year)		
Median (range)	58 (49–80)	
≥58	35	52.2%
<58	32	47.8%
ECOG performance status score		
0–1	49	73.1%
2	18	26.9%
Gender		
Male	51	76.1%
Female	16	23.9%
BCLC staging		
C	67	100.0%
Child–Pugh liver function classification		
A	57	85.1%
B	10	14.9%
HCC etiology		
HBV	57	85.0%
HCV	5	7.5%
Other	5	7.5%
Previous local therapy status		
Yes	9	13.4%
No	58	86.6%
Extrahepatic metastasis status		
Yes	14	20.9%
No	53	79.1%
Alpha fetoprotein (ng/mL)		
<400	24	64.9%
≥400	13	35.1%
Number of tumor lesions		
≤3	51	76.1%
>3	16	23.9%
PVTT type		
Vp1–Vp2	18	26.9%
Vp3–Vp4	49	73.1%
Number of TACE treatment (times)		
Median (range)	2 (1–5)	
Dosage of Lenvatinib (mg)		
8	19	28.4%
12	48	71.6%
PD-1 blockades		
Tislelizumab	28	41.8%
Sintilimab	21	31.4%
Camrelizumab	11	16.4%
Pembrolizumab	7	10.4%

patients, 18 patients (26.9%) had esophageal varices, which were identified by endoscopic examination or radiological assessment prior to the initiation of treatment. Of the 18 patients with esophageal varices, 11 patients (61.1%) received prophylactic treatment to prevent potential variceal bleeding, which included non-selective beta-blockers (propranolol) to reduce portal pressure and endoscopic variceal ligation for patients with high-risk varices.

Additionally, as shown in [Figure 1](#), based on the data cut-off date, 11 patients were still undergoing treatment with TACE combined with Lenvatinib and PD-1 blockade. The other 56 patients terminated the treatment: 38 patients

experienced disease progression, nine patients were intolerant to adverse reactions, five patients lost to follow-up and four patients received other treatments.

Efficacy of TACE Combined with Lenvatinib and PD-I Blockades

Results of each radiological evaluation of the 67 HCC patients were collected and recorded to assess the efficacy of the therapeutic regimen involving TACE combined with Lenvatinib and PD-1 blockades. The best response observed during treatment was used to calculate the ORR and DCR. Among the 67 patients, four achieved CR, 30 achieved PR, 25 were SD, five experienced disease progression, and three were not available of the response. Therefore, the ORR for the 67 HCC patients with PVTT undergoing the combined treatment of TACE plus Lenvatinib and PD-1 blockade was 50.7% (95% Confidence Interval [CI]: 38.2–63.2%), and the DCR was 88.1% (95% CI: 77.8–94.7%). Additionally, ORR of patients with Vp1-Vp2 was higher than that of Vp3-Vp4 (ORR: 61.1% vs 46.9%), though the differences were not statistically significant ($P=0.304$). A waterfall plot of the best percentage change in target lesions among patients with HCC and PVTT is shown in Figure 2. A significant reduction in tumor size was observed in most patients following TACE plus Lenvatinib and PD-1 blockades therapy. Additionally, a 61-year-old male patient achieved CR after two months of treatment with TACE combined with Lenvatinib and Sintilimab. The CT scans before and after combination treatment were shown in Figure 3. The patient benefited from the combination treatment.

All patients with HCC included in this study had concomitant tumor thrombi. Regarding the tumor thrombus response, after treatment with TACE combined with Lenvatinib and PD-1 blockades, 6 patients achieved CR and more than 30 patients showed a reduction in tumor thrombus, highlighting the encouraging effectiveness of this combination regimen in managing tumor-related vascular obstructions.

Prognosis of TACE Combined with Lenvatinib and PD-I Blockades

As described in methods section, the data cut-off date of this study was March 15, 2024, resulting in a median follow-up duration of 18.5 months (follow-up range: 0.3–43.5 months) among all patients included in this study. In the analysis of PFS by the data cut-off date, 47 patients experienced disease progression or death events, yielding a PFS data maturity of 70.1%. As shown in Figure 4, the median PFS for the 67 HCC patients with PVTT treated with the combination of TACE

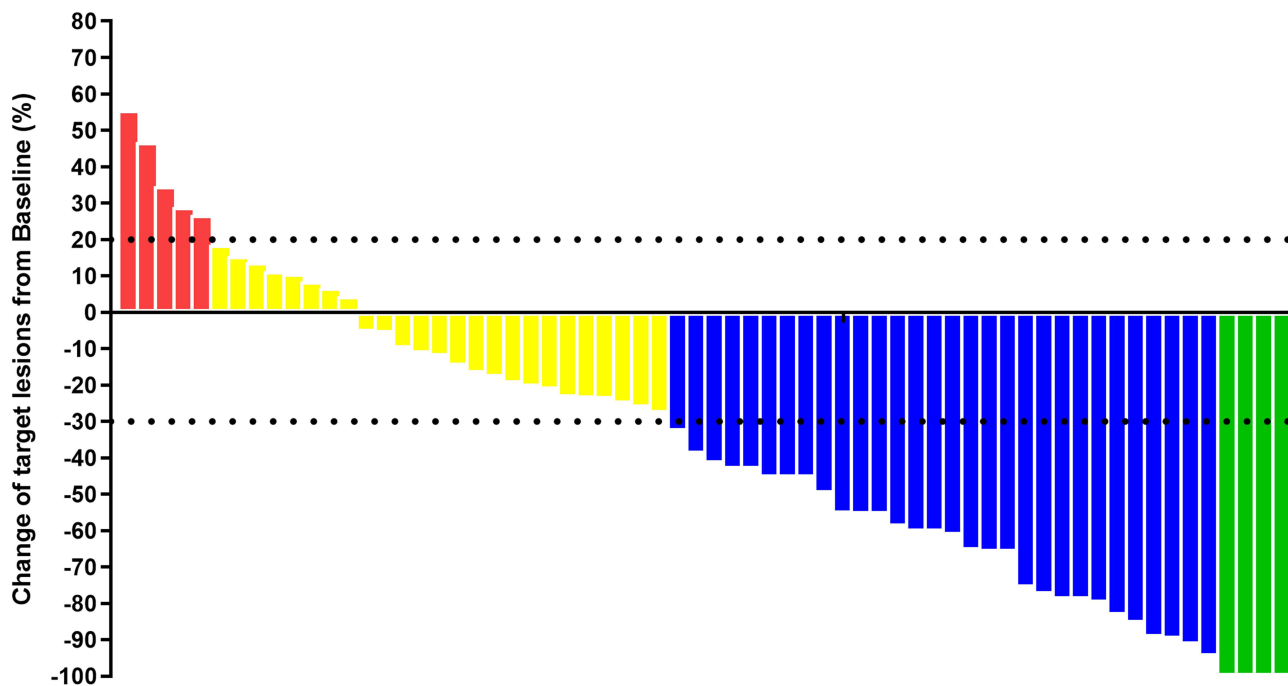


Figure 2 Waterfall plots of the best changes in target lesions of the 67 HCC patients with PVTT who received TACE combined with Lenvatinib and PD-I blockades (Green represent CR, blue represent PR, yellow represent SD and red represents PD during the best overall response).

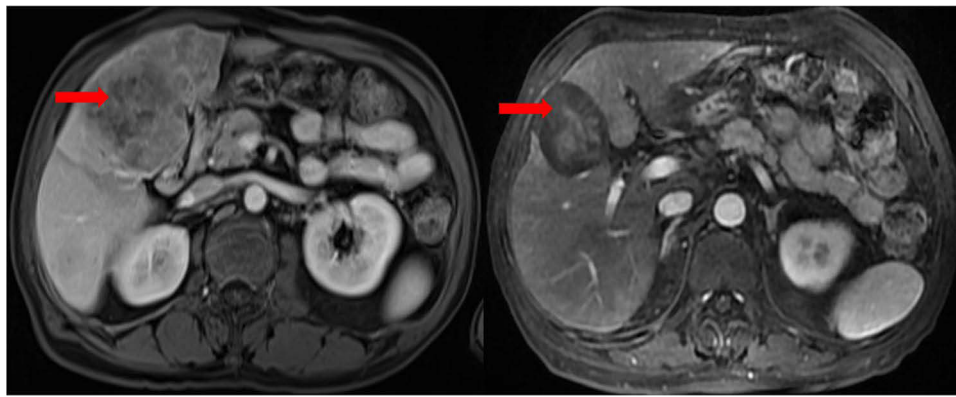


Figure 3 CT scan results of the changes for target lesions in the liver site of the CR patient with HCC before and after the administration of TACE combined with Lenvatinib and Sintilimab (Red arrows represent the location of target lesions).

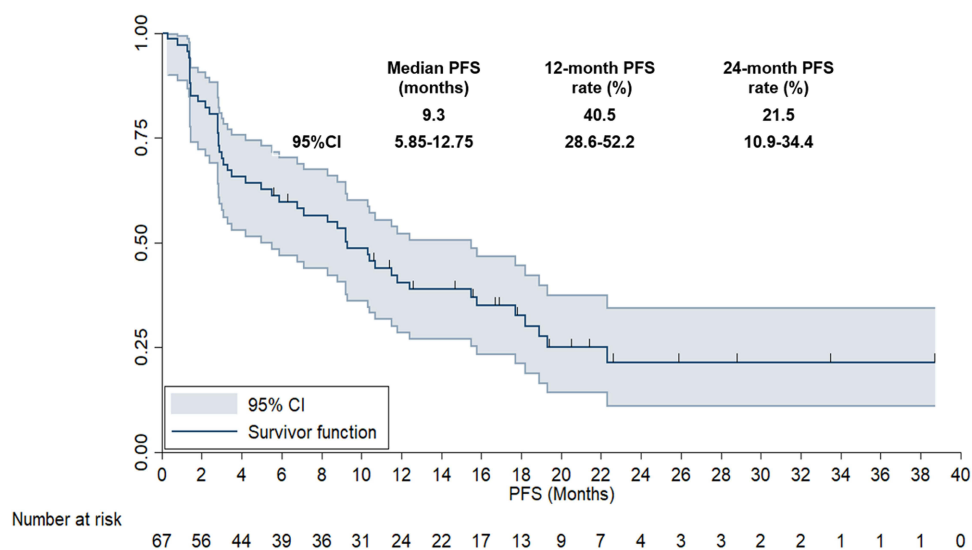


Figure 4 Progression free survival of the 67 patients with HCC who received the administration of TACE combined with Lenvatinib and PD-1 blockades.

plus Lenvatinib and PD-1 blockades was 9.3 months (95% CI: 5.85–12.75), and the 12-month and 24-month PFS rates were 40.5% and 21.5%, respectively.

The median duration of TACE combined with Lenvatinib and PD-1 blockades treatment of the 9 patients who could not tolerate the adverse reaction was 1.35 months (range: 0.3–2.85 months). And the median duration of TACE combined with Lenvatinib and PD-1 blockades treatment of the 38 patients who experienced disease progression or died during the treatment was 7.1 months (range: 2.85–19.3 months). The median duration of TACE combined with Lenvatinib and PD-1 blockades treatment of the 11 patients who were still in the treatment at the date of data cut-off was 20.4 months (range: 12.5–38.6 months).

Following a relatively extended follow-up period, the OS data also reached a substantial level of maturity. Based on the data cut-off date, 42 patients died, leading to an OS data maturity of 62.7%. As illustrated in Figure 5, the median OS of the 67 HCC patients with PVTT treated with TACE plus Lenvatinib and PD-1 blockades was 24.4 months (95% CI: 19.11–29.69). The 24-month and 36-month OS rates were 50.6% and 24.4%, respectively.

Furthermore, DOR of the 34 HCC patients with PVTT who achieved CR or PR was also assessed, as illustrated in Figure 6. The median DOR of these 34 HCC patients with PVTT was 11.2 months (95% CI: 6.34–16.06). The 12-month and 36-month DOR rates were 50.0% and 25.1%, respectively.

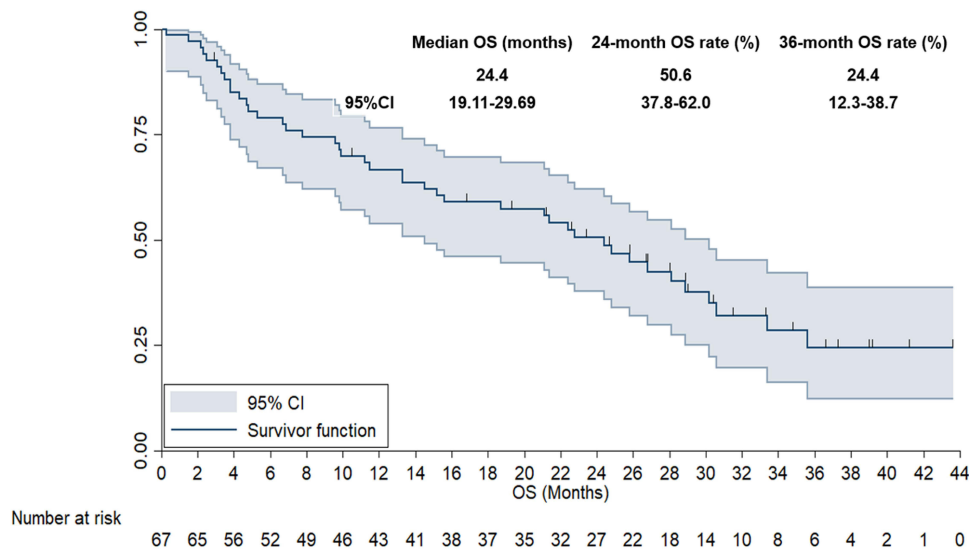


Figure 5 Overall survival of the 67 patients with HCC who received the administration of TACE combined with Lenvatinib and PD-1 blockades.

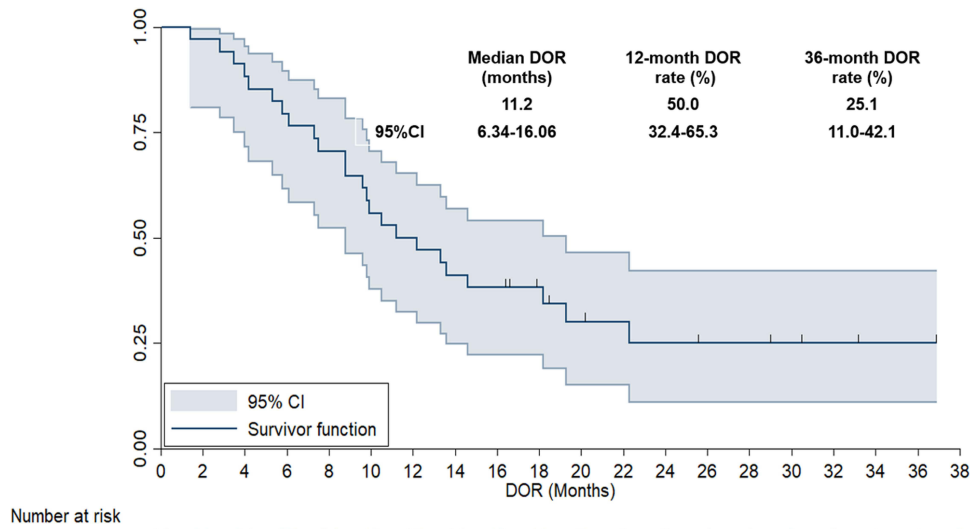


Figure 6 Duration of response of the 34 patients with HCC who received the administration of TACE combined with Lenvatinib and PD-1 blockades.

Association Between Baseline Clinical Characteristic Subgroups and PFS

Subsequently, association analysis was performed between baseline clinical characteristic subgroups and PFS, as presented in Table 2. Univariate analysis was used to identify the difference between the PFS and baseline clinical characteristic subgroups with the median PFS and 95% CI to describe the differences. Univariate analysis indicated that ECOG performance status, extrahepatic metastasis status, and number of tumor lesions were significantly associated with PFS. Patients with an ECOG performance status score of 0–1 had longer PFS (median PFS: 11.5 vs 7.1 months, $P=0.011$), patients with extrahepatic metastasis conferred poorer PFS (median PFS: 6.8 vs 11.5 months, $P=0.009$), and patients with more than three tumor lesions had shorter PFS (median PFS: 7.1 vs 11.8 months, $P=0.012$). Therefore, these three variables were included in the multivariate Cox analysis, which confirmed that ECOG performance status (HR=0.63, $P=0.022$), extrahepatic metastasis status (HR=0.59, $P=0.011$) and number of tumor lesions (HR=0.61, $P=0.018$) remained independent risk factors for PFS.

Table 2 Univariate and Multivariate Analysis of Baseline Characteristic Subgroups and PFS in 67 HCC Patients with PVTT

Baseline Characteristics	Median PFS (95% CI)	P (Univariate Analysis)	Multivariate Analysis	
			HR (95% CI)	P
Age				
<58	10.3 (6.13–14.47)	0.616		
≥58	9.2 (5.58–12.82)			
ECOG performance status score				
0–1	11.5 (7.14–15.86)	0.011	0.63 (0.45–0.92)	0.022
2	7.1 (4.09–10.11)			
Gender				
Male	8.8 (5.21–12.39)	0.532		
Female	10.3 (6.34–14.26)			
Child–Pugh liver function classification				
A	10.5 (6.76–14.24)	0.236		
B	8.3 (5.84–10.76)			
HCC etiology				
HBV	9.3 (6.32–12.28)	0.437		
Other	10.4 (6.83–13.97)			
Previous local therapy status		0.625		
Yes	10.3 (6.87–13.73)			
No	8.8 (5.68–11.92)			
Extrahepatic metastasis status				
No	11.5 (7.21–15.79)	0.009	0.59 (0.31–0.89)	0.011
Yes	6.8 (4.35–9.25)			
Alpha fetoprotein (ng/mL)				
<400	10.3 (6.89–13.71)	0.414		
≥400	8.8 (7.13–10.47)			
Number of tumor lesions				
≤3	11.8 (8.14–15.46)	0.012	0.61 (0.38–0.90)	0.018
>3	7.1 (5.14–9.06)			
PVTT type				
Vp1–Vp2	10.7 (6.35–15.05)	0.315		
Vp3–Vp4	8.8 (6.03–11.57)			
Number of TACE treatment (times)				
≤2	8.8 (5.89–11.71)	0.257		
>2	11.5 (7.88–15.12)			
Dosage of Lenvatinib (mg)				
8	9.2 (6.77–11.63)	0.313		
12	10.7 (7.12–14.28)			
PD-1 blockades				
Tislelizumab	8.8 (5.35–12.25)	0.438		
Sintilimab	9.3 (6.67–11.93)			
Camrelizumab	9.2 (7.13–11.27)			
Pembrolizumab	10.7 (6.89–14.51)			

Safety Profile of TACE Combined with Lenvatinib and PD-1 Blockades

This study documented the adverse reactions experienced among the 67 HCC patients with PVTT during treatment with TACE combined with Lenvatinib and PD-1 blockades, as presented in Table 3. Of the 67 patients treated, 65 experienced adverse reactions, regardless of grade (97.0%). A total of 34 patients suffered from grade ≥3 adverse reactions (50.7%), with most experiencing grade 3–4 adverse reactions (33 patients, 49.3%). One patient died of liver failure (1.5%) after two courses of combination treatment.

Table 3 Safety Profile of the 67 HCC Patients with PVTT Who Received TACE Combined with Lenvatinib and PD-1 Blockades

Safety Profile	Total (N, %)	Grade 1–2 (N, %)	Grade ≥3 (N, %)
Adverse reactions	65 (97.0)		34 (50.7)
Hypertension	41 (61.2)	30 (44.8)	11 (16.4)
Fatigue	38 (56.7)	28 (41.8)	10 (14.9)
Abnormal liver function	35 (52.2)	26 (38.8)	9 (13.4)
Nausea and vomiting	31 (46.3)	23 (34.3)	8 (11.9)
Diarrhea	26 (38.8)	21 (31.3)	5 (7.5)
Rash	21 (31.3)	18 (26.9)	3 (4.5)
Hand-foot syndrome	17 (25.4)	12 (17.9)	5 (7.5)
Hepatitis	12 (17.9)	9 (13.4)	3 (4.5)
Proteinuria	10 (14.9)	8 (11.9)	2 (3.0)
Hematologic toxicities	7 (10.4)	5 (7.5)	2 (3.0)
RCCEP	5 (7.5)	5 (7.5)	0 (0.0)

The most common adverse reactions were hypertension (61.2%), fatigue (56.7%), abnormal liver function (52.2%), nausea and vomiting (46.3%), diarrhea (38.8%), rash (31.3%), hand-foot syndrome (25.4%), hepatitis (17.9%), proteinuria (14.9%), hematologic toxicity (10.4%), and reactive cutaneous capillary endothelial proliferation (RCCEP, 7.5%). Among the 35 patients with abnormal liver function, which included both impairment in aminotransferase levels and clinical events of liver decompensation, a total of 22 patients (32.8%) were deemed as liver decompensation after TACE treatment, which consisted of new-onset ascites in 8 patients (11.9%), jaundice in 7 patients (10.4%), hepatic encephalopathy in 5 patients (7.4%) and variceal bleeding in 2 patients (3.0%). The other 13 patients had elevation in aminotransferase levels (19.4%). The most common grade ≥ 3 adverse reactions were hypertension (16.4%), fatigue (14.9%), abnormal liver function (13.4%), nausea and vomiting (11.9%), diarrhea (7.5%), hand-foot syndrome (7.5%), rash (4.5%), hepatitis (4.5%), proteinuria (3.0%), and hematologic toxicity (3.0%). The overall safety profile of 67 patients treated with TACE plus Lenvatinib and PD-1 blockade was manageable and controllable.

Discussion

This study conducted a retrospective analysis to explore the feasibility and safety of TACE plus Lenvatinib and PD-1 blockades in patients with advanced HCC and PVTT. These findings suggested that HCC patients with PVTT receiving this combined local and systemic treatment demonstrated a manageable safety profile and encouraging long-term survival benefits. Notably, ECOG performance status, extrahepatic metastasis status and number of tumor lesions were identified as three independent risk factors that might contribute to the benefits of this regimen. Results of this study provided valuable insights into the development of treatment strategies for patients with HCC and PVTT. And these synergistic effects might potentially change the treatment landscape for HCC with PVTT, providing a new therapeutic option that might improve patient outcomes significantly.

Currently, it seemed that neither sorafenib nor Lenvatinib monotherapy met the therapeutic needs in clinical practice for advanced HCC with PVTT.³⁰ Therefore, there was an ongoing need to explore more efficacious clinical therapeutic strategies for these patients.³¹ However, due to the poor prognosis, higher risk of bleeding and greater likelihood of liver failure, considerable phase III clinical trials targeting immune-related regimens excluded HCC patients with VP4, resulting in a scarcity of valuable prospective medical evidence for these patients.^{13,15} Therefore, by collating data on the feasibility and safety of treatment with TACE combined with Lenvatinib and PD-1 blockades in clinical practice among HCC patients PVTT, this study preliminarily provided real-world data on the efficacy and safety of a combined locoregional and targeted immunotherapy approach for advanced HCC with PVTT, offering valuable clinical guidance.

Patients included in this study was clinically representative of common patients with HCC with PVTT, with a median age of 58 years (range 49–80 years), which was similar to the previous study by Li et al.³¹ Additionally, the category and incidence rate of PVTT in this study were also aligned with previous research, which suggested that advanced HCC

patients with PVTT included in this study were clinically representative. Noteworthy, although this study was designed as a retrospective study, a total of 18 patients with ECOG performance status of 2 score were also included for analysis, unlike the prospective design of Li XM's team who only recruited patients with ECOG of 0–1 scores.³¹ Additionally, this study also enrolled 20.9% patients with extrahepatic metastasis, which was closely matched with the previous work by Zou et al (14.3%).³² Therapeutic outcomes in this study observed an ORR of 50.7% (95% CI: 44.0–68.8%) and a DCR of 88.1% (95% CI: 77.8–94.7%), which was consistent with the previous study investigating TACE combined with Lenvatinib and PD-1 blockades in HCC patients with PVTT (ORR: 26.1%–68.3%, DCR: 78.3–85.4%).^{26,32,33} Additionally, it should be noted that 4 patients achieved CR and a significant reduction in target lesions was observed in most patients. Regarding the tumor thrombus response to the combination regimens, CR was observed in 6 patients and a reduction in tumor thrombus in over 30 patients. These results suggested that TACE combined with Lenvatinib and PD-1 blockade demonstrated encouraging anti-tumor activity and relieved thrombus conditions in HCC patients with PVTT. Furthermore, the subsequent prognostic data showed a median PFS of 9.3 months and a 24-month PFS rate of 21.5%, a median OS of 24.4 months and a 36-month OS rate of 24.4%. It seemed that the prognostic outcomes were also comparable with those from previous studies that explored the combination of local treatment plus Lenvatinib and PD-1 blockades (median PFS: 7.5–14.5 months, median OS: 18.2–23.5 months).^{26,32,33} However, it should be noted that although this study included HCC patients with PVTT who were classified as BCLC stage C according to the guideline,³⁴ the median PFS and OS appeared to surpass those reported in previous clinical trials exploring the combination of immunotherapy with anti-angiogenic drugs numerically, such as IMbrave150 trial (median PFS: 6.9 months, median OS: 19.2 months) and the LEAP-002 trial (median PFS: 8.2 months, median OS: 21.2 months),^{15,35} in spite of the fact that patients with BCLC stage of B were also included in these two trials. Collectively, these results preliminarily highlighted a significant synergistic action of combining TACE with Lenvatinib and PD-1 blockades, capable of achieving not only short-term anti-tumor activity but also long-term survival benefits.³⁶ The potential mechanism underlay this synergy might highlight that TACE induced local hypoxia and activated hypoxia-induce factors, thereby modulating the high expression of other angiogenic factors, such as VEGF.³⁷ The addition of Lenvatinib might inhibit VEGF upregulated by TACE, maximizing its anti-angiogenic activity, thus achieving a synergistic action in killing tumors and inhibiting angiogenesis.³⁸ Furthermore, the necrosis of tumor tissue caused by TACE released tumor antigens, enhancing the anti-tumor immune response in vivo, which resulted in the basis for the synergistic activity when combined with PD-1 blockades.³⁹ Additionally, the synergistic action of Lenvatinib and PD-1 blockades was achieved through modulating the tumor immune microenvironment, which was elucidated in previous phase III trial,⁴⁰ highlighting the synergistic effect when anti-angiogenic TKIs were used with PD-1 blockades. Therefore, the interaction between TACE, Lenvatinib and PD-1 blockades in vivo collectively contributed to their therapeutic activity in treating patients with advanced HCC with PVTT.

Interestingly, the exploratory analysis in this study suggested that the ECOG performance status score, extrahepatic metastasis status and number of tumor lesions were associated with the PFS of patients undergoing this triple-combination regimen to some extent. However, the significance of performance status score and number of tumor lesions for PFS should be interpreted objectively. To our knowledge, patients with an ECOG score of 2 and more than three metastatic lesions had been confirmed to inherently confer a worse prognosis in previous studies, regardless of the treatment regimen applied.⁴¹ Nevertheless, for the 14 patients in this study with extrahepatic metastasis, our study suggested that these patients had a median PFS of only 6.8 months after receiving the combined treatment of TACE, Lenvatinib and PD-1 blockade, which was significantly shorter than the median PFS of 11.5 months observed in patients without extrahepatic metastases. It was noteworthy that the median PFS of 6.8 months was aligned closely with the 6.9 months median PFS reported in the IMbrave150 study for patients with unresectable HCC treated with atezolizumab combined with bevacizumab.¹⁴ This interesting finding suggested that TACE treatment might not provide a positive therapeutic benefit for patients with extrahepatic metastases. This was also consistent with the conclusions of previous research by Yoo et al.⁴² They also highlighted that HCC patients with extrahepatic metastases failed to benefit from TACE treatment. In summary, the results of multivariate analysis required further validation through prospective randomized controlled clinical trials to confirm these findings and to explore efficacious therapeutic strategies for this subgroup.

Safety analysis of this regimen failed to reveal any new or unexpected adverse reactions. Furthermore, the incidence rate of grade ≥ 3 adverse reactions was 50.7%, suggesting that this regimen had a relatively tolerable safety profile among patients with advanced HCC and PVTT. Safety data observed in this study were closely in line with previous reports of adverse reactions regarding the combination of TACE, Lenvatinib and PD-1 blockade in patients with HCC.²⁹ However, it should be noted that among the 67 patients with HCC, one patient (1.5%) died from liver failure. A similar case of death due to liver failure (2.7%) was also reported in a previous study investigating the combination of Lenvatinib and PD-1 blockade in patients with HCC.⁴³ These outcomes suggested that patients with abnormal liver function required careful assessment before initiating TACE combined with Lenvatinib and PD-1 blockade. Close monitoring of liver function was essential to adjust the dosage or change therapeutic strategies as necessary. Interestingly, the incidence of elevation in aminotransferase levels was 19.4% in our study, which was basically consistent with the immune-related liver injury incidence (11.4%) among advanced/unresectable HCC who received first-line atezolizumab plus bevacizumab therapy.⁴⁴ And the association analysis found that increase in aminotransferase levels failed to affect the outcomes negatively. This aligned with our observations that while liver enzyme abnormalities were frequent, clinical outcomes were not adversely affected when managed appropriately. Additionally, the relatively common toxicities of hypertension (61.2%), hand-foot syndrome (25.4%) and proteinuria (14.9%) might be attributed to lenvatinib administration, whereas rash (31.3%), hepatitis (17.9%) and RCCEP (7.5%) were likely due to PD-1 blockades treatment. And hematologic toxicity (10.4%) was probably a result of TACE treatment.⁴⁵ Overall, the triple combination of TACE, Lenvatinib and PD-1 blockades demonstrated a manageable and controllable safety profile among HCC patients with PVTT, highlighting its viability as a therapeutic option and the careful patient selection and monitoring was necessary.

This study has several limitations. First, its design as a single-center retrospective analysis and the relatively limited cohort of patients with HCC from clinical practice meant that the results needed to be validated in multicenter study subsequently. Additionally, this study failed to introduce a TACE-related control group, and the single-arm retrospective nature of the study was associated with a certain degree of bias, impairing the significance of comparisons with historical data. Furthermore, although we attempted to standardize imaging intervals to every two cycles (42 days), the actual timing could vary due to clinical practice discrepancy and patient-specific factors. This inherent variability might introduce biases in the assessment of PFS. Future prospective studies with predefined and strictly adhered to imaging schedules were needed to validate these findings and ensure more robust and reproducible results. Additionally, expanding the patient sample to include a broader and more diverse population might improve the representativeness of the study results. We recommended that future research efforts aimed to include larger cohorts to enhance the generalizability of the findings. Finally, this study failed to explore the potential synergistic mechanisms of combining TACE with Lenvatinib and PD-1 blockade, which was essential for advancing the understanding of treatment's efficacy. Then, further investigation of exploring biomarkers that might predict the efficacy of the treatment regimen was crucial for identifying patients who were most likely to benefit from the combination therapy. And long-term follow-up studies were essential to evaluate the sustained efficacy and safety of the treatment regimen. Monitoring patients over extended periods might provide data on the durability of the treatment response and the management of long-term complications.

Despite these limitations, this study provides a preliminary exploration of the feasibility and safety of combining TACE with Lenvatinib and PD-1 blockade therapy in HCC patients with PVTT. The findings of this study offer potential clinical guidance for the frontline treatment of HCC patients with PVTT using this combined treatment approach. Future research should address these limitations through prospective, multicenter study comparing this treatment approach with standard treatments according to NCCN guidelines and deeper investigations into the underlying mechanisms and predictive biomarkers are needed to refine and validate this therapeutic strategy comprehensively. Over the next five years, we anticipate significant advancements in the management of HCC with PVTT. This might likely include the development of more personalized treatment strategies, incorporating genetic and molecular profiling to tailor therapy to individual patients clinically.

Informed Consent Statement

Despite the informed consent was waived by the Ethics Committee of Beijing Ditan Hospital, we confirmed that the data of the patients included in this study was anonymized or maintained with confidentiality.

Disclosure

The authors declare that there are no conflicts of interest in this work.

References

1. Runggay H, Arnold M, Ferlay J, et al. Global burden of primary liver cancer in 2020 and predictions to 2040. *J Hepatol.* 2022;77(6):1598–1606. doi:10.1016/j.jhep.2022.08.021
2. Feng R, Su Q, Huang X, et al. Cancer situation in China: what does the China cancer map indicate from the first national death survey to the latest cancer registration? *Cancer Commun.* 2023;43(1):75–86. doi:10.1002/cac2.12393
3. Xia C, Dong X, Li H, et al. Cancer statistics in China and United States, 2022: profiles, trends, and determinants. *Chin Med J.* 2022;135(5):584–590. doi:10.1097/cm9.0000000000002108
4. Xu XF, Xing H, Han J, et al. Risk Factors, patterns, and outcomes of late recurrence after liver resection for hepatocellular carcinoma: a multicenter study from China. *JAMA Surg.* 2019;154(3):209–217. doi:10.1001/jamasurg.2018.4334
5. Wang H, Lu Z, Zhao X. Tumorigenesis, diagnosis, and therapeutic potential of exosomes in liver cancer. *J Hematol Oncol.* 2019;12(1):133. doi:10.1186/s13045-019-0806-6
6. Jiao T, Tang H, Zhang W, et al. Long-term survival and portal vein patency with novel PVTT surgery approach in advanced HCC patients with Vp3/4 PVTT following combination therapy of TKIs and PD-1 inhibitors. *BMC Surg.* 2023;23(1):384. doi:10.1186/s12893-023-02291-1
7. Tao ZW, Cheng BQ, Zhou T, Gao YJ. Management of hepatocellular carcinoma patients with portal vein tumor thrombosis: a narrative review. *Hepatobiliary Pancreat Dis Int.* 2022;21(2):134–144. doi:10.1016/j.hbpd.2021.12.004
8. Vogel A, Martinelli E. Updated treatment recommendations for hepatocellular carcinoma (HCC) from the ESMO clinical practice guidelines. *Ann Oncol.* 2021;32(6):801–805. doi:10.1016/j.annonc.2021.02.014
9. Feng JK, Liu ZH, Fu ZG, et al. Efficacy and safety of transarterial chemoembolization plus antiangiogenic- targeted therapy and immune checkpoint inhibitors for unresectable hepatocellular carcinoma with portal vein tumor thrombus in the real world. *Front Oncol.* 2022;12:954203. doi:10.3389/fonc.2022.954203
10. Sun J, Guo R, Bi X, et al. Guidelines for diagnosis and treatment of hepatocellular carcinoma with portal vein tumor thrombus in China (2021 Edition). *Liver Cancer.* 2022;11(4):315–328. doi:10.1159/000523997
11. Tan ZB, Zhang J. Recent advances in treatment strategies for hepatocellular carcinoma with portal vein cancer thrombus. *Eur Rev Med Pharmacol Sci.* 2023;27(17):8119–8134. doi:10.26355/eurrev_202309_33572
12. Wang Y, Deng B. Hepatocellular carcinoma: molecular mechanism, targeted therapy, and biomarkers. *Cancer Metastasis Rev.* 2023;42(3):629–652. doi:10.1007/s10555-023-10084-4
13. Kudo M, Finn RS, Qin S, et al. Lenvatinib versus sorafenib in first-line treatment of patients with unresectable hepatocellular carcinoma: a randomised Phase 3 non-inferiority trial. *Lancet.* 2018;391(10126):1163–1173. doi:10.1016/s0140-6736(18)30207-1
14. Cheng AL, Qin S, Ikeda M, et al. Updated efficacy and safety data from IMbrave150: atezolizumab plus bevacizumab vs. sorafenib for unresectable hepatocellular carcinoma. *J Hepatol.* 2022;76(4):862–873. doi:10.1016/j.jhep.2021.11.030
15. Llovet JM, Kudo M, Merle P, et al. Lenvatinib plus pembrolizumab versus lenvatinib plus placebo for advanced hepatocellular carcinoma (LEAP-002): a randomised, double-blind, phase 3 trial. *Lancet Oncol.* 2023;24(12):1399–1410. doi:10.1016/s1470-2045(23)00469-2
16. Rizzo A, Ricci AD, Brandi G. Immune-based combinations for advanced hepatocellular carcinoma: shaping the direction of first-line therapy. *Future Oncol.* 2021;17(7):755–757. doi:10.2217/fon-2020-0986
17. Zhang W, Tong S, Hu B, et al. Lenvatinib plus anti-PD-1 antibodies as conversion therapy for patients with unresectable intermediate-advanced hepatocellular carcinoma: a single-arm, Phase II trial. *J Immunother Cancer.* 2023;11(9). doi:10.1136/jitc-2023-007366
18. Tsurusaki M, Murakami T. Surgical and Locoregional Therapy of HCC: TACE. *Liver Cancer.* 2015;4(3):165–175. doi:10.1159/000367739
19. Xie DY, Zhu K, Ren ZG, et al. A review of 2022 Chinese clinical guidelines on the management of hepatocellular carcinoma: updates and insights. *Hepatobiliary Surg Nutr.* 2023;12(2):216–228. doi:10.21037/hbsn-22-469
20. Kudo M, Ueshima K, Ikeda M, et al. Randomised, multicentre prospective trial of transarterial chemoembolisation (TACE) plus sorafenib as compared with TACE alone in patients with hepatocellular carcinoma: TACTICS trial. *Gut.* 2020;69(8):1492–1501. doi:10.1136/gutjnl-2019-318934
21. Peng Z, Fan W, Zhu B, et al. Lenvatinib combined with transarterial chemoembolization as first-line treatment for advanced hepatocellular carcinoma: a phase III, randomized clinical trial (LAUNCH). *J Clin Oncol.* 2023;41(1):117–127. doi:10.1200/jco.22.00392
22. Cheu JW, Wong CC. Mechanistic Rationales Guiding Combination Hepatocellular Carcinoma Therapies Involving Immune Checkpoint Inhibitors. *Hepatology.* 2021;74(4):2264–2276. doi:10.1002/hep.31840
23. Wang WJ, Liu ZH, Wang K, et al. Efficacy and safety of TACE combined with lenvatinib and PD-1 inhibitors for unresectable recurrent HCC: a multicenter, retrospective study. *Cancer Med.* 2023;12(10):11513–11524. doi:10.1002/cam4.5880
24. Rizzo A, Ricci AD, Brandi G. Trans-arterial chemoembolization plus systemic treatments for hepatocellular carcinoma: an update. *J Pers Med.* 2022;12(11):1788. doi:10.3390/jpm12111788
25. Kudo M, Kitano M, Sakurai T, Nishida N. General rules for the clinical and pathological study of primary liver cancer, nationwide follow-up survey and clinical practice guidelines: the outstanding achievements of the liver cancer study group of Japan. *Dig Dis.* 2015;33(6):765–770. doi:10.1159/000439101
26. Li X, Ding X, Liu M, et al. A multicenter prospective study of TACE combined with lenvatinib and camrelizumab for hepatocellular carcinoma with portal vein tumor thrombus. *Cancer Med.* 2023;12(16):16805–16814. doi:10.1002/cam4.6302
27. Lencioni R, Llovet JM. Modified RECIST (mRECIST) assessment for hepatocellular carcinoma. *Semin Liver Dis.* 2010;30(1):52–60. doi:10.1055/s-0030-1247132
28. Finn RS, Ikeda M, Zhu AX, et al. Phase Ib study of lenvatinib plus pembrolizumab in patients with unresectable hepatocellular carcinoma. *J Clin Oncol.* 2020;38(26):2960–2970. doi:10.1200/jco.20.00808
29. Cai M, Huang W, Huang J, et al. Transarterial chemoembolization combined with lenvatinib plus PD-1 inhibitor for advanced hepatocellular carcinoma: a retrospective cohort study. *Front Immunol.* 2022;13:848387. doi:10.3389/fimmu.2022.848387

30. Khan AR, Wei X, Xu X. Portal vein tumor thrombosis and hepatocellular carcinoma - the changing tides. *J Hepatocell Carcinoma*. 2021;8:1089–1115. doi:10.2147/jhc.s318070
31. Zhang ZM, Lai EC, Zhang C, et al. The strategies for treating primary hepatocellular carcinoma with portal vein tumor thrombus. *Int J Surg*. 2015;20:8–16. doi:10.1016/j.ijsu.2015.05.009
32. Zou X, Xu Q, You R, Yin G. Correlation and efficacy of TACE combined with lenvatinib plus PD-1 inhibitor in the treatment of hepatocellular carcinoma with portal vein tumor thrombus based on immunological features. *Cancer Med*. 2023;12(10):11315–11333. doi:10.1002/cam4.5841
33. Li SQ, Wu JY, Wu JY, et al. Transarterial chemoembolization plus lenvatinib and PD-1 inhibitors for hepatocellular carcinoma with main trunk portal vein tumor thrombus: a multicenter retrospective study. *J Hepatocell Carcinoma*. 2023;10:1799–1811. doi:10.2147/jhc.s428980
34. Luo F, Li M, Ding J, Zheng S. The progress in the treatment of hepatocellular carcinoma with portal vein tumor thrombus. *Front Oncol*. 2021;11:635731. doi:10.3389/fonc.2021.635731
35. Finn RS, Qin S, Ikeda M, et al. Atezolizumab plus bevacizumab in unresectable hepatocellular carcinoma. *N Engl J Med*. 2020;382(20):1894–1905. doi:10.1056/NEJMoa1915745
36. Zhang Z, Wu Y, Zheng T, et al. Efficacy of transarterial chemoembolization combined with molecular targeted agents for unresectable hepatocellular carcinoma: a network meta-analysis. *Cancers*. 2022;14(15). doi:10.3390/cancers14153710
37. Lencioni R. Chemoembolization for hepatocellular carcinoma. *Semin Oncol*. 2012;39(4):503–509. doi:10.1053/j.seminoncol.2012.05.004
38. Ding X, Sun W, Li W, et al. Transarterial chemoembolization plus lenvatinib versus transarterial chemoembolization plus sorafenib as first-line treatment for hepatocellular carcinoma with portal vein tumor thrombus: a prospective randomized study. *Cancer*. 2021;127(20):3782–3793. doi:10.1002/ncr.33677
39. Sun T, Ren Y, Sun B, et al. The Feasibility of TACE Combined with TKIs Plus PD-1 antibody for advanced HCC. *J Hepatocell Carcinoma*. 2023;10:447–457. doi:10.2147/jhc.s400948
40. Qin S, Chan SL, Gu S, et al. Camrelizumab plus rivoceranib versus sorafenib as first-line therapy for unresectable hepatocellular carcinoma (CARES-310): a randomised, open-label, international phase 3 study. *Lancet*. 2023;402(10408):1133–1146. doi:10.1016/s0140-6736(23)00961-3
41. Cheng JD, Chai LX, Zhao ZP, Hao YY, Li S. Efficacy and safety of anlotinib for patients with advanced NSCLC who progressed after standard regimens and the preliminary analysis of an efficacy predictor. *Cancer Manag Res*. 2020;12:5641–5650. doi:10.2147/cmar.s253366
42. Yoo JJ, Lee JH, Lee SH, et al. Comparison of the effects of transarterial chemoembolization for advanced hepatocellular carcinoma between patients with and without extrahepatic metastases. *PLoS One*. 2014;9(11):e113926. doi:10.1371/journal.pone.0113926
43. Jia M, Jia JK, Xu J, Xue HZ. Feasibility and tolerability of lenvatinib, plus PD-1 blockades for patients with unresectable hepatocellular carcinoma: a retrospective exploratory study. *Cancer Manag Res*. 2022;14:2625–2638. doi:10.2147/cmar.s372125
44. Celsa C, Cabibbo G, Fulgenzi CAM, et al. Characteristics and outcomes of immunotherapy-related liver injury in patients with hepatocellular carcinoma versus other advanced solid tumours. *J Hepatol*. 2024;80(3):431–442. doi:10.1016/j.jhep.2023.10.040
45. Lin Z, Chen D, Hu X, et al. Clinical efficacy of HAIC (FOLFOX) combined with lenvatinib plus PD-1 inhibitors vs. TACE combined with lenvatinib plus PD-1 inhibitors in the treatment of advanced hepatocellular carcinoma with portal vein tumor thrombus and arterioportal fistulas. *Am J Cancer Res*. 2023;13(11):5455–5465.

International Journal of General Medicine

Dovepress

Publish your work in this journal

The International Journal of General Medicine is an international, peer-reviewed open-access journal that focuses on general and internal medicine, pathogenesis, epidemiology, diagnosis, monitoring and treatment protocols. The journal is characterized by the rapid reporting of reviews, original research and clinical studies across all disease areas. The manuscript management system is completely online and includes a very quick and fair peer-review system, which is all easy to use. Visit <http://www.dovepress.com/testimonials.php> to read real quotes from published authors.

Submit your manuscript here: <https://www.dovepress.com/international-journal-of-general-medicine-journal>