



Case Report

Lumbar cistern *Candida* intradural abscess following epidural anesthesia

Gabrielle Santangelo¹, Jonathan Stone¹, Mahlon Johnson², Kevin Walter¹

Departments of ¹Neurosurgery, and ²Neuropathology, University of Rochester, Strong Memorial Hospital, Rochester, New York, United States.

E-mail: *Gabrielle Santangelo - gabrielle_santangelo@urmc.rochester.edu; Jonathan Stone - jonathan_stone@urmc.rochester.edu; Mahlon Johnson - mahlon_johnson@urmc.rochester.edu; Kevin Walter - kevin_walter@urmc.rochester.edu



*Corresponding author:

Gabrielle Santangelo,
Department of Neurosurgery,
University of Rochester, Strong
Memorial Hospital, Rochester,
New York, United States.

gabrielle_santangelo@urmc.rochester.edu

Received : 18 August 2022
Accepted : 06 September 2022
Published : 23 September 2022

DOI
[10.25259/SNI_750_2022](https://doi.org/10.25259/SNI_750_2022)

Quick Response Code:



ABSTRACT

Background: This report describes a case of an immunocompetent patient with an intradural abscess from *Candida dubliniensis*. The majority of fungal spine infections, although rare in general, are due to *Aspergillus* or *C. albicans* through systemic fungemia. To date, there have only been two reports of spondylodiscitis from *C. dubliniensis*.

Case Description: A 37-year-old immunocompetent female patient presented to the neurosurgical service for worsening headaches with nausea, vomiting, vision changes, and weight loss. MRI studies showed diffuse leptomeningeal enhancement of the distal spinal cord, conus medullaris, and nerve roots of the cauda equina extending beyond the neural foramina bilaterally. She had persistent symptoms and no clear diagnosis on lumbar puncture or systemic testing therefore L5-S1 laminectomy for an intradural tissue biopsy was performed. During surgery, cultures were taken and grew colonies of *C. dubliniensis*.

Conclusion: This organism has been reported rarely in the literature as being an infectious agent, thus diagnosing remains a challenge but should be considered in patients with a suggestive history.

Keywords: *Candida dubliniensis*, Cauda equina, Intradural abscess, Spinal abscess

INTRODUCTION

In this report, the investigators describe a patient with an intradural abscess comprised *Candida dubliniensis* in an intravenous drug user following epidural anesthesia. This is the third report of *C. dubliniensis* causing intradural extramedullary spinal infection. However, this case differs from the previous reports in many aspects. This is the first case of *Candida dubliniensis* extramedullary spine infection occurring in the context of a confirmed competent immune system. The patient is a female in her third decade of life with no clear immunodeficiency, a positive history for intravenous drug use, and intrapartum epidural anesthesia coinciding with the onset her symptoms. The diagnosis and management are described in detail.

CASE REPORT

History and examination

A 37-year-old female patient who received epidural anesthesia during childbirth presented to the neurosurgical service eleven months postpartum for worsening headaches with nausea,

This is an open-access article distributed under the terms of the Creative Commons Attribution-Non Commercial-Share Alike 4.0 License, which allows others to remix, transform, and build upon the work non-commercially, as long as the author is credited and the new creations are licensed under the identical terms.

©2022 Published by Scientific Scholar on behalf of Surgical Neurology International

vomiting, vision changes, and weight loss. Here, a medical history was significant for peripheral neuropathies, unspecified mood disorder, herpes labialis, hepatitis C (HCV), intravenous substance abuse (including heroin and cocaine, now on buprenorphine), and noncompliance. Her medications before admission included gabapentin 300 mg daily, buprenorphine 2 mg daily, and topiramate 25 mg daily. She was never treated for hepatitis.

Delivery of her child the following month was uncomplicated, but she did require a second epidural injection during labor. After birth of her child, she had persistent headaches that were suspected to be secondary to a cerebrospinal fluid leak. She underwent epidural blood patch to treat the suspected leak, but her symptoms did not resolve. She began having shooting pain in her back that radiated into her legs. She described the headache as generalized, dull, nonradiating, and constant with a gradual onset that “worsen with laying down or standing up” and endorsed accompanying photophobia.

She had papilledema with diplopia, mild bilateral cranial nerve VI palsy, and decreased visual acuity. At this point, she was seen by ophthalmology and was admitted to the hospital. A lumbar puncture (LP) showed mildly elevated nucleated cell count of 179 with 50% PMNs, 42% lymphocytes, and 6% monocytes. Glucose was low at 36 mg/dL (serum glucose was 92 mg/dL) and protein was elevated at 287 mg/dL, consistent with a meningitis process and suggestive of bacterial meningitis. However, her CSF cultures were negative for histoplasma, tuberculosis, AFB, *Cryptococcus*, cytospin, fungus, and viruses. Additional testing showed HIV negativity, hepatitis A and C positivity and negative serology for listeria, *Brucella*, VDRL, syphilis, and lyme.

Her general chemistry panel on admission and throughout her hospital stay was normal. Liver function tests, CRP, IgG, and thrombocyte count were unremarkable. She was negative for antinuclear antibody, anti-LA/anti-RO, and antineutrophil cytoplasmic antibodies. Her CRP was normal with a mildly elevated ESR at the time of presentation in April, consistent with a largely resolved inflammatory process.

MRI studies showed diffuse leptomeningeal enhancement of the distal spinal cord, conus medullaris, and nerve roots of the cauda equina extending beyond the neural foramina bilaterally in T1 contrasted images [Figures 1 and 2]. The nerve roots were displaced laterally in the distal thecal sac. The dura appeared thickened and avidly enhanced from L5 to S2 and there was a fluid-fluid level appreciated on the T2-weighted sequences suggesting possibly proteinaceous debris, blood, or pus [Figure 3]. The DWI image showed marked restriction from L4 to L5 through the S2 levels [Figure 4].

Infectious disease was consulted and suggested chronic neutrophilic meningitis in the setting of an underlying

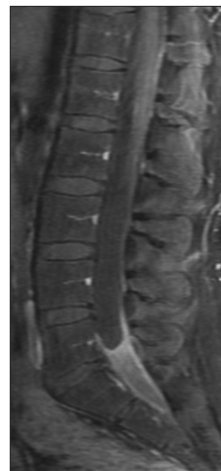

Figure 1: Intradural and leptomeningeal enhancement medullaris, sagittal T1 fat suppressed with contrast.

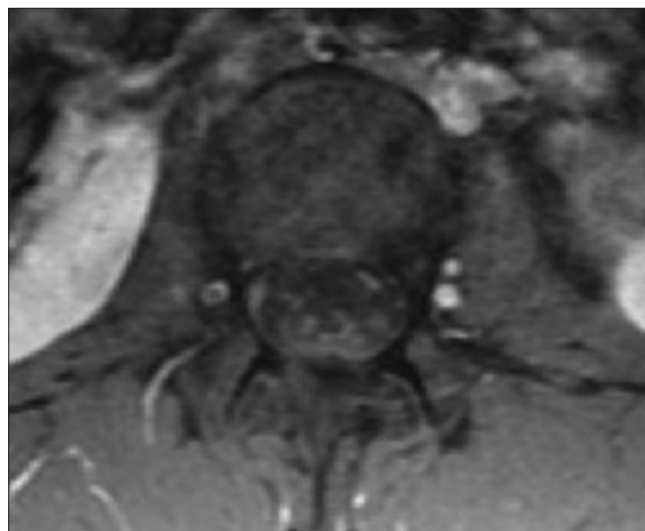


Figure 2: Enhancing nerve roots of the cauda equina, axial T1 with contrast.

autoimmune/inflammatory condition given the nature of her pain and her complicated medical history. She was discharged after 1 week on methylprednisolone (1 g/day for 5 days) that resulted in a near resolution of her back pain, headaches, and vision changes except for when she missed doses. She had no fevers, chills, or night sweats but reported a 10 lb weight loss with poor appetite. Her steroids were tapered to 50 mg, daily and when the dose was tapered, she had symptom return.

Infectious disease continued following and a lack of resolution of her pain prompted additional screening. Repeat

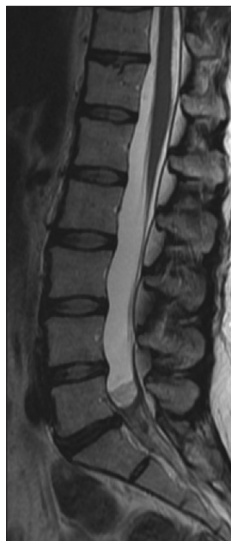

Figure 3: Thickening and enhancement at the lower lumbosacral spinal canal (from approximately L4 to L5 through the S2 levels), sagittal T2.

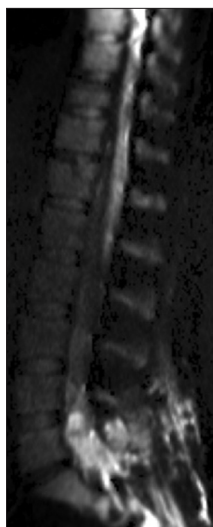


Figure 4: Soft-tissue collection demonstrating diffuse heterogeneous enhancement and marked restriction within the thecal sac, isotropic (diffusion-weighted imaging).

MRI at a month post-partum showed no significant changes from the previous scan and continued leptomeningeal enhancement of the distal spinal cord and cauda equina nerve

roots consistent with arachnoiditis. Her second LP showed a worsening inflammatory picture with 2682 nucleated cells (94% PMNs), low glucose at 26, elevated protein at 297, and 13 bands. The patient's WBC was elevated at 23.2 from 16.4 three months prior although she remained afebrile. Her back pain rating at this time was 6–7/10.

Operation

Given her persistent symptoms and lack of diagnosis, she was scheduled for an L5-S1 laminectomy for an intradural tissue biopsy. During surgery, cultures were taken at every level of the exposure. After the laminectomy was complete, the epidural space appeared normal, but the dura was thickened and difficult to open inferiorly. The dura incision was carried cranially and once the subarachnoid space was entered, a copious amount of white, soft purulence material was released. The nerve roots were adherent to surrounding dura and to each other. There were no obvious signs of a capsule; however, the infection was likely loculated based on its appearance and indolent course. The intradural compartment was irrigated until the CSF ran clear. There were no intraoperative complications and she was started on postoperative antibiotics, including 500 mg metronidazole q8 h, 1 g vancomycin q12 h, IV fluconazole 400 mg, daily, and 2 g cefepime q12 h. After the procedure, the patient remained afebrile, without aberration in vitals, and was ambulatory.

Pathological findings

The histology showed rare nonseptate pseudohyphae and blastospores without a broad-based bud, indicative of a *Candida* species [Figure 5]. The submitted tissue was necrotic and demonstrated local inflammation on pathologic examination [Figure 6]. Microbiology cultures from the abscess grew colonies of *C. dubliniensis*. No other organisms were isolated or seen under various other staining modalities and multiple cultures taken from the abscess all grew only *C. dubliniensis* and no other organisms. This was a pan-sensitive microbe with low minimum inhibitory concentrations to caspofungin, fluconazole, and voriconazole of 0/25, 1.0, and 0.012 mcg/mL, respectively.

Postoperative course

Cefepime, metronidazole, vancomycin, and IV fluconazole were discontinued and the patient was started on 400 mg fluconazole PO daily (rather than outpatient peripherally inserted central catheter due to IV drug abuse) for a planned minimum of 4 weeks. After surgery, she endorsed only mild low back pain at the incision site and with position changes.

At 3-week postoperative follow-up, her back pain was worsening and the operative site was infected with induration of the surrounding skin but remained afebrile. She reported

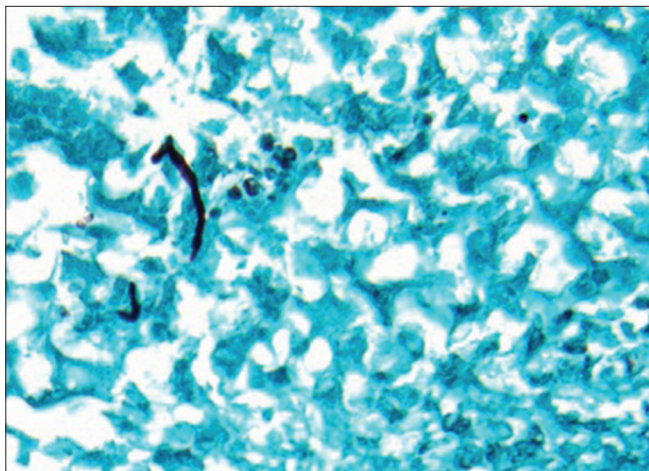


Figure 5: Gomori methenamine silver stain showing hyphal forms, original magnification $\times 400$.

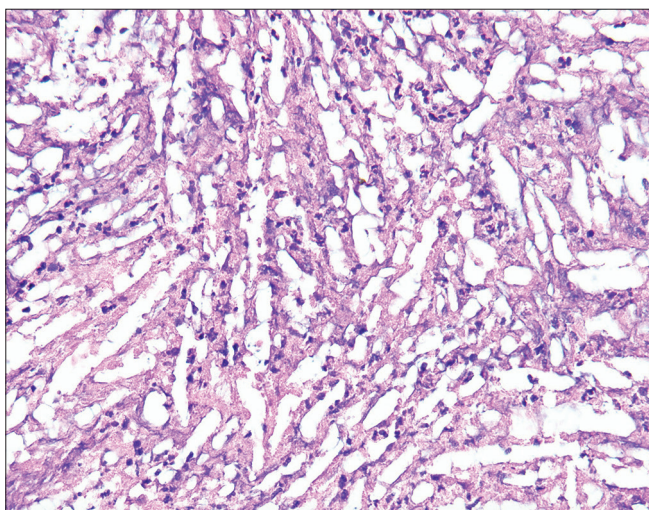


Figure 6: Hematoxylin and eosin stain showing necrosis, original magnification $\times 400$.

a significant amount of purulent drainage produced from her incision, which resulted in improvement of her symptoms. She was started on cephalexin. She is currently scheduled for follow-up with infectious disease and for a repeat MRI of her lumbar spine.

Of note, throughout the patient's entire hospital course and at her follow-up appointments, she remained without neurological deficit. Her mental status examination, cranial nerves, strength, sensory perception, coordination, and reflexes were all within normal limits and without significant change at any time point.

DISCUSSION

The majority of fungal spine infections, although rare in general, are due to *Aspergillus* or *C. albicans* through a

systemic fungemia. To date, there have only been two reports of spondylodiscitis from *C. dubliniensis*.^[6,9] In the previous reports, one patient was immunocompromised due to HIV and HCV coinfection and the other patient had a history of IV drug abuse and had chronic hepatitis C but was not tested for HIV. In the present study, the patient did not have any documented form of immunosuppression, including negative HIV testing. However, her symptoms developed shortly after the birth of her daughter and pregnancy can be considered a form of immunosuppression, particularly due to a shift from Th1 cytokines to Th2 during pregnancy that can allow fungi to establish within the host.^[10] Her hepatitis was not progressed to cirrhosis, which promotes increased susceptibility to fungal infections. The 3-month steroid course for presumed arachnoiditis was unlikely to be the inciting factor since the symptom onset preceded the steroid use.

To accurately diagnose and plan for intervention for intradural abscess, it has been shown that MRI with DWI is the most useful imaging to obtain, particularly in evaluating for dissemination.^[5,8] The MRI appearance in the case generated a broad differential diagnosis including postviral conditions, granulomatous diseases, neoplasm, inflammatory (pachymeningitis), and autoimmune flare. This broad differential, persistent symptoms, and negative serial LPs resulted in open biopsy of the intradural compartment.

While both of the previous reports described a hematogenous spread of the infection, the patient in the present case report showed no systemic involvement of the fungus.^[4,7] Fungal infections in the spine are more likely to cause a discitis or osteomyelitis.^[4,6,7] This case differs because she had an intradural extramedullary abscess without involvement of the bony structures. Both prior reports were to be found in men in the 6th decade or later. However, an intradural abscess is typically associated with meningitis, symptoms of which were appreciated in the present case.^[4,1] It is possible that the patient had meningitis early in the course and because she was immunocompetent, loculated the abscess, creating, and indolent course.

The etiology of the fungus remains unclear in this case. While *Candida dubliniensis* has been reported as an oral colonizer in HIV-positive patients, it is unclear how this fungus was introduced into this patient.^[6] There are reports, although rare, of intradural abscesses following epidural steroids injections.^[3,8] It is possible that *C. dubliniensis* may have been introduced through this route during labor. It is also possible that the patient was fungemic at the time of her epidural blood patch and an infection was created from her autologous blood. It has been shown that intravenous drug usage can lead to inoculation of fungus, which can

form spinal infection.^[7] This is a possibility in the present case; however, it is less likely given that there was no sign of systemic infection at any point. It is also feasible that the infection could have been systemic at its inception and resolved after the formation of a stable abscess. In fact, one study discusses that IV drug users can develop a transient systemic candidiasis hours after injection of the drug, although typically these patients present with a septic picture.^[7] Another possible etiology of the fungus is the blood patch, she received for symptomatic CSF leak after administration of spinal anesthesia. If she had a systemic infection from IV drug use and her blood was introduced into her spinal canal, the infection may have propagated within this space.

The complication of soft-tissue infection at the surgical site may be due to potential seeding during closure. The maintenance of intact neurological examination without focal findings is understandable considering the location of the abscess and the lack of fungal foci within the brain. However, this may be misleading and falsely reassuring without functional deficit as to the severity of infection.

Management of these cases is not clearly delineated in the literature. It is believed that treatment after diagnosis is relatively simple given limited involvement of skeletal structures and involves a 2–4 week treatment of fluconazole with following amphotericin b if not yet resolved.^[9] Surgically, the approach to management is similar to an intradural neoplasm involving the cauda equina. However, due to the challenges in diagnosis, it is routine to send for histopathology on the samples collected. As follow-up, it is prudent to assess MRI changes and leukocyte count.^[4]

CONCLUSION

This report described an indolent course of intradural *C. dubliniensis* infection in an immunocompetent woman. This pathogen is most frequently seen in cases of oral candidiasis, candidemia, and endophthalmitis and spinal involvement is extremely rare.^[2] The previous work has shown that fungal spine infections typically have a delay to diagnosis due to the difficulty isolating the organism; however, these delays can result in long-term neurological sequelae.^[10] Fortunately, diagnosis was made in this patient after an open biopsy was performed, and she remains ambulatory.

Declaration of patient consent

Patient's consent not required as patient's identity is not disclosed or compromised.

Financial support and sponsorship

Nil.

Conflicts of interest

There are no conflicts of interest.

REFERENCES

- Cheon JE, Yang HJ, Chung YN, Park SB. Pyogenic intradural abscess of lumbar spine : A case report. 2015;11:18-21.
- Chia SL, Tan BH, Tan CT, Tan SB. Candida spondylodiscitis and epidural abscess: Management with shorter courses of anti-fungal therapy in combination with surgical debridement. J Infect 2005;51:17-23.
- Kauffman CA, Malani AN. Fungal infections associated with contaminated steroid injections. Microbiol Spectr 2016;4:1-13.
- Kulkarni AG, Chu G, Fehlings MG. Pyogenic intradural abscess: A case report. Spine (Phila Pa 1976) 2008;32:E354-7.
- Moritani T, Kim J, Capizzano AA, Kirby P, Kademian J, Sato Y. Pyogenic and non-pyogenic spinal infections: Emphasis on diffusion-weighted imaging for the detection of abscesses and pus collections. Br J Radiol 2014;87:20140011.
- Oksi J, Finnilä T, Hohenthal U, Rantakokko-Jalava K. *Candida dubliniensis* spondylodiscitis in an immunocompetent patient. Case report and review of the literature. Med Mycol Case Rep 2014;3:4-7.
- Rowe IF, Wright ED, Higgins CS, Burnie JP. Intervertebral infection due to *Candida albicans* in an intravenous heroin abuser. Ann Rheum Dis 1988;47:522-5.
- Saigal G, Post MJ, Kozic D. Thoracic intradural *Aspergillus* abscess formation following epidural steroid injection. Am J Neuroradiol 2004;25:642-4.
- Salzer HJ, Rolling T, Klupp EM, Schmiedel S. Hematogenous dissemination of *Candida dubliniensis* causing spondylodiscitis and spinal abscess in a HIV-1 and HCV-coinfected patient. Med Mycol Case Rep 2015;8:17-20.
- Singh N, Perfect JR. Immune reconstitution syndrome and exacerbation of infections after pregnancy. Clin Infect Dis 2007;45:1192-9.

How to cite this article: Santangelo G, Stone J, Johnson M, Walter K. Lumbar cistern *Candida* intradural abscess following epidural anesthesia. Surg Neurol Int 2022;13:435.