



Diagnostic accuracy of sliding sign for detecting pouch of Douglas obliteration and bowel involvement in women with suspected endometriosis: systematic review and meta-analysis

J. L. ALCÁZAR¹, P. M. EGUEZ², P. FORCADA³, E. TERNERO⁴, C. MARTÍNEZ⁵,
M. Á. PASCUAL⁶ and S. GUERRIERO^{7,8}

¹Department of Obstetrics and Gynecology, Clínica Universidad de Navarra, Pamplona, Spain; ²Department of Obstetrics and Gynecology, University Hospital, Badajoz, Spain; ³Department of Obstetrics and Gynecology, University Hospital, Castellón, Spain; ⁴Department of Obstetrics and Gynecology, Puerta de Mar University Hospital, Cadiz, Spain; ⁵Department of Obstetrics and Gynecology, La Fe University Hospital, Valencia, Spain; ⁶Department of Obstetrics, Gynecology, and Reproduction, Hospital Universitari Dexeus, Barcelona, Spain; ⁷Centro Integrato di Procreazione Medicalmente Assistita e Diagnostica Ostetrico-Ginecologica, Azienda Ospedaliero Universitaria-Policlinico Duilio Casula Monserrato, Monserrato, Italy; ⁸Department of Obstetrics and Gynecology, University of Cagliari, Cagliari, Italy

KEYWORDS: bowel; endometriosis; pouch of Douglas; sliding sign; sonography

CONTRIBUTION

What are the novel findings of this work?

This is the first systematic review and meta-analysis to focus specifically on studies assessing the diagnostic performance of the sliding sign on transvaginal ultrasound for detecting bowel involvement in women with suspected pelvic endometriosis. This study also provides up-to-date evidence regarding the diagnostic performance of the sliding sign for detecting pouch of Douglas obliteration.

What are the clinical implications of this work?

Given its good diagnostic performance, evaluation of the sliding sign using ultrasound should be implemented to assess for pouch of Douglas obliteration and bowel involvement in patients with suspected pelvic endometriosis.

ABSTRACT

Objective The aim of this systematic review and meta-analysis was to evaluate the diagnostic accuracy of the sliding sign on transvaginal ultrasound (TVS) in detecting pouch of Douglas obliteration and bowel involvement in patients with suspected endometriosis, using laparoscopy as the reference standard.

Methods A search for studies evaluating the role of the sliding sign in the assessment of pouch of Douglas

obliteration and/or bowel involvement using laparoscopy as the reference standard published from January 2000 to October 2021 was performed in PubMed/MEDLINE, Web of Science, CINAHL, The Cochrane Library, ClinicalTrials.gov and SCOPUS databases. The Quality Assessment of Diagnostic Accuracy Studies-2 (QUADAS-2) was used to evaluate the quality of the studies. Analyses were performed using MIDAS and METANDI commands in STATA.

Results A total of 334 citations were identified. Eight studies were included in the analysis, resulting in 938 and 963 patients available for analysis of the diagnostic accuracy of the sliding sign for pouch of Douglas obliteration and bowel involvement, respectively. The mean prevalence of pouch of Douglas obliteration was 37% and the mean prevalence of bowel involvement was 23%. The pooled estimated sensitivity, specificity, positive likelihood ratio, negative likelihood ratio and diagnostic odds ratio of the sliding sign on TVS for detecting pouch of Douglas obliteration were 88% (95% CI, 81–93%), 94% (95% CI, 91–96%), 15.3 (95% CI, 10.2–22.9), 0.12 (95% CI, 0.07–0.21) and 123 (95% CI, 62–244), respectively. The heterogeneity was moderate for sensitivity and low for specificity for detecting pouch of Douglas obliteration. The pooled estimated sensitivity, specificity, positive likelihood ratio, negative likelihood ratio and diagnostic odds ratio of the sliding sign on TVS for detecting bowel involvement

Correspondence to: Dr J. L. Alcázar, Department of Obstetrics and Gynecology, Clínica Universidad de Navarra, Avenida Pío XII 36, 3110 Pamplona, Spain (e-mail: jlalcazar@unav.es)

Accepted: 2 March 2022

were 81% (95% CI, 64–91%), 95% (95% CI, 91–97%), 16.0 (95% CI, 9.0–28.6), 0.20 (95% CI, 0.10–0.40) and 81 (95% CI, 34–191), respectively. The heterogeneity for the meta-analysis of diagnostic accuracy for bowel involvement was high.

Conclusion The sliding sign on TVS has good diagnostic performance for predicting pouch of Douglas obliteration and bowel involvement in women with suspected endometriosis. © 2022 The Authors. *Ultrasound in Obstetrics & Gynecology* published by John Wiley & Sons Ltd on behalf of International Society of Ultrasound in Obstetrics and Gynecology.

INTRODUCTION

Endometriosis is a gynecological disease, defined as the presence of endometrial-like tissue outside the uterus, that affects up to 5–10% of premenopausal women, being more frequent in women with symptoms such as dysmenorrhea, chronic pelvic pain, dyspareunia, dyschezia and infertility¹.

The diagnosis of endometriosis can be difficult and is often delayed². Transvaginal ultrasound (TVS) has been shown to be a highly accurate and reproducible tool for detecting endometriosis. It has been proposed as the primary imaging modality in patients with pelvic pain^{3–5} and has shown a high correlation with laparoscopy⁶. The International Deep Endometriosis Analysis (IDEA) group proposed a systematic scanning technique for sonographic evaluation of the pelvis when a patient is suspected to have endometriosis⁷. This technique is based on four steps: evaluation of the uterus and the adnexa to identify and describe signs of adenomyosis and examine for the presence of endometrioma; assessment of ‘soft markers’, such as ‘kissing’ ovaries; assessment of the ‘sliding sign’; and identification of deep endometriotic nodules.

The sliding-sign diagnostic test, which involves determining whether the anterior rectum glides freely across the posterior aspect of the cervix, posterior vaginal wall (for an anteverted uterus) or uterine fundus (for a retroverted uterus)⁷, has been associated with bowel involvement, namely rectal or sigmoid anterior wall infiltration by endometriotic nodules⁸, and pouch of Douglas obliteration⁹. Pouch of Douglas obliteration is considered to be a sign of severe endometriosis and could result in marked anatomical distortion of the pelvis. Women with pouch of Douglas obliteration are three times more likely to have bowel endometriosis and bowel surgery than are patients with a non-obliterated pouch of Douglas¹⁰. A negative sliding sign is considered a ‘hard marker’ for rectal/sigmoid infiltration by deep endometriosis, which may make surgery more complex¹¹.

Pouch of Douglas obliteration or bowel involvement during surgery may increase the duration of the procedure and necessitate advanced surgical skills. Consequently, in addition to improving our understanding of pelvic pain symptoms, the ability to evaluate the sliding sign

preoperatively may help surgery planning, prompt colorectal surgeon support and allow proper informed consent to be obtained^{12,13}.

The aim of this systematic review and meta-analysis was to evaluate the diagnostic performance of the sliding sign assessed by TVS for detecting pouch of Douglas obliteration and bowel involvement in patients with suspected endometriosis, using laparoscopy as the reference standard.

METHODS

Protocol and registration

The systematic review and meta-analysis was performed according to preferred reporting items for systematic reviews and meta-analyses (PRISMA) and synthesizing evidence from diagnostic accuracy tests (SEDATe) guidelines^{14,15}. Inclusion and exclusion criteria and methods for data extraction and quality assessment were specified in advance. The protocol was registered with PROSPERO (CRD42021290671) and is available in Appendix S1. No amendment was made after registration. Institutional review board approval was waived owing to the nature and design of the study.

Data search

Studies published between January 2000 and October 2021 were identified by two authors (E.T. and C.M.) using PubMed/MEDLINE, Web of Science, CINAHL, The Cochrane Library, ClinicalTrials.gov and SCOPUS databases to identify potentially eligible studies. The search terms were as follows: ‘endometriosis’, ‘pouch of Douglas’, ‘bowel’, ‘recto-sigmoid’, ‘rectal’ and ‘sliding’. Language restriction in the search was set to English, French and Spanish.

Study selection and data collection

Three authors (P.M.E., P.F. and J.L.A.) screened the titles and abstracts of the identified studies to exclude articles that were not relevant to the topic under review, such as those focusing on magnetic resonance imaging instead of ultrasound as the diagnostic method, as well as reviews, letters and case reports. Full-text articles were obtained to identify eligible studies, and reviewers applied independently the following inclusion criteria: (1) prospective cohort design with at least 20 women included (sample size was set arbitrarily); (2) premenopausal women with a clinical suspicion of endometriosis included as participants; (3) TVS performed by an expert or trained gynecologist used as the index test; (4) laparoscopy (visual inspection with or without histological diagnosis) used as the reference standard; (5) sufficient data reported to construct a 2 × 2 table of diagnostic performance.

The ‘snowball strategy’ was used to identify relevant papers by reviewing the reference lists of the papers

selected for full-text review. In the case of missing relevant data, we sought to contact the authors to ask for more information.

For studies by the same research group, the time period of patient recruitment was examined. If we detected at least two studies from the same group with a clear overlap or a potential risk of overlap of patients, the most recent study was selected for analysis. The Patients, Intervention, Comparator, Outcomes and Setting (PICOS) criteria were used to describe the included studies (Table 1).

Diagnostic accuracy results and additional useful information about patients and procedures were retrieved from selected primary studies independently by three authors (P.M.E., P.F. and J.L.A.). Any disagreement regarding study selection and data collection was resolved by consensus among the three authors.

Risk of bias in individual studies

Quality assessment was conducted using the Quality Assessment of Diagnostic Accuracy Studies-2 (QUADAS-2) tool adapted to this systematic review. The QUADAS-2 tool includes four domains: patient selection, index test, reference standard and flow and timing. For each domain, the risk of bias and concerns regarding applicability were classified as high, low or unclear. The results of the quality assessment were used to evaluate the overall quality of included studies and investigate potential sources of heterogeneity. Three authors (P.M.E., P.F. and J.L.A.) studied independently the methodological quality using a standard form with quality assessment criteria and a flow diagram. Disagreements were resolved by discussion among the three authors until a consensus was reached.

The risk of bias in the patient-selection domain was determined based on the description of inclusion and

exclusion criteria of the studies. Patient selection was considered to be at high risk of bias if studies included a non-consecutive or non-random series of patients and performed inappropriate exclusions (for example, excluding patients with poor imaging).

The index-test domain was assessed based on the description of the technique of the sliding-sign assessment. The risk of bias was considered low when the sliding-sign technique was described in detail.

The reference-standard domain was evaluated based on the method used in the study to diagnose obliteration of the pouch of Douglas and/or bowel involvement. The correct reference standard was considered to be laparoscopic surgical and/or histological findings. A lack of blinding of surgeons to ultrasound findings was not considered to indicate a high risk of bias.

For the flow-and-timing domain, a description of the time elapsed from the index test to the reference-standard assessment was evaluated. An interval of more than 3 months was considered to indicate a high risk of bias.

Statistical analysis

Data on the diagnostic performance of the sliding-sign test performed during TVS were extracted or derived. A positive test (negative sliding sign) was defined as the absence of sliding between the anterior rectum and the serosa on the posterior surface of the cervix, posterior vaginal wall (for an anteverted uterus) or uterine fundus (for a retroverted uterus); the test was considered negative (positive sliding sign) when those structures were completely free of one another. The reference standard was obliteration of the pouch of Douglas and/or bowel involvement demonstrated on laparoscopy, either by visual inspection or histological confirmation.

Table 1 Characteristics of studies included in systematic review and meta-analysis, according to Patients, Intervention, Comparator, Outcomes and Setting (PICOS) criteria

Study	Country	Study design	Multi-center	Consecutive recruitment	Mean patient age (years)	Total (n)	PoD obliteration (n)	Bowel involvement (n)	Index test	TVS examiners (n)	Reference standard
Venkatesh (2020) ²⁴	India	Prosp	No	NS	NS	136	89	43	TVS	NS	LPS
Arion (2019) ²³	Canada	Prosp	No	NS	34.4	269	41	—	TVS	1	LPS
Reid (2018) ²²	Australia	Prosp	Yes	Yes	NS	376	—	76	TVS	> 2	LPS with/without histology
Menakaya (2016) ²¹	Australia	Prosp	Yes	Yes	32.1	199	51	—	TVS	> 2	LPS with/without histology
Piessens (2014) ²⁰	Australia	Prosp	No	NS	NS	85	34	25	TVS	1	LPS with/without histology
Leon (2014) ¹⁹	Chile	Prosp	No	No	32.6	51	24	13	TVS	1	LPS with/without histology
Hudelist (2013) ⁸	Austria	Prosp	No	NS	31.6	117	—	34	TVS	1	LPS with/without histology
Holland (2013) ¹⁸	UK	Prosp	Yes	Yes	35.0	198	54	9	TVS	2	LPS with histology

Only first author of each study is given. LPS, laparoscopy; NS, not stated; PoD, pouch of Douglas; Prosp, prospective; TVS, transvaginal ultrasound.

The primary outcome was pooled sensitivity, specificity, positive likelihood ratio (LR+), negative likelihood ratio (LR-) and diagnostic odds ratio (OR) of the sliding sign. The numbers of true-positive, true-negative, false-positive and false-negative cases were obtained from each included study. Post-test probabilities were calculated and plotted on Fagan nomograms, using the mean prevalence of pouch of Douglas obliteration and bowel involvement as the pretest probability.

The presence of heterogeneity for sensitivity and specificity was assessed graphically by drawing forest plots of sensitivity and specificity, and then using Cochran's Q and the I^2 statistic. A test for heterogeneity examines the null hypothesis that all studies are evaluating the same effect; $P < 0.1$ was considered to indicate heterogeneity. According to Higgins *et al.*¹⁶, I^2 values of 25%, 50% and 75% are considered to indicate low, moderate and high heterogeneity, respectively. In cases of moderate or high heterogeneity, meta-regression was used. The covariates analyzed in meta-regression were year of publication, sample size and prevalence of pouch of Douglas obliteration or bowel involvement.

Summary receiver-operating-characteristics (sROC) curves for each condition were plotted to illustrate the relationship between sensitivity and specificity, and the area under the curve was calculated.

Analyses were performed using Meta-analytical Integration of Diagnostic Accuracy Studies (MIDAS) and METANDI commands in STATA version 12 for Windows (Stata Corp., College Station, TX, USA); $P < 0.05$ was considered to indicate statistical significance.

The Grading of Recommendations Assessment, Development and Evaluation (GRADE) methodology was used to assess the quality of the retrieved evidence¹⁷. The online GRADE tool was adopted (<http://GRADEPro.org>, accessed in December 2021). The assessment was performed by three authors (J.L.A., S.G., M.A.P.) by consensus.

RESULTS

Search results

The electronic search provided a total of 334 citations. After removal of 162 duplicate records, 172 citations remained. Of these 172 citations, 123 were excluded after screening by title and abstract, including reviews ($n = 6$), case reports ($n = 3$), letters to the editor ($n = 1$), opinions ($n = 1$) and studies not related to the addressed topic ($n = 112$).

We reviewed the full text of the remaining 49 articles. Forty-three studies were excluded for the following reasons: study not relevant to the topic addressed ($n = 8$), data for 2×2 table not available ($n = 6$), retrospective study design ($n = 2$), surgery not used as the reference standard ($n = 4$), overlapping series ($n = 6$), no specific evaluation of the sliding sign ($n = 5$), review/opinion paper ($n = 7$) and reproducibility/learning curve rather than diagnostic type of study ($n = 5$) (Appendix S2). Two

additional relevant studies were found in the reference lists of the studies included in the review (snowball technique).

A flowchart summarizing study identification and selection is presented in Figure 1. There was no need to contact the authors, as all relevant data needed to perform the meta-analysis were available.

Characteristics of included studies

Eight studies published between October 2013 and January 2020 were included in the final analysis^{8,18–24}. Five studies analyzed the accuracy of the preoperative sliding sign for the prediction of both pouch of Douglas obliteration and bowel involvement in women with suspected deep infiltrating endometriosis^{18–21,24}. One study²³ analyzed the accuracy of the preoperative sliding sign for the prediction of pouch of Douglas obliteration only, and two studies^{8,22} analyzed the accuracy of the preoperative sliding sign for detecting bowel involvement only.

Two studies from the same research group were included^{21,22}. The study by Menakaya *et al.*²¹ provided

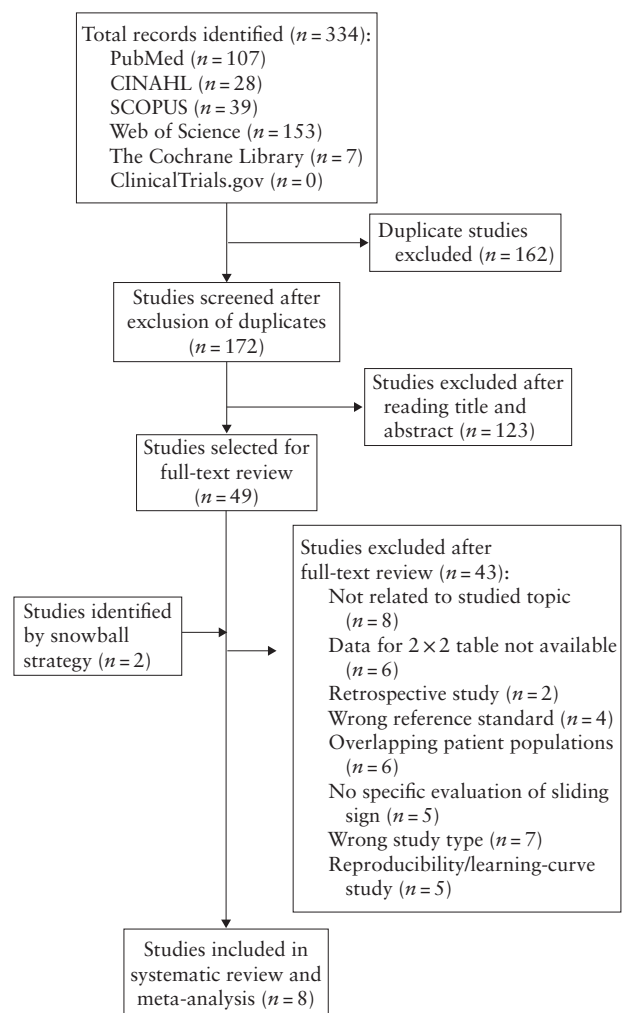


Figure 1 Flowchart summarizing inclusion in systematic review and meta-analysis of studies evaluating the diagnostic accuracy of the sliding sign on transvaginal ultrasound for pouch of Douglas obliteration and/or bowel involvement in women with suspected endometriosis.

data on diagnostic accuracy of the sliding sign to detect pouch of Douglas obliteration and bowel involvement, whereas the study by Reid *et al.*²² reported data on bowel involvement only. It was concluded that patients with bowel involvement in the study by Menakaya *et al.*²¹ were also included in the study by Reid *et al.*²². Therefore, data on bowel involvement from Menakaya *et al.* were excluded from the analysis. Thus, we analyzed data from six studies to assess the diagnostic performance of the sliding sign for detecting pouch of Douglas obliteration^{18–21,23,24} and from six studies to assess the diagnostic performance of the sliding sign for detecting bowel involvement^{8,18–20,22,24}.

Nine hundred and thirty-eight women were assessed for detecting obliteration of the pouch of Douglas. Of these 938 patients, 293 had pouch of Douglas obliteration on laparoscopy. The mean prevalence of pouch of Douglas obliteration was 37%, ranging from 15% to 65%.

Nine hundred and sixty-three women were assessed for detecting bowel involvement. Of these 963 patients, 200 had bowel involvement on laparoscopy. The mean prevalence of bowel involvement was 23%, ranging from 5% to 32%.

The mean age of patients was reported in five of the eight included studies^{8,18,19,21,23}. All studies were observational prospective studies. Three of them were multicenter studies^{18,21,22}. Only three studies specified that patient recruitment was consecutive^{18,21,22}; in one study, recruitment was non-consecutive¹⁹. Four studies did not specify the type of recruitment^{8,20,23,24}.

In all studies, TVS was performed by an expert or trained examiner. Most studies did not report whether the sonographer was blinded to the patient's medical history. In all studies, surgery was performed by an expert surgeon. One study reported that the surgeon was blinded to TVS findings¹⁸, and one reported that the surgeon was not blinded to TVS findings²². In the remaining studies, this information was not provided. The interval between TVS and surgery was not specified in four studies^{19,20,23,24}. In two studies^{21,22}, surgery was performed within 6 months after TVS, and in two other studies^{8,18}, the interval elapsed between TVS and

surgery was less than 3 months. Table 1 shows PICOS characteristics of the included studies.

Quality of included studies

Evaluation of the risk of bias and concerns regarding applicability of the selected studies is shown in Table 2.

Risk of bias

For the patient-selection domain, all studies included patients with clinical suspicion of endometriosis. Most studies were considered to be at low risk of bias for patient selection, as there was a clear explanation of inclusion and exclusion criteria. One study was considered to be high risk because it used non-consecutive recruitment and included patients with previous pelvic surgery¹⁹.

For the index-test domain, all studies were considered to be low risk because they provided an adequate description of the method for the sliding-sign assessment on TVS, as well as how it was interpreted. For the reference-standard domain, all but one studies were likely to classify correctly the target condition using the reference standard, and one study did not describe in detail the surgical procedure performed²⁴. For the flow-and-timing domain, the time elapsed between the index test and reference standard indicated a low risk of bias in two studies^{8,18} and a high risk in two studies^{21,22}. The risk for this domain was unclear in four studies^{19,20,23,24}.

Applicability

In terms of applicability, all studies were deemed to include patients who were relevant to the review question. For the index-test and reference-standard domains, all studies presented low concerns regarding applicability.

Sliding sign on TVS for detection of pouch of Douglas obliteration

Pooled sensitivity, specificity, LR+, LR– and OR of the sliding sign on TVS for detecting pouch of

Table 2 Quality assessment of studies included in systematic review and meta-analysis, according to Quality Assessment of Diagnostic Accuracy Studies-2 (QUADAS-2) tool

Study	Risk of bias				Applicability concerns		
	Patient selection	Index test	Reference standard	Flow and timing	Patient selection	Index test	Reference standard
Venkatesh (2020) ²⁴	Low	Low	Unclear	Unclear	Low	Low	Low
Arion (2019) ²³	Low	Low	Low	Unclear	Low	Low	Low
Reid (2018) ²²	Low	Low	Low	High	Low	Low	Low
Menakaya (2016) ²¹	Low	Low	Low	High	Low	Low	Low
Piessens (2014) ²⁰	Unclear	Low	Low	Unclear	Low	Low	Low
Leon (2014) ¹⁹	High	Low	Low	Unclear	Low	Low	Low
Hudelist (2013) ⁸	Low	Low	Low	Low	Low	Low	Low
Holland (2013) ¹⁸	Low	Low	Low	Low	Low	Low	Low

Only first author of each study is given.

Douglas obliteration were 88% (95% CI, 81–93%), 94% (95% CI, 91–96%), 15.3 (95% CI, 10.2–22.9), 0.12 (95% CI, 0.07–0.21) and 123 (95% CI, 62–244), respectively. Heterogeneity was moderate for sensitivity (Cochran’s Q, 16.20; $P=0.01$, $I^2=69.1\%$) and low for specificity (Cochran’s Q, 8.96; $P=0.11$, $I^2=44.2\%$) (Figure 2a). As heterogeneity was moderate,

metaregression was performed. We observed that the differences in the prevalence of pouch of Douglas obliteration across studies could explain this heterogeneity ($P < 0.01$).

The area under the sROC curve was 0.97 (95% CI, 0.95–0.98) (Figure 3a). As shown in the Fagan nomogram (Figure 4a), a positive test on TVS (negative sliding sign)

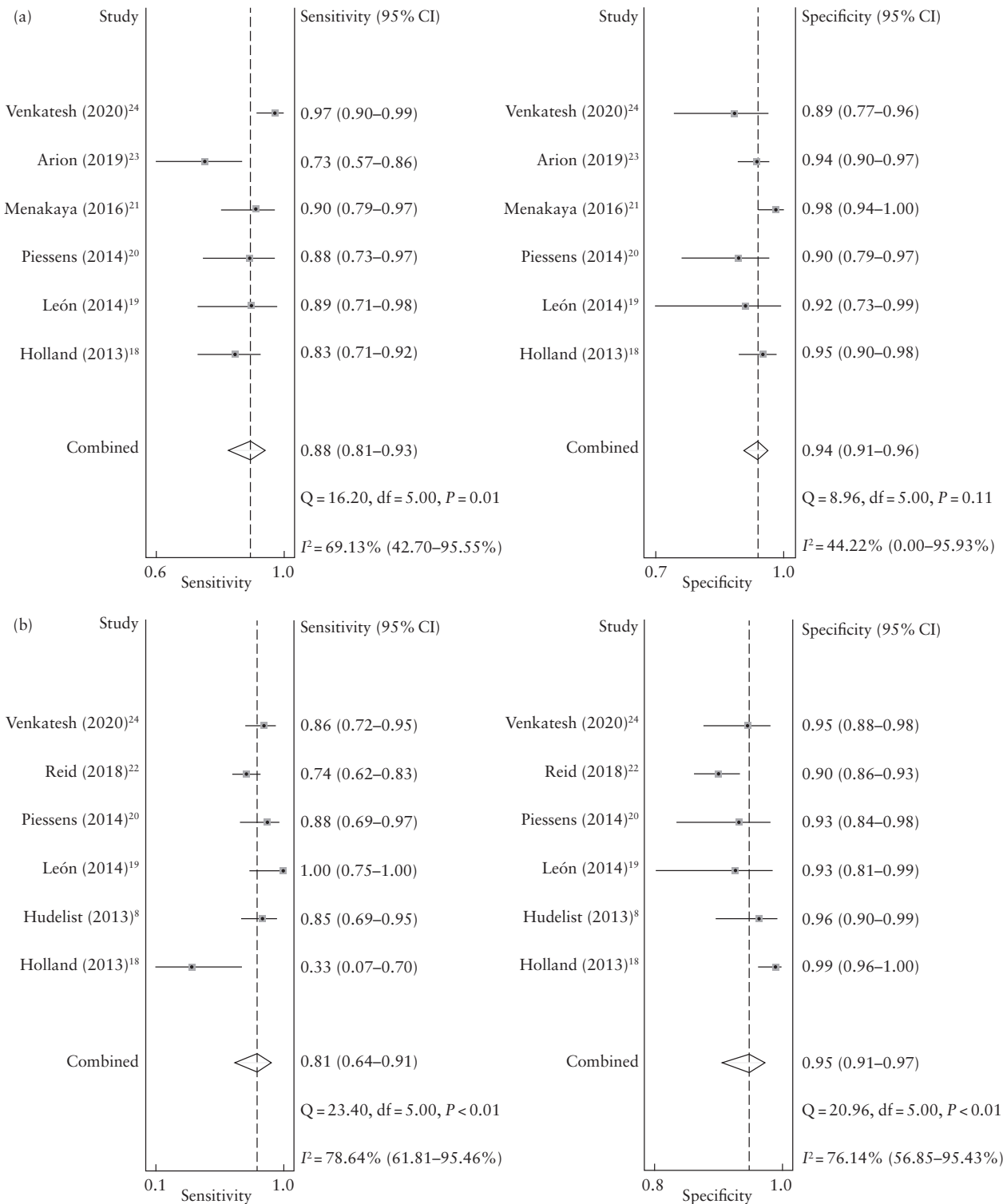


Figure 2 Forest plots showing pooled sensitivity and specificity of the sliding sign on transvaginal ultrasound in the detection of pouch of Douglas obliteration (a) and bowel involvement (b) in women with suspected endometriosis. Only first author of each study is given.

in women with suspected deep endometriosis significantly increased the pretest probability of pouch of Douglas obliteration on laparoscopy, from 37% to 90%, while a negative test (positive sliding sign) significantly decreased the pretest probability, from 37% to 7%. No publication bias was observed ($P=0.64$).

Sliding sign on TVS for detection of bowel involvement

Pooled sensitivity, specificity, LR+, LR- and OR of the sliding sign on TVS for detecting bowel involvement were 81% (95% CI, 64–91%), 95% (95% CI, 91–97%), 16.0 (95% CI, 9.0–28.6), 0.20 (95% CI, 0.10–0.40) and

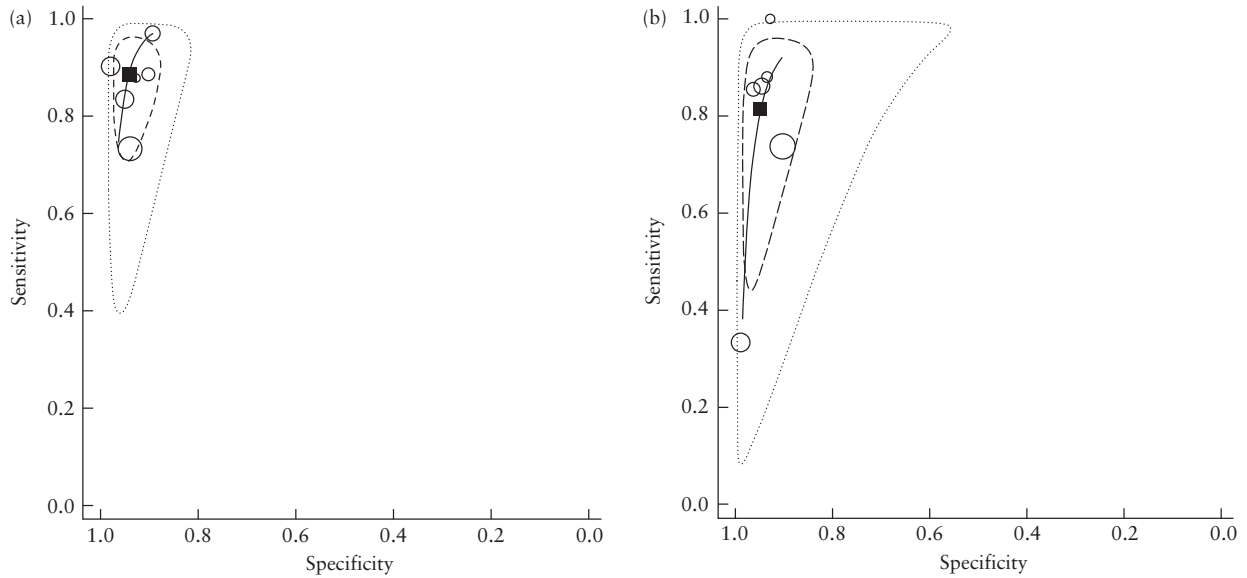


Figure 3 Summary receiver-operating-characteristics curves (—) showing performance of the sliding sign on transvaginal ultrasound in the detection of pouch of Douglas obliteration (a) and bowel involvement (b) in women with suspected endometriosis. ○, Study estimate; □, summary point; - - - -, 95% confidence region; ·····, 95% prediction region.

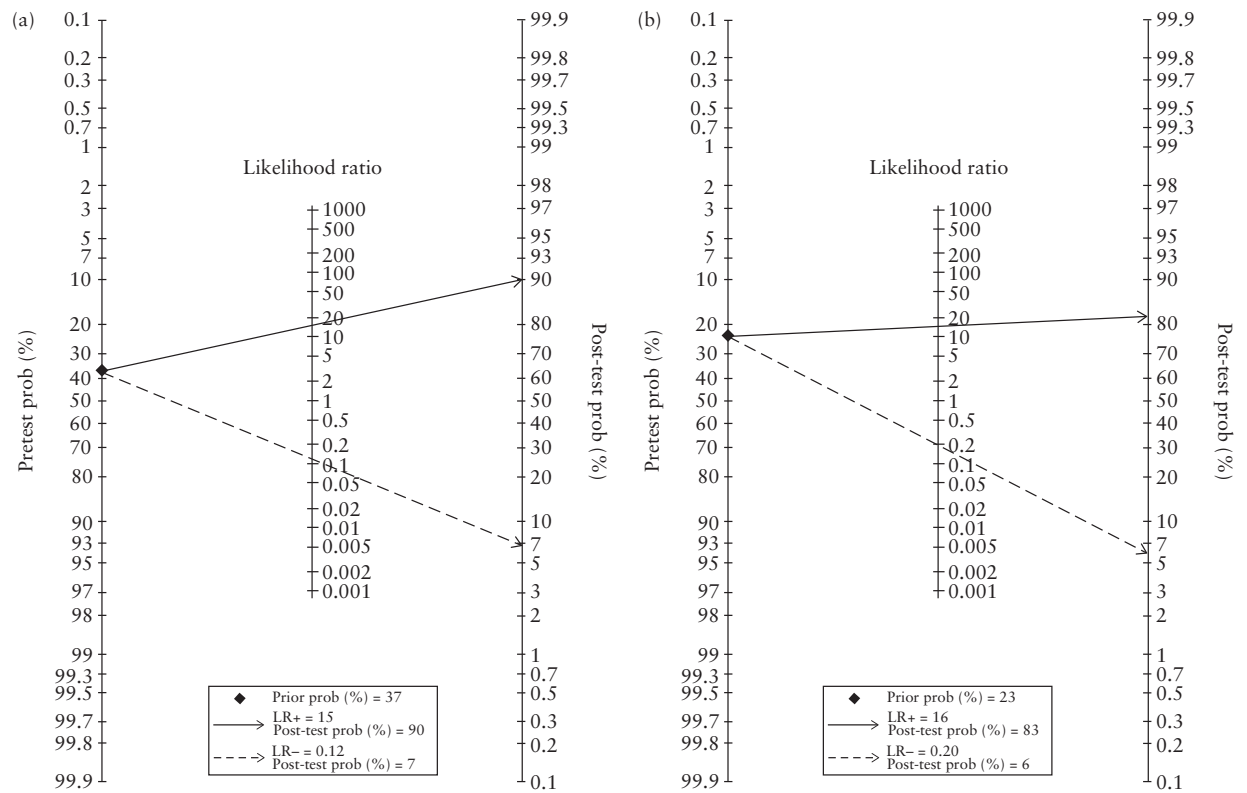


Figure 4 Fagan nomograms for detecting pouch of Douglas obliteration (a) and bowel involvement (b) based on negative (—→) and positive (—→) sliding sign on transvaginal ultrasound in women with suspected endometriosis. LR-, negative likelihood ratio; LR+, positive likelihood ratio; prob, probability.

Table 3 Grading of Recommendations Assessment, Development and Evaluation (GRADE) assessment of the quality of evidence regarding the diagnostic accuracy of the sliding sign on transvaginal ultrasound for pouch of Douglas obliteration in women with suspected endometriosis

Outcome	Studies (n)/ patients (n)	Study design	Factors that may decrease CoE				Publication bias	Effect per 1000 patients tested (95% CI) (n)*	Test accuracy CoE
			Risk of bias	Indirectness	Inconsistency	Imprecision			
True positive	Six studies/ 293 patients	Cohort diagnostic accuracy study	Not serious	Not serious	Not serious	Not serious	None	326 (300–344)	⊕⊕⊕⊕ High
False negative								44 (26–70)	
True negative	Six studies/ 645 patients	Cohort diagnostic accuracy study	Not serious	Not serious	Not serious	Not serious	None	592 (573–605)	⊕⊕⊕⊕ High
False positive								38 (25–57)	

*Pretest probability of 37%. CoE, class of evidence.

Table 4 Grading of Recommendations Assessment, Development and Evaluation (GRADE) assessment of the quality of evidence regarding the diagnostic accuracy of the sliding sign on transvaginal ultrasound for bowel involvement in women with suspected endometriosis

Outcome	Studies (n)/ patients (n)	Study design	Factors that may decrease CoE				Publication bias	Effect per 1000 patients tested (95% CI) (n)*	Test accuracy CoE
			Risk of bias	Indirectness	Inconsistency	Imprecision			
True positive	Six studies/ 200 patients	Cohort diagnostic accuracy study	Not serious	Not serious	Not serious	Not serious	None	186 (147–209)	⊕⊕⊕⊕ High
False negative								44 (21–83)	
True negative	Six studies/ 763 patients	Cohort diagnostic accuracy study	Not serious	Not serious	Not serious	Not serious	None	731 (701–747)	⊕⊕⊕⊕ High
False positive								39 (23–69)	

*Pretest probability of 23%. CoE, class of evidence.

81 (95% CI, 34–191), respectively. Heterogeneity was high for both sensitivity (Cochran's Q, 23.40; $P < 0.01$, $I^2 = 78.6\%$) and specificity (Cochran's Q, 20.96; $P < 0.01$, $I^2 = 76.1\%$) (Figure 2b). As heterogeneity was high, meta-regression was performed. We observed that the differences in the prevalence of bowel involvement across studies could explain this heterogeneity ($P < 0.01$).

The area under the sROC curve was 0.96 (95% CI, 0.94–0.98) (Figure 3b). As shown in the Fagan nomogram (Figure 4b), a positive test on TVS (negative sliding sign) in women with suspected deep endometriosis significantly increased the pretest probability of bowel involvement on laparoscopy, from 23% to 83%, while a negative test (positive sliding sign) significantly decreased the pretest probability, from 23% to 6%. No publication bias was observed ($P = 0.14$).

GRADE assessment and recommendation

Regarding GRADE assessment, evidence of high quality showed that the sliding sign as assessed by TVS has a

high accuracy for detecting pouch of Douglas obliteration and bowel involvement in women with endometriosis (Tables 3 and 4). This assessment should be recommended for all women evaluated for this clinical entity.

DISCUSSION

Summary of evidence

In this meta-analysis, we observed that the diagnostic performance of the TVS sliding sign for detecting pouch of Douglas obliteration and bowel involvement in women with suspected endometriosis was high, with pooled sensitivity of 88% and 81% and pooled specificity of 94% and 95%, respectively.

The studies included had mostly low risk of bias and low concerns regarding applicability. However, it should be borne in mind for the flow-and-timing domain that the time elapsed from TVS to laparoscopy was not reported in four studies. We cannot assume that the time elapsed between the two procedures was long; however, we believe that, if the time elapsed was long, it could be a potential confounding factor because the condition of the pelvis could become worse.

Interpretation of results

Our findings demonstrate that the sliding sign is an excellent ultrasound sign for detecting pouch of Douglas obliteration and bowel involvement in women undergoing surgery for suspected endometriosis. The heterogeneity observed across the studies analyzing pouch of Douglas obliteration was low for specificity and moderate for sensitivity, demonstrating comparability of the studies. However, the heterogeneity of the studies assessing bowel involvement was high. Therefore, in the latter case, our findings should be interpreted with caution.

These findings might be clinically relevant, as pouch of Douglas obliteration may increase the duration and complexity of surgery²⁵. Having this information prior to surgery may be helpful to surgeons, as it may influence the choice of surgical technique, lead to involvement of a multidisciplinary surgical team and allow referral to the most appropriate practice²⁶. Additionally, a negative sliding sign alone may be useful for identifying women with clinical suspicion of deep endometriosis who require further evaluation, for example, an examination by an expert sonologist to assess for the presence of classic signs of rectal infiltration. Furthermore, a negative sliding sign may be associated with sigmoid involvement. This may also constitute a reason for referring the patient for expert examination. However, five of the six studies on bowel involvement included in this meta-analysis did not provide separate information on rectal and sigmoid involvement; therefore, a subgroup analysis could not be performed.

Some studies have shown that assessment of the sliding sign may have a short learning curve and be reproducible among expert examiners^{4,27–29}. However, it is important to bear in mind that diagnostic performance depends on expertise and that not all trainees may reach competence^{28–30}. Reproducibility should be tested in larger prospective studies.

We should also consider the fact that a negative sliding sign may be produced by inflammatory changes, for example due to pelvic surgery or pelvic inflammatory disease. This might be a confounding factor. In patients with such a medical history, it would be difficult to ascertain whether a negative sliding sign is related to endometriosis or to postsurgical/disease-related inflammatory processes.

Strengths and limitations

Some limitations of this meta-analysis should be considered. We believe that the main limitation is the small number of studies and patients included. Additionally, the reported prevalence of pouch of Douglas obliteration on laparoscopy may vary depending on the surgeon's skills. Most of the included studies did not provide details regarding this aspect, and we should not assume that inspection of the abdominal cavity was made by properly trained experienced surgeons. In fact, one study did not describe at all the surgical procedures performed²⁴. However, we do not consider that this had a significant effect on the results of the quantitative synthesis.

The strengths of our study are that, to the best of our knowledge, it is the first meta-analysis to analyze specifically the performance of the TVS sliding sign in detecting bowel involvement and that it provides up-to-date evidence on the diagnostic performance of this sign for obliteration of the pouch of Douglas in women with clinical suspicion of endometriosis.

Two previous meta-analyses have assessed the diagnostic performance of TVS for detecting pouch of Douglas obliteration^{31,32}. However, neither of them assessed specifically the sliding sign for detecting bowel involvement. Nisenblat *et al.*³¹ assessed six studies that evaluated the diagnostic performance of TVS for detecting pouch of Douglas obliteration. Two of those studies have been included in our meta-analysis^{19,20}, but four of them were not^{9,33–35}. We did not include these four studies because they reported data from series that overlapped with more recent studies from the same group^{9,35} or did not report specifically on the sliding sign as a marker for diagnosing pouch of Douglas obliteration^{33,34}. The pooled sensitivity and specificity reported by Nisenblat *et al.* (83% and 97%, respectively) were similar to those in our study.

Noventa *et al.*³² reported data from eight studies that assessed the role of TVS in detecting pouch of Douglas obliteration. Two of these studies have been included in our meta-analysis^{18,19}. Six studies were excluded for one of the following reasons: overlapping data with more recent studies from the same group^{9,34}, not describing the sliding sign^{36,37}, data for constructing 2 × 2 table could not be extracted³⁸ or the study focused on transrectal ultrasound³⁹. The pooled sensitivity and specificity reported by Noventa *et al.* were 80% and 95%, respectively.

Our meta-analysis reports data from more recent studies and represents a larger series.

Conclusions

In conclusion, the TVS sliding sign seems to be an accurate method for the diagnosis of pouch of Douglas obliteration and bowel involvement in women with a clinical suspicion of pelvic endometriosis who undergo surgery when expert examiners perform the ultrasound examination. It remains to be seen whether the TVS sliding sign test performs equally well and is reproducible in the hands of less experienced examiners. The findings of this meta-analysis confirm the fundamental role of TVS as a diagnostic tool in women with suspected endometriosis, suggested by previous studies^{40–42}.


REFERENCES

- Piessens S, Edwards A. Sonographic Evaluation for Endometriosis in Routine Pelvic Ultrasound. *J Minim Invasive Gynecol* 2020; 27: 265–266.
- Ghai V, Jan H, Shakir F, Haines P, Kent A. Diagnostic delay for superficial and deep endometriosis in the United Kingdom. *J Obstet Gynaecol* 2020; 40: 83–89.
- Piketty M, Chopin N, Dousset B, Millischer-Bellaische AE, Roseau G, Leconte M, Borghese B, Chapron C. Preoperative work-up for patients with deeply infiltrating endometriosis: transvaginal ultrasonography must definitely be the first-line imaging examination. *Hum Reprod* 2009; 24: 602–607.

4. Holland TK, Hoo WL, Mavrelou D, Saridogan E, Cutner A, Jurkovic D. Reproducibility of assessment of severity of pelvic endometriosis using transvaginal ultrasound. *Ultrasound Obstet Gynecol* 2013; **41**: 210–215.
5. Bean E, Chaggar P, Thanatsis N, Dooley W, Bottomley C, Jurkovic D. Intra- and interobserver reproducibility of pelvic ultrasound for the detection and measurement of endometriotic lesions. *Hum Reprod Open* 2020; **2020**: hoaa001.
6. Leonardi M, Espada M, Choi S, Chou D, Chang T, Smith C, Rowan K, Condous G. Transvaginal Ultrasound Can Accurately Predict the American Society of Reproductive Medicine Stage of Endometriosis Assigned at Laparoscopy. *J Minim Invasive Gynecol* 2020; **27**: 1581–1587.e1.
7. Guerriero S, Condous G, van den Bosch T, Valentin L, Leone FP, Van Schoubroeck D, Exacoustos C, Installé AJF, Martins WP, Abrao MS, Hudelist G, Bazot M, Alcázar JL, Gonçalves MO, Pascual MA, Ajossa S, Savelli L, Dunham R, Reid S, Menakaya U, Bourne T, Ferrero S, Leon M, Bignardi T, Holland T, Jurkovic D, Benacerraf B, Osuga Y, Somigliana E, Timmerman D. Systematic approach to sonographic evaluation of the pelvis in women with suspected endometriosis, including terms, definitions and measurements: a consensus opinion from the International Deep Endometriosis Analysis (IDEA) group. *Ultrasound Obstet Gynecol* 2016; **48**: 318–332.
8. Hudelist G, Fritzer N, Staettner S, Tammaa A, Tinelli A, Sparic R, Keckstein J. Uterine sliding sign: a simple sonographic predictor for presence of deep infiltrating endometriosis of the rectum. *Ultrasound Obstet Gynecol* 2013; **41**: 692–695.
9. Reid S, Lu C, Casikar I, Reid G, Abbott J, Cario G, Chou D, Kowalski D, Cooper M, Condous G. Prediction of pouch of Douglas obliteration in women with suspected endometriosis using a new real-time dynamic transvaginal ultrasound technique: the sliding sign. *Ultrasound Obstet Gynecol* 2013; **41**: 685–691.
10. Khong SY, Bignardi T, Luscombe G, Lam A. Is pouch of Douglas obliteration a marker of bowel endometriosis? *J Minim Invasive Gynecol* 2011; **18**: 333–337.
11. Bendifallah S, Puchar A, Vesale E, Moawad G, Daraï E, Roman H. Surgical Outcomes after Colorectal Surgery for Endometriosis: A Systematic Review and Meta-analysis. *J Minim Invasive Gynecol* 2021; **28**: 453–466.
12. Working group of ESGE, ESHRE, and WES; Keckstein J, Becker CM, Canis M, Feki A, Grimbizis GF, Hummelshoj L, Nisolle M, Roman H, Saridogan E, Tanos V, Tomassetti C, Ulrich UA, Vermeulen N, De Wilde RL. Recommendations for the surgical treatment of endometriosis. Part 2: deep endometriosis. *Hum Reprod Open* 2020; **2020**: hoaa002.
13. Malzoni M, Casarella L, Coppola M, Falcone F, Iuzzolino D, Rasile M, Di Giovanni A. Preoperative Ultrasound Indications Determine Excision Technique for Bowel Surgery for Deep Infiltrating Endometriosis: A Single, High-Volume Center. *J Minim Invasive Gynecol* 2020; **27**: 1141–1147.
14. Moher D, Liberati A, Tetzlaff J, Altman DG; PRISMA Group. Preferred reporting items for systematic reviews and meta-analysis: the PRISMA statement. *BMJ* 2009; **339**: b2535.
15. Sotiriadis A, Papatheodorou SI, Martins WP. Synthesizing Evidence from Diagnostic Accuracy Tests: the SEDATE guideline. *Ultrasound Obstet Gynecol* 2016; **47**: 386–395.
16. Higgins JPT, Thompson SG, Deeks JJ, Altman DG. Measuring inconsistency in meta-analyses. *BMJ* 2003; **327**: 557–560.
17. Schünemann HJ, Oxman AD, Brozek J, Glasziou P, Bossuyt P, Chang S, Muti P, Jaeschke R, Guyatt GH. GRADE: assessing the quality of evidence for diagnostic recommendations. *Evid Based Med* 2008; **13**: 162–163.
18. Holland TK, Cutner A, Saridogan E, Mavrelou D, Pateman K, Jurkovic D. Ultrasound mapping of pelvic endometriosis: does the location and number of lesions affect the diagnostic accuracy? A multicentre diagnostic accuracy study. *BMC Womens Health* 2013; **13**: 43.
19. León M, Vaccaro H, Alcázar JL, Martínez J, Gutierrez J, Amor F, Iturra A, Sovino H. Extended transvaginal sonography in deep infiltrating endometriosis: use of bowel preparation and an acoustic window with intravaginal gel: preliminary results. *J Ultrasound Med* 2014; **33**: 315–321.
20. Piessens S, Healey M, Maher P, Tsaltas J, Rombauts L. Can anyone screen for deep infiltrating endometriosis with transvaginal ultrasound? *Aust N Z J Obstet Gynaecol* 2014; **54**: 462–468.
21. Menakaya U, Reid S, Lu C, Gerges B, Infante F, Condous G. Performance of ultrasound-based endometriosis staging system (UBESS) for predicting level of complexity of laparoscopic surgery for endometriosis. *Ultrasound Obstet Gynecol* 2016; **48**: 786–795.
22. Reid S, Espada M, Lu C, Condous G. To determine the optimal ultrasonographic screening method for rectal/rectosigmoid deep endometriosis: Ultrasound “sliding sign”, transvaginal ultrasound direct visualization or both? *Acta Obstet Gynecol Scand* 2018; **97**: 1287–1292.
23. Arion K, Aksoy T, Allaire C, Noga H, Williams C, Bedaiwy MA, Yong PJ. Prediction of pouch of Douglas obliteration: point-of-care ultrasound versus pelvic examination. *J Minim Invasive Gynecol* 2019; **26**: 928–934.
24. Venkatesh S, Anjali M, Vasudeva A, Kumar P. Sliding Sign and Gel Sonovaginography: A Sneak Peek Prior to Laparoscopy in Patients with Endometriosis. *J Hum Reprod Sci* 2020; **13**: 26–30.
25. Leonardi M, Gibbons T, Armour M, Wang R, Glanville E, Hodgson R, Cave AE, Ong J, Tong YYF, Jacobson TZ, Mol BW, Johnson NP, Condous G. When to Do Surgery and When Not to Do Surgery for Endometriosis: A Systematic Review and Meta-analysis. *J Minim Invasive Gynecol* 2020; **27**: 390–407.e3.
26. Espada M, Leonardi M, Aas-Eng K, Lu C, Reyftmann L, Tetstall E, Slusarczyk B, Ludlow J, Hudelist G, Reid S, Condous G. A Multicenter International Temporal and External Validation Study of the Ultrasound-based Endometriosis Staging System. *J Minim Invasive Gynecol* 2021; **28**: 57–62.
27. Tammaa A, Fritzer N, Strunk G, Krell A, Salzer H, Hudelist G. Learning curve for the detection of pouch of Douglas obliteration and deep infiltrating endometriosis of the rectum. *Hum Reprod* 2014; **29**: 1199–1204.
28. Menakaya U, Infante F, Lu C, Phua C, Model A, Messyne F, Brainwood M, Reid S, Condous G. Interpreting the real-time dynamic ‘sliding sign’ and predicting pouch of Douglas obliteration: an interobserver, intraobserver, diagnostic-accuracy and learning-curve study. *Ultrasound Obstet Gynecol* 2016; **48**: 113–120.
29. Leonardi M, Ong J, Espada M, Stamatoopoulos N, Georgousopoulou E, Hudelist G, Condous G. One-Size-Fits-All Approach Does Not Work for Gynecology Trainees Learning Endometriosis Ultrasound Skills. *J Ultrasound Med* 2020; **39**: 2295–2303.
30. Reid S, Lu C, Casikar I, Mein B, Magotti R, Ludlow J, Benzie R, Condous G. The prediction of pouch of Douglas obliteration using offline analysis of the transvaginal ultrasound ‘sliding sign’ technique: inter- and intra-observer reproducibility. *Hum Reprod* 2013; **28**: 1237–1246.
31. Nisenblat V, Bossuyt PM, Farquhar C, Johnson N, Hull ML. Imaging modalities for the non-invasive diagnosis of endometriosis. *Cochrane Database Syst Rev* 2016; **2**: CD009591.
32. Noventa M, Saccardi C, Litta P, Vitagliano A, D’Antona D, Abdulrahim B, Duncan A, Alexander-Sefre F, Aldrich CJ, Quaranta M, Gizzo S. Ultrasound techniques in the diagnosis of deep pelvic endometriosis: algorithm based on a systematic review and meta-analysis. *Fertil Steril* 2015; **104**: 366–383.e2.
33. Holland TK, Yazbek J, Cutner A, Saridogan E, Hoo WL, Jurkovic D. Value of transvaginal ultrasound in assessing severity of pelvic endometriosis. *Ultrasound Obstet Gynecol* 2010; **36**: 241–248.
34. Hudelist G, Ballard K, English J, Wright J, Banerjee S, Mastoroudes H, Thomas A, Singer CF, Keckstein J. Transvaginal sonography vs clinical examination in the preoperative diagnosis of deep infiltrating endometriosis. *Ultrasound Obstet Gynecol* 2011; **37**: 480–487.
35. Reid S, Lu C, Hardy N, Casikar I, Reid G, Cario G, Chou D, Almashat D, Condous G. Office gel sonovaginography for the prediction of posterior deep infiltrating endometriosis: a multicenter prospective observational study. *Ultrasound Obstet Gynecol* 2014; **44**: 710–718.
36. Abrao MS, Gonçalves MO, Dias JA Jr, Podgaec S, Chamie LP, Blasbalg R. Comparison between clinical examination, transvaginal sonography and magnetic resonance imaging for the diagnosis of deep endometriosis. *Hum Reprod* 2007; **22**: 3092–3097.
37. Carbognin G, Girardi V, Pinali L, Raffaelli R, Bergamini V, Pozzi Mucelli R. Assessment of pelvic endometriosis: correlation of US and MRI with laparoscopic findings. *Radiol Med* 2006; **111**: 687–701.
38. Fratelli N, Scioscia M, Bassi E, Musola M, Minelli L, Trivella G. Transvaginal sonography for preoperative assessment of deep endometriosis. *J Clin Ultrasound* 2013; **41**: 69–75.
39. Bazot M, Detchev R, Cortez A, Amouyal P, Uzan S, Daraï E. Transvaginal sonography and rectal endoscopic sonography for the assessment of pelvic endometriosis: a preliminary comparison. *Hum Reprod* 2003; **18**: 1686–1692.
40. Guerriero S, Ajossa S, Minguez JA, Jurado M, Mais V, Melis GB, Alcázar JL. Accuracy of transvaginal ultrasound for diagnosis of deep endometriosis in uterosacral ligaments, rectovaginal septum, vagina and bladder: systematic review and meta-analysis. *Ultrasound Obstet Gynecol* 2015; **46**: 534–545.
41. Guerriero S, Ajossa S, Orozco R, Perniciano M, Jurado M, Melis GB, Alcázar JL. Accuracy of transvaginal ultrasound for diagnosis of deep endometriosis in the rectosigmoid: systematic review and meta-analysis. *Ultrasound Obstet Gynecol* 2016; **47**: 281–289.
42. Guerriero S, Martínez L, Gomez I, Pascual MA, Ajossa S, Pagliuca M, Alcázar JL. Diagnostic accuracy of transvaginal sonography for detecting parametrial involvement in women with deep endometriosis: systematic review and meta-analysis. *Ultrasound Obstet Gynecol* 2021; **58**: 669–676.

SUPPORTING INFORMATION ON THE INTERNET

The following supporting information may be found in the online version of this article:

 **Appendix S1** Protocol for the systematic review and meta-analysis

Appendix S2 Studies excluded after full-text review



Precisión diagnóstica del signo deslizante para detectar la obliteración del fondo de saco de Douglas y la afectación intestinal en mujeres con sospecha de endometriosis: revisión sistemática y metaanálisis

RESUMEN

Objetivo. El objetivo de esta revisión sistemática y metaanálisis fue evaluar la precisión diagnóstica del signo deslizante en la ecografía transvaginal (ETV) para detectar la obliteración del fondo de saco de Douglas y la afectación intestinal en pacientes con sospecha de endometriosis, utilizando la laparoscopia como estándar de referencia.

Métodos. Se realizó una búsqueda de estudios que hubieran evaluado la función del signo deslizante en la valoración de la obliteración del fondo de saco de Douglas y/o la afectación intestinal utilizando la laparoscopia como estándar de referencia, publicados desde enero de 2000 hasta octubre de 2021 en las bases de datos PubMed/MEDLINE, Web of Science, CINAHL, The Cochrane Library, ClinicalTrials.gov y SCOPUS. Para evaluar la calidad de los estudios se utilizó la herramienta de Evaluación de Calidad de los Estudios de Precisión Diagnóstica-2 (QUADAS-2, por sus siglas en inglés) Los análisis se realizaron mediante los comandos MIDAS y METANDI de STATA.

Resultados. Se identificaron un total de 334 citas. En el análisis se incluyeron ocho estudios, lo que dio como resultado 938 y 963 pacientes disponibles para el análisis de la precisión diagnóstica del signo deslizante para la obliteración del fondo de saco de Douglas y la afectación intestinal, respectivamente. La prevalencia media de la obliteración del fondo de saco de Douglas fue del 37% y la prevalencia media de la afectación intestinal fue del 23%. La estimación combinada de la sensibilidad, especificidad, cociente de verosimilitud positivo, cociente de verosimilitud negativo y razón de momios del diagnóstico del signo deslizante en la ETV para detectar la obliteración del fondo de saco de Douglas fue del 88% (IC 95%, 81–93%), 94% (IC 95%, 91–96%), 15,3 (IC 95%, 10,2–22,9), 0,12 (IC 95%, 0,07–0,21) y 123 (IC 95%, 62–244), respectivamente. La heterogeneidad fue moderada en cuanto a la sensibilidad y baja en cuanto a la especificidad para detectar la obliteración del fondo de saco de Douglas. La estimación combinada de la sensibilidad, especificidad, cociente de verosimilitud positivo, cociente de verosimilitud negativo y razón de momios del diagnóstico del signo deslizante en la ETV para detectar la afectación intestinal fue del 81% (IC 95%, 64–91%), 95% (IC 95%, 91–97%), 16,0 (IC 95%, 9,0–28,6), 0,20 (IC 95%, 0,10–0,40) y 81 (IC 95%, 34–191), respectivamente. La heterogeneidad del metaanálisis de la precisión diagnóstica de la afectación intestinal fue alta.

Conclusiones. El signo deslizante en la ETV tiene un buen rendimiento diagnóstico para predecir la obliteración del fondo de saco de Douglas y la afectación intestinal en mujeres con sospecha de endometriosis.

滑动征检测疑似子宫内位症女性道格拉斯小袋闭塞和肠道受累的诊断准确性：系统评价和荟萃分析

摘要

目的本系统评价和荟萃分析的目的在于以腹腔镜作为参考标准用于评估经阴道超声 (TVS) 滑动征在检测疑似道格拉斯小袋闭塞和肠道受累并伴有子宫内位患者中的诊断准确性。

方法使用2000年1月至2021年10月出版的《腹腔镜参考标准》，在PubMed/MEDLINE、Web of Science、CINAHL、Cochrane图书馆、ClinicalTrials.gov和SCOPUS数据库中搜索滑动征在评估道格拉斯小袋闭塞和/或肠道受累中的作用的研究。使用诊断准确性研究的质量评价工具-2 (Quality Assessment of Diagnostic Accuracy Studies-2) 来评估这些研究的质量。在STATA中使用MIDAS和METANDI命令进行分析。

结果共识别出334次引用。共有八项研究被纳入分析，分别有938名和963名患者可用于分析滑动征对道格拉斯小袋闭塞和肠道受累的诊断准确性。道格拉斯小袋闭塞的平均患病率为37%，肠道受累的平均患病率为23%。经阴道超声 (TVS) 滑动征检测道格拉斯小袋闭塞的综合估计敏感性、特异性、阳性似然比、阴性似然比和诊断优势比分别为88% (95% CI, 81–93%)、94% (95% CI, 91–96%)、15.3 (95% CI, 10.2–22.9)、0.12 (95% CI, 0.07–0.21) 和123 (95% CI, 62–244)。检测道格拉斯小袋闭塞敏感性中的异质性为中等，特异性低。经阴道超声 (TVS) 滑动征检测肠道受累的汇总估计敏感性、特异性、阳性似然比、阴性似然比和诊断优势比分别为81% (95% CI, 64–91%)、95% (95% CI, 91–97%)、16.0 (95% CI, 9.0–28.6)、0.20 (95% CI, 0.10–0.40) 和81 (95% CI, 34–191)。肠道受累诊断准确性的荟萃分析异质性很高。

结论经阴道超声 (TVS) 滑动征对预测疑似患有道格拉斯小袋闭塞和肠道受累的子宫内位女性具有良好的诊断性能。