

Case Report

# Pursuing an Elusive Prostate Carcinoma: A Case Report Involving Multiparametric MR and CT-Guided Biopsy

Dana O. Olson<sup>a</sup> Joseph M. Baisden<sup>b</sup> David L. Groten<sup>a</sup> Can Talug<sup>c</sup>

<sup>a</sup>Professional Imaging, Princeton, WV, USA; <sup>b</sup>21st Century Oncology of West Virginia, Princeton, WV, USA; <sup>c</sup>Mercer Medical Group Urology, Princeton, WV, USA

## Keywords

Prostate adenocarcinoma · mpMRI · IMRT · IGRT · CT-guided biopsy

## Abstract

Prostate cancer is usually diagnosed when elevated PSA levels lead to a TRUS biopsy. We present a case in which there were several negative biopsies and a rising PSA. This led to a multiparametric MR (mpMRI) which demonstrated a large mass which originated in the anterior transition zone and had extended through the anterior fibromuscular stroma and prostate capsule with a significant extra-prostatic component. The mass was successfully approached anteriorly with a CT-guided biopsy. The patient was subsequently successfully treated with radiotherapy utilizing MR in the planning process. This case report summarizes the utility of mpMRI in this clinical setting. For patients with high suspicion of prostate malignancy despite prior negative biopsies, it can identify tumor in locations not amenable to TRUS biopsy. It also is critical for accurate radiation treatment planning, allowing for increased confidence in tumor targeting as well as sparing sensitive normal tissue.

© 2019 The Author(s)  
Published by S. Karger AG, Basel

## Case Presentation

This case involves a 68-year old male with elevated PSA who had previously had 5 negative biopsies over a 6-year period (2007 through 2013) during which the PSA had continued to rise from 7.1 to 59.8. He remained asymptomatic during this period. The patient was evaluated by a new urologist and mpMRI was ordered. This demonstrated a 3 cm mass in the anterior fibromuscular stroma and anterior aspect of the transition zone, to the right of midline. The mass involved the base and mid portions of the prostate. The apex was not involved. The mass demonstrated homogeneous T2 hypointensity (Fig. 1a) and had restricted diffusion with hyperintensity on high b-value diffusion ( $b = 1,000 \text{ s/mm}^2$ ) (Fig. 1b). Average ADC value within the mass was  $0.6 (10^{-3}) \text{ mm}^2/\text{s}$  or  $600 \text{ mm}^2/\text{s}$ , consistent with high-grade malignancy [1]. The mass also demonstrated early enhancement and washout on dynamic contrast enhancement imaging (Fig. 1c). There was extra-prostatic extension. The peripheral zone and seminal vesicles had normal appearances. This resulted in a score (transition zone) of PI-RADS 5 – Very high (clinically significant cancer is highly likely to be present) [2].

It was determined to biopsy the mass via an anterior approach utilizing CT (Fig. 2). The biopsy needle was advanced along a trajectory above the symphysis and below the bladder under CT guidance. 4 core biopsies were obtained. Pathology demonstrated prostate adenocarcinoma, Gleason grade  $5 + 4 = 9$ , involving greater than 95% of the needle core tissue, and measuring at least 15 mm in aggregate length. No normal benign appearing prostate tissue was identified. Prostate specific antigen immunohistochemical staining was performed: The adenocarcinoma showed strong positive staining for prostate specific antigen. A single enlarged lymph node was noted on the MRI and felt to represent metastatic cancer; the patient was Stage IV T3aN1M0 Gleason 9, high risk prostate cancer. No evidence of distant metastasis was noted.

The patient elected treatment with definitive radiotherapy and androgen deprivation. The patient received external beam treatment with Helical Tomotherapy which integrates Image-Guided Radiation Therapy (IGRT) with Intensity Modulated Radiation Therapy (IMRT). MR imaging was used in the treatment planning process by fusing the T2-weighted axial images with the images from the planning CT. The pelvic lymph nodes were included in the initial treatment plan. Figure 3 includes representative images of the treatment plan. Treatment of the pelvis was followed with a boost to the known gross disease, including the prostate and extraprostatic tumor as well as the lymph node. Both the tumor and lymph node were noted to have responded to the initial radiation treatments during repeat CT scan performed for planning the boost treatments. The prostate and tumor combined were initially 92 cc; they were noted to be 51 cc on the boost CT. During the second half of the course of radiation treatments, the patient reported mild fatigue and loose bowel movements which required no medication. Both symptoms had resolved within one month of completion of radiation treatments. Imaging was repeated with mpMRI at 1 month after his treatments. Significant regression of the extraprostatic tumor was confirmed (Fig. 3d). The patient was noted to have PSA  $<0.1$  for the subsequent 2 years until present, during which time he continued androgen deprivation.

## Discussion

Prostate cancer is a prevalent disease in the US, with around 165,000 new cases diagnosed in 2018. The majority of cancers are situated in the posterior prostate and standard TRUS biopsies are usually sufficient [3]. According to Alcala et al., 5% of prostate cancers are

located in the anterior fibromuscular stroma, an area not included in systematic prostate biopsies [4]. TRUS misses some percentage of cancers in the posterior peripheral zone as well. These cases of high suspicion of cancer despite a negative TRUS biopsy may be identified with mpMRI. A report by Hansen et al. evaluated this situation, with mpMRI guided biopsies for 487 patients with previous negative TRUS biopsies. They found that 9% of Gleason 7–10 cancers were missed with TRUS and combining mpMRI targeted biopsy with systematic TRUS biopsy is required for the most reliable detection of Gleason 7 and higher prostate cancer [5]. In light of this, mpMRI should be considered earlier in the course of monitoring for persistent PSA rise in the setting of negative TRUS biopsy. The widespread implementation of mpMRI may help identify those patients with limited disease and propel them to treatment earlier, improving their chance of cure.

In summary, the utility of mpMRI for prostate cancer is well established. Worldwide implementation has demonstrated its benefits in screening, diagnosing as well as treatment planning for prostate cancer. This case report echoes these technological leaps for prostate cancer, showing how an individual patient benefitted from its use. His previously undiagnosed cancer was imaged clearly, allowing for successful tumor-directed biopsy. This same image added substantial value to the patient's radiation treatment planning, helping to ensure the highest quality, aggressive treatment to definitive dose.

### **Acknowledgement**

The authors would like to acknowledge their families and co-workers, without whom this work would not be possible.

### **Statement of Ethics**

This patient has given their written informed consent to publish his case (including publication of images).

### **Disclosure Statement**

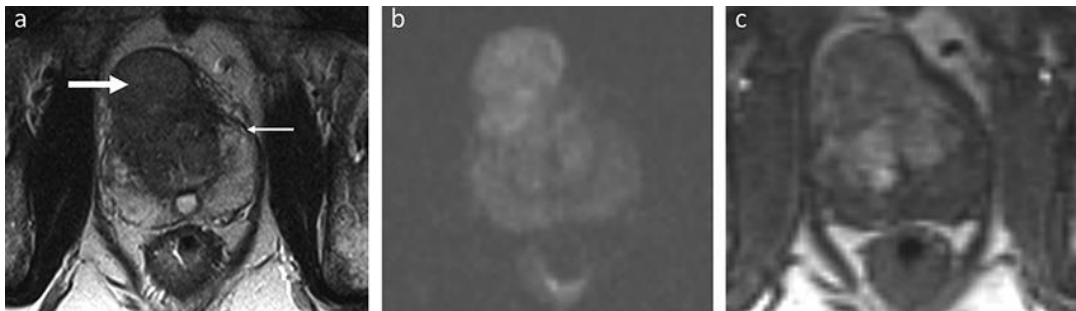
The authors have no conflicts of interest to declare.

### **Author Contributions**

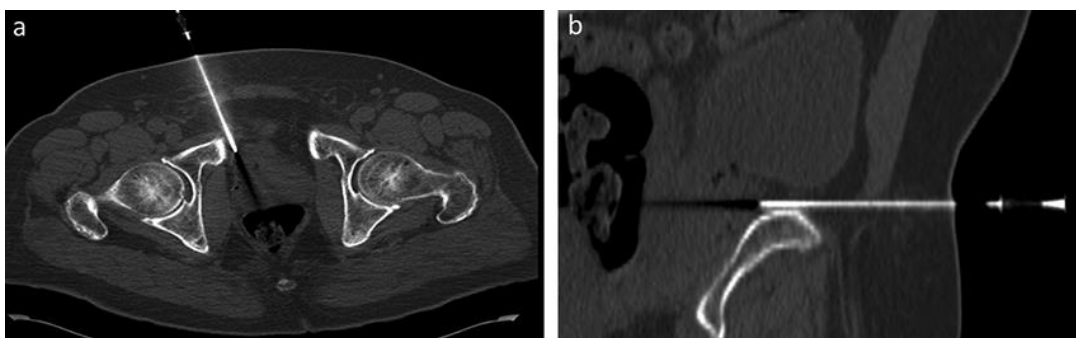
Dr. Talug is the patient's urologist and established the diagnosis of cancer in addition to managing his urologic care. Dr. Groten performed the CT-guided biopsy with the direct participation of Dr. Talug and Dr. Olson. Dr. Olson interpreted the patient's mpMRI and contributed to manuscript preparation. Dr. Baisden treated the patient and contributed to manuscript preparation. All authors contributed to manuscript editing.

## References

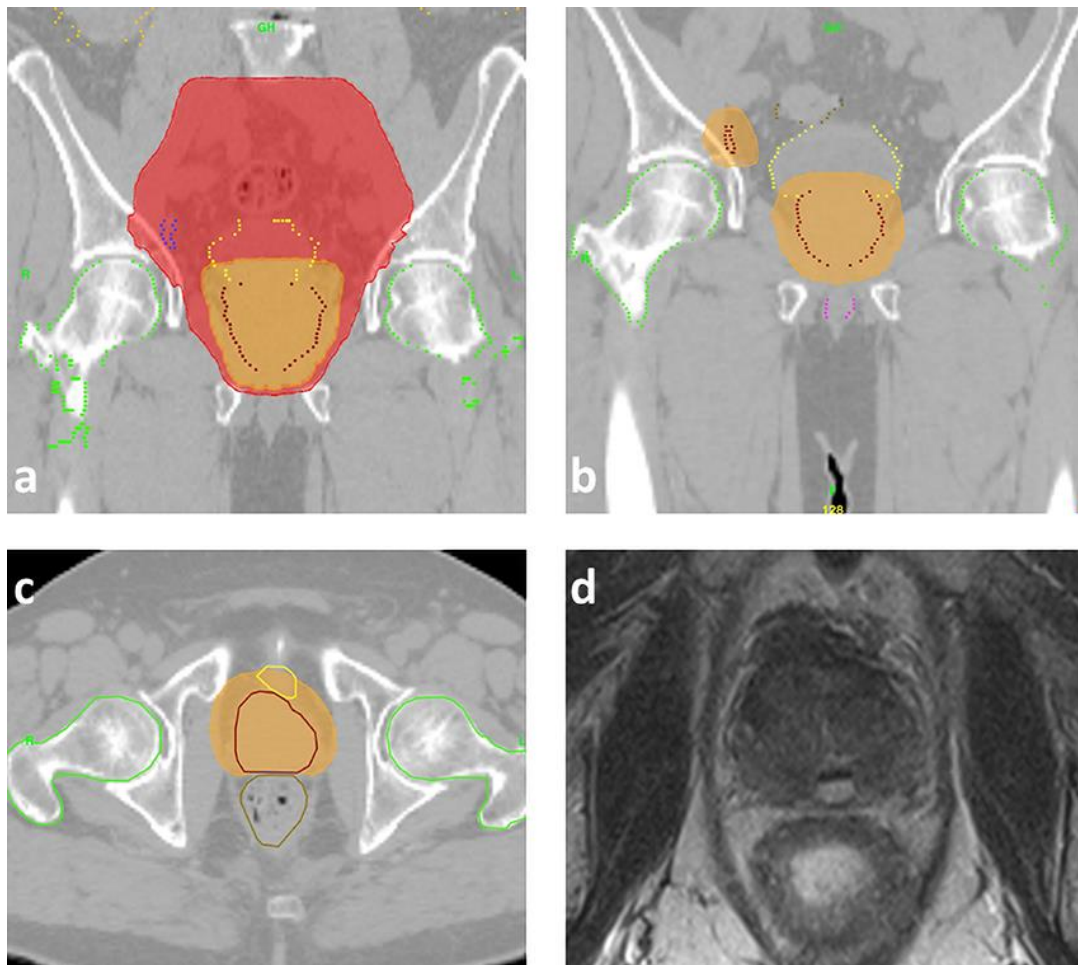
- 1 Nagarajan R, Margolis D, Raman S, Sheng K, King C, Reiter R, et al. Correlation of Gleason scores with diffusion-weighted imaging findings of prostate cancer. *Adv Urol*. 2012;2012:374805.
- 2 Weinreb JC, Barentsz JO, Choyke PL, Cornud F, Haider MA, Macura KJ, et al. PI-RADS prostate imaging - reporting and data system: 2015, version 2. *Eur Urol*. 2016 Jan;69(1):16–40.
- 3 Yacoub JH, Oto A. MR Imaging of Prostate Zonal Anatomy. *Radiol Clin North Am*. 2018 Mar;56(2):197–209.
- 4 Alcalá L, Catalá V, Campos EN, Potolicchio M, Luna AA. Multiparametric-MR, Anterior Fibromuscular Stroma and Prostate Cancer: What do you need to know? RSNA 2018, UR180-ED-MOAB.
- 5 Hansen NL, Barrett T, Kesch C, Pepdjonovic L, Bonekamp D, O'Sullivan R, et al. Multicentre evaluation of magnetic resonance imaging supported transperineal prostate biopsy in biopsy-naïve men with suspicion of prostate cancer. *BJU Int*. 2018 Jul;122(1):40–9.



**Fig. 1.** mpMR imaging identifying a large tumor originating in the transitional zone and extending through the capsule with a significant extraprostatic component. **a** T2 weighted MR image showing hypodense tumor (large white arrow) extending through the prostate capsule (small white arrow). **b** High b-value image shows restricted diffusion. **c** Post-contrast T1 image showing early enhancement of the tumor.



**Fig. 2.** Images of CT-guided biopsy of anterior tumor previously missed with 5 prior TRUS biopsies. **a** Axial image. **b** Sagittal image.



**Fig. 3.** Radiation treatment planning images and MR follow-up. **a** Coronal view of initial pelvic treatment plan. **b** Coronal view of radiation boost plan including prostate and pelvic lymph node. **c** Axial view of boost plan. Significant tumor response was noted during the repeat CT planning image performed for the boost. **d** Follow-up MR imaging performed showed significant tumor regression.