



Retrospective Study

## Computer-aided clinical image analysis as a predictor of sentinel lymph node positivity in cutaneous melanoma

Marios Papadakis, Alexandros Paschos, Andreas S Papazoglou, Andreas Manios, Hubert Zirngibl, Georgios Manios, Dimitra Koumaki

**Specialty type:** Oncology

**Provenance and peer review:**

Invited article; Externally peer reviewed.

**Peer-review model:** Single blind

**Peer-review report's scientific quality classification**

Grade A (Excellent): A

Grade B (Very good): B

Grade C (Good): C

Grade D (Fair): 0

Grade E (Poor): 0

**P-Reviewer:** Mangla A, United States; Wang P, China

**Received:** February 28, 2022

**Peer-review started:** February 28, 2022

**First decision:** May 31, 2022

**Revised:** June 24, 2022

**Accepted:** July 26, 2022

**Article in press:** July 26, 2022

**Published online:** August 24, 2022



**Marios Papadakis, Hubert Zirngibl**, Department of Surgery II, University of Witten-Herdecke, Wuppertal 42283, Germany

**Alexandros Paschos**, Department of Dermatology, Helios St. Elisabeth Hospital Oberhausen, Oberhausen 46045, Germany

**Andreas S Papazoglou**, Faculty of Medicine, Aristotle University of Thessaloniki, Thessaloniki 54124, Greece

**Andreas Manios**, Department of Surgical Oncology, University Hospital of Heraklion, Heraklion 71110, Greece

**Georgios Manios**, Department of Computer Science and Biomedical Informatics, University of Thessaly, Lamia 35131, Greece

**Dimitra Koumaki**, Department of Dermatology, University Hospital of Heraklion, Heraklion 71110, Greece

**Corresponding author:** Marios Papadakis, MD, MSc, PhD, Research Scientist, Surgeon, Department of Surgery II, University of Witten-Herdecke, Heusnerstrasse 40, Wuppertal 42283, Germany. [marios\\_papadakis@yahoo.gr](mailto:marios_papadakis@yahoo.gr)

### Abstract

#### BACKGROUND

Delays in sentinel lymph node (SLN) biopsy may affect the positivity of non-SLNs. For these reasons, effort is being directed at obtaining reliable information regarding SLN positivity prior to surgical excision. However, the existing tools, e.g., dermoscopy, do not recognize statistically significant predictive criteria for SLN positivity in melanomas.

#### AIM

To investigate the possible association of computer-assisted objectively obtained color, color texture, sharpness and geometry variables with SLN positivity.

#### METHODS

We retrospectively reviewed and analyzed the computerized medical records of all patients diagnosed with cutaneous melanoma in a tertiary hospital in Germany

during a 3-year period. The study included patients with histologically confirmed melanomas with Breslow > 0.75 mm who underwent lesion excision and SLN biopsy during the study period and who had clinical images shot with a digital camera and a handheld ruler aligned beside the lesion.

## RESULTS

Ninety-nine patients with an equal number of lesions met the inclusion criteria and were included in the analysis. Overall mean ( $\pm$  standard deviation) age was 66 (15) years. The study group consisted of 20 patients with tumor-positive SLN (SLN+) biopsy, who were compared to 79 patients with tumor-negative SLN biopsy specimen (control group). The two groups differed significantly in terms of age (61 years *vs* 68 years) and histological subtype, with the SLN+ patients being younger and presenting more often with nodular or secondary nodular tumors ( $P < 0.05$ ). The study group patients showed significantly higher eccentricity (*i.e.* distance between color and geometrical midpoint) as well as higher sharpness (*i.e.* these lesions were more discrete from the surrounding normal skin,  $P < 0.05$ ). Regarding color variables, SLN+ patients demonstrated higher range in all four color intensities (gray, red, green, blue) and significantly higher skewness in three color intensities (gray, red, blue),  $P < 0.05$ . Color texture variables, *i.e.* lacunarity, were comparable in both groups.

## CONCLUSION

SLN+ patients demonstrated significantly higher eccentricity, higher sharpness, higher range in all four color intensities (gray, red, green, blue) and significantly higher skewness in three color intensities (gray, red, blue). Further prospective studies are needed to better understand the effectiveness of clinical image processing in SLN+ melanoma patients.

**Key Words:** Melanoma; Skin cancer; Image processing; Sentinel lymph node; Presurgical

©The Author(s) 2022. Published by Baishideng Publishing Group Inc. All rights reserved.

**Core Tip:** Computer-aided image analysis can facilitate prediction of sentinel lymph-node positivity. Several color, sharpness and geometry parameters can predict positive lymph node occurrence, while color texture cannot determine sentinel lymph node positivity.

**Citation:** Papadakis M, Paschos A, Papazoglou AS, Manios A, Zirngibl H, Manios G, Koumaki D. Computer-aided clinical image analysis as a predictor of sentinel lymph node positivity in cutaneous melanoma. *World J Clin Oncol* 2022; 13(8): 702-711

**URL:** <https://www.wjgnet.com/2218-4333/full/v13/i8/702.htm>

**DOI:** <https://dx.doi.org/10.5306/wjco.v13.i8.702>

## INTRODUCTION

Cutaneous melanoma is a highly aggressive tumor that often spreads to local lymph nodes. Sentinel lymph node biopsy (SLNB) is commonly performed to identify nodal metastases because sentinel lymph node (SLN) status is a strong prognostic factor for survival in melanoma patients, especially in those without evidence of clinically positive lymph nodes[1]. In some subgroups, *e.g.*, in patients with thick melanomas (*i.e.* Breslow thickness > 4 mm) and patients with melanomas of the scalp, SLN status is considered the most important prognostic survival factor[2,3].

According to the existing guidelines, the decision for SLNB is based on the thickness of the primary tumor. SLNB is indicated for all primary tumors thicker than 1 mm and tumors thicker than 0.75 mm in the presence of ulceration or high mitotic rate (> 1 mm<sup>2</sup>). SLNB is of crucial importance in disease management because positive SLNB should be followed by lymph node dissection for regional disease control and staging purposes. Delays in SLNB may affect the positivity of non-SLNs[4]. For these reasons, an effort is being directed at obtaining reliable information regarding SLN positivity before surgical excision.

Dermoscopy is a non-invasive technique that facilitates early melanoma detection by revealing skin features invisible to the naked eye. However, dermoscopy does not recognize statistically significant predictive criteria for SLN positivity in melanomas because specific melanoma criteria strongly associated with a higher Breslow thickness, such as gray-blue areas or an atypical vascular pattern, do not seem to associate with SLN positivity[5].

Computer-aided clinical image analysis is also used to improve diagnostic accuracy for skin melanoma. We have shown that geometrical and color parameters objectively extracted by computer-aided clinical image processing may correlate with tumor thickness in patients with cutaneous melanoma[6]. However, to the best of our knowledge, there is no study investigating the possible association of computer-assisted objectively obtained color, color texture, sharpness and geometry variables with SLN positivity. The aim of this study was to investigate whether such an association exists.

## MATERIALS AND METHODS

### **Patient recruitment**

We retrospectively reviewed and analyzed the computerized medical records of all patients diagnosed with cutaneous melanoma in a tertiary hospital in Germany during a 3-year period. The study included patients with histologically confirmed melanomas with Breslow > 0.75 mm who underwent lesion excision and SLN biopsy during the study period and who had clinical images shot with a digital camera and a handheld ruler aligned beside the lesion. Patients with melanomas with Breslow < 0.75 mm and in situ melanomas as well as patients without digital images were excluded from the study. Patients referred to our center after primary excision to undergo SLN biopsy were also excluded from the study.

The study group consisted of patients with a positive SLN biopsy who were compared to patients with a negative SLN biopsy (control group). Clinical features studied included age, sex, tumor location and diagnosis date. Histopathologic features included tumor subtype [superficial spreading (de novo and nevus-associated) and nodular, including secondary nodular], Breslow thickness, Clark level, presence of ulceration, nevus pre-existence and SLN status (positive or negative). The study was approved by the institutional review board of the University of Witten-Herdecke.

### **Image collection, storage system and image database**

All lesions were photographed at admission with the same commercial digital camera at a resolution of 1600 × 1200 pixels and with a handheld ruler aligned beside the lesion to allow for correct image scaling. All photos were obtained from the same educated nurse to minimize inconsistencies in methodology and were uploaded to a local server. The lesions were then excised under local anesthesia, and the diagnosis was histologically confirmed.

### **Image processing**

The color images obtained underwent digital processing with an almost fully automated noncommercial software developed by one of the authors for study purposes. The software applies several kinds of algorithms to allow image segmentation and geometry, color and color texture analysis (Figure 1). The only manual involvement was the selection of the lesion border with the mouse cursor when the algorithm failed to do so (*i.e.* in very small lesions) (Figure 2). Such cases were independently analyzed twice by two of the authors (MP and GM) to avoid intraobserver errors (Figure 3). In cases of discrepancies, the mean scores were accepted and further analyzed. The 34 variables studied are classified as follows: (1) Geometrical variables (*i.e.* area, maximum diameter, perimeter, circularity, eccentricity and mean radius); (2) Color variables [*i.e.* range, standard deviation, coefficient of variation and skewness for all four color intensities (gray, red, green, blue)]; (3) Sharpness variables; and (4) Color texture variables (*i.e.* lacunarity)[7]. All variables are thoroughly described in Table 1.

### **Statistical analysis**

Normal distribution was determined using histogram plots, box plots and the Shapiro-Wilk test. Continuous data are presented in mean-standard deviation form. Categorical variables were compared using the two-tailed Fisher's exact test and continuous variables using the two-tailed Student's *t* test. A *P* value of less than 0.05 was considered statistically significant. Univariate and multivariate analysis using logistic regression were employed to identify potential independent determinants of a positive SLN result. Data analyses were performed using SPSS 23.

## RESULTS

Ninety-nine patients with an equal number of lesions met the inclusion criteria and were included in the analysis. Of these, 52 (52%) were males and the rest (48%) females. Histogram plots, box plots and the Shapiro-Wilk test demonstrated an almost normal distribution appearance for all continuous variables. The overall mean (standard deviation) age was 66 (15) years. The youngest patient was 14-years-old and the oldest 92-years-old. The study group consisted of 20 patients with tumor-positive SLN (SLN+) biopsy who were compared to 79 patients with tumor-negative SLN biopsy specimens (control group).

**Table 1 Explanation of geometric, sharpness, color and color texture variables studied[7]**

Classification	Parameter	Explanation
Geometry variables	Area	Lesion surface area, measured in cm <sup>2</sup>
	Maximum diameter	The longest line that joins two points on the border of the lesion, measured in cm
	Perimeter	Total boundary length of the region of interest ( <i>i.e.</i> lesion), measured in cm
	Circularity	Ratio of the perimeter of the lesion divided by the perimeter of a circle with the same midpoint and same area as the lesion
	Mean radius (Rm)	Mean value of the lesion's radii
	Standard deviation of Rm	Standard deviation of the mean radius
	Coefficient of variation of Rm	Expresses the standard deviation as a percentage of the mean
	Eccentricity	Distance between color and geometric midpoint within the lesion
	Eccentricity ratio	Distance between midpoint and color midpoint expressed as a fraction of the maximum diameter
Sharpness variables	SD of gray intensity	Intensity of gray on the border of the lesion
	Coefficient of variation of SD of gray intensity	SD of gray intensity in grayscale image. The higher the value, the more discrete the lesion is from the surrounding normal skin (Manousaki <i>et al</i> [7], 2016)
Color texture variables	Grayscale lacunarity of lesion (Lac gray)	It is estimated in grayscale image and assesses image texture heterogeneity or incomplete space filling within the lesion
Color variables	Range of gray, red, green, blue	Range of values of gray, red, green, blue intensity
	Mean gray, red, green, blue	Mean value of gray, red, green, blue intensity within the lesion
	SD of gray, red, green, blue	Standard deviation of gray, red, green, blue intensity within the lesion
	Coefficient of variation of gray, red, green, blue	Expresses the standard deviation of gray, red, green, blue intensity values as mean percentage
	Skewness from Gaussian curve (gray, red, green, blue)	Deviation of each color's histogram from the normal distribution curve

SD: Standard deviation.

The two groups differed significantly in terms of age (61 years *vs* 68 years) and histological subtype; the SLN+ patients were younger and presented more often with nodular or secondary nodular tumors ( $P < 0.05$ ).

The study group patients also showed significantly higher eccentricity (*i.e.* the distance between color and geometrical midpoint) and higher sharpness (*i.e.* these lesions were more discrete from the surrounding normal skin,  $P < 0.05$ ). Regarding color variables, SLN+ patients demonstrated a higher range in all four color intensities (gray, red, green, blue) and significantly higher skewness in three color intensities (gray, red, blue),  $P < 0.05$ . Color texture variables (*i.e.* lacunarity) were similar in both groups. Comparative data are summarized in Table 2.

Multivariate analysis of univariately significant variables ( $P < 0.05$ ) revealed that younger age and higher eccentricity were independently associated with a higher probability of positive lymph node occurrence [for age: adjusted odds ratio (aOR) = 0.95, 95% confidence interval (CI): 0.91 to 0.99 and for eccentricity: aOR = 1.45, 95% CI: 1.12 to 1.89]. Nevus, nodular and secondary nodular histotypes were also significantly linked with higher odds of positive lymph node presence when compared to the superficial spreading histotype (for nevus: aOR = 14.19, 95% CI: 1.15 to 174.76, for nodular: aOR = 10.71, 95% CI: 1.48 to 77.48 and for secondary nodular: aOR = 18.21, 95% CI: 2.19 to 151.22). The proposed multivariate model can predict the presence of SLN+ with an accuracy of 85% and is summarized in Table 3.

## DISCUSSION

Computer-aided image analysis is a noninvasive method and as such an established tool in the physicians' armamentarium to obtain reliable information regarding malignancy before surgical excision. SLN status is a strong prognostic factor for survival in melanoma patients (the tumor thickness threshold for SLNB being 1 mm) in the absence of risk factors. We herein investigated the possible association of computer-assisted objectively obtained color, texture and geometric variables with SLN

**Table 2 Demographic, clinical and image processing characteristics of melanoma patients with positive and negative sentinel lymph node biopsy**

Variable	Study group, SLNB+; <i>n</i> = 20	Control group, SLNB-; <i>n</i> = 79	<i>P</i> value
Demographics			
Sex			
Male	12 (60%)	40 (50%)	0.62
Female	8 (40%)	39 (50%)	
Age (yr)	61 (13)	68 (15)	0.05
Tumor thickness (mm)	2.6 (2.7)	2.2 (3.0)	0.64
Subtype	Superficial spread	44 (56%)	0.04
	Nodular	25 (32%)	
	Secondary nodular	10 (12%)	
Geometric variables			
Area (cm <sup>2</sup> )	3.4 (2.9)	2.8 (4.7)	0.49
MaxD (cm)	2.4 (1.2)	2 (1.1)	0.22
Perimeter (cm)	6.6 (3.0)	5.7 (3.3)	0.25
Circularity (ratio)	1.1 (0.1)	1.1 (0.1)	0.44
Rm (cm)	0.98 (0.5)	0.84 (0.5)	0.21
SDRm	0.14 (0.1)	0.12 (0.1)	0.48
CVRm	13 (7.1)	13 (5.5)	0.88
Delta (cm)	0.04 (0.03)	0.03 (0.03)	0.04
Delta ratio	1.8 (0.9)	1.6 (1.3)	0.42
Sharpness variables			
Sharpness	31 (9)	26 (8)	0.02
CV sharpness	22 (6)	18 (7)	0.02
Color texture variables			
Lac gray	2 (0.28)	1.97 (0.30)	0.65
Color variables			
Mean gray	104 (21)	113 (24)	0.12
SD gray	32 (6)	30 (7)	0.12
CV gray	8 (2)	10 (1)	0.07
Range gray	201 (21)	187 (32)	0.03
Skewness gray	0.52 (0.5)	0.23 (0.6)	0.03
Mean red	144 (26)	157 (32)	0.06
SD red	37 (9)	33 (11)	0.14
CV red	27 (10)	23 (11)	0.14
Range red	205 (23)	190 (37)	0.04
Skewness red	0.03 (0.43)	-0.04 (0.83)	0.003
Mean green	89 (23)	96 (23)	0.24
SD green	33 (7)	31 (6)	0.19
CV green	39 (12)	35 (13)	0.13
Range green	209 (24)	195 (33)	0.04

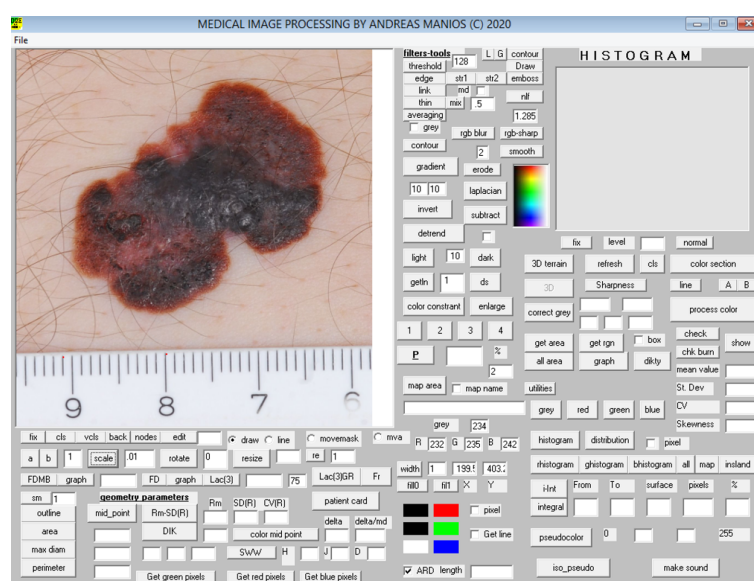
Skewness green	0.64 (0.46)	0.41 (0.60)	0.08
Mean blue	87 (22)	94 (25)	0.22
SD blue	33 (7)	31 (6)	0.24
CV blue	40 (10)	35 (13)	0.14
Range blue	218 (23)	201 (34)	0.02
Skewness blue	0.67 (0.47)	0.42 (0.56)	0.05

All continuous variables were normally distributed and therefore expressed in mean-deviation form. Categorical variables were expressed in terms of absolute (n) and relative (%) frequencies. Statistical significance: *P* value < 0.05. SD: Standard deviation; CV: Coefficient of variation; MaxD: Maximum diameter; SLNB+: Tumor-positive sentinel lymph node biopsy; SLNB-: Tumor-negative sentinel lymph node biopsy; Rm: Mean radius; SDRm: Standard deviation of the mean radius; CVRm: Coefficient variation of the mean radius; Lac: Lacunarity.

**Table 3 Multivariate analysis of univariately significant predictors of a positive sentinel lymph node result**

Variable	Coefficient ( $\beta$ )	Standard Error	Wald $\chi^2$	<i>P</i> value	Odds ratio	95%CI
Age	-0.05	0.20	7.60	0.006	0.95	0.91 to 0.99
Subtype, nevus-associated	2.65	1.28	4.28	0.038	14.19	1.15 to 174.76
Subtype, nodular	2.37	1.01	5.51	0.019	10.71	1.48 to 77.48
Subtype, secondary nodular	2.90	1.08	7.22	0.007	18.21	2.19 to 151.22
Eccentricity	0.38	0.13	7.84	0.005	1.46	1.12 to 1.89

95%CI: The 95% confidence interval for the estimated odds ratios.



DOI: 10.5306/wjco.v13.i8.702 Copyright © The Author(s) 2022.

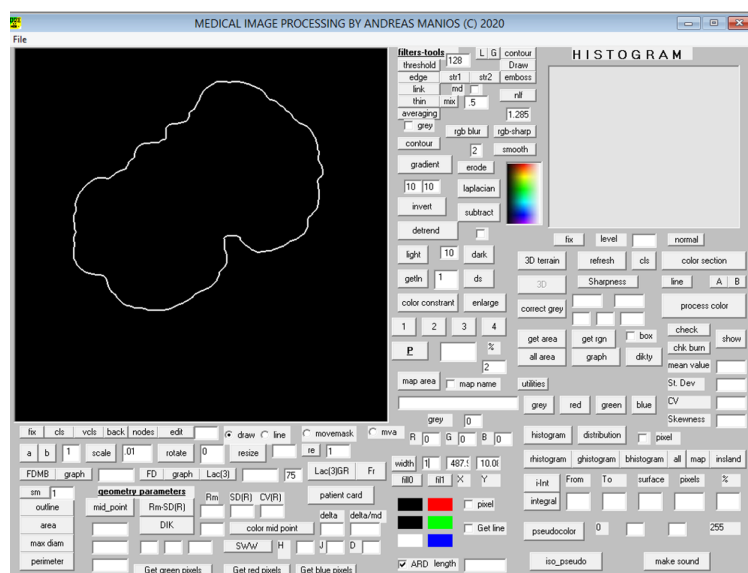
**Figure 1 Scaling of the lesion.**

positivity.

SLN+ patients have a higher range in all four color intensities (gray, red, green, blue) and significantly higher skewness in three color intensities (gray, red, blue). Blue and black pigmentation is associated with the presence of nodular melanoma, which in our study accounted for 50% of the SLN+ tumors[8]. Malignant epidermal structures, (e.g., atypical pigment network, radial streaks and pseudopods) are rarely seen in SLN+ melanomas, while they are observed in one-fourth of SLN negative lesions[5].

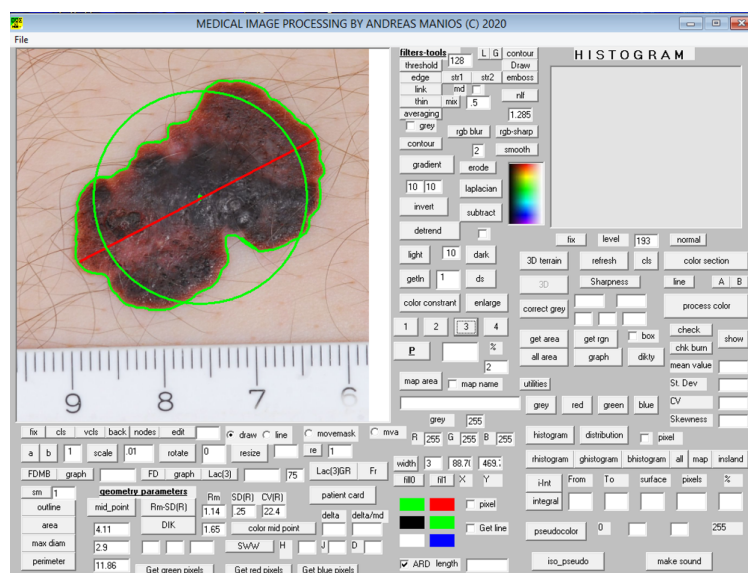
Despite the significant differences in all color intensities, we found that lacunarity (a measure of the variation of the color intensity) cannot predict SLN status in melanoma patients although it is a proven





DOI: 10.5306/wjco.v13.i8.702 Copyright © The Author(s) 2022.

Figure 2 Automatic recognition of the lesion's borders.



DOI: 10.5306/wjco.v13.i8.702 Copyright © The Author(s) 2022.

Figure 3 Measurements.

promising parameter in the automated differentiation of melanoma from non-melanoma[9]. We also found the lesions of SLN+ patients have significantly higher eccentricity, which is an index of uneven lesion coloration. Eccentricity represents a special case of asymmetry, and as shown before eccentric lesions may be thicker[6]. Dermoscopically, only the presence of ulceration and blotch correlate with positive SLNB[10].

Regarding histological type, González-Álvarez *et al*[10] found nodular melanomas to be the most associated with SLN positivity, reporting an OR of 3.98. This is consistent with our findings, where half of the SLN+ tumors were nodular, and the OR was 14.4. Moreover, we found that secondary nodular tumors are much more often associated with SLN+, with the OR exceeding 25. This may reflect more aggressive tumor growth because angiolymphatic invasion is observed in the majority of nodular melanomas with SLN+[5]. According to our findings, a multivariate model consisting of age, histological type and eccentricity can predict the presence of SLN+ with an accuracy of up to 85%.

A recent study described a deep learning-based digital biomarker to predict SLN+ from digitized hematoxylin and eosin slides of primary melanoma tumors. Artificial neural networks predicted SLN status with an accuracy of 55%-62%[11]. This relatively low accuracy is attributed to morphological changes of the tumor cells or tumor architecture. Moreover, the histopathological workup may have

caused tumor cells to be missed in the lymph nodes. Neural networks failed to detect features other than thickness and age that predict SLN+. We found that higher values of eccentricity, sharpness, blue, gray, green range, red skewness and red mean could also predict positive lymph node occurrence.

Our study is limited regarding its retrospective nature and small sample size. First, it is a single-center study of German individuals, and therefore the results cannot be easily generalized. Second, only melanoma patients with available clinical images made before the diagnosis was established were included. Therefore, there is a high risk of bias due to no consecutive cases being included. Selection bias may have led to suspect cases being more frequently photographed. Moreover, we excluded all patients with melanomas with Breslow thickness < 0.75 mm. However, the specimens were analyzed by different pathologists during the study period, so the interpretation bias of tumor thickness may have led to eligible cases being excluded.

## CONCLUSION

In conclusion, computer-aided image analysis can facilitate the prediction of SLN+. SLN+ patients demonstrated significantly higher eccentricity, higher sharpness and higher range in all four color intensities (gray, red, green, blue) as well as significantly higher skewness in three color intensities (gray, red, blue). Further prospective studies are needed to better understand the effectiveness of clinical image processing in SLN+ melanoma patients.

## ARTICLE HIGHLIGHTS

### Research background

Computer-aided clinical image analysis is used to improve diagnostic accuracy for skin melanoma.

### Research motivation

To the best of our knowledge, there is no study investigating the possible association of computer-assisted objectively obtained color, color texture, sharpness and geometry variables with sentinel lymph node positivity (SLN+).

### Research objectives

To investigate a possible association of computer-assisted objectively obtained color, color texture, sharpness and geometry variables with SLN+.

### Research methods

The study included patients with histologically confirmed melanomas with Breslow > 0.75 mm who underwent lesion excision and SLN biopsy during the 3-year study period and who had clinical images shot with a digital camera and a handheld ruler aligned beside the lesion. All the color images obtained underwent digital processing with an almost fully automated noncommercial software developed by one of the authors for study purposes.

### Research results

Ninety-nine patients with an equal number of lesions met the inclusion criteria and were included in the analysis. The study group consisted of 20 patients with SLN+ biopsy who were compared to 79 patients with tumor-negative SLN biopsy specimen (control group). The study group patients showed significantly higher eccentricity (*i.e.* distance between color and geometrical midpoint) as well as higher sharpness (*i.e.* these lesions were more discrete from the surrounding normal skin,  $P < 0.05$ ). Regarding color variables, SLN+ patients demonstrated higher range in all four color intensities (gray, red, green, blue) and significantly higher skewness in three color intensities (gray, red, blue),  $P < 0.05$ . Color texture variables, *i.e.* lacunarity, were comparable in both groups.

### Research conclusions

Computer-aided image analysis can facilitate the prediction of SLN+. SLN+ patients demonstrated significantly higher eccentricity, higher sharpness and higher range in all four color intensities (gray, red, green, blue) as well as significantly higher skewness in three color intensities (gray, red, blue).

### Research perspectives

Further prospective studies are needed to better understand the effectiveness of clinical image processing in SLN+ melanoma patients.



## FOOTNOTES

**Author contributions:** Papadakis M designed the research, performed the research, analyzed the data and wrote the paper; Paschos A participated in the data collection; Papazoglou A analyzed the data, Manios A contributed a new software used for the study; Zirngibl H contributed literature sources; Manios G analyzed the data; Koumaki D designed the research, performed the research, analyzed the data and wrote the paper; All authors reviewed and approved the final manuscript.

**Institutional review board statement:** The study was approved from the Ethics Committee of University Witten/Herdecke and was performed in accordance with institutional guidelines. Written informed consent was waived for retrospective study participation.

**Informed consent statement:** Patients were not required to give informed consent to the study because the analysis used anonymous clinical data that were obtained after each patient agreed to treatment by written consent.

**Conflict-of-interest statement:** All authors declare no conflicts of interest.

**Data sharing statement:** The datasets used and/or analyzed during the current study are available from the corresponding author on reasonable request.

**Open-Access:** This article is an open-access article that was selected by an in-house editor and fully peer-reviewed by external reviewers. It is distributed in accordance with the Creative Commons Attribution NonCommercial (CC BY-NC 4.0) license, which permits others to distribute, remix, adapt, build upon this work non-commercially, and license their derivative works on different terms, provided the original work is properly cited and the use is non-commercial. See: <https://creativecommons.org/licenses/by-nc/4.0/>

**Country/Territory of origin:** Germany

**ORCID number:** Marios Papadakis 0000-0002-9020-874X; Andreas S Papazoglou 0000-0003-4981-8121.

**S-Editor:** Wang LL

**L-Editor:** Filipodia

**P-Editor:** Wang LL

## REFERENCES

- Narang J, Hue JJ, Bingmer K, Hardacre JM, Winter JM, Ocuin LM, Ammori JB, Mangla A, Bordeaux J, Rothermel LD. Sentinel lymph node biopsy guideline concordance in melanoma: Analysis of the National Cancer Database. *J Surg Oncol* 2021; **124**: 669-678 [PMID: 34109633 DOI: 10.1002/jso.26565]
- Gutzmer R, Satzger I, Thoms KM, Völker B, Mitteldorf C, Kapp A, Bertsch HP, Kretschmer L. Sentinel lymph node status is the most important prognostic factor for thick (> or = 4 mm) melanomas. *J Dtsch Dermatol Ges* 2008; **6**: 198-203 [PMID: 18093216 DOI: 10.1111/j.1610-0387.2007.06569.x]
- Cappello ZJ, Augenstein AC, Potts KL, McMasters KM, Bumpous JM. Sentinel lymph node status is the most important prognostic factor in patients with melanoma of the scalp. *Laryngoscope* 2013; **123**: 1411-1415 [PMID: 23625541 DOI: 10.1002/Lary.23793]
- Richtig G, Richtig E, Neiss AN, Quehenberger F, Gmainer DG, Kamolz LP, Lumenta DB. Does the time interval between sentinel lymph node biopsy and completion lymph node dissection affect outcome in malignant melanoma? *Int J Surg* 2020; **75**: 160-164 [PMID: 32036082 DOI: 10.1016/j.ijsu.2020.01.146]
- Pagnanelli G, Bono R, Pizzichetta MA, Talamini R, Ascierto PA, Testori A, Stanganelli I; Italian Melanoma Intergroup (IMI). Clinical and dermoscopic criteria related to melanoma sentinel lymph node positivity. *Anticancer Res* 2007; **27**: 2939-2944 [PMID: 17695474]
- Papadakis M, Paschos A, Manios A, Lehmann P, Manios G, Zirngibl H. Computer-aided clinical image analysis for non-invasive assessment of tumor thickness in cutaneous melanoma. *BMC Res Notes* 2021; **14**: 232 [PMID: 34127072 DOI: 10.1186/s13104-021-05650-4]
- Manousaki AG, Manios AG, Tsompanaki EI, Panayiotides JG, Tsiftsis DD, Kostaki AK, Tosca AD. A simple digital image processing system to aid in melanoma diagnosis in an everyday melanocytic skin lesion unit: a preliminary report. *Int J Dermatol* 2006; **45**: 402-410 [PMID: 16650167 DOI: 10.1111/j.1365-4632.2006.02726.x]
- Argenziano G, Fabbrocini G, Carli P, De Giorgi V, Delfino M. Clinical and dermoscopic criteria for the preoperative evaluation of cutaneous melanoma thickness. *J Am Acad Dermatol* 1999; **40**: 61-68 [PMID: 9922013 DOI: 10.1016/s0190-9622(99)70528-1]
- Gilmore S, Hofmann-Wellenhof R, Muir J, Soyer HP. Lacunarity analysis: a promising method for the automated assessment of melanocytic naevi and melanoma. *PLoS One* 2009; **4**: e7449 [PMID: 19823688 DOI: 10.1371/journal.pone.0007449]
- González-Álvarez T, Carrera C, Bennassar A, Vilalta A, Rull R, Alos L, Palou J, Vidal-Sicart S, Malvey J, Puig S. Dermoscopy structures as predictors of sentinel lymph node positivity in cutaneous melanoma. *Br J Dermatol* 2015; **172**: 1269-1277 [PMID: 25418318 DOI: 10.1111/bjd.13552]
- Brinker TJ, Kiehl L, Schmitt M, Jutzi TB, Krieghoff-Henning EI, Krahel D, Kutzner H, Gholam P, Haferkamp S, Klode J,

Schadendorf D, Hekler A, Fröhling S, Kather JN, Haggemüller S, von Kalle C, Heppt M, Hilke F, Ghoreschi K, Tiemann M, Wehkamp U, Hauschild A, Weichenthal M, Utikal JS. Deep learning approach to predict sentinel lymph node status directly from routine histology of primary melanoma tumours. *Eur J Cancer* 2021; **154**: 227-234 [PMID: [34298373](#) DOI: [10.1016/j.ejca.2021.05.026](#)]



Published by **Baishideng Publishing Group Inc**  
7041 Koll Center Parkway, Suite 160, Pleasanton, CA 94566, USA

**Telephone:** +1-925-3991568

**E-mail:** [bpgoffice@wjgnet.com](mailto:bpgoffice@wjgnet.com)

**Help Desk:** <https://www.f6publishing.com/helpdesk>

<https://www.wjgnet.com>

