

Tetравentricular Hydrocephalus Following Eosinophilic Meningitis due to *Angiostrongylus cantonensis* in a 14-Month-Old Boy From Mayotte: A Case Report

Chiara Cattaneo,^{1,2} Marion Hoarau,³ Sophie Valois,³ Abdourahim Chamouine,¹ Yacouba Dembele,⁴ Luis Collet,⁵ and Raphaëlle Sarton³

¹Department of Paediatrics, Centre Hospitalier de Mayotte, Mamoudzou, France, ²Division of Infectious Diseases, Department of Medicine II, University of Freiburg, Freiburg, Germany, ³Department of Paediatrics, CHU La Réunion Groupe Hospitalier du Sud, Saint Pierre, France, ⁴Department of Radiology, Centre Hospitalier de Mayotte, Mamoudzou, France, and ⁵Medical Biology Laboratory, Centre Hospitalier de Mayotte, Mamoudzou, France

Angiostrongylus cantonensis is endemic in Mayotte, and cases of meningitis due to angiostrongyliasis are regularly diagnosed in young children. In a 14-month-old boy with slow-onset psychomotor regression, brain magnetic resonance imaging revealed communicating hydrocephalus. Reverse transcription polymerase chain reaction for *A. cantonensis* on cerebrospinal fluid was positive. The evolution was favorable with repeated lumbar punctures and a 2-week treatment with albendazole and high-dose corticosteroids.

Keywords. angiostrongyliasis; *Angiostrongylus cantonensis*; eosinophilic meningitis; hydrocephalus; child.

Angiostrongylus cantonensis is a zoonotic pathogen that occasionally causes human angiostrongyliasis (HA) and is the leading cause of eosinophilic meningitis worldwide [1, 2]. In Mayotte, a French department in the Indian Ocean, *A. cantonensis* is endemic and cases of meningitic angiostrongyliasis are regular, mostly in very young children [3, 4]. Humans become infected with third-stage larvae by consuming raw or undercooked snails or slugs, carrier hosts that have themselves eaten infected molluscs, or vegetables contaminated by mollusc slime, even though mucus from slugs and snails poses only a low infection risk to humans [1, 5, 6]. In Mayotte, *Achatina fulica*, the giant African snail, seems to have a main role in transmission of HA [3]. Children may get contaminated by direct contact, playing with infected molluscs. *A. cantonensis* real-time polymerase chain

reaction (RT-PCR) is an essential tool for confirming the diagnosis of HA and is available in Mayotte [3]. Here we describe a case of eosinophilic meningitis complicated by tetравentricular hydrocephalus due to *A. cantonensis* in a 14-month-old child treated in Mayotte and in Reunion Island.

CASE REPORT

A 14-month-old boy presented with new-onset convergent strabismus of the right eye and slow-onset psychomotor and language regression in the hospital of Mamoudzou, the main hospital of Mayotte Island. Four weeks before admission, he was taken to a general practitioner (GP) because of a fever of a few days' duration with asthenia, drowsiness, and anorexia. His head circumference was measured at 47.5 cm at that time point, and he received a symptomatic treatment with paracetamol.

The child was born in Mayotte at 35 weeks of pregnancy and had no complications at birth. His psychomotor development was normal: He was able to sit at 6 months of age and to walk with support and say a few words at the age of 10 months. He had no history of epilepsy or any other neurological pathology.

On examination, the patient was afebrile, and his hemodynamic parameters were normal. His head circumference was measured at 49.5 cm. Cardiac and pulmonary examination was normal, and he had no cutaneous rash. He presented no signs of intracranial hypertension; his pupils were symmetric and reactive with a convergent strabismus of the right eye. During neurological examination, he showed axial hypotonia, right hemiparesis, abnormal movements of the upper limbs, and tremor of the right foot.

His blood leukocyte count was 12 200 cells/ μ L with a blood eosinophilia of 11.5% (1400 cells/ μ L) and C-reactive protein of 7 mg/L at admission. The blood test performed by the GP 4 weeks before showed 16 100 leucocytes/ μ L with a blood eosinophilia of 18.9% (3040 cells/ μ L) and C-reactive protein 9 mg/L. Magnetic resonance imaging (MRI) of the brain showed communicating tetравentricular hydrocephalus with periventricular hypersignal (Figure 1).

A lumbar puncture revealed 148 white blood cells/ mm^3 with 25% eosinophils and 60% lymphocytes, an elevated cerebrospinal fluid (CSF) protein level of 77 mg/dL, and a CSF glucose level of 29 mmol/dL. Gram stain was negative; CSF culture for bacteria yielded no growth. RT-PCR for *A. cantonensis* on CSF was positive.

The patient was referred to the pediatric ward of the University Hospital in Saint Pierre (Reunion), which has a neurosurgery department.

Treatment with albendazole at 15 mg/kg/d and intravenous methylprednisolone at 1 mg/kg/d was promptly started;

Received 26 October 2020; editorial decision 14 January 2021; accepted 21 January 2021.

Correspondence: Chiara Cattaneo, MD, Department of Paediatrics, Centre Hospitalier de Mayotte, Rue de l'hôpital, 97600 Mamoudzou, France (chiara.cattaneo@uniklinik-freiburg.de).

Open Forum Infectious Diseases® 2021

© The Author(s) 2021. Published by Oxford University Press on behalf of Infectious Diseases Society of America. This is an Open Access article distributed under the terms of the Creative Commons Attribution-NonCommercial-NoDerivs licence (<http://creativecommons.org/licenses/by-nc-nd/4.0/>), which permits non-commercial reproduction and distribution of the work, in any medium, provided the original work is not altered or transformed in any way, and that the work is properly cited. For commercial re-use, please contact journals.permissions@oup.com DOI: 10.1093/ofid/ofab031

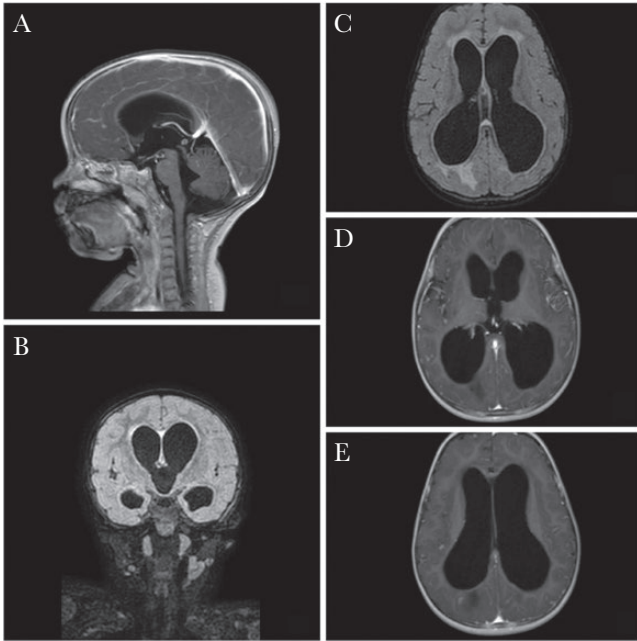

Figure 1. Magnetic resonance image of a 14-month-old child with postmeningitic hydrocephalus. A, Sagittal gadolinium-enhanced T1 images showing communicated, enlarged lateral third and fourth ventricles. B, Coronal fluid-attenuated inversion recovery (FLAIR) images showing enlargement of third and lateral ventricles. C, Axial FLAIR images showing enlargement of lateral ventricles with periventricular hypersignal. D, Axial gadolinium-enhanced T1 images showing leptomeningeal enhancement. E, Axial gadolinium-enhanced T1 images showing enlargement of lateral ventricles.

methylprednisolone was switched for oral prednisone at 1 mg/kg/d after 48 hours and continued for 14 days in total. Repeated large-volume lumbar punctures (LPs) were performed. Opening pressure at LP was normal, CSF was clear, and eosinophil count and protein level in CSF gradually decreased (Table 1, Figure 2). Significant clinical improvements were noted over time. After the first large-volume LP, stability while sitting improved and the right hemiparesis gradually disappeared. After 1 week of treatment, the child completely regained function of the paretic limb and was able to use both hands equally. His language skills improved after

14 days of treatment. Ophthalmology examination revealed no signs of intracranial hypertension or ocular involvement; strabismus regressed. Transfontanellar doppler ultrasounds were regularly performed and showed a good diastolic flow with a low resistance index and no signs of intracranial hypertension. The follow-up brain computed tomography scan after 14 days of treatment showed persisting tetraventricular hydrocephalus.

Considering the prompt clinical improvement with conservative treatment, neurosurgery to place a ventriculoperitoneal shunt was not performed; the 14-day course of high-dose steroids was followed by a weaning course of oral prednisolone, with a decrease of 2.5 mg every 3 days over 9 days. The child went back to Mayotte, and his neurological examination was normal for his age at the 1-month follow-up visit.

DISCUSSION

Human angiostrongyliasis is the main cause of eosinophilic meningitis in Mayotte, where the incidence is estimated at 2.3 cases per year (~1 case per 100 000 inhabitants per year) [3]. Most cases are reported in Asia, particularly China, Southeastern Asia, and in the Pacific Ocean islands worldwide [2, 7, 8]. In Mayotte and other places in the Indian Ocean, the vector is the African giant snail, *A. fulica*, which is omnipresent in the environment. Previous cases in Mayotte have been reported, and infants younger than 2 years are the most affected [3, 9, 10]. This epidemiology is related to the habit of infants to lick and play with the snails. Cases occur mostly during the rainy season, as *A. fulica* estivates during the dry season. In a case series from Mayotte, a 1-year mortality of 35.7% and high incidence of neurological sequelae were reported [3].

Clinical presentation is variable and generally differs between infants and adults. The most common symptoms in adults are headache, neck stiffness, nausea, and vomiting because of increased intracranial pressure. High-grade fever, abdominal pain, drowsiness, and severe neurological manifestations up to coma and death are more frequently reported in young children

Table 1. Biological Parameters of CSF in 3 Large-Volume Lumbar Punctures

	1st LP	2nd LP	3rd LP
Day of treatment ^a	1 day before	Day 2	Day 14
Head circumference, cm	50	49.5	49.2
Withdrawn volume, mL	10	10	5
Opening pressure, mmHg	<25	<25	<25
CSF cells count, /mm ³	148	140	90
Eosinophils, %	25	14	10
CSF glucose level, mmol/dL	29	38	37
CSF protein level, mg/dL	77	67	36

Abbreviations: CSF, cerebrospinal fluid; LP, lumbar puncture.

^aAlbendazole at 15 mg/kg/d and intravenous methylprednisolone followed by oral prednisone at 1 mg/kg/d.

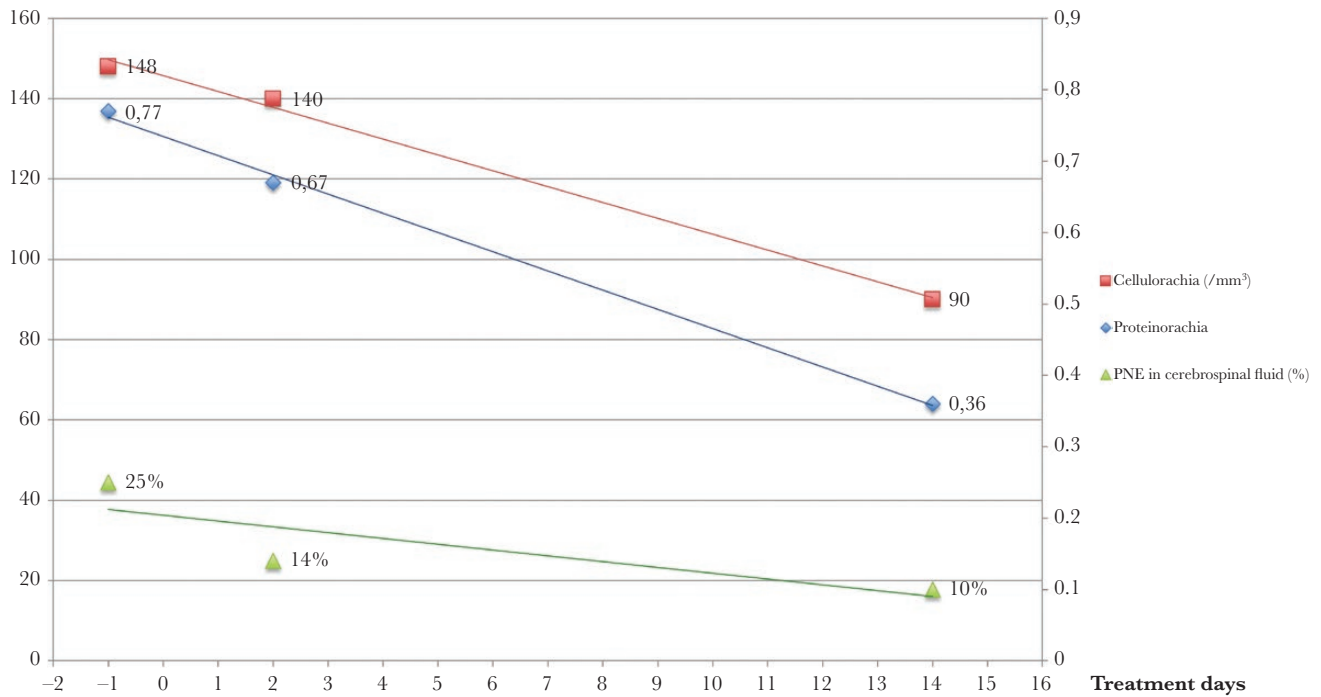


Figure 2. Biological parameters of cerebrospinal fluid in 3 large-volume lumbar punctures. Abbreviation: PNE, polynuclear eosinophil.

[1, 4, 11]. In meningitic angiostrongyliasis, LP typically reveals pleocytosis in the CSF with increased eosinophil count, accompanied by a peripheral eosinophilia [12].

Since the first publication of the biological method in 2010 [13], RT-PCR on CSF has become an essential tool for confirming the diagnosis of eosinophilic meningitis due to *A. cantoniensis* because of high sensitivity and specificity [3, 11, 14].

MRI is the imaging study of choice, and several features seen on MRI are suggestive of neuroangiostrongyliasis, including leptomeningeal enhancement in postcontrast studies, increased signal intensity in the subcortical white matter on T2-weighted and fluid-attenuated inversion recovery images, and nodular, enhancing lesions on gadolinium-enhanced T1 images [11, 15].

Here, we report a case of eosinophilic meningitis in a 14-month-old boy with a mild onset, slow instauration of neurological symptoms, and hydrocephalus. The time point of exposure was unfortunately unknown, and the time course of infection could not be estimated. Cases of hydrocephalus as a late complication of eosinophilic meningitis have been reported in adult and pediatric patients from different countries of the world. In these cases, onset is generally more severe, neurosurgery for ventriculoperitoneal shunt is sometimes performed, and prognosis is often poor [4, 9, 10, 15, 16]. In a previous case series from Mayotte reported by Epelboin et al. [3], 5 children between 8 and 12 months of age had ventricular dilatation. They all received anthelmintic and corticosteroids; 4/5 children died after 1 year, and the remaining child had severe neurological sequelae. We hypothesize that the

older age of our case and the large-volume LP performed along with medical treatment may have contributed to the favorable evolution. Previous studies have reported slow resolution over several weeks of the brain lesions due to *A. cantoniensis* on follow-up MRI [17]; hence, decisions on the therapeutic management of our case were based on clinical findings. We believe that a 2-week course of high-dose corticosteroids was helpful in treating the inflammatory response to the tissue invasion by *Angiostrongylus* and the presence of dead or dying worms. Anthelmintic may be beneficial as well, even though the role of anthelmintic in eosinophilic meningitis remains unclear [11, 17, 18]. Large-volume LP led to some immediate improvement and may have contributed to the favorable evolution. LP are recommended along with the medical treatment [12], while the benefit of a ventriculoperitoneal (VP) shunt in hydrocephalus due to eosinophilic meningitis has not been investigated so far.

CONCLUSIONS

We report a case of a 14-month-old boy with tetraventricular hydrocephalus as a complication of eosinophilic meningitis. The clinical evolution was favorable after repeated lumbar punctures and a 2-week treatment with high-dose corticosteroids and albendazole, without necessity of a VP shunt. HA should be considered as a possible cause of hydrocephalus in endemic areas of *A. cantoniensis* or in returning travelers. Early diagnosis of eosinophilic meningitis in patients at risk may prevent late complications and poor prognosis.

Acknowledgments

Financial support. The authors received no specific funding for this work.

Potential conflicts of interest. We declare no competing interests. All authors have submitted the ICMJE Form for Disclosure of Potential Conflicts of Interest. Conflicts that the editors consider relevant to the content of the manuscript have been disclosed.

Author contributions. C.C., M.H., S.V., A.C., and R.S. were the patient's pediatricians. Y.D. was the consulting radiologist for the case. L.C. was the consulting biologist for the case. C.C., M.H., and R.S. wrote the manuscript and did the review of the literature. S.V., A.C., Y.D., and L.C. reviewed and edited the manuscript.

Patient consent. Written informed consent was obtained from the patient's parents for publication. Publication of the retrospectively obtained and anonymized data conformed to the General Data Protection Regulation of 23rd May 2018 of the French Data Protection Authority (Commission Nationale de l'Informatique et des Libertés [CNIL]).

References

1. Wang QP, Lai DH, Zhu XQ, et al. Human angiostrongyliasis. *Lancet Infect Dis* **2008**; 8:621–30.
2. Martins YC, Tanowitz HB, Kazacos KR. Central nervous system manifestations of *Angiostrongylus cantonensis* infection. *Acta Trop* **2015**; 141:46–53.
3. Epelboin L, Blondé R, Chamouine A, et al. *Angiostrongylus cantonensis* infection on Mayotte Island, Indian Ocean, 2007–2012. *PLoS Negl Trop Dis* **2016**; 10:e0004635.
4. Epelboin L, Collet L, Raz M, Villemant N, Malvy D, Blondé R. Langiostrongylose humaine: une maladie tropicale négligée. *Rev Francoph des Lab* **2016**; 483:45–55.
5. Luessi F, Sollors J, Torzewski M, et al. Eosinophilic meningitis due to *Angiostrongylus cantonensis* in Germany. *J Travel Med* **2009**; 16:292–4.
6. Kramer KJ, Posner J, Gosnell WL. Role of gastropod mucus in the transmission of *Angiostrongylus cantonensis*, a potentially serious neurological infection. *ACS Chem Neurosci* **2018**; 9:629–32.
7. Barratt J, Chan D, Sandaradura I, et al. *Angiostrongylus cantonensis*: a review of its distribution, molecular biology and clinical significance as a human pathogen. *Parasitology* **2016**; 143:1087–118.
8. Tseng YT, Tsai HC, Sy CL, et al. Clinical manifestations of eosinophilic meningitis caused by *Angiostrongylus cantonensis*: 18 years' experience in a medical center in Southern Taiwan. *J Microbiol Immunol Infect* **2011**; 44:382–9.
9. Graber D, Jaffar-Bandjee MC, Attali T, et al. Angiostrongylosis in infants in Reunion and Mayotte. Apropos of 3 cases of eosinophilic meningitis including 1 fatal radiculo-myeloencephalitis with hydrocephalus. *Arch Pediatr* **1997**; 4:424–9.
10. Graber D, Hebert JC, Jaffar-Bandjee MC, et al. Severe forms of eosinophilic meningitis in infants of Mayotte. Apropos of 3 cases. *Bull Soc Pathol Exot* **1999**; 92:164–6.
11. Ansdell V, Wattanagoon Y. *Angiostrongylus cantonensis* in travelers: clinical manifestations, diagnosis, and treatment. *Curr Opin Infect Dis* **2018**; 31:399–408.
12. Sawanyawisuth K, Chindaprasit J, Senthong V, et al. Clinical manifestations of eosinophilic meningitis due to infection with *Angiostrongylus cantonensis* in children. *Korean J Parasitol* **2013**; 51:735–8.
13. Qvarnstrom Y, da Silva AC, Teem JL, et al. Improved molecular detection of *Angiostrongylus cantonensis* in mollusks and other environmental samples with a species-specific internal transcribed spacer 1-based taqman assay. *Appl Environ Microbiol* **2010**; 76:5287–9.
14. Eamsobhana P, Wanachiwanawin D, Dechkum N, et al. Molecular diagnosis of eosinophilic meningitis due to *Angiostrongylus cantonensis* (nematoda: metastrongyloidea) by polymerase chain reaction-DNA sequencing of cerebrospinal fluids of patients. *Mem Inst Oswaldo Cruz* **2013**; 108:116–8.
15. Sawanyawisuth K, Thammaroj J, Limpawattana P, et al. Communicating hydrocephalus as a complication of eosinophilic meningoencephalitis. *J Med Assoc Thai* **2006**; 89:1024–8.
16. Enzenauer RW, Yamaoka RM. Eosinophilic meningitis and hydrocephalus in an infant. *Arch Neurol* **1982**; 39:380–1.
17. Sawanyawisuth K, Sawanyawisuth K. Treatment of angiostrongyliasis. *Trans R Soc Trop Med Hyg* **2008**; 102:990–6.
18. Chotmongkol V, Sawanyawisuth K, Thavornpitak Y. Corticosteroid treatment of eosinophilic meningitis. *Clin Infect Dis* **2000**; 31:660–2.