



Successful retreatment with osimertinib after osimertinib-induced acute pulmonary embolism in a patient with lung adenocarcinoma: A case report



Takayuki Shiroyama*, Manabu Hayama, Shingo Satoh, Shingo Nasu, Ayako Tanaka, Satomu Morita, Naoko Morishita, Hidekazu Suzuki, Norio Okamoto, Tomonori Hirashima

Department of Thoracic Malignancy, Osaka Prefectural Medical Center for Respiratory and Allergic Diseases, Osaka, Japan

ARTICLE INFO

Article history:

Received 29 September 2016

Received in revised form

31 October 2016

Accepted 4 November 2016

Keywords:

Osimertinib

Acute pulmonary embolism

Venous thromboembolism

Retreatment

Interstitial lung disease

ABSTRACT

Pulmonary embolism (PE) can be life-threatening, and it is challenging to diagnose because of its nonspecific signs and symptoms. PE is also an important potential risk of osimertinib treatment, however, clinical courses regarding retreatment after osimertinib-induced acute pulmonary embolism remain unclear. We described a 77-year-old woman with postoperative recurrent lung adenocarcinoma who developed osimertinib-induced acute PE. She received apixaban and was later successfully retreated with osimertinib. This case suggests that retreatment with osimertinib after osimertinib-induced acute PE may be a treatment option when alternative therapeutic options are limited.

© 2016 The Authors. Published by Elsevier Ltd. This is an open access article under the CC BY-NC-ND license (<http://creativecommons.org/licenses/by-nc-nd/4.0/>).

1. Introduction

Venous thromboembolism (VTE), comprising deep vein thrombosis (DVT) and pulmonary embolism (PE), is a major cause of death in cancer patients. Osimertinib has been approved for the treatment of epidermal growth factor receptor (*EGFR*) T790M mutation-positive non-small cell lung cancer that are resistant to first- or second-generation *EGFR* tyrosine kinase inhibitors. However, little is known about VTE induced by osimertinib. Here, we report a case of successful retreatment with osimertinib after osimertinib-induced acute PE in a patient with lung adenocarcinoma.

2. Case

A 77-year-old non-smoking woman with postoperative recurrent lung adenocarcinoma harboring an *EGFR* L858R mutation was found to have disease progression after receiving gefitinib

treatment for 2 years followed by afatinib treatment for 3 months. A chest computed tomography (CT) and head magnetic resonance imaging (MRI) scan demonstrated that recurrence was confined to multiple pulmonary metastases and the brain metastases in the right frontal lobe. To evaluate resistance mechanisms, bronchoscopic rebiopsy was performed, for which the cobas[®] *EGFR* Mutation Test v2 (Roche Molecular Systems) was used, and results showed the emergence of an *EGFR* T790M mutation. Therefore, osimertinib (80 mg once daily) was started. After 16 days of osimertinib treatment, she developed acute shortness of breath on exertion. A CT scan showed a very small area of ground-glass opacity in the right lung (Fig. 1). It was likely that osimertinib-induced interstitial lung disease (ILD) developed; therefore, osimertinib was discontinued. After one week of careful observation, a CT scan showed disappearance of the shadow in the apex of the right lung and no new findings. However, shortness of breath on exertion persisted. Although she had no chest pain, leg pain, hemodynamic instability, and abnormalities on echocardiography, PE was considered. The D-dimer level was as high as 37.7 µg/mL, and a subsequent contrast CT scan showed a thrombus in both pulmonary arteries (Fig. 2A) and the vein of the lower extremities. She was immediately given apixaban, a direct inhibitor of factor Xa. After one month, dyspnea completely disappeared and the D-dimer values normalized, however, neurological deterioration occurred

Abbreviations: EGFR, epidermal growth factor receptor; ILD, interstitial lung disease; VTE, venous thromboembolism.

* Corresponding author. Department of Thoracic Malignancy, Osaka Prefectural Medical Center for Respiratory and Allergic Diseases, 3-7-1 Habikino, Habikino City, Osaka, 583-8588, Japan.

E-mail address: takayuki.s12@hotmail.co.jp (T. Shiroyama).

<http://dx.doi.org/10.1016/j.rmcr.2016.11.009>

2213-0071/© 2016 The Authors. Published by Elsevier Ltd. This is an open access article under the CC BY-NC-ND license (<http://creativecommons.org/licenses/by-nc-nd/4.0/>).

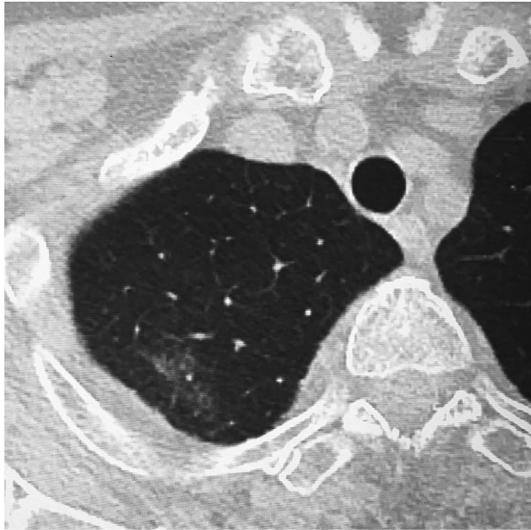


Fig. 1. Computed tomography scan of the right lung. A very small area of ground-glass opacity is observed in the apex of the right lung after 16 days of osimertinib treatment.

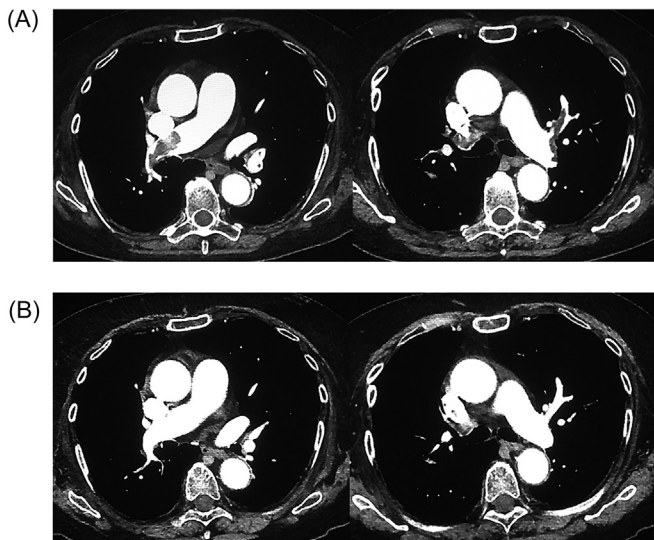


Fig. 2. Contrast computed tomography (CT) scan of the pulmonary arteries. A thrombus is shown in both pulmonary arteries (A). A contrast CT scan 2 months from starting anticoagulant treatment showing no evidence of a thrombus (B).

rapidly. We retreated her with osimertinib (80 mg daily) after receiving full informed consent for the risk of recurrent VTE, because no alternative treatment was available. One month later, a contrast CT and MRI scan showed disappearance of the thrombus (Fig. 2B) and partial remission of multiple pulmonary and brain metastases. As a result, her neurological symptoms improved. Currently, she is being treated with osimertinib and apixaban for 4 months without major adverse events.

3. Discussion

VTE is a disease that includes DVT and PE, and DVT is the cause of PE in more than 90% of patients. Cancer and chemotherapy are the main risk factors for VTE, and VTE is considered an important potential risk of osimertinib treatment, based on the finding that the most common Grade 3–4 adverse reaction in the AURA study was pulmonary embolism (2.4%, 6/253) [1]. Cancer-associated

thrombosis is characterized by multiple pathophysiological mechanisms, and cancer biology and thrombus formation are interconnected; however, the precise mechanism of VTE induced by osimertinib remains unknown [2]. PE can be life-threatening, and it is challenging to diagnose because of its nonspecific signs and symptoms. Furthermore, PE is largely undiagnosed because clinical suspicion is not raised in most instances. In fact, the patient presented in this case had no obvious signs of VTE and was considered low probability for VTE according to the Wells criteria [3]. Therefore, clinical suspicion is important to make an early diagnosis of VTE. A recent report has shown that in patients diagnosed with acute symptomatic PE, concomitant DVT was significantly associated with increased 30-day mortality [4]. The diagnosis of PE should be suspected in cancer patients with respiratory symptoms unexplained by an alternative diagnosis. It is difficult to differentiate between tumor embolism and thromboembolism. Pulmonary wedge aspiration cytology has been reported to be useful in the diagnosis of pulmonary tumor embolism [5,6]. In our case, we think that pulmonary embolism was caused by the thrombus induced by osimertinib and not from the metastatic lung cancer, because the thrombus immediately disappeared only after anticoagulation therapy. The tiny shadow that was found via CT on day 16 of osimertinib treatment was thought to result from VTE. Ground-glass opacity of the lung is sometimes seen in patients with acute PE, and this may be explained by decreased blood flow and bronchoconstriction [7].

According to the American Society of Clinical Oncology guideline for VTE prevention, hospitalized patients with cancer may be considered for pharmacologic thromboprophylaxis in the absence of bleeding or other contraindications [8]. In practice, adherence to this guideline seems to still be low because of the additional bleeding risk associated with anticoagulant treatment and interaction between drugs. Previous studies have shown that prophylaxis for VTE is rarely used in patients undergoing treatment for cancer [9,10].

To our knowledge, this is the first report of successful retreatment with osimertinib after the development of osimertinib-induced VTE. Considering that VTE is associated with a high mortality, physicians should be aware of the possibility of such a severe adverse event as well as ILD during treatment with osimertinib, and retreatment with osimertinib must be carefully chosen based on the balance of a patient's risk and benefit. This case suggests that retreatment with osimertinib after osimertinib-induced PE may be a treatment option when alternative therapeutic options are limited.

Conflict of interest statement

None declared.

Funding

None.

References

- [1] P.A. Jänne, J.C. Yang, D.W. Kim, et al., AZD9291 in EGFR inhibitor-resistant non-small-cell lung cancer, *N. Engl. J. Med.* 372 (2015) 1689–1699.
- [2] G.H. Lyman, A.A. Khorana, Cancer, clots and consensus: new understanding of an old problem, *J. Clin. Oncol.* 27 (2009) 4821–4826.
- [3] P.S. Wells, D.R. Anderson, M. Rodger, et al., Derivation of a simple clinical model to categorize patients probability of pulmonary embolism: increasing the models utility with the SimpliRED D-dimer, *Thromb. Haemost.* 83 (2000) 416–420.
- [4] C. Becattini, A.T. Cohen, G. Agnelli, et al., Risk stratification of patients with acute symptomatic pulmonary embolism based on presence or absence of lower extremity DVT: systematic review and meta-analysis, *Chest* 149 (2016)

- 192–200.
- [5] Bhuvaneshwaran JS1, C.G. Venkitachalam, S. Sandhyamani, Pulmonary wedge aspiration cytology in the diagnosis of recurrent tumour embolism causing pulmonary arterial hypertension, *Int. J. Cardiol.* 39 (1993) 209–212.
- [6] A. Abati, D. Landucci, R.L. Danner, D. Solomon, Diagnosis of pulmonary microvascular metastases by cytologic evaluation of pulmonary artery catheter-derived blood specimens, *Hum. Pathol.* 25 (1994) 257–262.
- [7] S. Matsuoka, Y. Kurihara, K. Yagihashi, H. Niimi, Y. Nakajima, Quantification of thin-section CT lung attenuation in acute pulmonary embolism: correlations with arterial blood gas levels and CT angiography, *AJR Am. J. Roentgenol.* 186 (2006) 1272–1279.
- [8] G.H. Lyman, A.A. Khorana, N.M. Kuderer, et al., Venous thromboembolism prophylaxis and treatment in patients with cancer: American Society of Clinical Oncology clinical practice guideline update, *J. Clin. Oncol.* 31 (2013) 2189–2204.
- [9] C.C. Kirwan, E. Nath, G.J. Byrne, C.N. McCollum, Prophylaxis for venous thromboembolism during treatment for cancer: questionnaire survey, *BMJ* 327 (2003) 597–598.
- [10] S.R. Kahn, A. Panju, W. Geerts, et al., Multicenter evaluation of the use of venous thromboembolism prophylaxis in acutely ill medical patients in Canada, *Thromb. Res.* 119 (2007) 145–155.