OMCR

Oxford Medical Case Reports, 2019;4, 120–123

doi: 10.1093/omcr/omz013
Case Report

CASE REPORT

A case of pulmonary tuberculosis diagnosed in a patient with manifestations of haemophagocytic lymphohistiocytosis

Shinya Ohata[1], Kenta Hara[2], Takashi Arai[3], Tomofumi Takayoshi[2], Katsuhito Nishiyama[3], Yoshiro Yasutomo[3], Koichi Yokono[3] and Takeshi Sugimoto[1,*]

[1]Department of Hematology and Oncology, Kita-Harima Medical Center, Hyogo, Japan, [2]Department of Diabetes and Endocrinology, Kita-Harima Medical Center, Hyogo, Japan, and [3]Department of General and Geriatric Internal Medicine, Kita-Harima Medical Center, Hyogo, Japan

*Correspondence address. Department of Hematology and Oncology, Kita-Harima Medical Center, Zip 675-1392, 926-250 Ichiba-cho, Ono City, Hyogo, Japan. Tel: +81-794-88-8800; Fax: +81-794-62-9931; E-mail: takeshi_sugimoto@kitahari-mc.jp

Abstract

An 80-year-old woman was admitted with continuous fever, hepatic dysfunction and cytopaenia. The presence of hepatosplenomegaly, hyperferritinaemia, hypofibrinogenaemia and phagocytosis by macrophages in the bone marrow was consistent with a diagnosis of haemophagocytic lymphohistiocytosis (HLH). We suspected that HLH was induced by pre-existing tuberculosis, and antitubercular agents were started. Positive nucleic acid amplification and sputum culture for *Mycobacterium tuberculosis* resulted in a diagnosis of pulmonary tuberculosis. The patient improved with three months of treatment. In this patient, manifestations of HLH preceded those of pulmonary tuberculosis. A diagnosis of HLH should increase suspicion of disseminated tuberculosis and thus contribute to early detection.

INTRODUCTION

Haemophagocytic lymphohistiocytosis (HLH) follows macrophage activation and is accompanied by hypercytokinaemia. In bacteria-associated HLH, the elimination of infected cells by immunocompetent cells such as cytotoxic T cells or natural killer cells is dysfunctional. In this condition, hyperimmunisation for infected cells is sustained and inflammatory cytokines are produced by immunocompetent cells at an abnormal level. This cytokine storm will activate macrophages, resulting in HLH state [1, 2], presenting with fever, rash, hepatosplenomegaly, coagulation abnormalities and neurological symptoms [3]. Haemophagocytosis is observed in reticuloendothelial tissues including the bone marrow, lymph nodes, liver or spleen. In adults, HLH may be associated with infection, malignancy, rheumatologic disorders or immunodeficiency syndromes. The state of HLH as an initial manifestation of tuberculosis infection is rarely seen, as the incidence is 0.3–0.8% [4, 5]. In this patient, secondary HLH occurred following a pulmonary tuberculosis infection. Thus, a diagnosis of HLH contributes to early detection of pulmonary tuberculosis.

Received: January 9, 2018. **Revised:** January 5, 2019. **Accepted:** January 31, 2019

© The Author(s) 2019. Published by Oxford University Press.
This is an Open Access article distributed under the terms of the Creative Commons Attribution Non-Commercial License (http://creativecommons.org/licenses/by-nc/4.0/), which permits non-commercial re-use, distribution, and reproduction in any medium, provided the original work is properly cited. For commercial re-use, please contact journals.permissions@oup.com

CASE PRESENTATION

In the summer of 2014, an 80-year-old woman complaining of a 2-week fever despite antibiotic therapy was admitted to a local hospital. She had a history of cervical disc herniation and mitral valve insufficiency. Laboratory tests revealed hepatic dysfunction and cytopaenia, and she was transferred to our hospital for further evaluation. On admission, we noted purpura of the skin and conjunctival appearance consistent with anaemia. The liver margin was palpable at a finger breadth below the central costal margin, and physical examination revealed no other abnormalities. Her blood pressure was 98/68 mmHg, pulse rate was 84 beats/min, body temperature was 37.8°C, and respiratory rate was 16 breaths/min. The blood count revealed pancytopenia, with 15.4 × 10^2 /μl white blood cells (WBC; normal range: 35–97 × 10^2 /μl), 10.7 g/dl haemoglobin (Hb; normal range: 10.8–14.9 g/dl) and 4.5 × 10^4 platelets/μl (normal range: 14–37 × 10^4 /μl). The activated partial thromboplastin time was 69.9 s (normal range: 24–39 s), prothrombin time was 16.8 s (normal range: 10.5–14.0 s) and fibrinogen level was 36 mg/dL (normal range: 186–355 mg/dl), indicating prolongation of coagulation index and severe hypofibrinogenaemia. Serological testing revealed values of 296 IU/L aspartate aminotransferase (AST; normal range: 13–33 IU/l), 2.3 mg/dl total bilirubin (normal range: 0.2–1.3 mg/dl), 0.74 mg/dl C-reactive protein (CRP; normal range: ≦0.3 mg/dl), 3 267 IU/l lactate dehydrogenase (normal range: 119–229 IU/l), 125,180 ng/ml ferritin (normal range: 12–60 ng/ml) and 9880 U/ml serum Interleukin-2 (IL-2) receptors (normal range: 145–519 U/ml) (Table 1). Chest computed tomography (CT) revealed a granular shadow in the lower lung field. An abdominal CT scan also revealed conspicuous hepatosplenomegaly (Fig. 1A). Haemophagocytosis was observed in the bone marrow specimen, but there were no signs of haematological malignancy, such as myelodysplastic syndromes or leukaemia (Fig. 1B). The clinical signs, including high fever,

Table 1: Laboratory data on admission

White blood cells	15.4	×10^2/μl	Total bilirubin	2.3	mg/dl
Neutrophil	78	%	BUN	29.2	mg/dl
Monocyte	3	%	Creatinine	0.79	mg/dl
Lymphocyte	18	%	Na	138	mEq/l
Eosinophil	0	%	K	4.3	mEq/l
Basophil	1	%	Cl	101	mEq/l
Red blood cells	384	×10^4/μl	CRP	0.74	mg/dl
Haemoglobin	10.7	g/dl	BS	91	mg/dl
MCV	81.3	fL	Ferritin	125,180	ng/ml
Platelet	4.5	×10^4/μl	PT	16.8	sec.
AST	37	IU/l	PT-INR	1.78	
ALT	296	IU/l	APTT	69.9	sec.
LD	3267	IU/l	Fibrinogen	36	mg/dl
ALP	37	IU/l	FDP	13.4	μg/ml
γGTP	105	mg/dl	sIL-2R	9880	U/ml

MCV, mean corpuscular volume; AST, aspartate aminotransferase; ALT, alanine aminotransferase; LD, lactate dehydrogenase; ALP, alkaline phosphatase; γGTP, gamma-glutamyltransferase; BUN, blood urea nitrogen; CRP, C-reactive protein; PT, prothrombin time; PT-INR, prothrombin time-international normalized ratio; APTT, activated partial thromboplastin time; FDP, fibrin degradation products; sIL-2R, soluble interleukin-2 receptor.

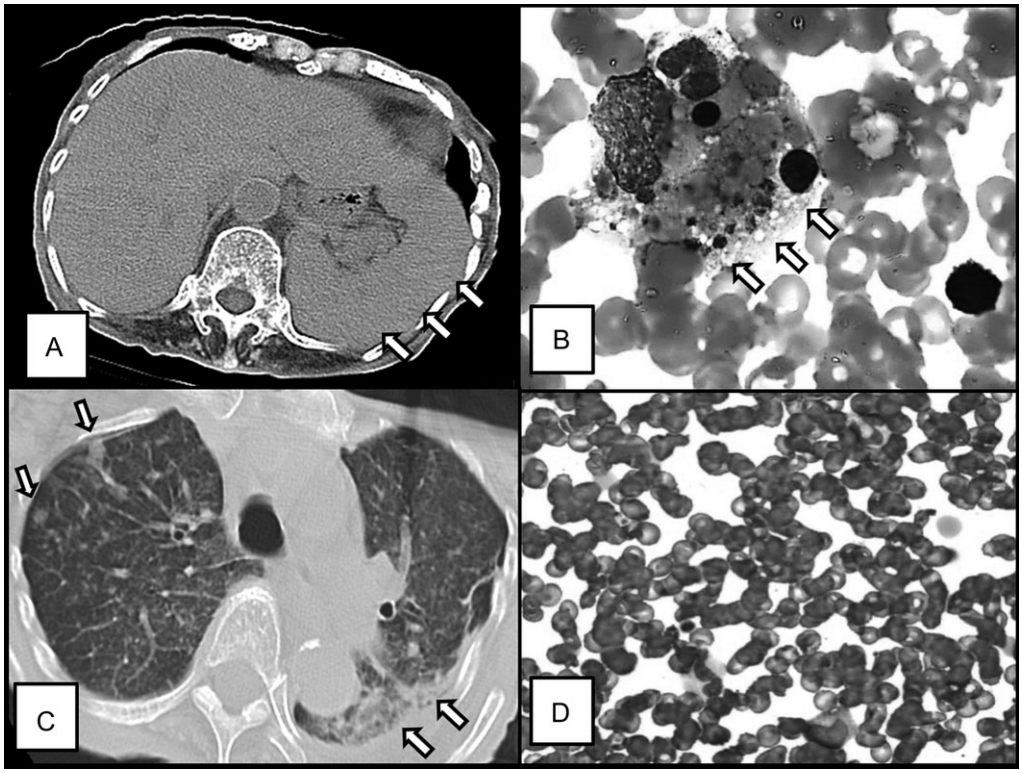

Figure 1: (**A**) Marked splenomegaly (arrow) and hepatomegaly are shown in this CT scan. (**B**) Bone marrow aspirate obtained on admission. (haematoxylin and eosin × 600). The arrow indicates a haemophagocytic cell. (**C**) CT scan of the middle lung field showing a granular shadow extending to the left middle area (arrow). (**D**) Bone marrow aspirate obtained 3 months after starting tuberculosis treatment. (haematoxylin and eosin × 200). No haemophagocytic cells were evident.

Table 2: Tuberculosis-induced HLH

Age (years)	54 (average)
Sex (female)	14/37 (38%)
Fever	39/39 (100%)
Splenomegaly	19/39 (49%)
Thrombocytopenia	29/35 (83%)
Secondary HLH	21/39 (54%)
Under treatment with immunosuppressive drugs	22/39 (56%)
Disseminated tuberculosis	20/37 (54%)
Fatal outcome	19/39 (49%)

The data summarizes the findings of 39 case reports of HLH accompanied by tuberculosis [7–13].

splenomegaly, cytopaenia affecting two lineages, hypofibrinogenaemia, haemophagocytosis in the bone marrow, hyperferritinaemia, and elevation of serum IL-2 receptors, satisfied the criteria for a diagnosis of HLH [3].

We speculated that the remarkable hepatosplenomegaly and hepatodysfunction were caused by the tuberculosis infection. As there was a possibility that HLH was induced by tuberculosis infection, an antitubercular drug regimen of isoniazid, rifampicin, ethambutol and pyrazinamide was started on day 3 after obtaining samples for culture and nucleic acid amplification testing for mycobacterial tuberculosis. The patient's respiratory status included transient hypoxia, which responded to oxygen administration. To investigate the cause of the hypoxia, we examined the chest CT scan again, and observed a granular shadow spreading to the middle lung field (Fig. 1C). As pneumocystis or fungal pneumonia could not be definitively excluded, sulfamethoxazole/trimethoprim and antifungal drugs were administered. Considering a possible exacerbation of HLH, methylprednisolone pulse therapy (500 mg/day) was started on day 4. A liver biopsy to identify the cause of HLH was not performed due to her high bleeding risk, as reflected by her low platelet count.

Results of the nucleic acid amplification test and acid-fast staining of sputum obtained on day 5 confirmed the presence of *Mycobacterium tuberculosis* (*M. tuberculosis*). Her final diagnosis was pulmonary tuberculosis with tuberculosis-induced HLH. The antituberculosis therapy was continued and acid-fast staining was negative on day 21. The abnormal findings of cytopaenia, liver dysfunction and granular shadow in the lung improved after 1 month. Haemophagocytosis of the bone marrow was resolved after 3 months of antituberculosis therapy (Fig. 1D), and the pulmonary tuberculosis was considered cured. The patient was transferred to her local hospital to continue tuberculosis therapy and observation.

DISCUSSION

The first report of HLH was in 1939 by Scott and Robb-Smith [6]. The clinical manifestations and organ dysfunction characteristic of HLH are caused by a severe inflammatory response to a hereditary or acquired trigger [1, 4]. The primary symptoms are fever, hyperferritinaemia, organomegaly and cytopaenia. The key pathological finding is haemophagocytosis in any tissue. This patient experienced fever, splenomegaly, cytopaenia affecting two lineages, hypofibrinogenaemia, haemophagocytosis in the bone marrow, hyperferritinaemia, and elevation of serum IL-2 receptors, all of which are consistent with the 2004 criteria for HLH [3]. Secondary HLH is caused by infection, malignancy, rheumatologic disorders or immunodeficiency syndromes [1, 4]. Approximately 70% of infectious HLH cases are caused by viruses, and the Epstein–Barr virus is predominant. Bacterial infection comprises about 18% of infection-caused HLH, with tuberculosis involved in 7% of HLH cases [3].

Table 2 summarizes 39 HLH case reports accompanied by tuberculosis [7–13]. Splenomegaly seems to occur less frequently in tuberculosis-induced HLH than other types of secondary HLH; no other specific associations were found in those reports. Tuberculosis-induced HLH was often reported in patients younger than 65 years of age. Disseminated tuberculosis was reported in 54% of tuberculosis-induced HLH cases and involved the lungs (50%), bone marrow (32%), lymph nodes (32%) and liver (24%). Tuberculosis involved the extrapulmonary regions in 76% of cases, and about half of those cases had only extrapulmonary involvement. For that reason, a diagnosis of extrapulmonary tuberculosis involving the bone marrow, lymph nodes, or liver should increase suspicion of tuberculosis-induced HLH. A previous report noted that administration of immunosuppressive drugs for tuberculosis-induced HLH with no pulmonary findings worsened the patient's condition [14].

There is a limitation that warrants discussion. A liver biopsy was not performed due to a relative contraindication of low platelet count. The resulting liver biopsy could have provided useful information to decide if this patient has disseminated tuberculosis or not.

In conclusion, a diagnosis of HLH contributed to the early detection and treatment of pulmonary tuberculosis. If tuberculosis-induced HLH is suspected, evaluation of extrapulmonary regions should be performed. Findings of HLH in a patient with clinical and radiographic evidence of tuberculosis should raise suspicion of disseminated tuberculosis.

ACKNOWLEDGEMENTS

The authors would like to thank Enago (www.enago.jp) for their English language review.

CONFLICT OF INTEREST STATEMENT

The authors have no conflicts of interest.

FUNDING

No funding was provided.

ETHICAL APPROVAL

Ethical approval was not required.

CONSENT

The patient gave her written informed consent.

GUARANTOR

Dr Takeshi Sugimoto

REFERENCES

1. Ramos-Casals M, Brito-Zerón P, López-Guillermo A, Khamashta MA, Bosch X. Adult haemophagocytic syndrome. *Lancet* 2014;**383**:1503–16.
2. Akashi K, Hayashi S, Gondo H, Mizuno S, Harada M, Tamura K, *et al.* Involvement of interferon-gamma and macrophage colony-stimulating factor in pathogenesis of haemophagocytic lymphohistiocytosis in adults. *Br J Haematol* 1994;**87**:243–50.

3. Henter JI, Horne A, Aricó M, Egeler RM, Filipovich AH, Imashuku S, *et al*. HLH-2004: diagnostic and therapeutic guidelines for hemophagocytic lymphohistiocytosis. *Pediatr Blood Cancer* 2007;**48**:124–31.
4. Ishii E, Ohga S, Imashuku S, Yasukawa M, Tsuda H, Miura I, *et al*. Nationwide survey of hemophagocytic lymphohistiocytosis in Japan. *Int J Hematol* 2007;**86**:58–65.
5. Wang JY, Hsueh PR, Lee LN, Liaw YS, Shau WY, Yang PC, *et al*. Mycobacterium tuberculosis inducing disseminated intravascular coagulation. *Thromb Haemost* 2005;**93**:729–34.
6. Scott RB, Robb-Smith AHT. Histiocytic medullary reticulosis. *Lancet* 1939;**234**:194–8.
7. Su NW, Chen CK, Chen GS, Hsieh RK, Chang MC. A case of tuberculosis-induced hemophagocytic lymphohistiocytosis in a patient under hemodialysis. *Int J Hematol* 2009;**89**:298–301.
8. Fujiki R, Shiraishi K, Noda K, Ohshita Y, Fukahori S, Johjima H, *et al*. A case of hemophagocytic syndrome associated with miliary tuberculosis. *Kekkaku* 2003;**78**:443–8. (Article in Japanese).
9. Brastianos PK, Swanson JW, Torbenson M, Sperati J, Karakousis PC. Tuberculosis-associated haemophagocytic syndrome. *Lancet Infect Dis* 2006;**6**:447–54.
10. Yoshimoto A, Fujimura M, Nakamura H, Nakao S. A case of hemophagocytic syndrome caused by tuberculosis. *Ann Jpn Res Soc* 2002;**11**:889–93. (Article in Japanese).
11. Machida H, Shinohara T, Hatakeyama N, Okano Y, Nakano M, Tobiume M, *et al*. A case of miliary tuberculosis with pancytopenia showing positive blood culture for mycobacterium tuberculosis. *Iryo* 2011;**65**:618–22. (Article in Japanese).
12. Oyaizu H, Yosimura C, Wakayama T, Okamoto K, Imanaka M, Kubo Y, *et al*. Hemophagocytic syndrome associated with tuberculosis and mycoplasma infection in two patients. *Ann Jpn Res Soc* 1998;**36**:787–91. (Article in Japanese).
13. Inoue T, Katsuragi T, Kunimoto M, Ichino I, Tanaka S, Hamada T, *et al*. A case of miliary tuberculosis with type 2 diabetes mellitus complicated with hemophagocytic syndrome, disseminated intravascular coagulation, acute respiratory distress syndrome and acute renal failure. *J Japan Diab Soc* 2010;**53**:699–705. (Article in Japanese).
14. Dilber E, Erduran E, Kalyoncu M, Aynaci FM, Okten A, Ahmetoğlu A. Hemophagocytic syndrome as an initial presentation of miliary tuberculosis without pulmonary findings. *Scand J Infect Dis* 2002;**34**:689–92.