

# Correcting Nipple Inversion Simultaneously with Implant Augmentation of the Breast, Using “Pirelli” Technique

Kishen Nara, MBBS  
Darryl Hodgkinson, MBBS  
(Honors II), FRCS(C), FACS

**Background:** Most techniques of isolated nipple inversion correction are well published. Simultaneous breast augmentation with nipple inversion correction is less often found in the literature. Previously, nipple inversion correction was thought to be performed as a staged procedure after other breast operations. We present a study of 19 patients and 34 breasts who had concomitant breast augmentation and nipple inversion correction treated with a “Pirelli” technique to assess the complication rates and the rate of recurrence of inversion.

**Methods:** The Pirelli technique was used, involving division of lactiferous ducts and deep closure of breast tissue before closure. An external “Pirelli tire” was then applied and secured circumferentially around the nipple–areolar complex, which helped to maintain eversion of the nipple after 1 week. Patients were then followed up with specific postoperative instructions to ensure wound healing and maintenance of eversion.

**Results:** Nineteen patients were included where 34 breasts were involved. Eighteen patients had primary breast implants. The recurrence rate was 5.9%, involving 2 patients who had unilateral recurrences. These patients were managed with the same technique and had no further recurrences. Two patients successfully breastfed at a median time of 10 years postoperatively.

**Conclusion:** Simultaneous breast mammoplasty with nipple inversion correction using the Pirelli technique is safe with low complication rates and high long-term patient satisfaction. (*Plast Reconstr Surg Glob Open* 2020;8:e3004; doi: 10.1097/GOX.0000000000003004; Published online 27 July 2020.)

## INTRODUCTION

Nipple inversion was first described by Cooper<sup>1</sup> in 1840. It has a prevalence rate of up to 8.93% of the population.<sup>2</sup> Isolated benign cases are as common as 1.7%–3.5% as described by various authors.<sup>3–6</sup> The pathophysiology of it is predominantly congenital. Rare causes may involve mastitis, previous breast operations, or even cancer. The histology of the inversion involves failure of the mesenchyma/parenchyma to mature, hence the formation of dense fibrous strictures that invaginate the nipple.<sup>3</sup> Fibromuscular connections that accompany lactiferous ducts, insert into the nipple dermis causing nipple inversion.<sup>7</sup> Different classifications and varying nipple–areolar complex dimensions have been described<sup>3,8–10</sup> These grading systems assist with various treatment options.

Historically, patients sought cosmetically improved nipple inversion correction, but also considered its hygiene and potentially breastfeeding benefits.<sup>11</sup>

## Techniques for Correction

Nipple inversion correction techniques are well described in the literature, primarily since the early description by Kehrer<sup>12</sup> in 1879. Since then a constellation of techniques evolved, involving purse string sutures, local flaps, dermal grafts, autografts, blocking notches, implant insertion with biodegradable polydioxanone, injectable fillers, and external devices to maintain eversion.<sup>13–28</sup> Lactiferous preserving techniques have also been used.<sup>7,23</sup> Loop magnification and endoscopic techniques to release tight fibrous bands have been described.<sup>29,30</sup>

External distraction techniques may have led to contracture from nondivision of the lactiferous ducts. This possibly leads only a minority to breastfeed.<sup>11</sup> The “Drawbridge” Flap dermal areolar pedicle technique resulted in excellent nipple sensitivity; however, it was not confirmed that there was successful milk expression in the

From the Cosmetic and Restorative Surgery Clinic, Sydney, Australia.

Received for publication January 1, 2020; accepted May 26, 2020.

Copyright © 2020 The Authors. Published by Wolters Kluwer Health, Inc. on behalf of The American Society of Plastic Surgeons. This is an open-access article distributed under the terms of the Creative Commons Attribution-Non Commercial-No Derivatives License 4.0 (CCBY-NC-ND), where it is permissible to download and share the work provided it is properly cited. The work cannot be changed in any way or used commercially without permission from the journal.

DOI: 10.1097/GOX.0000000000003004

**Disclosure:** The authors have no financial interest to declare in relation to the content of this article.

patients who consequently breastfed.<sup>31</sup> A drawback of this technique is nipple–areolar distortion.

Surgical techniques can be categorized into either lactiferous sacrificing or preserving techniques. However, there are no statistical significant conclusions of recurrences between techniques that can be drawn from a recent systemic review given the small sample sizes and heterogeneity of studies.<sup>6</sup> Their principles involve preservation of blood supply, preservation of lactiferous ducts, and maintenance of projection. Despite enormous techniques in the literature, the recurrence rates are notably considerable up to 22% with an average of 9.9% per nipple involving most grades of nipple inversion severity. The overall complication rate being 10%.<sup>6,9</sup>

**Combining Augmentation and Nipple Inversion Correction**

The nipple–areolar complex is a vital component to the breast aesthetic, particularly in the setting of breast augmentation. Simultaneous nipple inversion with breast augmentation is less often seen in the literature.<sup>21</sup> Gould described a technique in which 5 of the 191 nipple inversion correction cases had concurrent breast augmentation.<sup>21</sup> It was previously thought that nipple inversion correction should be performed as a staged procedure if other breast procedures such as augmentation or breast reduction were needed.<sup>2</sup> This was because of the perceived additive complication rates.

We present our study on 19 patients who had concomitant breast augmentation with nipple inversion correction using a carefully designed “Pirelli” technique with the aim to analyze complications and recurrence rates of nipple inversion. We then compared this to the established literature on complication rates of isolated nipple inversion correction.

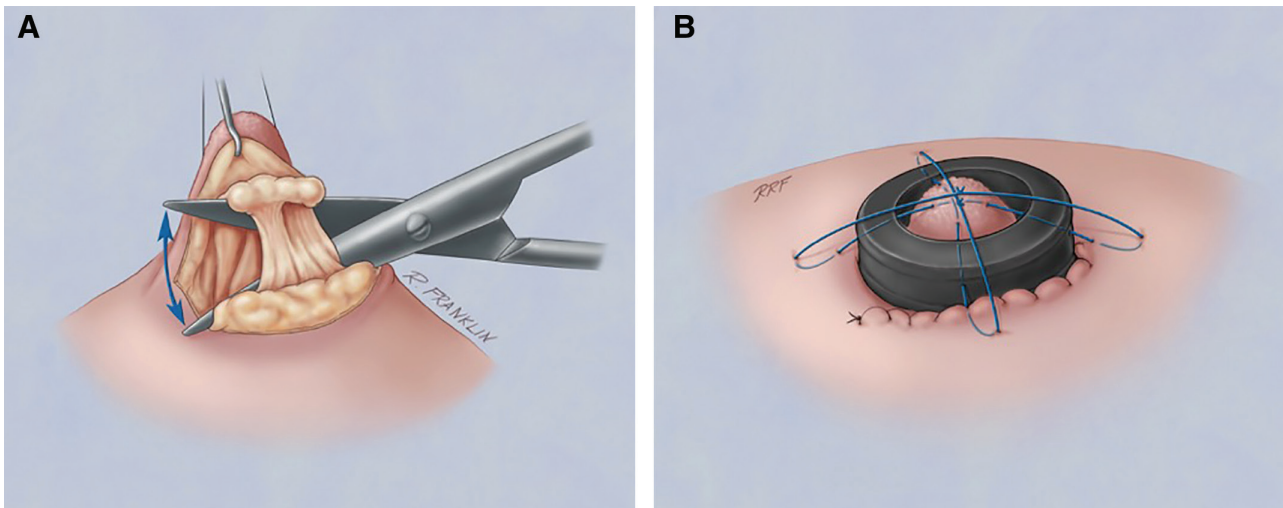
**METHODS**

The inclusion criteria for our study were all patients who had simultaneous nipple inversion correction with

simultaneous breast augmentation with implants performed by the same surgeon from 2006 to 2017. These patients had nipple inversion of grade 2 or 3 in keeping with the classification by Gould and Stevens,<sup>9</sup> where nipple inversion is not easily protracted. Specifically, grade 2 is where the inverted nipple can be protracted, but the projection remains to be inverted. Grade 3 is where the nipple is severely inverted. The exclusion criteria were all isolated nipple inversion cases or simultaneous aesthetic procedures not of the breast. Epidemiologic, clinical, and documented follow-up data were then analyzed up to 6 months. An interim analysis of patients of childbearing age was performed via verbal assessment to assess breastfeeding functionality at a median time of 10 years from surgery.

The senior author used a specific Pirelli tire technique. Virtually an internal component or metaphorically the wheel was used as the base to bolster up the nipple. The external component involved a tire in maintaining the eversion and projection of the nipple. First, the nipple base was infiltrated with xylocaine and adrenaline. Then, a silk suture was used to maintain eversion of the nipple. A small semilunar incision inferior to the nipple–areolar junction was made. The tight fibrotic strands, very frequently associated with the tight lactiferous ducts, were divided carefully to preserve as many ducts as possible. The spreading motion of the scissors accomplished this, being parallel to the axis of the lactiferous ducts. The endpoint was the successful eversion of the nipple, and the remaining lactiferous ducts were preserved. The description above depicts the selective division of the ducts where once nipple eversion was achieved; the remaining ducts were preserved. The breast tissue was then bolstered underneath with a 5-0 chromic suture before closure.

The external Pirelli tire was then applied and secured circumferentially at 4 right angle corners around the nipple–areolar complex with a 3-0 nylon suture. This helped



**Fig. 1.** The “Pirelli” surgical technique illustration. A, The inverted nipple everted with a silk suture. Selective tight lactiferous ducts responsible for nipple inversion were divided longitudinally or parallel to the axis of the ducts until satisfactory nipple eversion is achieved via a semilunar incision at the nipple–areolar junction. Followed by bolstering the nipple with the closure of the breast tissue with absorbable sutures. B, Pirelli tire applied externally over and within the circumference of nipple. This was secured with a nylon suture.

maintain nipple eversion. The “Pirelli ring” remained for a period of a week to 10 days before removal (Fig. 1).

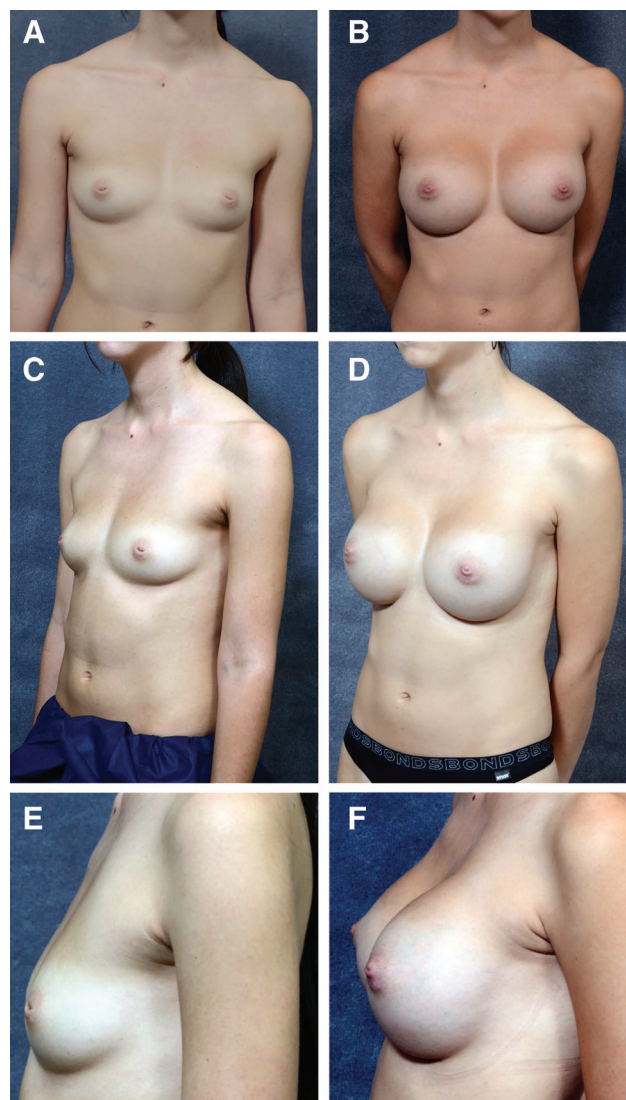
The Pirelli tire is the sterile rubber plunger seal of a 20-mL syringe contoured to accommodate different respective nipple diameters which are readily available and comfortable on the surface of the skin when interposed with antibiotic Xeroform dressings. Pressure sores are avoided by doing so. Patients are then followed up with specific postoperative instructions to ensure wound healing and maintenance of eversion. A padded dressing was used for a period of 2–3 months postoperatively for comfort. Patients were followed up for 6 months in the clinic.

## RESULTS

Nineteen patients were included, where 34 breasts were involved. Fifteen patients had bilateral nipple inversions, and the remainder 4 were unilateral. Of the 4 unilateral patients, 2 (age: 22 and 28 years) had chest wall deformities. The mean age was 32.8 with a range between 19 and 65 years. Most patients were <45 years old. The mean body mass index was 21.1 kg/m<sup>2</sup> with a range of 17.2–26.7 kg/m<sup>2</sup>. All patients had saline breast implants. Three patients had periareolar mastopexies. Eighteen patients had primary breast implants with a mean volume of 328.2 mL. The mean volume for all patients was 353 mL. Implants were inserted via inframammary incisions. Subpectoral pockets were used in 12 patients, whereas 7 patients had subfascial pockets. Recurrence was 5.9% per nipple. These 2 patients who each had unilateral recurrences returned to theater for reoperation using the same technique. One of the patients who required the reoperation was an active smoker, and the other had breastfed 2 children previously. Both of these patients had subpectoral implants. One patient developed a unilateral eschar (2.9%) and was managed conservatively. She was on aspirin for a previous myocardial infarction. These patients who were managed surgically and conservatively had no further recurrences. No nipple necrosis or infection was seen. All patients had good nipple projection and excellent satisfaction (Fig. 2).

There were no complications relating to the breast augmentation component of surgery specifically, no wound dehiscence, infection, hematoma, or capsular contracture. Further patient details of the study are found in Table 1.

As an interim analysis, all patients of childbearing age under the age of 40 years were contacted verbally via telephone to enquire about satisfaction and success of breastfeeding postoperatively. Five of these 14 patients were successfully contacted via telephone consults, while the other patients had changed numbers and were unable to be contacted. The median time from surgery was 10 years, with a range of 5–15 years. Based on the Likert 5-point scale, patients were asked whether they were either very unsatisfied, unsatisfied, neutral, very satisfied, or extremely satisfied. Four of these patients were extremely satisfied with the outcome of nipple inversion. One patient had a unilateral recurrence which was corrected with the same technique (Fig. 3) and since then was very satisfied. Two patients who had bilateral Pirelli inversion corrections reported that they were able to express milk and breastfeed



**Fig. 2.** Preoperative and 4-month postoperative digital images of a 20-year-old patient who had subpectoral saline implants inserted via inframammary incisions. A, Preoperative frontal view. B, Postoperative frontal view. C, Preoperative left oblique view. D, Postoperative left oblique view. E, Preoperative left lateral view. F, Postoperative left lateral view.

with no issues bilaterally (Fig. 4). One patient was unable to breastfeed because she was unable to express milk.

## DISCUSSION

This pilot study for combined nipple inversion correction and breast augmentation with implants using the Pirelli technique depicts a safe risk profile comparable to that in the literature with per case recurrence of 5.9%. There are clear benefits to the patient involving a single general anesthetic, minimal scarring, and excellent patient satisfaction. In our study of 19 patients, no complications were seen for breast augmentation. However, a higher-powered study with more significant numbers would be good to confirm this finding.

**Table 1. Patient Data, Surgical Details, and Complications**

Age	Grade of Inversion	Side of Nipple Inversion	Surgery	Volume of Implants (mL)	Recurrence	Complications
36	2	Bilateral	Removal and replacement	From previously 590–800	—	—
22	2	Left	Augmentation	350	—	—
54	2	Bilateral	Augmentation	280 right /270 left	—	—
27	3	Bilateral	Augmentation with periareolar mastopexy	275	—	—
65	2	Bilateral	Augmentation	325	—	—
28	2	Right	Augmentation	250	—	—
32	2	Bilateral	Augmentation	410	Yes: unilateral	—
19	2	Bilateral	Augmentation	400	—	—
23	2	Bilateral	Augmentation	325	—	—
22	2	Bilateral	Augmentation	425	—	—
35	3	Bilateral	Augmentation	350	—	—
23	2	Bilateral	Augmentation	325	—	—
45	2	Left	Augmentation with periareolar mastopexy	180 right /220 left	—	—
20	2	Bilateral	Augmentation	300	—	—
30	2	Bilateral	Augmentation with periareolar mastopexy	200 right /375 left	—	—
41	2	Bilateral	Augmentation	450	—	—
27	2	Bilateral	Augmentation	370 right/390 left	—	—
53	2	Right	Augmentation	300	—	Eschar
22	3	Bilateral	Augmentation	280	Yes: bilateral	—

Augmentation denotes primary breast augmentation with implants. Removal and replacement, in this case, implied the patient requested for larger sized implants for deflated upper poles of the breasts.

A possible predisposition for recurrence is smoking, given that the wound healing cascade is reduced, which eventually inhibits stable granulation formation that aids nipple projection. The nicotine oxide derived from smoking promotes vasoconstriction and reduces tissue oxygenation through the stimulation of thromboxane A2 pathway. Therefore, the risks of wound separation dehiscence, infection, and skin necrosis are significantly increased when compared with nonsmokers.<sup>32</sup> Although the sample size was not large enough to confirm this finding, the perceived risks of smoking were certainly a confounding factor.

Chest wall or skeletal deformity may also be a predisposition for patients with unilateral nipple inversion. Fifty percent of the patients in our study who had unilateral nipple inversion had chest wall deformities. Recognition of this would help address any underlying chest wall deformity with the use of solid prefabricated customized implants described by Hodgkinson.<sup>33</sup> This not only masks the defect but improves the aesthetics of the breast. Again, conducting future studies with a larger sample size would be helpful to confirm this finding.

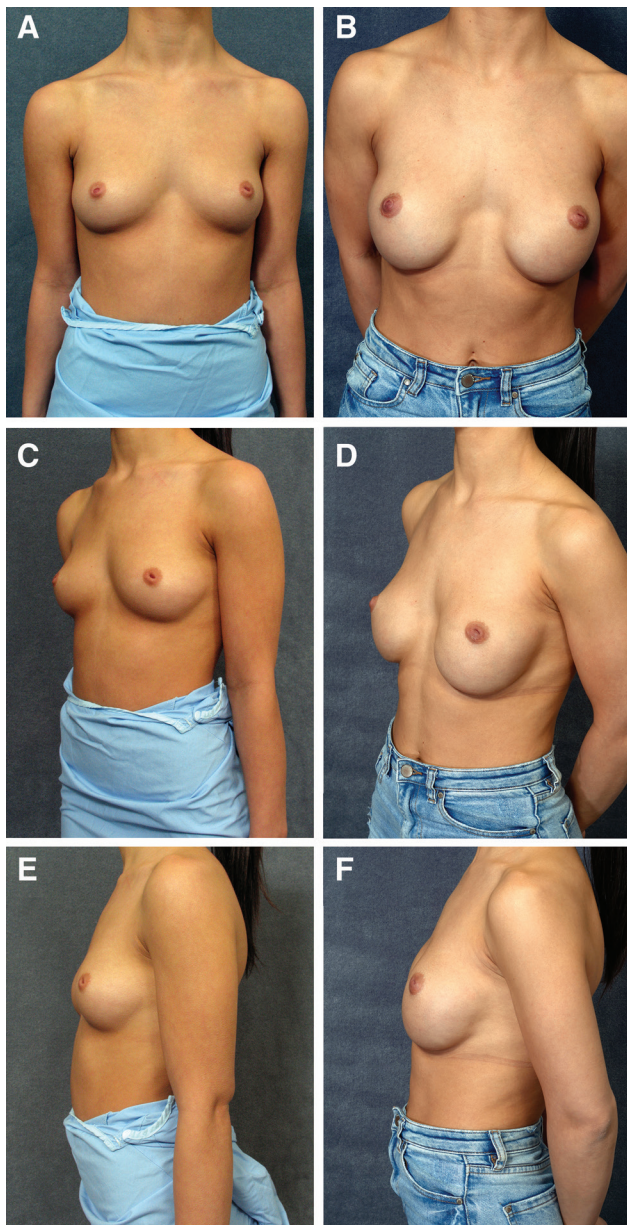
Teimourian<sup>34</sup> had described the increased incidence of nipple inversion in patients with larger breasts and possibly higher body mass index. This was thought to be due to greater subcutaneous fat that causes tension on the nipple, causing failure of the lactiferous ducts to grow. The inverse correlation of our study from the above with a mean body mass index of 21 would be explained by a different patient population seeking breast mammoplasty.

Given that the external component or Pirelli ring is removed around the 1 week mark, patients would feel more comfortable with their activities of daily living such as work, light exercises, or intimacy. It is thought that this period of suspension allows for external suspension of the nipple while allowing the internal nipple tissues to heal with less compression forces. Compliance would be achievable, and self-esteem regained early postoperatively

and maintained for the long term. Also, hygiene issues are addressed soon given that the internal component supports the eversion. Of note, the younger patients in the study did not complain of issues relating to breastfeeding. However, breastfeeding had variable success rates from previous studies, and it is even difficult to predict the likelihood of breastfeeding in patients without any deformity.

It remains a challenge for techniques where external devices are exclusively used because it may at times inconvenience patients for up to 6 months before removal of the device. This may be complicated by mastitis or cellulitis. Major long-term complications have been described, involving chronic pain, fistula around the sutures, and nipple erosion.<sup>35</sup> On the other hand, invasive techniques involving skin flaps, double Z-plasties, V-Y flaps, or alternating glandular flaps may leave unwanted scarring and sometimes recurrences are prominent.<sup>14–18,20</sup> Furthermore, these effective techniques and devices that require prolonged management may not be practical especially for patients who also seek breast mammoplasty. Even a compliant patient may find it difficult to manage this.

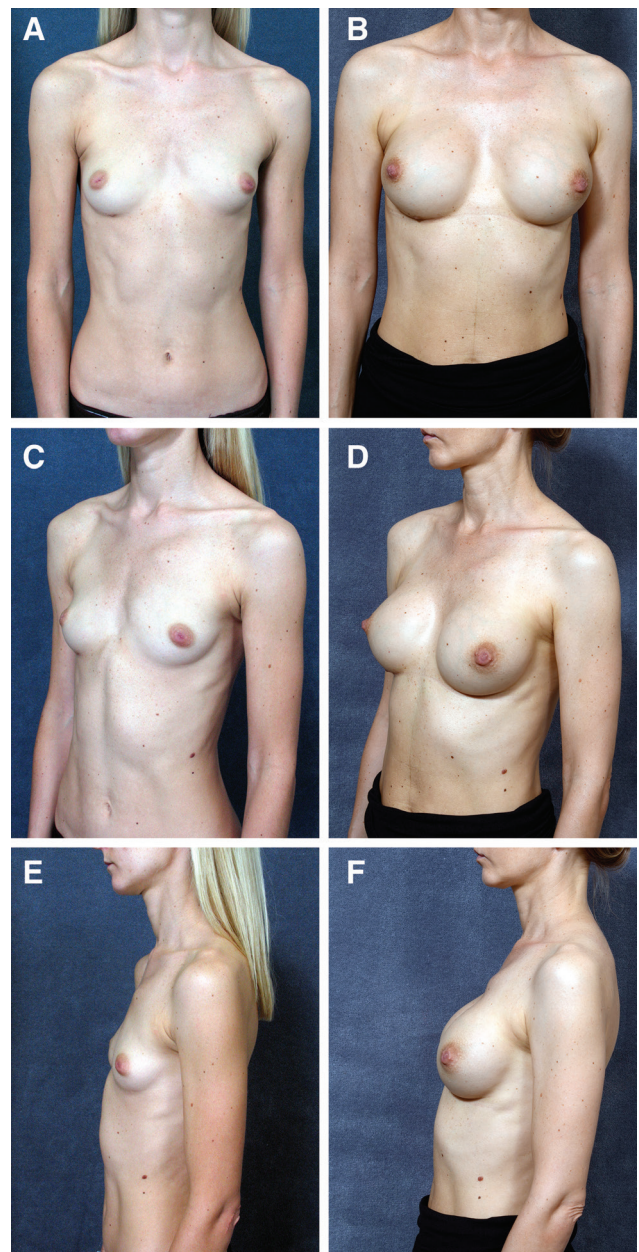
The Pirelli technique combines both the external and internal aspects for nipple inversion correction so that each respective component need not be exaggerated particularly when this is performed simultaneously with breast augmentation. Our study is in support of Namba and Itoh<sup>27</sup> and Cavaggioli et al<sup>36</sup> that compliment internal selective division of the fibrous bands together with external component support.<sup>23</sup> Aiache<sup>37</sup> describes an effective dual internal imbrication method to prevent recurrence. However, the radical eversion and extensive exposure may compromise wound healing and lead to scarring.<sup>38</sup> The inversion correction technique reported by Broadbent and Woolf<sup>39</sup> is similar to the technique used in our study, where in addition to selective scar tissue release the deeper tissue is bolstered to maintain eversion. This reduces internal pressure that may impede on



**Fig. 3.** Preoperative and 11-year postoperative digital images of a 30-year-old patient who had partial subpectoral 280-mL saline implants inserted via inframammary incisions. She had a recurrence of right nipple inversion 6 weeks after the initial surgery, after which it was recorrected with the same Pirelli technique. A, Preoperative frontal view. B, Postoperative frontal view. C, Preoperative left oblique view. D, Postoperative left oblique view. E, Preoperative left lateral view. F, Postoperative left lateral view.

lactiferous duct viability from avoiding the insertion of any pedicle, flap, or substance. A single-stage operation avoids additional anesthetic risks and associated costs to the patient.

The 2 patients who successfully breastfed had implant sizes of 250 and 325 mL, both of which were moderately projected. The patient who was unable to breastfeed had a 400-mL implant of high projection. We can infer that because there are relatively lesser internal releases



**Fig. 4.** Preoperative and 10-year postoperative digital images of a 36-year-old nulliparous patient who had partial subpectoral 250-mL saline implants inserted via inframammary incisions, where she was 3 months postpartum with her third child. She had successfully breastfed all her children. A, Preoperative frontal view. B, Postoperative frontal view. C, Preoperative left oblique view. D, Postoperative left oblique view. E, Preoperative left lateral view. F, Postoperative left lateral view.

performed and omission of graft, pedicle, or substance additions beneath the nipple, this possibly allows for dilation of the unsacrificed lactiferous ducts. However, large and highly projected implants may limit the patient's ability to breastfeed.

Five patients were able to be contacted about satisfaction outcomes 10 years postoperatively. We recognize that this is a small number of patients, but we are encouraged

that 4 patients were extremely satisfied. However, larger scale studies are needed to validate this finding.

To avoid severe complications, a fundamental understanding of their respective causes is vital. Necrosis may occur from excessively tight purse string sutures. Hypopigmentation and disfigurement of areolar may occur from creating flaps. Puckering at the base of the nipple from the above reasons may occur in addition to inadequate fibrous tissue release.<sup>38</sup> Careful patient selection and avoidance of aggressive techniques help minimize these complications. Here, our recurrence rate per nipple was 5.9%, which is comparable to that in the literature of an average of 9.9%.<sup>6,9</sup>

During the study period, there were 79 isolated nipple inversion corrections without breast augmentation. One patient had bilateral elevation of the nipples after having a partial amputation by paper clips during homoerotic sex. The lower recurrence rate is explained by the general age of patients being 10 years older than that of the study group. Here, duct division was more complete, considering the older nonaugmented group.

## CONCLUSIONS

Simultaneous Pirelli technique nipple inversion correction with breast augmentation with implants, when performed as a single-stage operation, has recurrence rates comparable to those in the literature. Therefore, it is crucial to recognize nipple inversion during a preoperative breast augmentation consult, given its common prevalence. More importantly, patients can avoid disappointing results from the misconception that nipple inversion auto-corrects after breast augmentation. There is evidence post Pirelli with mammoplasty that breastfeeding is possible but cannot be guaranteed. Satisfaction outcomes in the long term would need to be confirmed by larger studies.

**Kishen Nara, MBBS**

Cosmetic and Restorative Surgery Clinic  
20 Manning Road  
Double Bay  
New South Wales 2028, Australia  
E-mail: neshique@hotmail.com

## ACKNOWLEDGEMENT

*The study is retrospective; hence, informed consent was previously obtained from all patients who had surgery consistent with the Declaration of Helsinki.*

## REFERENCES

- Cooper A. *Anatomy of the Breast*. London, United Kingdom: Brown and Longmans; 1840.
- Cristenu JM. The correction of inverted nipples without scars: 17 years experience 452 operations. *Aest Plast Surg*. 2000;24:52–57.
- Schwager RG, Smith JW, Gray GF, et al. Inversion of the human female nipple, with a simple method of treatment. *Plast Reconstr Surg*. 1974;54:564–569.
- Park HS, Yoon CH, Kim HJ. The prevalence of congenital inverted nipple. *Aesthetic Plast Surg*. 1999;23:144–146.

- Sanuki J, Fukuma E, Uchida Y. Morphologic study of nipple-areola complex in 600 breasts. *Aesthetic Plast Surg*. 2009;33:295–297.
- Hernandez Yenty QM, Jurgens WJ, van Zuijlen PP, et al. Treatment of the benign inverted nipple: a systematic review and recommendations for future therapy. *Breast*. 2016;29:82–89.
- Pitanguy I. *Aesthetic Plastic Surgery of Head and Body*. New York, N.Y.: Springer-Verlag; 1981.
- Han S, Hong YG. The inverted nipple: its grading and surgical correction. *Plast Reconstr Surg*. 1999;104:389–395; discussion 396.
- Gould DJ, Stevens WG. Correction of the inverted nipple. In: Shiffman MA, ed. *Nipple-Areolar Complex Reconstruction*. Los Angeles, Calif.: Springer; 2018:331–339.
- Bostwick J III. *Aesthetic Reconstructive Breast Surgery*. St. Louis, Mo.: Mosby; 1983.
- Feng R, Li W, Yu B, Zhou Y. A modified inverted nipple correction technique that preserves breastfeeding. *Aesthet Surg*. 2018;39:NP165–NP175.
- Kehrer F. Uber Excision des Warzenhofs bei Hohlwerzen. *Beitr Exp Geburtshilfe Gynaekol Gzessen*. 1879;43:170.
- Skoog T. An operation for inverted nipples. *Br J Plast Surg*. 1953;5:65.
- Axford WL. Mammillaplasty. *Ann Surg*. 1889;9:277–279.
- Grodsky M. Reconstruction des mamelons deformes. *Rev Chir Struc*. 1937;15:126.
- Kim DY, Jeong EC, Eo SR, et al. Correction of inverted nipple: an alternative method using two triangular areolar dermal flaps. *Ann Plast Surg*. 2003;51:636–640.
- Wu HL, Huang X, Zheng SS. A new procedure for correction of severe inverted nipple with two triangular areolar dermofibrous flaps. *Aesthetic Plast Surg*. 2008;32:641–644.
- Lee HB, Roh TS, Chung YK, et al. Correction of inverted nipple using strut reinforcement with deepithelialized triangular flaps. *Plast Reconstr Surg*. 1998;102:1253–1258.
- Kurihara K, Maezawa N, Yanagawa H, et al. Surgical correction of the inverted nipple with a tendon graft: hammock procedure. *Plast Reconstr Surg*. 1990;86:999–1003.
- Ritz M, Silfen R, Morgan D, et al. Simple technique for inverted nipple correction. *Aesthetic Plast Surg*. 2005;29:24–27.
- Teimourian B, Adham MN. Simple technique for correction of inverted nipple. *Plast Reconstr Surg*. 1980;65:504–506.
- Pribaz JJ, Pousti T. Correction of recurrent nipple inversion with cartilage graft. *Ann Plast Surg*. 1998;40:14–17.
- Kolker AR, Torina PJ. Minimally invasive correction of inverted nipples: a safe and simple technique for reliable, sustainable projection. *Ann Plast Surg*. 2009;62:549–553.
- Persichetti P, Poccia I, Pallara T, et al. A new simple technique to correct nipple inversion using 2 V-Y advancement flaps. *Ann Plast Surg*. 2011;67:343–345.
- Gould DJ, Nadeau MH, Macias LH, et al. Inverted nipple repair revisited: a 7-year experience. *Aesthet Surg J*. 2015;35:156–164.
- Stevens WG, Fellows DR, Vath SD, et al. An integrated approach to the repair of inverted nipples. *Aesthet Surg J*. 2004;24:211–215.
- Namba K, Itoh T. Some devices for surgical repair of inverted nipple. *J Plast Surg*. 1966;9:93
- Dessena L, Dast S, Perez S, et al. Inverted nipple treatment and poliglecaprone spacer. *Aesthetic Plast Surg*. 2018;42:958–963.
- Pagkalos V, Ghali S, Heden P. Nipple elevation using loupe magnification and a purse-string suture. *Aesth Plas Surg*. 2013;37:354–358
- Chen SH, Gedebo T, Chen PH. The endoscope as an adjunct to correction of nipple inversion deformity. *Plast Reconstr Surg*. 2007;119:1178–1182.
- Mathur B, Loh CYY. Sensation-sparing correction of inverted nipple using the “drawbridge” flap approach. *Aesth Plast Surg*. 2019;43:348–353

32. Theocharidis V, Katsaros I, Sgouromallis E, et al. Current evidence on the role of smoking in plastic surgery elective procedures: a systematic review and meta-analysis. *J Plast Reconstr Aesthet Surg.* 2018;71:624–636.
33. Hodgkinson DJ. The management of anterior chest wall deformity in patients presenting for breast augmentation. *Plast Reconstr Surg.* 2002;109:1714–1723.
34. Teimourian B. Surgical correction of inverted nipples using the modified Namba or Teimourian technique. *Plast Reconstr Surg.* 2004;113:328–336; discussion 337–338.
35. Yukun L, Ke G, Jiaming S. Application of nipple retractor for correction of nipple inversion: a 10-year experience. *Aesthetic Plast Surg.* 2016;40:707–715.
36. Caviggioli F, Fabio C, Ventura D, et al. Inverted nipple: use of an effective and personalized splint after surgical correction with Pitanguy's technique to avoid relapse of the inversion in 28 cases. *Plast Reconstr Surg.* 2008;121:139e–140e.
37. Aiache A. Surgical repair of the inverted nipple. In: Shiffman MA, ed. *Nipple-Areolar Complex Reconstruction.* Cham, Switzerland: Springer; 2018:301–306.
38. Isac C, Isac A. Inverted nipples. In: Mugea TT, Shiffman MA, eds. *Aesth Surg Breast.* Heidelberg, Germany: Springer-Verlag; 2015:1009–1015.
39. Broadbent TR, Woolf RM. Benign inverted nipple: trans-nipple-areolar correction. *Plast Reconstr Surg.* 1976;58:673–677.