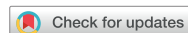

Brief Communication



Received: Nov 15, 2021
Revised: Mar 20, 2022
Accepted: May 22, 2022
Published online: Jun 13, 2022






Correspondence to

Ho Yong Park




Department of Surgery, Kyungpook National University Chilgok Hospital, School of Medicine, Kyungpook National University, 807 Hoguk-ro, Buk-gu, Daegu 41404, Korea.
Email: phy123@knu.ac.kr

© 2022 Korean Breast Cancer Society
This is an Open Access article distributed under the terms of the Creative Commons Attribution Non-Commercial License (<https://creativecommons.org/licenses/by-nc/4.0/>) which permits unrestricted non-commercial use, distribution, and reproduction in any medium, provided the original work is properly cited.

ORCID iDs

Byeongju Kang 
<https://orcid.org/0000-0002-3589-5559>
Jong Ho Lee 
<https://orcid.org/0000-0002-8318-5404>
Jeeyeon Lee 
<https://orcid.org/0000-0003-1826-1690>
Jin Hyang Jung 
<https://orcid.org/0000-0003-2607-1686>
Wan Wook Kim 
<https://orcid.org/0000-0002-7363-5889>

Comparative Study Between Radioisotope Uptake and Fluorescence Intensity of Indocyanine Green for Sentinel Lymph Node Biopsy in Breast Cancer

Byeongju Kang ¹, Jong Ho Lee ², Jeeyeon Lee ¹, Jin Hyang Jung ¹,
Wan Wook Kim ¹, Gyoyeong Chu ¹, Yeeseo Chae ³, Soo Jung Lee ³,
In Hee Lee ³, Jung Dug Yang ², Joon Seok Lee ², Ho Yong Park ¹

¹Department of Surgery, Kyungpook National University Chilgok Hospital, School of Medicine, Kyungpook National University, Daegu, Korea



²Department of Plastic and Reconstructive Surgery, Kyungpook National University Chilgok Hospital, School of Medicine, Kyungpook National University, Daegu, Korea

³Department of Oncology/Hematology, Kyungpook National University Chilgok Hospital, School of Medicine, Kyungpook National University, Daegu, Korea

ABSTRACT

Recently, several breast surgeons have reported a new method for sentinel lymph node biopsy (SLNB) by using indocyanine green (ICG) with infrared camera. This study aimed to determine whether the lymph nodes (LNs) with ICG uptake are true SLNs and to assess the reliability of using only ICG for SLNB. Data were prospectively collected between April and September 2021. All palpable LNs were fat-trimmed and ordered from high to low signal of the gamma detector. The degree of radioisotope uptake and brightness of ICG staining of the axillary LNs detected with a fluorescent camera were compared and associated factors were analyzed. Discordance was defined as sentinel LNs (SLNs) showing a single uptake of radioisotope or fluorescence of ICG only, or when the orders of uptake and intensity degree were different between the 2 materials. A total of 79 SLNBs were performed on 78 patients with breast cancer. The breast cancer was classified as cTis-2N0-1. The discordance rate was 14/79 (17.7%) overall and 45/270 (16.7%) of the total retrieved axillary LNs. The first SLNs showed the lowest discordance rate of 6.3%, whereas the second and third SLNs showed higher discordance rates of 27.6% and 60.0%, respectively. There were no associated clinicopathologic factors that affected the discordance between uptake of radioisotope and fluorescence intensity of ICG. The use of ICG alone for SLNB may be insufficient because of the high discordance rates between radioisotopes and ICG uptake. However, the first SLN could be cautiously regarded as a true SLN.

Keywords: Breast Neoplasms; Indocyanine Green; Radioisotopes; Sentinel Lymph Node

Gyoyeong Chu <https://orcid.org/0000-0003-3625-892X>Yeesoo Chae <https://orcid.org/0000-0002-8585-4982>Soo Jung Lee <https://orcid.org/0000-0003-0066-4109>In Hee Lee <https://orcid.org/0000-0002-0139-9768>Jung Dug Yang <https://orcid.org/0000-0002-9121-3604>Joon Seok Lee <https://orcid.org/0000-0002-1580-0487>Ho Yong Park <https://orcid.org/0000-0002-4380-0089>**Conflict of Interest**

The authors declare that they have no competing interests.

Author Contributions

Conceptualization: Kang B, Lee J; Data curation: Lee JH, Jung JH, Kim WW, Chu G, Chae Y, Lee SJ, Lee IH; Formal analysis: Kang B, Lee JH, Chu G, Lee SJ, Lee IH; Investigation: Kang B, Chu G, Yang JD, Lee JS; Resources: Jung JH, Kim WW, Chae Y; Writing - original draft: Kang B, Lee J; Writing - review & editing: Chae Y, Park HY.

INTRODUCTION

Axillary staging is an essential factor for predicting the prognosis of breast cancer [1-3]. This can be performed either by sentinel lymph node biopsy (SLNB) or axillary lymph node dissection (ALND), both of which are diagnostic and therapeutic (for the staging and removal of metastatic LNs, respectively). However, indiscriminate resection of axillary LNs can reduce the quality of life owing to postoperative pain, seroma, lymphedema, and movement restriction [4,5]. Therefore, for decades, SLNB has been assessed using radioisotopes or blue dyes (e.g., indigo carmine, methylene blue), and the retrieved LNs were evaluated by pathologists for the presence of metastasis from breast cancer [6-8]. Although the dual method has a higher sensitivity, using only a single technique is sufficient for some well-experienced surgeons. Recently, the coronavirus disease 2019 (COVID-19) pandemic has interrupted the import and export of many items [9,10]. Furthermore, indigo carmine cannot be produced owing to the lack of raw materials in Korea. Because of these circumstances, several breast surgeons have attempted to use an alternative staining dye that can replace the blue dye, and indocyanine green (ICG) has been identified as a candidate.

The usefulness of ICG has been established in both clinical and surgical fields, such as its utility in angiography (even intraoperatively), measurement of cerebral blood flow in neurosurgery, assessment of hepatic function and blood flow of harvested flaps, and SLNB in breast cancer [11-15]. Several studies have reported that using an infrared camera, ICG can be used to detect axillary LNs owing to its fluorescent properties and that these axillary LNs are well matched with sentinel LNs (SLNs). However, these studies only proved the feasibility of ICG for SLNB.

This study aimed to determine whether LNs exhibiting fluorescence intensity of ICG are true SLNs and to assess the reliability of using only ICG for SLNB. This was performed by comparing the order of intensity between radioisotope uptake and ICG brightness. We also calculated the discordance rate in all retrieved axillary LNs and evaluated the associated clinicopathological factors.

METHODS

Between April and September 2021, 79 SLNBs in 78 female patients with cTis-2N0-1 breast cancer were performed at Kyungpook National University Chilgok Hospital. All procedures performed involving human participants were in accordance with the ethical standards of the institutional and/or national research committee and with the 1964 Helsinki declaration and its later amendments or comparable ethical standards. This study was approved by the institutional review board Kyungpook National University Chilgok Hospital (KNUCH 2021-08-018). Informed consent was obtained from all participants included in the study. All breast cancers were diagnosed prior to surgery as either noninvasive or invasive via needle biopsy; if a suspicious LN was detected in the axilla, fine-needle aspiration cytology was performed. Patients in whom SLNB failed and those with breast cancer diagnosed via excision biopsy or vacuum-assisted breast biopsy were excluded because of the possibility of incomplete lymphatic channels (**Figure 1**). Patients who received neoadjuvant chemotherapy were also excluded from this study because of the possibility of altered lymphatic channels due to treatment.

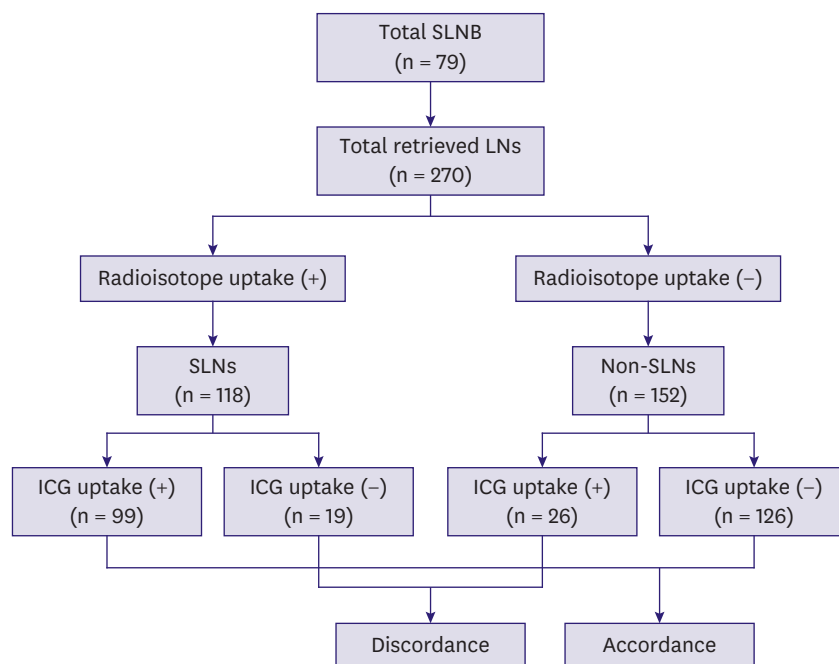


Figure 1. Patient selection diagram for comparison of uptake of radioisotope and ICG for SLNB in breast cancer. SLNB = sentinel lymph node biopsy; LN = lymph node; SLN = sentinel lymph node; ICG = indocyanine green.

After breast cancer was diagnosed by needle biopsy, the clinical stage, number, and location of the tumor were evaluated via mammography, ultrasonography, and breast magnetic resonance imaging prior to surgery. All the patients provided written informed consent to participate in the study.

Breast cancer is usually managed via breast-conserving surgery or mastectomy, and the surgical margins are assessed via intraoperative frozen sections in breast-conserving surgery. Two breast surgeons performed the surgeries for breast cancer.

Surgical technique for SLNB

For SLNB using radioisotopes, ^{99}Tc -phytate was injected by nuclear medicine physicians either in the afternoon on the day before surgery or on the morning of the day of surgery. After patients were administered general anesthesia, 25 mg of ICG (Daiichi Sankyo, Tokyo, Japan) was diluted with 10 mL of pure water; 1 mL of ICG solution was injected on the superior side of the areola, and a betadine drape was administered for breast cancer surgery. Because ICG is rapidly cleared from the circulatory system (half-life of only 2–4 minutes), SLNB was performed prior to removal of the breast cancer tissue [16].

An axillary incision of 2 cm was made and standard procedures for SLNB were performed. SLNs were defined as ^{99}Tc -phytate-containing LNs detected using a comprehensive gamma detection system (Neoprobe[®]; Ethicon Endo-Surgery, Inc., Cincinnati, USA), which contained $\geq 10\%$ of the radioactive count of the hottest LN [17,18]. In the bundles of axillary tissues containing LNs, other LNs that were palpable but not detected using the gamma detector were defined as non-SLNs.

All palpable LNs were fat-trimmed using mayo scissors and ordered from high to low signal of the gamma detector and from large to small size. These fat-trimmed LNs were illuminated

using an integrated fluorescence imaging solution (FLUOOPTICS®, Grenoble, France) to identify those containing ICG.

After removal of the SLNs, the axilla was rechecked for uptake of the radioisotope and fluorescence intensity of ICG to confirm whether any portion of the SLN remained.

Protocol of ICG injection for SLNB

In a preliminary study, various protocols were designed to determine the best protocol for ICG detection in SLNs. First, different injection times were used, specifically 30, 20, and 10 minutes before SLNB. Second, different injection sites were tested, namely, at the superior aspect of the periareolar area and the upper outer quadrant of the ipsilateral breast. Third, the protocol was tested with and without manual massage after ICG injection. Based on the results of the preliminary study, the protocol was determined as follows: 20 minutes before SLNB, peri-areolar site, and without manual massage. When ICG was undetectable in the axillary LNs, ICG was assumed to have either already passed or did not reach the area.

Comparison between radioisotope uptake and fluorescence intensity of ICG in LNs

The number of SLNs and non-SLNs was determined based on fluorescent signal intensity and LN size, respectively. LNs containing ICG were assessed using the integrated fluorescence imaging system, and these results were compared with those of LNs containing radioisotopes to determine concordance and discordance. The results of the 2 methods were compared by 3 different breast surgeons. While using a near-infrared camera to measure the fluorescence intensity of ICG, the image was captured, and the uptake of the radioisotope was recorded. The 3 breast surgeons verified the fluorescence intensity of ICG through the images using ImageJ (National Institutes of Health, Bethesda, USA) and subsequently confirmed the concordance between ICG and radioisotope results.

“Concordance” was defined as a case in which the order of the amount of radioisotope uptake and the intensity of ICG brightness was in agreement when the ICG was detected in LNs. If the uptake of radioisotope and fluorescence intensity of ICG did not match or the order of brightness of ICG did not match the order of uptake of radioisotope, it was defined as a “discordant” case (**Figure 2**).

The clinical variables assessed included age, body mass index, type of breast and axillary surgery, clinical and pathological stages, tumor type, number of metastatic and retrieved axillary LNs, immunohistochemical staining results, mean operation time, and treatment modalities. The treatment variables assessed included adjuvant chemotherapy, radiotherapy, hormone therapy, and targeted therapy.

Statistical analyses were performed using SPSS version 25 (SPSS Inc., Chicago, USA). To determine the related clinical factors that affect the concordance between radioisotope uptake and ICG expression in axillary LNs, the χ^2 test or Student's *t*-test was used, depending on the presence of categorical or continuous variables. Statistical significance was set at *p*-values < 0.05.

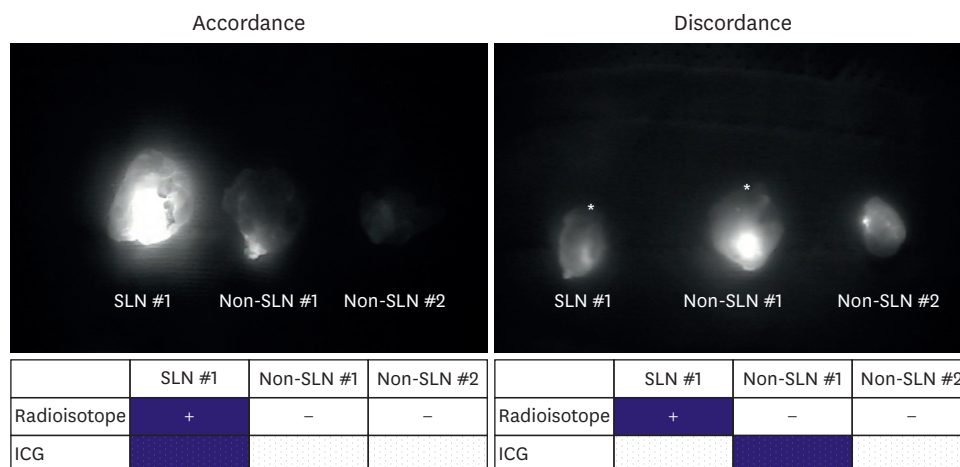


Figure 2. Definition of concordance and discordance between uptake of radioisotope and fluorescence intensity of ICG for SLN biopsy in breast cancer. Concordance was defined as SLNs showing identical results and orders in the uptake of radioisotope and fluorescence intensity of ICG. Discordance was defined as SLNs showing a single uptake of radioisotope or fluorescence of ICG (asterisk) only or when the orders of uptake and intensity degree were different between the 2 materials.

SLN = sentinel lymph node; ICG = indocyanine green.

RESULTS

There were 79 cases of SLNBs performed in 78 patients using radioisotopes and ICG in Kyungpook National University Chilgok Hospital. The mean age of the patients was 57.8 years (standard deviation [SD]: ± 10.9), and their mean body mass index was 23.8 kg/m² (SD: ± 4.1). Although 3 patients were diagnosed with Tis (ductal carcinoma *in situ*), SLNBs were performed because of the possible presence of invasive lesions in breast cancer. Most patients exhibited clinical T1 (55/79, 69.6%) and N0 (76/79, 96.2%) breast cancer. The mean number of LNs obtained for SLNB was 3.4 (SD: ± 1.24), and the mean number of retrieved and metastatic axillary LNs was 5.4 (SD: ± 3.1) and 0.2 (SD: ± 0.5), respectively. In addition, 74 patients had SLNs only, whereas in 4 patients, SLNB was followed by ALND because of the large burden of tumor metastasis. The radioisotope was injected into the peri-tumoral site either the afternoon before (47/79, 59.5%) or early in the morning of (32/79, 40.5%) on the day of surgery.

The total discordance rate of axillary LNs was 17.7% (14/79), and this rate was slightly higher in non-SLNs than in SLNs. The discordance rate was only 6.3% (5/79) in the first SLN, whereas this was 27.6% (8/29) and 60.0% (6/10) in the second and third SLN, respectively (**Table 1**). The discordance rate was higher in later-order SLNs than in earlier-order non-SLNs. Furthermore, all first SLNs in concordant cases showed the highest brightness of ICG on the infrared camera (**Table 1**). The detection rate of radioisotopes and ICG for FNA-proven metastatic LNs was 66.6% (2/3). None of the variables were statistically significant in the analysis (**Table 2**).

DISCUSSION

SLNB using radioisotopes and indigo carmine is widely performed in breast cancer. Since the early 1990s, radioisotopes and blue dyes have become standard detection methods for SLNs

Table 1. Comparison between radioisotope detection and ICG detection in each axillary lymph node including SLNs and non-SLNs

Characteristics	ICG detection	ICG non-detection	Discordance rate (%)
Radioisotope detection			
SLN #1 (n = 79)	74 (93.7)	5 (6.3)	6.3
SLN #2 (n = 29)	21 (72.4)	8 (27.6)	27.6
SLN #3 (n = 10)	4 (40.0)	6 (60.0)	60.0
Total			19/118 (16.1)
Radioisotope non-detection			
Non-SLN #1 (n = 73)	22 (30.1)	51 (69.9)	30.1
Non-SLN #2 (n = 49)	4 (8.2)	45 (8.2)	8.2
Non-SLN #3 (n = 23)	0	23 (100.0)	0
Non-SLN #4 (n = 7)	0	7 (100.0)	0
Total			26/152 (17.1)
Total retrieved lymph nodes			45/270 (16.7)
Total cases			14/79 (17.7)

Values are presented as number (%).

SLN = sentinel lymph node; ICG = indocyanine green.

in breast cancer [7,8]. Several studies have shown that they have the highest accuracy when used together [19,20]. However, the restrictions imposed by the COVID-19 pandemic have made it impossible to import raw materials for indigo carmine production in South Korea [9,10]. Therefore, an alternative dye for staining SLNs in breast cancer was sought, and ICG was selected for evaluation during SLNB. The benefits of using ICG for SLNB include a high detection rate, low cost, and simplicity of use [21]. Previous studies have reported that ICG is equivalent to the radioisotope for SLNB in patients with breast cancer [22,23]. However, the concordance between the order derived from the amount of radioisotope uptake and the intensity of ICG fluorescence during SLNB is yet to be studied.

In this study, approximately 83%–84% of retrieved axillary LNs were identical in the uptake of radioisotope and fluorescence intensity of ICG, regardless of whether they were SLNs or non-SLNs. However, 16.7% had inconsistent results between the 2 methods. Although the first SLNs showed a very high concordance rate of 93.7%, the second and third SLNs showed much lower rates of 73.4% and 40.0%, respectively. Conversely, although the first non-SLNs showed the highest discordance rate, this may not be reliable because the order of non-SLNs was not associated with radioisotope uptake. Considering these results, an axillary LN that shows the highest brightness of ICG can be regarded as the true first SLN.

To our knowledge, this is the first study to compare each retrieved axillary LN and distinguish between SLNs and non-SLNs. Although the obtained results have significant clinical implications, some limitations exist. This was a single-center study with a relatively small number of patients with early breast cancer. In addition, the presence or level of brightness of ICG fluorescence may be somewhat subjective. However, to confirm the feasibility of the ICG test in breast cancer, a multicenter, randomized clinical trial with a larger number of patients is warranted, and additional studies are needed in patients with early-stage and advanced breast cancer.

In conclusion, when SLNB in breast cancer is performed using only ICG without radioisotopes, an axillary LN with the highest fluorescence intensity of ICG can be regarded as the true first SLN based on high reliability. However, the use of ICG alone for SLNB is insufficient owing to the relatively high discordance rate between the second SLNs and non-SLNs. In cases where an axillary LN contains a metastatic focus of breast cancer, it may be difficult to distinguish whether the pattern of axillary metastasis is serial or skip.

Table 2. Comparison of clinicopathologic parameters between concordant and discordant cases

Characteristics	Concordant cases (n = 65)	Discordant cases (n = 14)	p-value
Age (yr)	57.5 ± 11.3	59.4 ± 9.0	0.184
BMI (kg/m ²)	24.1 ± 4.1	22.4 ± 3.5	0.820
Family history of breast cancer	1 (1.5)	1 (7.1)	0.325
Radioisotope injection in surgery day			0.380
Yes	37 (56.9)	10 (71.4)	
No	28 (43.1)	4 (28.6)	
Location			0.818
Right	31 (47.7)	7 (50.0)	
Left	34 (52.3)	7 (50.0)	
Breast surgery			0.417
Breast-conserving surgery	53 (81.5)	12 (85.7)	
Mastectomy	12 (18.5)	2 (14.3)	
Axillary surgery			0.174
Sentinel lymph node biopsy	61 (93.8)	14 (100.0)	
Axillary lymph node dissection	4 (6.2)	-	
Multifocality	18 (27.7)	3 (21.4)	0.749
Clinical tumor size	1.7 ± 0.9	1.8 ± 1.4	
Pathologic tumor size	2.0 ± 0.9	1.6 ± 0.7	
Clinical T stage			0.143
0	2 (3.1)	1 (7.1)	
1	44 (67.7)	12 (85.7)	
2	20 (30.8)	1 (7.1)	
Clinical N stage			0.347
0	64 (98.5)	14 (100.0)	
1	1 (1.5)	-	
Pathologic T stage			0.484
0	2 (3.1)	-	
1	38 (58.5)	11 (78.6)	
2	25 (38.5)	3 (21.4)	
Axillary LN metastasis	15 (23.1)	1 (7.1)	0.285
Histologic grade*			0.288
1	9 (13.8)	7 (50.0)	
2	36 (55.4)	2 (14.3)	
3	18 (27.7)	5 (35.7)	
Existence of extensive intraductal component	16 (24.6)	3 (21.4)	0.562
Estrogen receptor, positive	52 (80.0)	10 (71.4)	0.486
Progesterone receptor, positive	40 (61.5)	8 (57.1)	0.760
Her2/neu gene, positive	5 (7.7)	11 (78.6)	0.383
Ki67 index			0.523
Low (< 14%)	17 (26.2)	6 (42.9)	
High (≥ 15%)	48 (73.8)	8 (57.1)	
Triple negative breast cancer	6 (9.2)	2 (14.3)	0.298
Adjuvant chemotherapy	38 (58.5)	6 (42.9)	0.286
Adjuvant radiotherapy	42 (64.6)	9 (64.3)	1.000
Adjuvant hormone therapy	40 (61.5)	10 (71.4)	0.486
Adjuvant target therapy	7 (10.8)	2 (14.3)	0.657

Values are presented as mean ± standard deviation or number (%).

BMI = body mass index; HER2 = human epidermal growth factor 2; LN = lymph node.

*Invasive carcinomas were only included.

REFERENCES

1. Rivadeneira DE, Simmons RM, Christos PJ, Hanna K, Daly JM, Osborne MP. Predictive factors associated with axillary lymph node metastases in T1a and T1b breast carcinomas: analysis in more than 900 patients. *J Am Coll Surg* 2000;191:1-6.
[PUBMED](#) | [CROSSREF](#)
2. Chang JM, Leung JW, Moy L, Ha SM, Moon WK. Axillary nodal evaluation in breast cancer: state of the art. *Radiology* 2020;295:500-15.
[PUBMED](#) | [CROSSREF](#)

3. Garcia-Etienne CA, Ferrari A, Della Valle A, Lucioni M, Ferraris E, Di Giulio G, et al. Management of the axilla in patients with breast cancer and positive sentinel lymph node biopsy: an evidence-based update in a European breast center. *Eur J Surg Oncol* 2020;46:15-23.
[PUBMED](#) | [CROSSREF](#)
4. Toyserkani NM, Jørgensen MG, Haugaard K, Sørensen JA. Seroma indicates increased risk of lymphedema following breast cancer treatment: a retrospective cohort study. *Breast* 2017;32:102-4.
[PUBMED](#) | [CROSSREF](#)
5. Srivastava V, Basu S, Shukla VK. Seroma formation after breast cancer surgery: what we have learned in the last two decades. *J Breast Cancer* 2012;15:373-80.
[PUBMED](#) | [CROSSREF](#)
6. Brackstone M, Baldassarre FG, Perera FE, Cil T, Chavez Mac Gregor M, Dayes IS, et al. Management of the axilla in early-stage breast cancer: Ontario health (cancer care Ontario) and ASCO guideline. *J Clin Oncol* 2021;39:3056-82.
[PUBMED](#) | [CROSSREF](#)
7. Krag DN, Weaver DL, Alex JC, Fairbank JT. Surgical resection and radiolocalization of the sentinel lymph node in breast cancer using a gamma probe. *Surg Oncol* 1993;2:335-40.
[PUBMED](#) | [CROSSREF](#)
8. Giuliano AE, Kirgan DM, Guenther JM, Morton DL. Lymphatic mapping and sentinel lymphadenectomy for breast cancer. *Ann Surg* 1994;220:391-401.
[PUBMED](#) | [CROSSREF](#)
9. Kuo PF, Chiu CS. Airline transportation and arrival time of international disease spread: a case study of COVID-19. *PLoS One* 2021;16:e0256398.
[PUBMED](#) | [CROSSREF](#)
10. Wei P, Jin C, Xu C. The influence of the COVID-19 pandemic on the imports and exports in China, Japan, and South Korea. *Front Public Health* 2021;9:682693.
[PUBMED](#) | [CROSSREF](#)
11. Yannuzzi LA. Indocyanine green angiography: a perspective on use in the clinical setting. *Am J Ophthalmol* 2011;151:745-751.e1.
[PUBMED](#) | [CROSSREF](#)
12. Kortgen A, Recknagel P, Bauer M. How to assess liver function? *Curr Opin Crit Care* 2010;16:136-41.
[PUBMED](#) | [CROSSREF](#)
13. Schaafsma BE, Mieog JS, Hutteman M, van der Vorst JR, Kuppen PJ, Löwik CW, et al. The clinical use of indocyanine green as a near-infrared fluorescent contrast agent for image-guided oncologic surgery. *J Surg Oncol* 2011;104:323-32.
[PUBMED](#) | [CROSSREF](#)
14. Polom K, Murawa D, Rho YS, Nowaczyk P, Hünerbein M, Murawa P. Current trends and emerging future of indocyanine green usage in surgery and oncology: a literature review. *Cancer* 2011;117:4812-22.
[PUBMED](#) | [CROSSREF](#)
15. Alander JT, Kaartinen I, Laakso A, Pätälä T, Spillmann T, Tuchin VV, et al. A review of indocyanine green fluorescent imaging in surgery. *Int J Biomed Imaging* 2012;2012:940585.
[PUBMED](#) | [CROSSREF](#)
16. Bae PK, Jung J, Chung BH. Highly enhanced optical properties of indocyanine green/perfluorocarbon nanoemulsions for efficient lymph node mapping using near-infrared and magnetic resonance imaging. *Nano Converg* 2014;1:6.
[PUBMED](#) | [CROSSREF](#)
17. Martin RC 2nd, Edwards MJ, Wong SL, Tuttle TM, Carlson DJ, Brown CM, et al. Practical guidelines for optimal gamma probe detection of sentinel lymph nodes in breast cancer: results of a multi-institutional study. *Surgery* 2000;128:139-44.
[PUBMED](#) | [CROSSREF](#)
18. McMasters KM, Reintgen DS, Ross MI, Wong SL, Gershenwald JE, Krag DN, et al. Sentinel lymph node biopsy for melanoma: how many radioactive nodes should be removed? *Ann Surg Oncol* 2001;8:192-7.
[PUBMED](#) | [CROSSREF](#)
19. Lyman GH, Giuliano AE, Somerfield MR, Benson AB 3rd, Bodurka DC, Burstein HJ, et al. American Society of Clinical Oncology guideline recommendations for sentinel lymph node biopsy in early-stage breast cancer. *J Clin Oncol* 2005;23:7703-20.
[PUBMED](#) | [CROSSREF](#)
20. Mariani G, Manca G, Orsini F, Vidal-Sicart S, Olmos RA. *Atlas of Lymphoscintigraphy and Sentinel Node Mapping: A Pictorial Case-based Approach*. New York: Springer; 2013.

21. Yin R, Ding LY, Wei QZ, Zhou Y, Tang GY, Zhu X. Comparisons of ICG-fluorescence with conventional tracers in sentinel lymph node biopsy for patients with early-stage breast cancer: a meta-analysis. *Oncol Lett* 2021;21:114.
[PUBMED](#) | [CROSSREF](#)
22. Agrawal SK, Hashlamoun I, Karki B, Sharma A, Arun I, Ahmed R. Diagnostic performance of indocyanine green plus methylene blue versus radioisotope plus methylene blue dye method for sentinel lymph node biopsy in node-negative early breast cancer. *JCO Glob Oncol* 2020;6:1225-31.
[PUBMED](#) | [CROSSREF](#)
23. Sugie T, Kinoshita T, Masuda N, Sawada T, Yamauchi A, Kuroi K, et al. Evaluation of the clinical utility of the ICG fluorescence method compared with the radioisotope method for sentinel lymph node biopsy in breast cancer. *Ann Surg Oncol* 2016;23:44-50.
[PUBMED](#) | [CROSSREF](#)