



OPEN ACCESS

## CASE REPORT

## Releasing forced grasp reflex by use of concomitant imitation behaviour during rehabilitation of a stroke patient

Daisuke Watanabe,<sup>1</sup> Ikue Matsunobe,<sup>1</sup> Yasuyuki Okuma,<sup>2</sup> Masanori Nagaoka<sup>3,4</sup>

<sup>1</sup>Division of Rehabilitation Service, Juntendo University Shizuoka Hospital, Izunokuni-shi, Shizuoka Prefecture, Japan

<sup>2</sup>Department of Neurology, Juntendo University Shizuoka Hospital, Izunokuni-shi, Shizuoka Prefecture, Japan

<sup>3</sup>Departments of Neurology and Rehabilitation Medicine, Juntendo University, Tokyo, Japan

<sup>4</sup>Department of Internal Medicine, Nikko Noguchi Hospital, Nikko, Tochigi Prefecture, Japan

**Correspondence to**

Professor Masanori Nagaoka, nagaokam@juntendo.ac.jp

Accepted 15 May 2019

**SUMMARY**

An 80-year-old woman had a stroke during treatment for diffuse large B cell lymphoma. She exhibited left hemispatial inattention, forced grasping with her left hand and moderate left hemiplegia. She always grasped the guard rail of the bed with her left hand, which prevented her from standing up and performing activities of daily living (ADL) centred on move and transfer operations. During a medical examination, she showed an imitation behaviour (IB), mimicking gestures visually presented by the examiner, such as holding up. By using her IB in rehabilitation training, flexor-dominated posture of the upper arm was gradually reduced and performance of ADL improved. Her brain lesion was localised in the right middle frontal gyrus. Based on our experience of concomitant appearance of forced grasping and IB in this case, the pathophysiological involvement of the lesion was discussed.

**BACKGROUND**

Forced grasping or grasp reflex (GR) is known to be a primitive reflex not normally seen in adults and is caused by a pathological lesion located in the frontal lobe.<sup>1,2</sup> A positive GR is defined as forced grasping of the examiner's hand by the patient in response to the examiner touching the patient's palm between the thumb and index finger. When a patient unintentionally grasps a visually presented object, it is called a groping reflex. Forced grasping and groping are usually performed by the hand contralateral to a destructive lesion in the frontal lobe, such as a lesion in the supplementary motor area (Brodmann area 6) or front-orbital area (Brodmann area 8). Forced grasping may be released by stroking the back of the hand. When this manoeuvre is ineffective to release the forced grasp, the patient may lose balance and fall when trying to stand up while grasping the guard rail of the bed at the same time, which hinders him/her from standing. This reflex is considered one of the symptoms that impede the performance of ADL in stroke rehabilitation.<sup>3,4</sup>

On the other hand, imitation behaviour (IB) is a tendency to imitate the examiner's gesture or movement, even after explicit instructions not to imitate or copy.<sup>5,6</sup> Lesions in the front-orbital area (Brodmann area 8) and the frontal pole (Brodmann area 10) have been reported to be associated with this symptom. Despite the topological similarities of the lesions, simultaneous manifestation of GR or

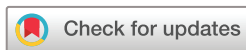groping reflex and IB in the same patient is rarely observed.

We encountered a patient with a stroke lesion located in the right middle frontal gyrus who exhibited both forced grasping and IB. This case suggested that forced grasping that hindered performance of activities of daily living (ADLs) may be released by inducing the IB. Furthermore, we discuss the possibility that IB may promote functional recovery of the paretic hand and render the synergistic posture.

**CASE PRESENTATION**

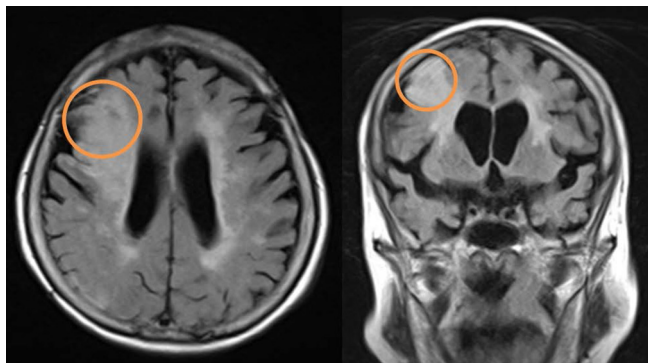
An 80-year-old woman living independently with her daughter presented at the department of otolaryngology of our hospital because of throat pain and common cold symptoms for 2 months. Examination revealed lymphadenopathy in the cervical region, and she was diagnosed with malignant lymphoma (stage III). Treatment was started with 50 mg/day of prednisolone, but improvement was not observed. She was admitted to our hospital because of difficulties with eating. Chemotherapy was started the next day. On day 5 of hospitalisation, she suddenly showed conjugated deviation of the eyes to the right together with left hemiparesis. Her symptoms included left hemispatial inattention, forced grasping with the left hand and left hemiparesis. The Mini-Mental State Examination could not be completed because of her hearing impairment, but she was able to follow our instructions except to release the grasping hand. Her Barthel Index score was 5/100. MRI revealed a high signal intensity area in the right middle frontal gyrus on fluid-attenuated inversion recovery images (figure 1).

Physiotherapy and occupational therapy were started on the same day. Early in rehabilitation intervention, inattention to the left side, forced grasping with the left hand, muscle weakness (grade 3/5 in the right upper and lower limbs and 5/5 in the finger by the manual muscle testing) and moderate left hemiplegia (Brunnstrom stage 4 in the arm, fingers and leg) were identified. Particularly, her left paretic hand was eager to grasp anything that her left hand touched. Verbal instruction to release the grasp and to refrain from holding any object did not resolve the forced grasping (figure 2A). In addition, during training of transfer between the bed and the wheel chair, her left hand held the guard rail of the bed and the armrest of the chair, preventing her from standing up. In the walking training, she assumed



© BMJ Publishing Group Limited 2019. Re-use permitted under CC BY-NC. No commercial re-use. See rights and permissions. Published by BMJ.

**To cite:** Watanabe D, Matsunobe I, Okuma Y, et al. *BMJ Case Rep* 2019;**12**:e228304. doi:10.1136/bcr-2018-228304



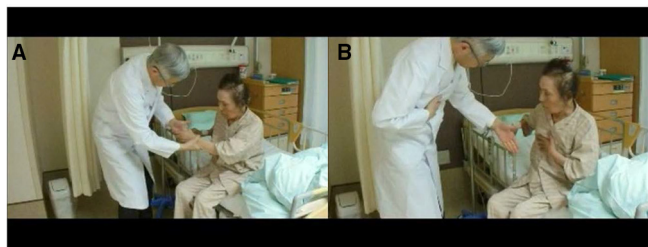**Figure 1** MRI revealed a high-signal intensity area in the right middle frontal gyrus on fluid-attenuated inversion recovery images.

a forward bending posture, with the left hand tending to hold on to anything. She needed assistance to perform all items of ADLs. She showed increased muscle tone in her left arm during passive movements and a flexor synergistic pattern during active left arm movement. All these findings made training very difficult. Therefore, the goals of rehabilitation in the early period were to resolve the forced grasping and to reduce the amount of assistance in ADL training.

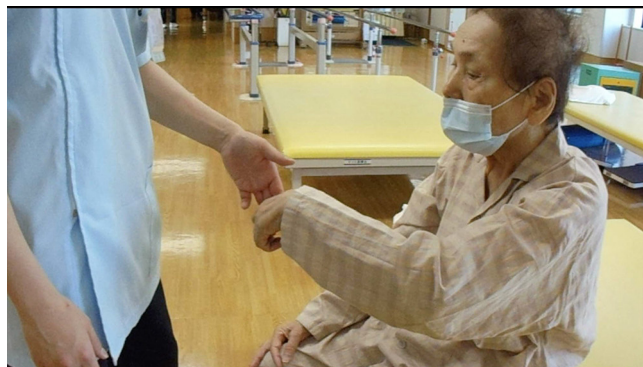One day during medical examination, while exhibiting compulsive grasping, the patient unexpectedly imitated a gesture when prompted by the action of the neurologist (MN). In doing so, she released her hand from the nearby guard rail of the bed that she had grasped. Furthermore, when the examiner made a gesture of putting his right hand (left as seen from the patient) on his knee or his back, the patient imitated the gesture. After that, even when given verbal instruction not to imitate, the patient continued to perform the act of placing her left hand on the left knee or on her back. The act recognised repeatability. Therefore, observed IB was obstinate (figure 2B).<sup>7</sup> These observations suggest that IB may appear at the same time as GR because of the pathological lesion. We suspected that during the training at rehabilitation, IB could be used to control the GR that hindered the patient from performing ADLs independently.

## TREATMENT

The patient was prescribed rehabilitation training 4 days a week, 40 min a day. The training included feeding, dressing, getting in and out of bed, standing up and sitting down, and walking. During the training, the physiotherapist intentionally used the IB to resolve the GR. For example, during standing-up training, the physiotherapist presented to the patient the act of holding up the right hand in order to prompt the patient to imitate this action and to release her grasp on the parallel bar. This strategy resulted



**Figure 2** Forced grasping reflex and imitation behaviour. (A) The patient held the examiner's hand forcefully, and the grasp could not be released. (B) When the examiner showed her a gesture to put the left hand on the chest, she imitated the act and released her left hand.



**Figure 3** The patient no longer showed grasp reflex after training using her imitation behaviour.

in the performance of the following activities: standing up, transferring, balancing and walking. The IB also prompted the patient to use her paretic left hand actively and eventually enhanced functional recovery of the paretic hand.

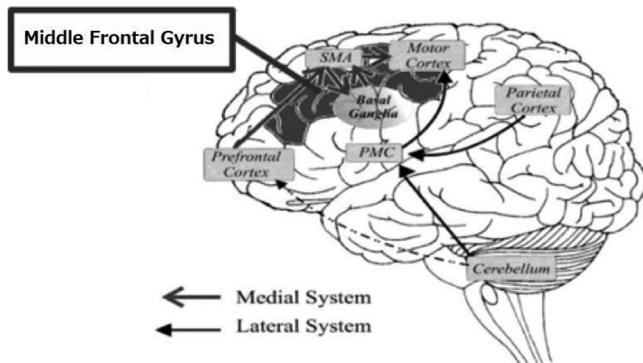
Seven days after the start of rehabilitation training, the GR became subtle and even stopped through verbal instructions (figure 3). When she handled an object unconsciously, she was able to release it by herself. As a result, her performance of ADLs improved, the standing-up motion was possible with light support of the buttocks, and transfer between the bed and the wheelchair became possible with only oral instructions. In addition, she was able to walk 50 m using a walker. After walking, she was able to move away from the handrail of the walker by herself and sit down. Finally, her Barthel Index score improved to 35/100. Although IB remained, it was possible to suppress it when she understood the situation, and IB was not a factor impeding performance of ADLs. Regarding motor paralysis, paresis was evaluated as grade 5/5 by the manual muscle testing and Brunnstrom stage 5 for the arm, fingers and leg. Improvement in voluntary control was confirmed. This change was attained mainly by the task-specific training, but the hampering effect by GR was lessened by IB, particularly in the early stage of rehabilitation training. However, increased muscle tone in the forearm flexor muscle group and poor dexterity remained. Finally, she was transferred to a rehabilitation hospital on the eighth day after initiation of rehabilitation.

## OUTCOME AND FOLLOW-UP

Although forced grasping is considered as one of the restricting factors in stroke rehabilitation, concomitant appearance of IB has suppressed grasping and prompted functional recovery. Finally, the patient finished acute-stage rehabilitation and transferred to a rehabilitation hospital within 8 days since the onset of stroke.

## DISCUSSION

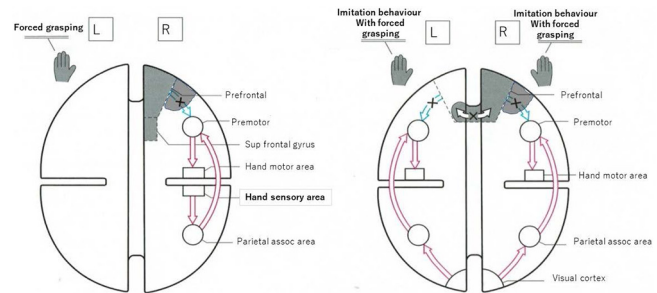
Denny-Brown and Chambers discussed forced grasping as a sensorimotor imbalance between the frontal lobe and the parietal lobe.<sup>2</sup> The frontal lobe and the parietal lobe represent internal and external worlds, respectively. Frontal lobe damage and loss of normal inhibitory function of the frontal lobes presumably release parietal lobe activity elicited by visual, auditory and tactile sensory information. IB, first coined by Lhermitte *et al*, refers to a tendency to imitate the examiner's gestures or movements.<sup>5 6</sup> For example, patients may cover their mouths, wave or clap their hands in response to observing the examiner performing the same motions. This tendency to imitate or copy



**Figure 4** Medial system and lateral system (modified from Goldberg, 1985).<sup>8</sup> PMC, primary motor cortex; SMA, supplementary motor area.

movements persists even after the patients are explicitly told not to imitate or copy and are given negative feedback after they have copied the movements. This IB was classified as obstinate IB and was exclusive to the frontotemporal pathology.<sup>7</sup> Lhermitte *et al* interpreted IB as the environmental dependency syndrome (EDS), which strongly depends on the stimulation of social and physical environments to guide human behaviour in a socially complex context.<sup>5,6</sup> As one symptom of EDS, Lhermitte *et al* coined utilisation behaviour (UB), referred to as automatic elicitation of usage of instrument. Like GR, IB is also regarded as resulting from a loss of inhibitory control over a more primitive reflex, although involving a more complex set of sensory and motor functions. Both GR and IB are seen as phenomena of release from the frontal inhibitory function; GR is the primitive reflex induced by tactile stimulation, while IB is one induced by visual stimulation. With regard to these different functions of the nervous system, Goldberg proposed the theoretical framework of an inner motor system and an outer motor system, as shown in figure 4.<sup>8</sup> Using this theory, he tried to explain the behavioural abnormalities that are supposed to be based on the imbalance between the inner (medial) motor system, in which movement is planned and executed by the person him/herself (voluntary, goal directed and future directed), and the external (lateral) motor system (automatic, stimulus bound, and visually based) in which movement is triggered from outside. The frontal lobe has connections with many cerebral tissues. Stuss and Benson pointed out that frontal lobe dysfunction may result in the following: (1) disturbance of spontaneous behaviour, (2) disturbance of execution of a series of actions and gestures and (3) implementation of actions not done normally.<sup>9</sup> Of these, the GR and the IB observed in our case are considered to correspond to the third category. In other words, these reflexes may appear due to dominant excitation of the outer motor system accompanying declined function of the frontal lobe, including the middle frontal gyrus.

In addition, the phenomenon of suppression of the GR by IB as observed in our case may be explained by the difference in sensory input and a shift of dependency from tactile to visual. Hirayama reported that these reflexes are all due to decreased suppression of the prefrontal cortex for motor response (figure 5).<sup>10</sup> In either GR or IB, sensory input is projected from the proper sensory area to the parietal association area and is transferred to the premotor area and the hand motor area. Finally, GR or IB is elicited in the case of disturbance in the frontal lobe or in infancy. In that report, Hirayama also commented on the possibility of coexistence of GB and IB.<sup>10</sup> In our case, we observed the



**Figure 5** Schematic illustration of forced grasping and IB (modified from Hirayama, 1993).<sup>10</sup> The red arrow represents facilitation, the blue arrow represents suppression and the cross represents lesion. The diagram on the left explains forced grasping, and that on the right explains the coexistence of forced grasping and IB. assoc, association; IB, imitation behaviour; L, left; R, right; sup, superior.

beneficial effect of IB in overcoming GR during rehabilitation training in a patient who had a stroke.

Hirayama proposed the concept that GR, forced groping, IB and mirror movements are seen normally in childhood, whereas they are suppressed accompanying development of motor function in children.<sup>10</sup> A recent study has pointed out the importance of mirror neurons in the process of motor learning in children. The mirror neuron is a system (an observation and execution matching system) that matches observation and execution of an action.<sup>11</sup> The system works when the person watches the action only, without the need to actually perform the act. In other words, the system is activated by input of visual information alone through seeing an action performed by others. This suggests that children may learn movement and communication through the mirror neuron system. Ertelt *et al* reported that upper limb functions of hemiplegic patients are significantly improved through using the mirror neuron system.<sup>12</sup> Several theories have been proposed regarding the existence of mirror neurons, such as the innate theory and the learning experience theory. However, motor learning through imitation may be involved in newborn imitative movements, early childhood language acquisition process and also performance of skills in sports. Among many theories of learning in humans, imitation is the most natural and familiar.<sup>11</sup>

Mirror neurons are hypothesised to be in the posterior part of the inferior frontal cortex and the anterior part of the inferior parietal lobule and are interconnected to the mirror neuronal system (MNS).<sup>13</sup> The stroke lesion in our case was in the right middle frontal gyrus. Therefore, the MNS spared from the lesion in our case could exert its mimicking function as IB which was escaped from the monitoring function of the middle frontal gyrus, besides GR is best conceived as an aspect of interhemispheric or intrahemispheric fibre-disconnection syndrome.<sup>4</sup> For EDS such as IB and UB, the supervisory attentional system (SAS) is supposed to monitor and inhibit actions triggered by perceptual input and inappropriate to the situation.<sup>14</sup> Thus, we suggest that the middle frontal gyrus could be related to SAS.

As a limitation of this study, we did not have SPECT data that reflect brain function, and we did not know the outcome of the patient after discharge from our hospital. Also, we are not sure whether using IB led to the correct, and not erroneous, direction toward recovery.

In conclusion, we experienced the appearance of some primitive reflexes in a patient who had a stroke with cerebral infarction confined to the right middle frontal gyrus. Forced grasping



reflex impeded the performance of ADLs but was suppressed by using IB.

### Learning points

- ▶ Despite the causative lesions similarly in the frontal lobes, simultaneous manifestation of grasping reflex and imitation behaviour (IB) in the same patient who had a stroke was rarely observed.
- ▶ Forced grasping impeded performance of activity of daily living but was suppressed by using IB.
- ▶ The rare combination of these frontal signs was seen in the patient with the localised lesion in the contralateral middle frontal gyrus.
- ▶ In case of forced grasping, the IB should be checked in a neurological examination, because its examination is not included in standard neurological examination.

**Contributors** DW and IM treated the patient through rehabilitation. YO diagnosed the patient. MN reviewed and wrote the manuscript.

**Funding** The authors have not declared a specific grant for this research from any funding agency in the public, commercial or not-for-profit sectors.

**Competing interests** None declared.

**Patient consent for publication** Next of kin consent obtained.

**Provenance and peer review** Not commissioned; externally peer reviewed.

**Open access** This is an open access article distributed in accordance with the Creative Commons Attribution Non Commercial (CC BY-NC 4.0) license, which permits others to distribute, remix, adapt, build upon this work non-commercially,

and license their derivative works on different terms, provided the original work is properly cited and the use is non-commercial. See: <http://creativecommons.org/licenses/by-nc/4.0/>

### REFERENCES

- 1 Adie WJ, Critchley M. Forced grasping and groping. *Brain* 1927;50:142–70.
- 2 Denny-Brown D, Chambers RA. The parietal lobe and behavior. *Res Publ Assoc Res Nerv Ment Dis* 1958;36:35–117.
- 3 Arima M, Ogata A, Kawahira K, *et al.* Improvement and Neuroplasticity after Combined Rehabilitation to Forced Grasping. *Case Rep Neurol Med* 2017;2017:1028390.
- 4 Choi I, Jung KI, Yoo WK, *et al.* Novel information on anatomic factors causing grasp reflex in frontal lobe infarction: a case report. *Ann Rehabil Med* 2015;39:150–3.
- 5 Lhermitte F, Pillon B, Serdaru M. Human autonomy and the frontal lobes. Part I: Imitation and utilization behavior: a neuropsychological study of 75 patients. *Ann Neurol* 1986;19:326–34.
- 6 Lhermitte F. Human autonomy and the frontal lobes. Part II: Patient behavior in complex and social situations: the "environmental dependency syndrome". *Ann Neurol* 1986;19:335–43.
- 7 Shimomura T, Mori E. Obstinate imitation behaviour in differentiation of frontotemporal dementia from Alzheimer's disease. *The Lancet* 1998;352:623–4.
- 8 Goldberg G. Supplementary motor area structure and function: Review and hypotheses. *Behav Brain Sci* 1985;8:567–616.
- 9 Stuss DT, Benson DF. The frontal lobes. *New York* 1986.
- 10 Hirayama K. Frontal lobe lesions and behavioral disturbances. *Jpn J Neuropsychology* 1993;9:2–12. (Japanese).
- 11 Rizzolatti G, Craighero L. The mirror-neuron system. *Annu Rev Neurosci* 2004;27:169–92.
- 12 Ertelt D, Small S, Solodkin A, *et al.* Action observation has a positive impact on rehabilitation of motor deficits after stroke. *Neuroimage* 2007;36:T164–T173.
- 13 Kojović M, Bhatia KP. Bringing order to higher order motor disorders. *J Neurol* 2019;266:797–805.
- 14 Besnard J, Allain P, Aubin G, *et al.* A contribution to the study of environmental dependency phenomena: the social hypothesis. *Neuropsychologia* 2011;49:3279–94.

Copyright 2019 BMJ Publishing Group. All rights reserved. For permission to reuse any of this content visit <https://www.bmj.com/company/products-services/rights-and-licensing/permissions/>  
BMJ Case Report Fellows may re-use this article for personal use and teaching without any further permission.

Become a Fellow of BMJ Case Reports today and you can:

- ▶ Submit as many cases as you like
- ▶ Enjoy fast sympathetic peer review and rapid publication of accepted articles
- ▶ Access all the published articles
- ▶ Re-use any of the published material for personal use and teaching without further permission

### Customer Service

If you have any further queries about your subscription, please contact our customer services team on +44 (0) 207111 1105 or via email at [support@bmj.com](mailto:support@bmj.com).

Visit [casereports.bmj.com](http://casereports.bmj.com) for more articles like this and to become a Fellow