

# The phosphorylation level of Cofilin-1 is related to the pathological subtypes of gastric cancer

Xi Kang, MD, PhD<sup>a</sup>, Chunfang Zhao, BD<sup>b</sup>, Yueping Liu, MD, PhD<sup>c</sup>, Guiying Wang, MD, PhD<sup>d,e,\*</sup> 

## Abstract

The purpose of the study was to explore the relationship between multiple proteins belonging to the LIMK/Cofilin pathway, including LIMK1, LIMK2, Cofilin-1, and p-Cofilin-1 and clinical features of gastric cancer (GC) patients, including overall survival, TNM stages, and pathological subtypes. The expression of LIMK1, LIMK2, Cofilin-1 and p-Cofilin-1 in the GC tissues and adjacent normal stomach tissues from 141 patients were detected using immunohistochemistry (IHC) staining. Wilcoxon rank-sum test and Spearman rank correlation coefficients were used to measure the relationship between different TNM stages, pathological types, and selected parameters. OS was estimated using the Kaplan–Meier method and survival curves were compared using the log-rank test. Our results showed that, compared to those in the adjacent normal stomach tissues, LIMK1, LIMK2 and Cofilin-1 were up-regulated while p-Cofilin-1 was down-regulated in the GC tissues. LIMK1 level was positively correlated to the TNM stages of GC. According to the published dataset, the expression levels of both LIMK1 and LIMK2 were correlated to the overall survival time of GC patients. The level of Cofilin-1 was significantly different between GCs of different TNM stages. Moreover, most importantly, this is the first study to reveal that the level of Cofilin-1 is higher, and the level of p-Cofilin-1 is lower in the diffuse type of GC compared to that in intestinal type. Taken together, our study demonstrated that multiple factors in LIMK/Cofilin pathway including LIMK1, LIMK2, Cofilin-1, and p-Cofilin-1 were associated with the clinical and pathological features of GC, which is potentially helpful for the diagnosis and treatment of GC.

**Abbreviations:** EMT = epithelial-mesenchymal transition, GC = gastric cancer, IHC = immunohistochemistry, LIMK = LIM kinase.

**Keywords:** Cofilin-1, gastric cancer, LIMK, pathological subtypes, phosphorylation

## 1. Introduction

Gastric cancer (GC) is one of the leading causes of cancer-related death worldwide. According to the International Agency for Research on Cancer (IARC), there were over a million new GC cases and 780,000 GC-related deaths in 2018 worldwide.<sup>[1]</sup> More than 679,000 new cases and 498,000 related deaths happen in China every year, accounting for approximately half of the total number of GC globally.<sup>[2]</sup> GC is asymptomatic in the early stages and about 80% to 90% of GC patients are diagnosed at advanced stage which accompanied by extensive invasion, lymphatic metastasis and limited median survival time of 1 year.<sup>[3]</sup> Therefore, it is critical to understand the mechanism underlying GC invasion and metastasis.

As key regulators of the cell cytoskeleton dynamics, LIM kinases (LIMKs) play a crucial role in cancer and neurological

diseases.<sup>[4–6]</sup> The LIMK family consists of two homologs, LIMK1 and LIMK2. Although differentially expressed in cells,<sup>[7,8]</sup> both LIMKs perform similar functions by phosphorylating and inactivating Cofilin-1, regulating actin polymerization and depolymerization during cell migration.<sup>[4]</sup> Many studies have shown that abnormal activation of the LIMK/Cofilin signaling pathway provokes cancer development, invasion, and metastasis,<sup>[9,10]</sup> and LIMK/Cofilin inhibitors has been exhibited to inhibit cancer metastasis.<sup>[11,12]</sup> You et al<sup>[13]</sup> demonstrated that the overexpression of LIMK1 in GC is associated with tumor differentiation, tumor size, clinical stage, lymph node metastasis, and poor prognosis. LIMK1 knockdown may inhibit tumor cell proliferation, migration, invasion, tumor growth and metastatic potential both in vitro and in vivo. We have previously found by transcriptome sequencing that the expression of LIMK1 was significantly up-regulated in GC tissues and peritoneal metastases.<sup>[12]</sup> Wang et al<sup>[14]</sup> reported that Cofilin-1

The authors have no funding and conflicts of interest to disclose.

The datasets generated during and/or analyzed during the current study are available from the corresponding author on reasonable request.

All data generated or analyzed during this study are included in this published article.

This study was approved by the Clinical Research Ethics Committee of Hebei Medical University 4th Hospital.

<sup>a</sup> Department of Hepatobiliary Surgery, Hebei Medical University 4th Hospital, Shijiazhuang, China, <sup>b</sup> Department of Histology and Embryology, Hebei Medical University, Shijiazhuang, China, <sup>c</sup> Department of Pathology, Hebei Medical University 4th Hospital, Shijiazhuang, China, <sup>d</sup> Department of General Surgery, Hebei Medical University 3rd Hospital, Shijiazhuang, China, <sup>e</sup> Department of General Surgery, Hebei Medical University 4th Hospital, Shijiazhuang, China.

\* Correspondence: Guiying Wang, Department of General Surgery, Hebei Medical University 3rd Hospital, No. 139 Ziqiang road, Shijiazhuang 050000, China (e-mail: wangguiying@hebmh.edu.cn).

Copyright © 2022 the Author(s). Published by Wolters Kluwer Health, Inc. This is an open-access article distributed under the terms of the Creative Commons Attribution-Non Commercial License 4.0 (CCBY-NC), where it is permissible to download, share, remix, transform, and buildup the work provided it is properly cited. The work cannot be used commercially without permission from the journal.

How to cite this article: Kang X, Zhao C, Liu Y, Wang G. The phosphorylation level of Cofilin-1 is related to the pathological subtypes of gastric cancer. *Medicine* 2022;101:43(e31309).

Received: 11 June 2022 / Received in final form: 20 September 2022 / Accepted: 21 September 2022

<http://dx.doi.org/10.1097/MD.00000000000031309>

expression was elevated in GC and could induce epithelial-mesenchymal transition (EMT) by promoting cytoskeletal rearrangement. These evidences suggest that the LIMK/Cofilin signaling pathway may be involved in GC development.

Therefore, we aim to analyze the relationship between the expression of LIMK1, LIMK2, Cofilin-1, phosphorylated Cofilin-1 (p-Cofilin-1) and the clinical characteristics of GC, to further explore the role of LIMK/Cofilin signaling pathway in the occurrence and progression of GC. Furthermore, we evaluated the potential of LIMK1 and LIMK2 mRNA expressions to be a prognostic marker in GC patients.

## 2. Materials and Methods

### 2.1. Patients and human samples

All 141 patients included in this study were from Hebei Medical University 4th Hospital, China. All patients provided informed consent for obtaining the tissue specimens. This study was approved by the Clinical Research Ethics Committee of Hebei Medical University 4th Hospital.

### 2.2. Immunohistochemistry (IHC)

For IHC analysis, following primary antibodies were used: Anti-LIMK1 (1:200, Origene, USA), Anti-LIMK2 (1:200, Abcam, UK), Anti-Cofilin-1 (1:200, Affinity, USA), and Anti-phospho-Cofilin-1 (ser3) (1:200, Affinity, USA). Tissue specimens were deparaffinized, rehydrated, and processed in boiling citrate buffer for 6 minutes for antigen retrieval. Slides were blocked in blocking reagent (Origene, USA) incubated with primary antibodies in 4 °C overnight, washed with Tris-buffered saline with 0.1% Tween 20 (TBST), and then incubated with secondary antibody (Origene, USA) for 45 min. HRP/DAB kit (Origene, USA) was used to visualize staining. Images of IHC were acquired by microscope using 10× and 20× objectives.

IHC staining was scored by percentage positive area and intensity as follows. All scoring was done by two separate pathologists blindly. Staining intensity was recorded as following: 0 for no staining, 1 for weak staining, 2 for medium staining, and 3 for strong staining. Proportion of positive cells: 0 for <5% positive area, 1 for 5%-25% positive area, 2 for 26%-50% positive area, 3 for 51%-75% positive area, and 4 for >75% positive area. The final IHC score was calculated using the intensity score multiplied by the proportion score. “-“ for 0-1 point, “+” for 2-3 points, “++” for 4-5 points, “+++” for ≥6 points.

### 2.3. Statistical analysis

The data of LIMK1/2 mRNA levels and the overall survival of GC patients were from published data set.<sup>[15]</sup> The cutoffs and *P*-values were calculated by the Kaplan–Meier Plotter.<sup>[16]</sup>

Levels of LIMK1/2, Cofilin-1, and p-Cofilin-1, different TNM stages and pathological types were compared using the Wilcoxon rank-sum test. Spearman rank correlation coefficients were used to measure the relationship between different TNM stages, pathological types, and selected parameters. OS was estimated using the Kaplan–Meier method and survival curves were compared using the log-rank test. *P* values < 0.05 were considered to indicate significance. \**P* < .05; \*\**P* < .01; \*\*\**P* < .001; \*\*\*\**P* < .0001.

## 3. Results

### 3.1. Expression of LIMK1, LIMK2, Cofilin-1 and p-Cofilin-1 in GC and adjacent normal stomach tissues

Total 141 GC tissues and 50 adjacent normal stomach tissues from patients were checked. Clinicopathologic characteristics

of patients were collected and listed in Table 1. IHC staining for LIMK1, LIMK2, Cofilin-1 and p-Cofilin-1 were performed in both tumor and adjacent normal stomach tissue samples. Our results showed that, compared to those of adjacent normal stomach tissue, LIMK1, LIMK2 and Cofilin-1 expression were all significantly increased while p-Cofilin-1 was decreased in the tumor tissues (Fig. 1). These results indicated that LIMK1, LIMK2, and Cofilin-1 may promote the tumor progression of GC, while p-Cofilin-1 might function as a tumor suppressor.

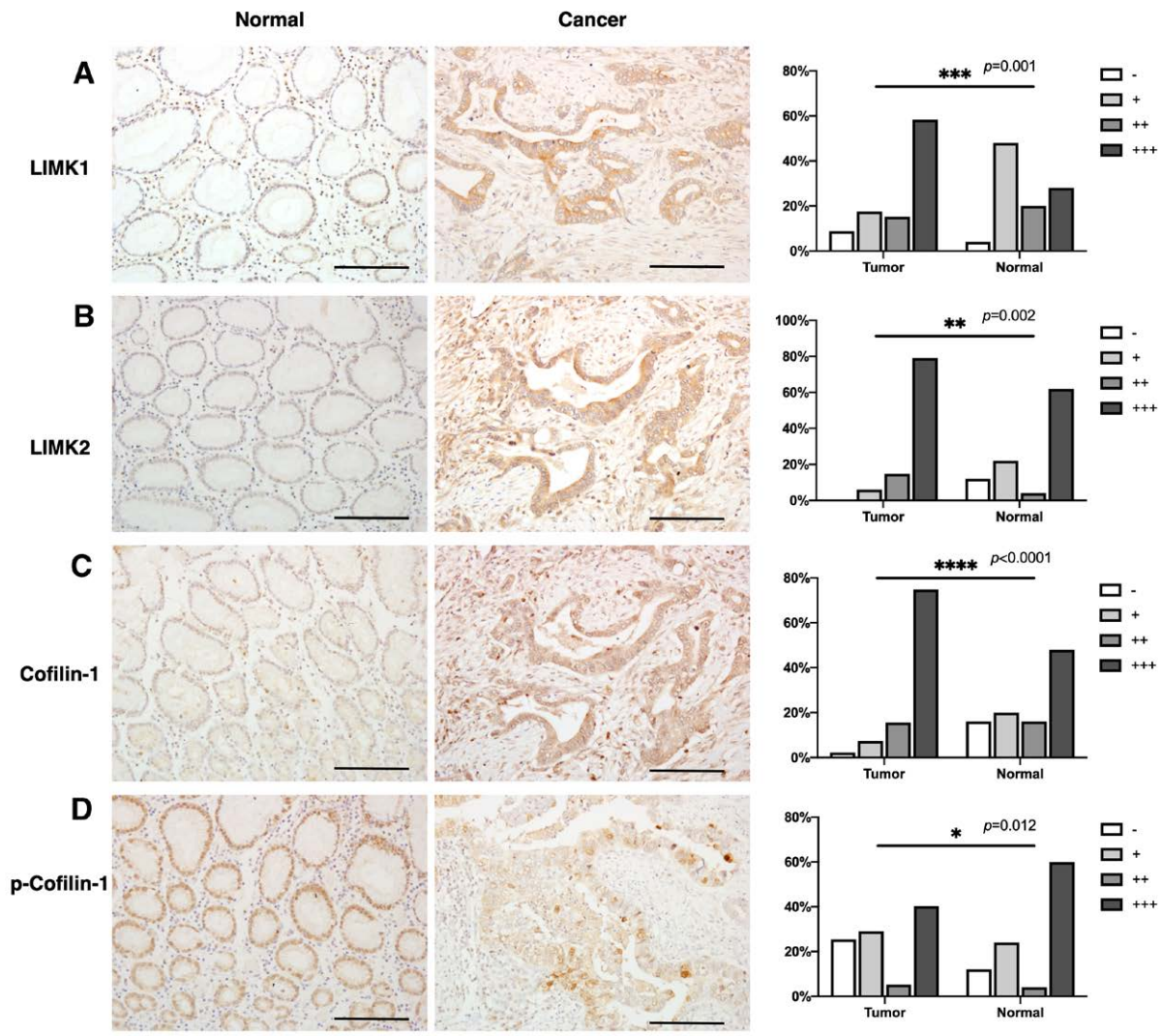
### 3.2. Correlation between LIMKs expressions in GC and clinical parameters

To further explore the relationship between LIMK1/2 and GC, we analyzed the expression of LIMK1 and LIMK2 in GC tissue at different TNM stages. Our results showed that LIMK1 could be expressed in all GC tissues and was dominantly expressed in the tumor tissues of TNM III and IV stages. Spearman rank correlation analysis showed that LIMK1 expression was positively correlated with more advanced TNM stages (*R* = 0.269, *P* = .002) (Fig. 2a).

We also checked the expression of LIMK1/2 in different T, N, or M stages separately. Samples from T3 and T4 stages tended to show higher LIMK1 expression compared to that in T1 and T2 stages (Fig. 2b). Since patients with distant metastasis are not candidate for surgical treatment except accompanied by bleeding or obstruction, only 4 GC samples from M1 stage were collected in our study. High expression level of LIMK1

**Table 1**  
Clinicopathologic characteristics of patients.

Characteristic	No. of cases	%
<b>Gender</b>		
Male	37	26.2
Female	104	73.8
<b>Age</b>		
20-29	2	1.4
30-39	4	2.8
40-49	15	10.6
50-59	39	27.7
60-69	57	40.4
70	24	17
<b>Location</b>		
Distal	72	51.1
Proximal	69	48.9
<b>Lauren type</b>		
Intestinal	32	22.7
Diffuse	49	34.8
Mixed	54	38.3
Unclassified	6	4.2
<b>TNM stage</b>		
I	24	17
II	26	18.4
III	84	59.6
IV	7	5
<b>T stage</b>		
1	23	16.3
2	19	13.5
3	8	5.7
4	91	64.5
<b>N stage</b>		
0	46	32.6
1	23	16.3
2	26	18.5
3	46	32.6
<b>M stage</b>		
0	137	97.2
1	4	2.8



**Figure 1.** Compared to that in adjacent normal stomach tissues, the IHC staining of LIMK1 (a), LIMK2 (b), and Cofilin-1 (c) is stronger in GC tissue, which is manifested as having higher IHC scores overall. On the contrary, the IHC staining of p-Cofilin-1 (d) is weaker in GC tissue compared to that in normal stomach tissues. All IHC pictures were captured at 20X objective lenses, the scale bars are 100  $\mu$ m. GC = gastric cancer, IHC = immunohistochemistry, LIMK = LIM kinase.

(+++)) were found in all 4 samples. No significant differences in LIMK1 expression between any different N stages (Fig. 2c). These results indicated that LIMK1 is more related to T and M stages of GC. LIMK2 expression did not show any significant difference between different TNM stages (data not shown).

In present study, we analyzed the correlation between LIMK1/2 mRNA level and the overall survival of GC patients of a published dataset.<sup>[15]</sup> Results showed that up-regulated expression of LIMK1 leads to poor survival of GC patients (Fig. 3a). Patients with higher LIMK2 expression in tumor tissue had better overall survival in the same patient cohort (Fig. 3b).

### 3.3. The expression and phosphorylation of Cofilin-1 in different pathological subtypes of GC

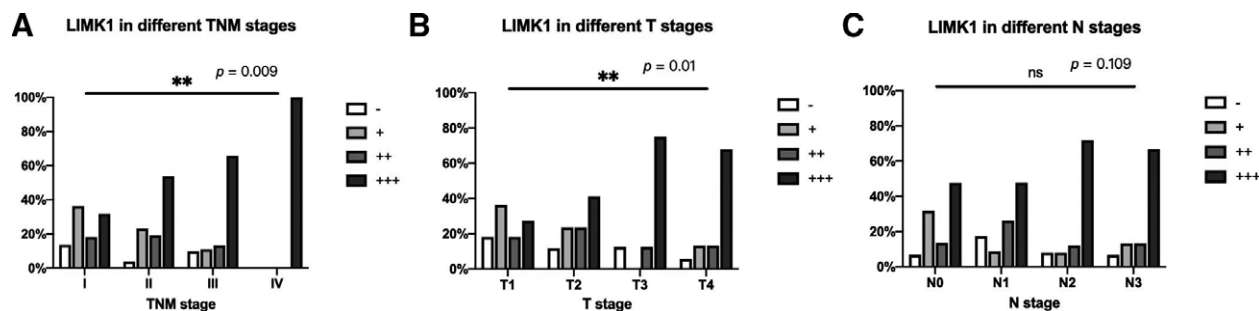
According to the Lauren classification, gastric adenocarcinoma can be classified into diffuse, intestinal, and mixed types.<sup>[17]</sup> Diffuse type of GC accounts for approximately 30% of all GC and is associated with aggressive progression, peritoneal metastasis, and poorer clinical outcomes than intestinal type.<sup>[18,19]</sup> In order to check the relationship between Cofilin-1 and clinical characteristics of GC, we then investigated the expression level

of Cofilin-1 and its phosphorylated form p-Cofilin-1. Cofilin-1 expression is different between GC tissues of different TNM stages. The expression of Cofilin-1 was relatively higher in stage II and stage III GC than in stage I and IV (Fig. 3a). The expression level of Cofilin-1 is relatively higher in diffuse-type GC than intestinal type (Fig. 4a). On the contrary, the level of p-Cofilin-1, the phosphorylated form of Cofilin-1, was significantly lower in intestinal-type GC compared to those in diffuse type (Fig. 4b).

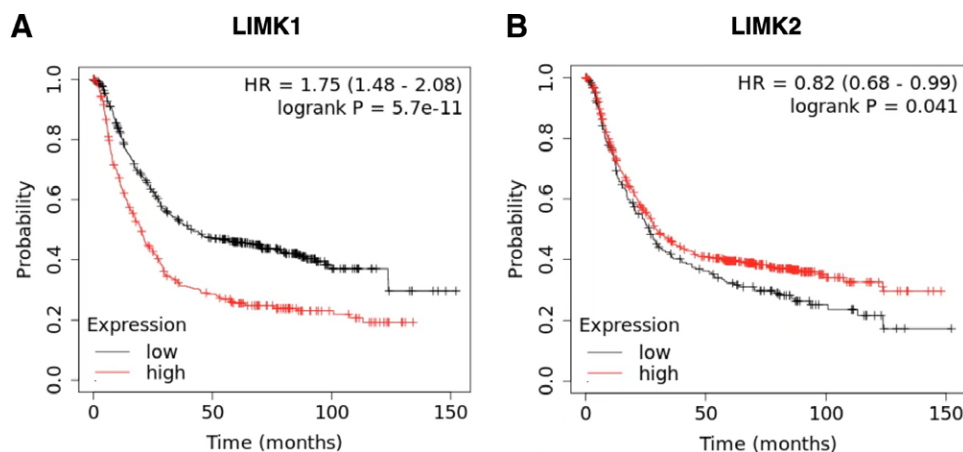
Previous studies showed that LIMK1 and LIMK2 could phosphorylate Cofilin-1, turning Cofilin-1 into p-Cofilin-1.<sup>[4]</sup> Nevertheless, in our study, results showed no correlation between the expression levels of either LIMK1 or LIMK2 and p-Cofilin-1 were found ( $P > .05$ ) (data not shown).

## 4. Discussion

LIMK/Cofilin signaling pathway plays an important role in tumor cell invasion and metastasis and its dysregulated expression has been observed in various types of cancer.<sup>[5]</sup> In the present study, we have evaluated the expression of multiple factors in LIMK/Cofilin pathway including LIMK1, LIMK2, Cofilin-1, and p-Cofilin-1 in GC and their correlations with clinical



**Figure 2.** (a) The expression level of LIMK1 is up-regulated in the tumor tissues of more advanced TNM stage. (b) The expression level of LIMK1 is significantly different between different T stages. (c) LIMK1 expression in GC showed no significantly different between different N stages ( $n = 137$ ). GC = gastric cancer, LIMK = LIM kinase.



**Figure 3.** (a) According to published dataset, up-regulated expression of LIMK1 leads to a poor survival of GC patients. (b) Patients with higher LIMK2 expression in tumor tissue had a better overall survival in the same patient cohort. Both cutoff of LIMK1 and LIMK2 were calculated by the Kaplan–Meier Plotter. GC = gastric cancer, LIMK = LIM kinase.

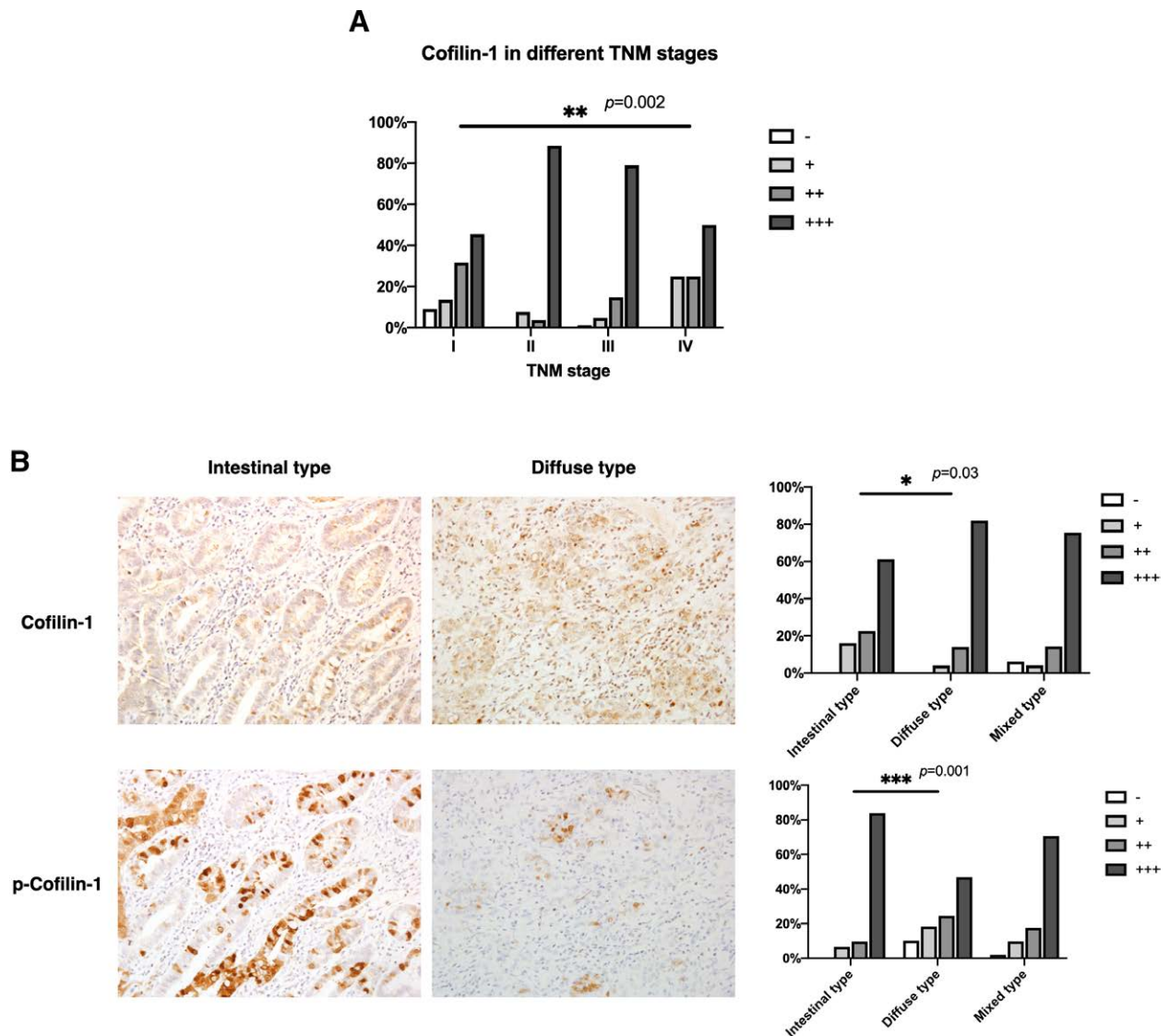
parameters of GC patients. The results suggested that LIMK/Cofilin signaling pathway may contribute to the carcinogenesis and progression of GC. To the best of our knowledge, our study evaluated the association between LIMK2 and p-Cofilin-1 and the clinicopathological features of GC for the first time.

Previous studies have shown that LIMK1 is highly expressed in GC and is related to tumor differentiation, invasion depth, clinical stage, lymph node metastasis, and prognosis. Knockdown of LIMK1 expression could inhibit cell proliferation, migration, and invasion in vitro, and retard tumor growth and peritoneal metastasis in vivo.<sup>[12,13,20]</sup> Mostly consistent with previous studies, in the present study, we also found that LIMK1 is highly expressed in GC tissues and is related to TNM stage, tumor size and extent, and distant metastasis. Importantly, spearman rank correlation analysis showed that the expression of LIMK1 was positively correlated with the more advanced TNM stage, suggesting that LIMK1 is associated with the clinical prognosis of GC patients. Differently, the expression of LIMK1 in our study cohort was not associated with lymph node metastasis. We think this might be due to the different mechanisms between the local proliferation and invasion, distant metastasis, and lymph node metastasis of tumor. The unique microenvironment within lymph nodes, including chemokines and lymph angiogenesis, can mediate the metastatic spread in the lymph system,<sup>[21]</sup> which might conceal the functions of LIMK/Cofilin-1 pathway.

LIMK2, which is similar to LIMK1, has been found involved in multiple aspects of cancer development, including cell migration,<sup>[22]</sup> angiogenesis,<sup>[23]</sup> and cell cycle arrest and apoptosis.<sup>[24]</sup> However, it has never been studied in GC. In the present study, we were the first to find that LIMK2 expression was increased

in GC, but not associated with TMN stages or Lauren histological classification. Our analysis using the online Kaplan–Meier plotter database also indicated that GC patients with low expression of LIMK2 mRNA had a poorer prognosis. The conclusions of LIMK2 expression in cancer tissue in previous studies were quite inconsistent. Overexpression of LIMK2 has been reported in bladder cancer,<sup>[25]</sup> breast cancer,<sup>[22]</sup> and colorectal cancer.<sup>[10]</sup> Conflicting results found by Lourenco et al showed that reduced LIMK2 expression in colorectal cancer was associated with shorter patient survival and increased colon tumor size.<sup>[26]</sup> The hypothesis was that there is selective pressure for reduced LIMK2 expression in colorectal cancer to relieve negative constraints imposed upon gastrointestinal stem cells.<sup>[26]</sup> That might explain the poorer prognosis of GC patients with low expression of LIMK2 mRNA in our study. Nevertheless, these conflicting results indicated that further research is needed to better understand the function of LIMK2 in cancer.

In our study, we found that Cofilin-1 is highly expressed in tumor cells of primary GC and is associated with TNM stage, tumor size and extent, and Lauren histological classification. While the expression of p-Cofilin-1 in GC is significantly lower than that in normal tissues and is related to Lauren histological classification. It is worth mentioning that diffuse type of GC had an observably high expression of Cofilin-1 and low expression of p-Cofilin-1 compared to that in intestinal type. High expression of Cofilin-1 has been found in various cancers,<sup>[27–29]</sup> and suggested to induces EMT by promoting cytoskeletal rearrangement and cell-cell adhesion.<sup>[14,30]</sup> Therefore, Cofilin-1 can be an important regulatory factor of



**Figure 4.** (a) The expression level of Cofilin is different between GC tissues of different TNM stages ( $n = 135$ ). (b) The expression level of Cofilin is relatively higher in diffuse type GC compared to intestinal type. On the contrary, the level of p-Cofilin is significantly lower in intestinal type GC compared to diffuse type. ( $n = 81$ ). GC = gastric cancer.

cytoskeletal reorganization in tumor cells, and its expression significantly correlates with the EMT of cancer.<sup>[31–33]</sup> Tanabe et al found that diffuse type of GC underwent extensive EMT and the hedgehog-EMT pathway is preferentially activated compared to intestinal type.<sup>[34]</sup> In the present study, the decreased p-Cofilin-1 and the increased total Cofilin-1 levels also indicated that the level of non-phosphorylated active Cofilin-1 in diffuse-type GC tissues was increased. Therefore, we believe that the increased level of active Cofilin-1 in diffuse-type GC tissues might activate EMT, leading to tumor metastasis and invasion.

In summary, our data suggest that elevated LIMK1, LIMK2, Cofilin-1 level, and reduced p-Cofilin-1 level may be associated with the development and progression of disease. Especially, we provided novel evidence that the dephosphorylation of Cofilin-1 is closely related to diffuse-type GC, which can be a potential therapeutic target for the treatment of diffuse-type GC.

#### Authors' contributions

XK analyzed and interpreted the data and was the major contributor in writing the manuscript. CZ and YL collected the

tissue samples and performed the IHC staining and scoring of all samples. GW supervised the study, reviewed, and edited the manuscript.

**Data curation:** Xi Kang.

**Investigation:** Chunfang Zhao, Yueping Liu, Xi Kang.

**Methodology:** Xi Kang.

**Supervision:** Guiying Wang.

**Project administration:** Guiying Wang, Xi Kang.

**Validation:** Xi Kang.

**Visualization:** Chunfang Zhao, Yueping Liu, Xi Kang.

**Writing – original draft:** Xi Kang.

**Writing – review & editing:** Guiying Wang.

#### References

- [1] Rawla P, Barsouk A. Epidemiology of gastric cancer: global trends, risk factors and prevention. *Przegląd Gastroenterologiczny*. 2019;14:26–38.
- [2] Chen W. Cancer statistics: Updated cancer burden in china. *Chin J Cancer Res*. 2015;27.
- [3] Mariette C, Benoist S, De Mestier P. Phase III study of docetaxel and cisplatin plus fluorouracil compared with cisplatin and fluorouracil as first-line therapy for advanced gastric cancer: a report of the V325 study group - Commentary. *J Chir (Paris)*. 2007;144.

- [4] Bernard O. Lim kinases, regulators of actin dynamics. *Int J Biochem Cell Biol.* 2007;39:1071–6.
- [5] Scott RW, Olson MF. LIM kinases: function, regulation and association with human disease. *J Mol Med.* 2007;85:555–68.
- [6] Cuberos H, Vallée B, Vourc’h P, et al. Roles of LIM kinases in central nervous system function and dysfunction. *FEBS Lett.* 2015;589:3795–806.
- [7] Foletta VC, Moussi N, Sarmiere PD, et al. LIM kinase 1, a key regulator of actin dynamics, is widely expressed in embryonic and adult tissues. *Exp Cell Res.* 2004;294.
- [8] Acevedo K, Moussi N, Li R, et al. LIM kinase 2 is widely expressed in all tissues. *J Histochem Cytochem.* 2006;54:487–501.
- [9] Mardilovich K, Baugh M, Crighton D, et al. LIM kinase inhibitors disrupt mitotic microtubule organization and impair tumor cell proliferation. *Oncotarget.* 2015;6:38469–86.
- [10] Aggelou H, Chadla P, Nikou S, et al. LIMK/cofilin pathway and Slingshot are implicated in human colorectal cancer progression and chemoresistance. *Virchows Arch.* 2018;472:727–37.
- [11] Prunier C, Josserand V, Vollaire J, et al. LIM kinase inhibitor Pyr1 reduces the growth and metastatic load of breast cancers. *Cancer Res.* 2016;76.
- [12] Kang X, Li W, Liu W, et al. LIMK1 promotes peritoneal metastasis of gastric cancer and is a therapeutic target. *Oncogene.* 2021;40:3422–33.
- [13] You T, Gao W, Wei J, et al. Overexpression of LIMK1 promotes tumor growth and metastasis in gastric cancer. *Biomed Pharmacother.* 2015;69:96–101.
- [14] Haibo W, Lide T, Feng J, et al. Cofilin 1 induces the epithelial-mesenchymal transition of gastric cancer cells by promoting cytoskeletal rearrangement. *Oncotarget.* 2017;8.
- [15] Szász AM, Lánckzy A, Nagy A, et al. Cross-validation of survival associated biomarkers in gastric cancer using transcriptomic data of 1,065 patients. *Oncotarget.* 2016;7:49322–33.
- [16] Lánckzy A, Gyórfy B. Web-based survival analysis tool tailored for medical research (KMplot): development and implementation. *J Med Internet Res.* 2021;23:e27633.
- [17] Lauren P. The two histological main types of gastric carcinoma: diffuse and so-called intestinal-type carcinoma. An attempt at a histo-clinical classification. *Acta Pathol Microbiol Scand.* 1965;64.
- [18] Shen L, Shan YS, Hu HM, et al. Management of gastric cancer in Asia: resource-stratified guidelines. *Lancet Oncol.* 2013;14:e535–47.
- [19] Fukamachi H, Kim SK, Koh J, et al. A subset of diffuse-type gastric cancer is susceptible to mTOR inhibitors and checkpoint inhibitors. *J Exp Clin Cancer Res.* 2019;38.
- [20] Bo S, Jian S, Ying Z, et al. Diallyl disulfide suppresses epithelial-mesenchymal transition, invasion and proliferation by downregulation of LIMK1 in gastric cancer. *Oncotarget.* 2016;7:10498–512.
- [21] Kawada K, Taketo MM. Significance and mechanism of lymph node metastasis in cancer progression. *Cancer Res.* 2011;71:1214–8.
- [22] Malvi P, Janostiak R, Chava S, et al. LIMK2 promotes the metastatic progression of triple-negative breast cancer by activating SRPK1. *Oncogenesis.* 2020;9.
- [23] Vlecken DH, Bagowski CP. LIMK1 and LIMK2 are important for metastatic behavior and tumor cell-induced angiogenesis of pancreatic cancer cells. *Zebrafish.* 2009;6:433–9.
- [24] Gamell C, Schofield AV, Suryadinata R, et al. LIMK2 mediates resistance to chemotherapeutic drugs in neuroblastoma cells through regulation of drug-induced cell cycle arrest. *PLoS One.* 2013;8.
- [25] Wang W, Yang C, Nie H, et al. LIMK2 acts as an oncogene in bladder cancer and its functional SNP in the microRNA-135a binding site affects bladder cancer risk. *Int J Cancer.* 2019;144.
- [26] Lourenço FC, Munro J, Brown J, et al. Reduced LIMK2 expression in colorectal cancer reflects its role in limiting stem cell proliferation. *Gut.* 2014;63.
- [27] Zhou J, Wang Y, Fei J, et al. Expression of cofilin 1 is positively correlated with the differentiation of human epithelial ovarian cancer. *Oncol Lett.* 2012;4.
- [28] Lu L, Fu N, Luo X, et al. Overexpression of cofilin 1 in prostate cancer and the corresponding clinical implications. *Oncol Lett.* 2015;9.
- [29] Mousavi S, Safaralizadeh R, Hosseinpour-Feizi M, et al. Study of cofilin 1 gene expression in colorectal cancer. *J Gastrointest Oncol.* 2018;9.
- [30] Sousa-Squiavinato ACM, Rocha MR, Barcellos-de-Souza P, et al. Cofilin-1 signaling mediates epithelial-mesenchymal transition by promoting actin cytoskeleton reorganization and cell-cell adhesion regulation in colorectal cancer cells. *Biochim Biophys Acta Mol Cell Res.* 2019;1866.
- [31] Wang W, Mounieimne G, Sidani M, et al. The activity status of cofilin is directly related to invasion, intravasation, and metastasis of mammary tumors. *J Cell Biol.* 2006;173.
- [32] Wang WS, Zhong HJ, Xiao DW, et al. The expression of CFL1 and N-WASP in esophageal squamous cell carcinoma and its correlation with clinicopathological features. *Dis Esophagus.* 2010;23.
- [33] Tahtamouni LH, Shaw AE, Hasan MH, et al. Non-overlapping activities of ADF and cofilin-1 during the migration of metastatic breast tumor cells. *BMC Cell Biol.* 2013;14.
- [34] Tanabe S, Aoyagi K, Yokozaki H, et al. Gene expression signatures for identifying diffuse-type gastric cancer associated with epithelial-mesenchymal transition. *Int J Oncol.* 2014;45:1955–70.