

Arthroscopic Biceps Tenodesis by Bicortical Drilling Technique



Bancha Chernchujit, M.D., Sumit Agrawal, M.S., and Arrisna Artha, M.D.

Abstract: Pain arising from the long head of biceps tendon can cause significant disability of the shoulder. In young and physically demanding patients, biceps tenodesis is advised, in which the biceps tendon is cut from the native origin and fixed distally. Many methods have been proposed for this. This Technical Note describes arthroscopic biceps tenodesis in the bicipital groove by a bicortical drilling technique. The far cortex is breached only once by a guide wire, and the reamers do not breach the far cortex. The tendon is fixed in the new position using a PopLok anchor. This technique is safe and easy to perform but presents a learning curve.

Biceps tendinopathy encloses 2 terms, namely tendinitis and tendinosis of the long head of biceps tendon.¹ Biceps tendinitis is inflammation of the long head of biceps tendon. Tendinosis, however, is a degeneration of the tendon's collagen in response to chronic overuse. However, the terms biceps tendinitis and tendinosis have often been used interchangeably to describe pain arising from long head of biceps tendon. Biceps tendinopathy can be a cause of significant pain and dysfunction of the shoulder. Biceps tendinopathy is usually associated with full-thickness rotator cuff tears.²

Tenotomy and tenodesis are the 2 procedures described for the treatment of tendinopathy. Both procedures have advantages and disadvantages. Tenotomy has the advantages of being technically less demanding and favoring early return to pre-morbid condition, but the disadvantages of a cosmetic popeye deformity and association with cramping pain.³ Tenotomy is usually reserved for elderly and less physically demanding patients.

Tenodesis provides a better length-tension relation of the tendon and thus preserves flexion and supination strength, and it prevents muscle from atrophy. It is technically demanding, however, and has a longer rehabilitation period. It is usually performed on young, active, and physically demanding patients.

Many techniques of tenodesis have been proposed. They may be arthroscopic or open, suprapectoral or subpectoral, and tenodesis to bone or soft tissue and use unicortical fixation with screw or tendon fixation devices (PopLok/TenoLok anchor; Conmed, Utica, NY) and bicortical fixation with Endobutton (Smith & Nephew, London).

Indications for tenodesis are pain over the long head of biceps on physical examination, a positive Speed's or Yergason's test in an active, physically demanding patient, and magnetic resonance imaging (MRI) showing subluxated or torn biceps or biceps pulley lesions.

In this Technical Note, we describe a technique of biceps tenodesis in which tenodesis is done in the bicipital groove with bicortical drilling and transosseous fixation using a PopLok anchor.

Surgical Technique

After induction of general anaesthesia, the patient is placed in beach chair position. The involved upper limb is painted and draped (Fig 1). Surface marking of the involved shoulder is done (Fig 2). A posterior viewing portal is created, and diagnostic arthroscopy of the shoulder joint is performed. After confirming the diagnosis of biceps pathology, another portal is created anterolaterally (if there is a full-thickness cuff tear) or just anterior to the acromioclavicular joint (ACJ) (for partial-thickness cuff tear) (Fig 2).

Department of Orthopaedics, Faculty of Medicine, Thammasat University Hospital, Pathumthani, Thailand.

The authors report that they have no conflicts of interest in the authorship and publication of this article. Full ICMJE author disclosure forms are available for this article online, as [supplementary material](#).

Received September 7, 2020; accepted November 12, 2020.

Address correspondence to Sumit Agrawal, M.S., Department of Orthopaedics, Trauma Centre, National Academy of Medical Science, Kathmandu, Nepal. E-mail: drsumitbp@gmail.com

© 2020 by the Arthroscopy Association of North America. Published by Elsevier. This is an open access article under the CC BY-NC-ND license (<http://creativecommons.org/licenses/by-nc-nd/4.0/>).

2212-6287/201530

<https://doi.org/10.1016/j.eats.2020.11.014>

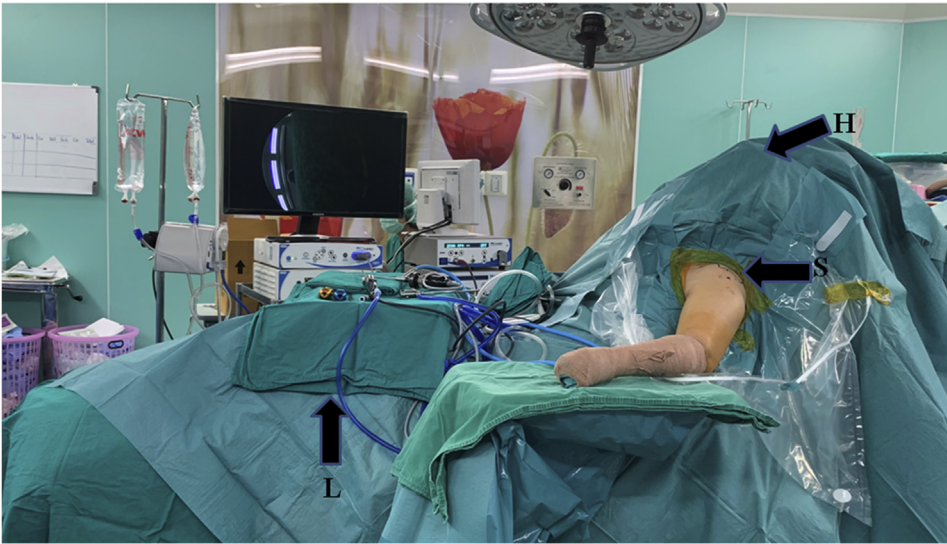

Fig 1. Shows that the patient is positioned in a beach chair position. Painting and draping has been done. Left shoulder is the affected shoulder (S). Head and leg ends are marked with H and L respectively. The left upper limb is draped in such a way to allow the shoulder and elbow to be moved as and when required during the procedure.

A Mayo scissors is passed through the second portal, and the long head of biceps tendon is cut as medially as possible (Fig 3; Video 1). The tenotomy can also be done using an electrocautery device. The viewing portal is then shifted to the anterolateral portal. The arthroscope is inserted into the subacromion space. The subacromial bursal tissue is removed with a shaver, which is inserted through the posterior portal. After the subacromion space is cleared, a posterolateral portal is

created. The arthroscope is inserted through the posterolateral portal into the subacromion space and is the viewing portal for the rest of the procedure.

An electrocautery device is used to trace the biceps tendon along the bicipital groove and free it completely after releasing the transverse ligament. The arm is abducted to 30°, and the elbow is flexed to 90° and supinated to relax the biceps. The biceps tendon is then grasped with a grasper and pulled out through the anterolateral portal (Fig 4). It is sutured with ultrabraid

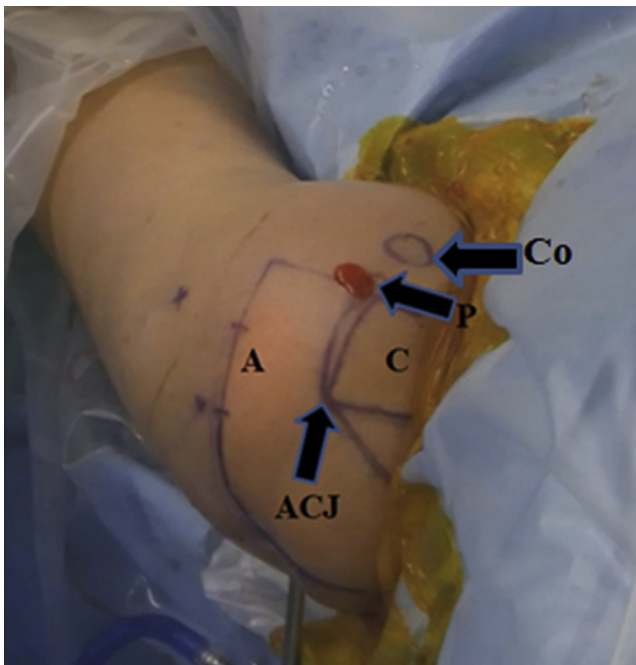


Fig 2. Shows the surface marking of left shoulder. Acromion process (A), Lateral end of the clavicle (C), Coracoid Process (Co) and Tenotomy Portal (P). The tenotomy portal is just anterior to the Acromio-Clavicular Joint (ACJ).

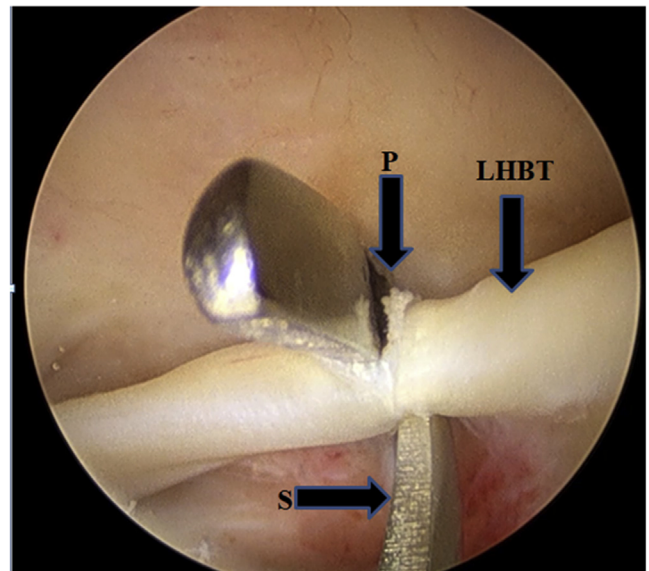


Fig 3. Shows the arthroscopic view of left shoulder as viewed from the posterior portal. In this figure we can see the internal opening of the tenotomy portal (P), Long Head of Biceps Tendon (LHBT) is being cut by a Mayo scissors (S). The tendon is cut as medial as possible. Cautery can also be used to cut the tendon.

Fig 4. Shows arthroscopic and outside view of left shoulder. **Fig 4A** shows arthroscopic view of left shoulder as viewed from the postero-lateral portal in which the cut end of long head of Biceps Tendon (LHBT) is held with a grasper (G). Grasper is inserted through the antero-lateral portal. **Fig 4B** shows outside view of left shoulder after the LHBT is brought out of the joint through antero-lateral portal. The arthroscope (A) is inserted through postero-lateral portal (PLP), the grasper (G) is holding the LHBT and an artery forceps is being used to clamp the base of LHBT.

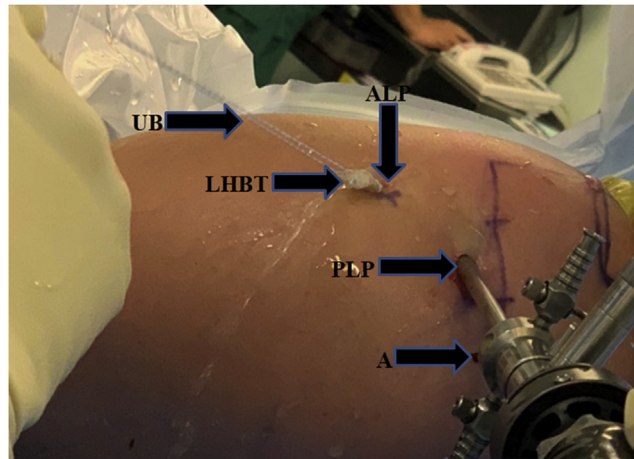
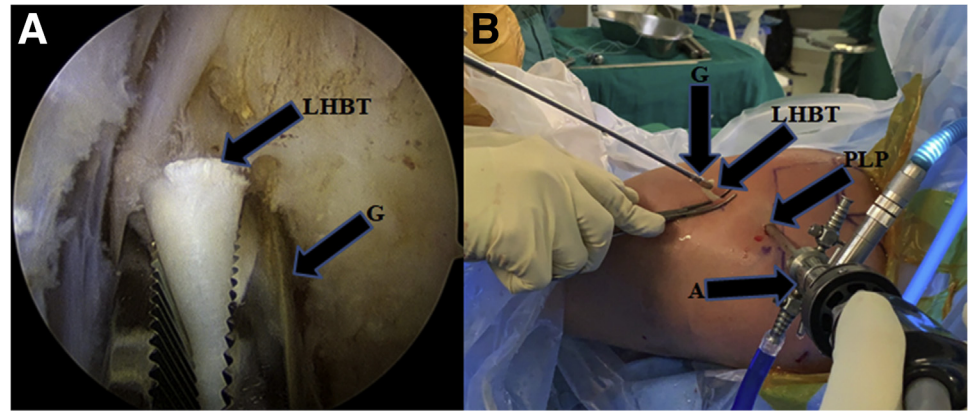


Fig 5. Shows the outside view of left shoulder. The arthroscope (A) is inserted through the posterolateral portal (PLP). The cut end of long head of biceps tendon (LBTH) is pulled out of antero lateral portal (ALP) and is sutured with ultrabraid suture (UB).

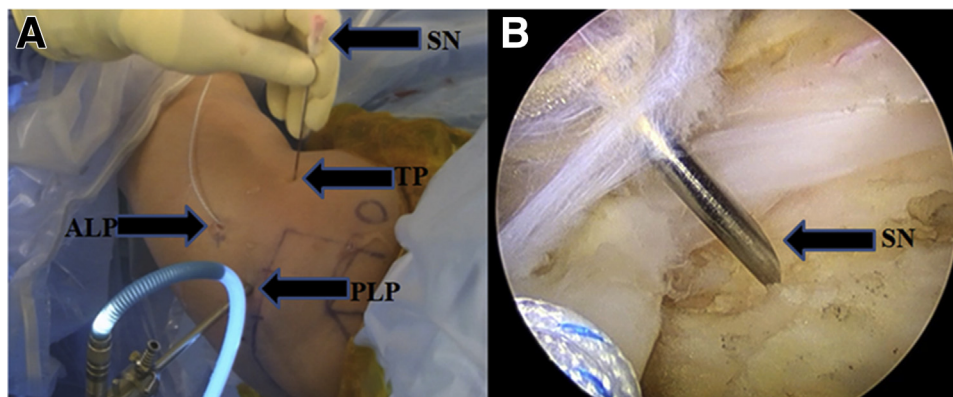


Fig 6. Shows the outside and arthroscopic view of left shoulder. **Fig 6A** shows that the arthroscope is inserted through postero lateral portal (PLP). Ultrabraid suture is seen hanging out of antero lateral portal (ALP). Spinal needle (SN) is used to identify the position to make a tenodesis portal (TP). **Fig 6B** shows the arthroscopic view of left shoulder as viewed from postero-lateral portal in which we can see the spinal needle at the level of bicipital groove. Once the spinal needle reaches the satisfactory position a stab incision is given in the skin to make the tenodesis portal.

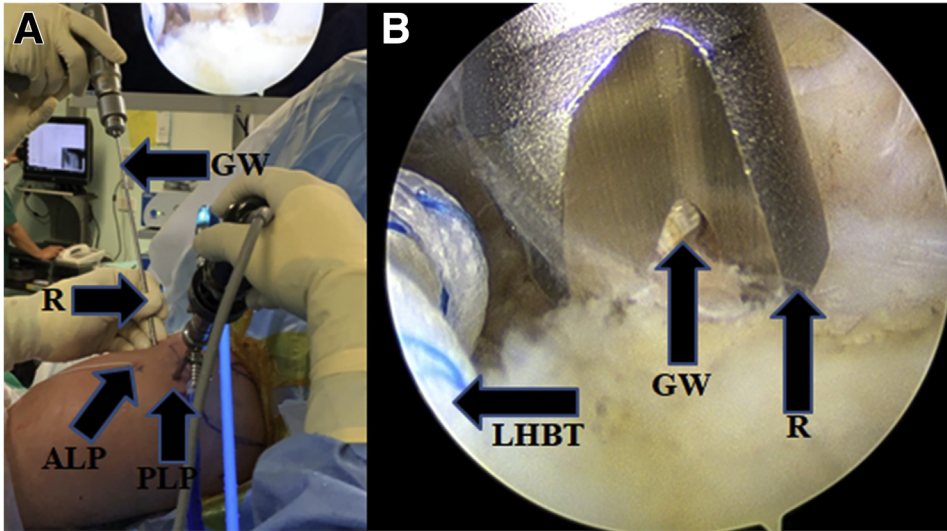


Fig 7. Shows the outside and arthroscopic view of left shoulder. **Fig 7A** shows arthroscope is inserted through the postero lateral portal (PLP). Ultrabraid is seen hanging out of the antero-lateral portal. Through the tenodesis portal a 4.2 mm reamer (R) is passed to touch the bicipital groove. A guide wire (GW) is passed through R to drill hole for tenodesis. **Fig 6B** shows arthroscopic view of left shoulder as viewed from postero-lateral portal. Reamer (R) is at the bicipital groove. The tip of the guide wire (GW) can be seen in R. Long head of biceps tendon (LHBT) is also seen.

(Smith & Nephew) by whipstitch technique, leaving 2 ends of the suture free (**Fig 5; Video**). The diameter of the biceps tendon is measured with the measuring guide. An anteroinferior portal (tenodesis portal) is then created with the outside-in technique lateral to the coracoid process (**Fig 6**). The arm is kept in abducted position, the elbow is fully extended, and the upper limb is internally rotated.

A 2.4-mm guide wire is loaded on a drill, and a hole is drilled at the middle to lower part of the bicipital groove until the far cortex is reached (**Fig 7**). The

direction of the drill is kept perpendicular to the plane of the shaft of humerus. Only the near cortex is drilled, and drilling is stopped once the far cortex is reached. The far cortex is breached by malleting the guide wire (**Fig 8**), and the guide wire is left in situ. A 4.9-mm cannulated reamer is loaded on the drill and reamed over the guide wire to ~40 mm. The diameter of the reamer is increased subsequently to match the diameter of the biceps tendon. Note that the far cortex is breached only with the guide wire and not by the reamers.

Fig 8. Shows the outside view of left shoulder. **Fig 8A** shows arthroscope is inserted through the postero lateral portal (PLP). Ultrabraid is seen hanging out through the antero-lateral portal (ALP). The guide wire (G) is passed through a reamer from tenodesis portal (TP) to drill a hole for tenodesis. The drilling is stopped when the guide wire reaches the far cortex. Beyond this point a mallet is used to mallet the guide wire to breach the far cortex as well as the soft tissues and the skin. **Fig 8B** shows that the guide wire (G) has breached the skin posteriorly also.

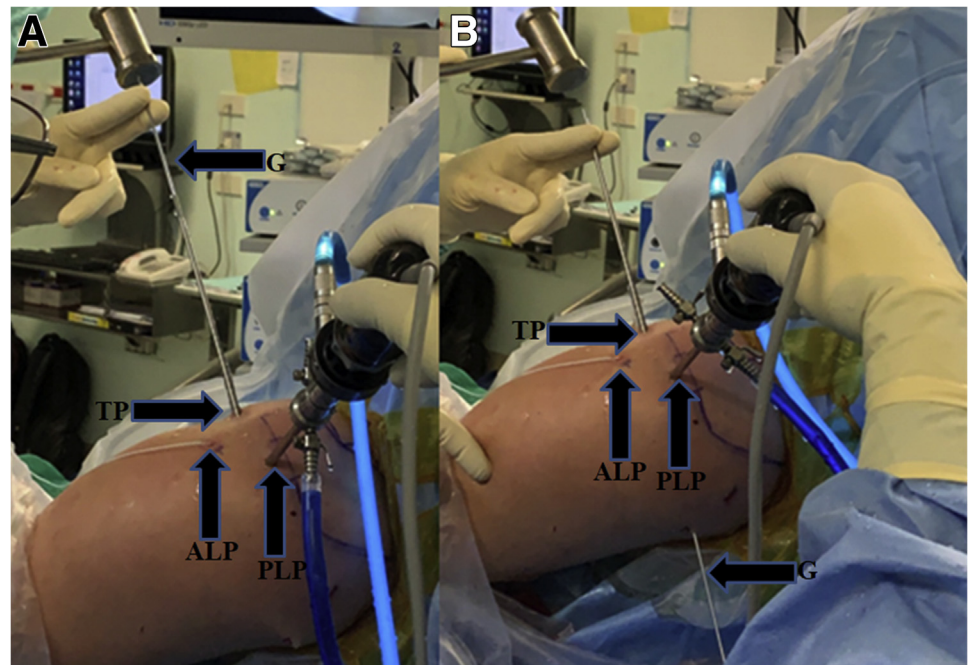
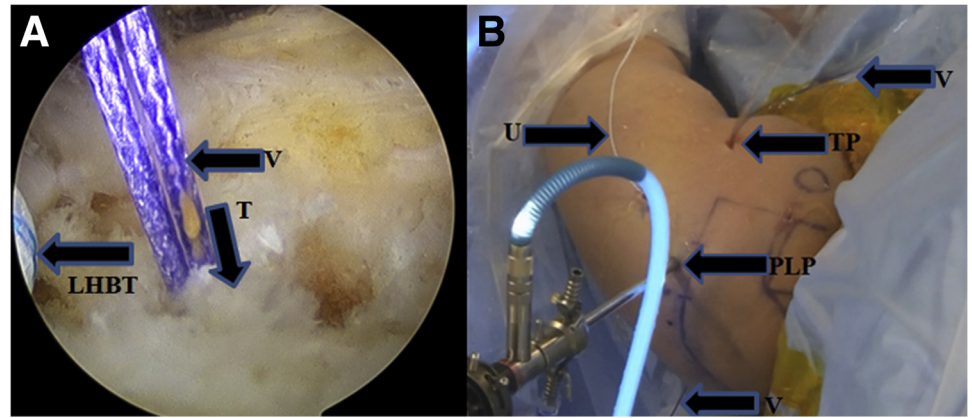


Fig 9. Shows the arthroscopic and outside view of left shoulder. **Fig 9A** shows arthroscopic view of left shoulder as viewed from postero-lateral portal. Vicryl (V) is in the tunnel (T). Long Head of Biceps Tendon is also seen. **Fig 9B** shows outside view of left shoulder. Arthroscope is inserted through postero-lateral portal (PLP). Ultrabraid (U) is seen hanging out of antero-lateral portal (ALP). Through the tenodesis portal (TP) Vicryl loop (V) is hanging out and the free ends of vicryl (V) is also seen in the posterior aspect of the shoulder.



A loop of Vicryl 2-0 (Ethicon; Johnson & Johnson, New Brunswick, NJ) is passed through the eye of the guide wire, and the guide wire is pulled out posteriorly, pulling the free ends of the vicryl with it posteriorly and leaving the loop anteriorly (**Fig 9**). An assistant holds the free ends of the vicryl. The ultrabraid and vicryl loop are then pulled together out of the anterolateral portal with a suture retriever (**Fig 10**). The ultrabraid is then engaged in the vicryl loop and pulled into the drilled hole by pulling the free ends of the vicryl (**Fig 11**).

Once the tendon is in the drilled hole, the ultrabraid is held gently and firmly to avoid excess tension in the tendon. The upper limb is kept in abduction, with the elbow in neutral rotation and full extension. A PopLok anchor is passed through the tenodesis portal (**Fig 12**), and the biceps tendon is securely fixed in the drilled hole by gently malleting it into the hole (**Fig 13; Video**).

The stability of the fixation is checked by moving the arm and elbow. The portals are sutured using 3-0 Ethilon (Johnson & Johnson) (**Fig 14**). Dressing is done. The patient is shifted out of the operating room after patient recovering from general anaesthesia.

Discussion

We describe a an arthroscopic technique for tenodesis of the long head of biceps in the bicipital groove, with bicortical drilling and using a PopLok anchor. Our technique has all the advantages of arthroscopic surgery over open surgery. Infection, increased blood loss, scarring, and musculocutaneous nerve injury are a few reported complications of open tenodesis that are absent in arthroscopic tenodesis.⁴ There is a statistically significant difference in complication rates between open and arthroscopic tenodesis, but this may not reflect clinical significance, as the complication rates remain <2% in both techniques.⁵

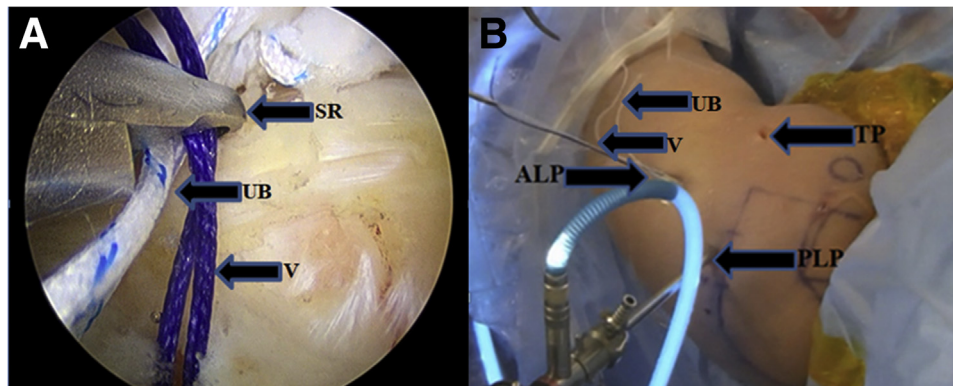


Fig 10. Shows the arthroscopic and outside view of left shoulder. **Fig 10 A** shows arthroscopic view of left shoulder as viewed from the postero-lateral portal. The suture retriever (SR) is holding both the vicryl (V) and ultrabraid(UB) sutures. The SR is passed in the joint through the antero-lateral portal. An assistant holds the free ends of vicryl in the posterior aspect and the surgeon pulls the UB and loop end of V out through the antero-lateral portal. **Fig 10 B** shows the outside view of left shoulder. The arthroscope is inserted through the postero lateral portal (PLP). The vicryl loop (V) and ultrabraid (UB) are both seen coming out of antero lateral portal (ALP). TP is tenodesis portal.

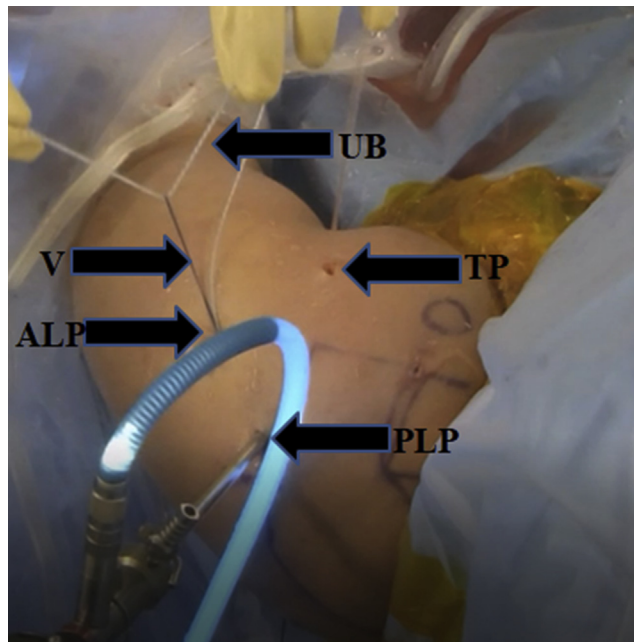


Fig 11. Shows the outside view of left shoulder. The arthroscope is inserted through the postero lateral portal (PLP). Ultrabraid (UB) is engaged in the vicryl loop (V), both of which are coming out of antero-lateral portal (ALP). The vicryl is pulled from the posterior aspect pulling the ultrabraid with it into the tunnel that is drilled for tenodesis. TP is tenodesis portal.

After tenotomy, the biceps tendon is freed from the groove. The groove is completely cleared of transverse humeral ligament. This is done to see if there are any hidden lesions in the tendon within the groove or beyond it.⁶ This problem does not occur in open subpectoral tenodesis, as the tendon is exposed very distally and all hidden lesions can be seen.

Kerschbaum et al.⁷ developed a tenodesis technique in which a suture loop is applied at the proximal end of

the biceps tendon after tenotomy. The loop functions by enlarging the proximal end of the tendon so that it does not pass through the entrance of the bicipital groove, giving a tenodesis effect.⁷ However, some studies have shown that if the transverse ligament is not released, it may continue to cause anterior shoulder pain and higher revision rates compared with surgeries in which it is released.⁸

While drilling in the bicipital groove, it is very important to internally rotate the arm and drill in a

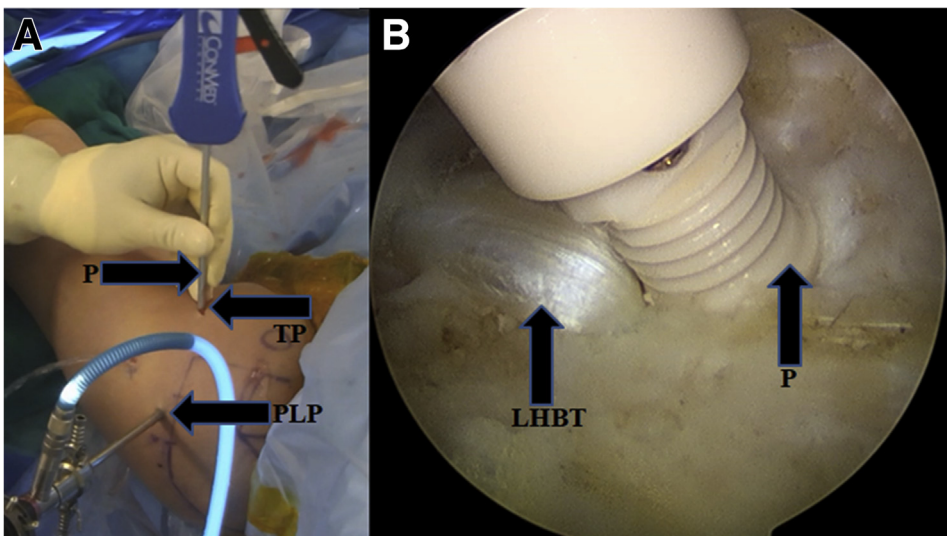


Fig 12. Shows the outside and arthroscopic view of left shoulder. **Fig 12 A** shows that the arthroscope is inserted through the postero-lateral portal (PLP). Through the tenodesis portal (TP) Poplok anchor (P) is inserted. It can be noted that the elbow is fully extended. **Fig 12 B** shows arthroscopic view of left shoulder as viewed from postero-lateral portal. The long head of biceps tendon (LHBT) is in the tunnel drilled for tenodesis and Poplok anchor (P) is at the opening of the tenodesis tunnel. The LHBT is held in this position by gently holding the ultrabraid from the posterior aspect without much traction. Poplok anchor is then malleted gently to fix the tendon in desired position.

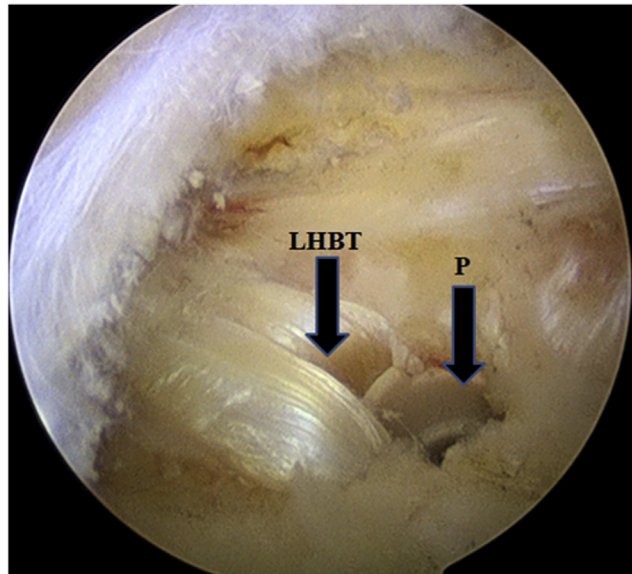


Fig 13. Shows the arthroscopic view of left shoulder as viewed from the postero-lateral portal. The long head of biceps tendon (LHBT) is fixed in the tenodesis tunnel with the poplok anchor (P). Poplok anchor is completely buried in the tunnel.

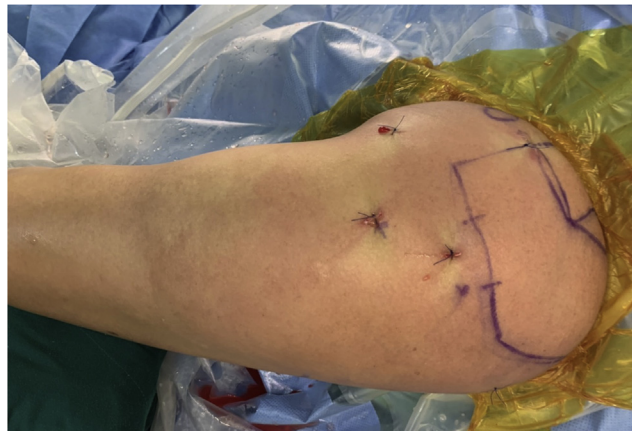

Fig 14. Shows the outside view of left shoulder. The tenodesis is completed and the portals are sutured with 3-0 ethilon. Dressing is done and the patient is shifted out of the operating room after recovering from general anaesthesia.

Table 1. Pearls and pitfalls

Pearls

1. The tension in the tendon can be adjusted as desired
2. The chance of tendon damage by fixation device is reduced
3. No added extra cost compared with other techniques
4. No cosmetic popeye deformity or pain

Pitfalls

1. Tenotomy and tenodesis portals are needed
 2. Drilling of the tunnel should be made carefully so as not to breach the far cortex
 3. The elbow should be extended, and tension on the tendon should be very gentle
 4. The PopLok anchor should be malletted gently
 5. The technique is technically demanding
-

Table 2. Advantages and disadvantages

Advantages
1. Safe for biceps tenodesis
2. Provides stability to the tendon
3. No loss of supination strength
4. Muscle does not atrophy
Disadvantages
1. If elbow is not extended or the tendon is not tensioned, may give rise to cramping pain
2. Longer rehabilitation

plane perpendicular to the shaft of humerus. By doing this, the guide pin is directed away from the axillary nerve. The position of the axillary nerve is at the level of the superior border of pectoralis major.^{9,10}

Malleting of the guide wire to breach the second cortex is done only as a precautionary method to avoid looping around any vital structure in the posterior aspect. The diameter of the hole is matched to the diameter of the tendon, usually ~5.5 to 6 mm. Theoretically, there is concern about a potential complication such as fracture of the proximal humerus. We breach the far cortex only with a 2.4-mm guide wire. Moreover, as shown by McCrum et al.,¹¹ the incidence of postoperative fracture after tenodesis is 0.085%. This is also reported in subpectoral tenodesis and not in suprapectoral tenodesis.¹¹ The tunnel is in the metaphyseal region and not in the diaphyseal region, thus decreasing the chance of iatrogenic fracture.

There are many methods for fixing the tendon to the bone: interference screw, suture anchor, and Endobutton have been proposed. Biomechanically, there is no statistical significant difference between the use of screws and suture anchors, as shown by Patzer et al.¹² and Dekker et al.¹³ There is a chance of screw threads damaging the tendon as it goes inside the tunnel. In the postoperative period, the tendon may be damaged by the screw threads as it is compressed against the bone in the tunnel.¹⁴

The PopLok anchor avoids such problems (Table 1). The technique proposed by Kongmalai¹⁵ also uses Poplok anchors, but differs from our technique in 2 ways. First, the drilled hole is unicortical; second, the tendon is fixed epiosseously. We believe that our method provides a more stable and secure fixation of the long head of biceps tendon.

Biceps tenodesis with bicortical drilling at the distal half of the bicapital groove using a PopLok anchor is a safe and stable method of tenodesis (Table 2). The chance of axillary nerve injury is very minimal, as it is ~2 to 2.5 cm distal. A pitfall of this technique is that it is technically demanding (Table 1).

References

1. Bass E. Tendinopathy: Why the difference between tendinitis and tendinosis matters. *Int J Ther Massage Bodywork* 2012;5:14-17.
2. Beall DP, Williamson EE, Ly JQ, Adkins MC, Emery RL, Jones TP, Rowland CM. Association of biceps tendon tears with rotator cuff abnormalities: Degree of correlation with tears of the anterior and superior portions of the rotator cuff. *AJR Am J Roentgenol* 2003;180:633-639.
3. Patel KV, Bravman J, Vidal A, Chrisman A, McCarty E. Biceps tenotomy versus tenodesis. *Clin Sports Med* 2016;35:93-111.
4. Nho SJ, Reiff SN, Verma NN, Slabaugh MA, Mazzocca AD, Romeo AA. Complications associated with subpectoral biceps tenodesis: Low rates of incidence following surgery. *J Shoulder Elbow Surg* 2010;19:764-768.
5. Yeung M, Shin JJ, Lesniak BP, Lin A. Complications of arthroscopic versus open biceps tenodesis in the setting of arthroscopic rotator cuff repairs: An analysis of the American Board of Orthopaedic Surgery database. *J Am Acad Orthop Surg* 2020;28:113-120.
6. Moon SC, Cho NS, Rhee YG. Analysis of "hidden lesions" of the extra-articular biceps after subpectoral biceps tenodesis: The subpectoral portion as the optimal tenodesis site. *Am J Sports Med* 2015;43:63-68.
7. Kerschbaum M, Alt V, Pfeifer C. The all-inside arthroscopic loop tenodesis procedure to treat long head of biceps tendon pathologies. *Arthrosc Tech* 2019;22(8):e1551-e1554.
8. Sanders B, Lavery KP, Pennington S, Warner JJP. Clinical success of biceps tenodesis with and without release of the transverse humeral ligament. *J Shoulder Elbow Surg* 2012;21:66-71.
9. Lancaster S, Smith G, Ogunleye O, Packham I. Proximity of the axillary nerve during bicortical drilling for biceps tenodesis. *Knee Surg Sports Traumatol Arthrosc* 2016;24:1925-1930.
10. Ding DY, Gupta A, Snir N, Wolfson T, Meislin RJ. Nerve proximity during bicortical drilling for subpectoral biceps tenodesis: A cadaveric study. *Arthroscopy* 2014;30:942-946.
11. McCrum CL, Alluri RK, Batech M, Mirzayan R. Complications of biceps tenodesis based on location, fixation, and indication: A review of 1526 shoulders. *J Shoulder Elbow Surg* 2019;28:461-469.
12. Patzer T, Kircher J, Krauspe R. All-arthroscopic suprapectoral long head of biceps tendon tenodesis with interference screw-like tendon fixation after modified lasso-loop stitch tendon securing. *Arthrosc Tech* 2012;1:e53-e56.
13. Dekker TJ, Peebles LA, Preuss FR, Goldenberg BT, Dornan GJ, Provencher MT. A systematic review and meta-analysis of biceps tenodesis fixation strengths: Fixation type and location are biomechanically equivalent. *Arthroscopy* 2020;36:3081-3091.
14. Koch BS, Burks RT. Failure of biceps tenodesis with interference screw fixation. *Arthroscopy* 2012;28:735-740.
15. Kongmalai P. Arthroscopic extra-articular suprapectoral biceps tenodesis with knotless suture anchor. *Eur J Orthop Surg Traumatol* 2019;29:493-497.