



## Featured Operative Technique

# The Modified Skate Flap: A New Technique for Nipple-Areola Complex Reconstruction in Implant-Based Breast Reconstruction

Lee L. Q. Pu, MD, PhD<sup>o</sup>; and Ping Song, MD

Aesthetic Surgery Journal Open Forum  
2021, 1–10

© 2021 The Aesthetic Society.

This is an Open Access article distributed under the terms of the Creative Commons Attribution-NonCommercial-NoDerivs licence (<http://creativecommons.org/licenses/by-nc-nd/4.0/>), which permits non-commercial reproduction and distribution of the work, in any medium, provided the original work is not altered or transformed in any way, and that the work is properly cited. For commercial re-use, please contact [journals.permissions@oup.com](mailto:journals.permissions@oup.com)  
DOI: 10.1093/asjof/ojab004  
[www.asjopenforum.com](http://www.asjopenforum.com)

**OXFORD**  
UNIVERSITY PRESS

**Abstract**

Nipple-areola complex (NAC) reconstruction is an important part of breast reconstruction. Although several techniques for NAC reconstruction have been described in the literature, the long-term outcomes after NAC reconstruction remain less satisfactory, especially following implant-based breast reconstruction. The authors reported their newly developed technique for NAC reconstruction in implant-based breast reconstruction. The authors describe their modified skate flap, by preserving more dermal tissues from the skate flap, for NAC reconstruction, following implant-based breast reconstruction. Additional derma-fat grafts, harvested from the full-thickness skin graft site, are also added to the reconstructed nipple to ensure long-term shape, size, and projection of the reconstructed nipple. A total of 30 patients underwent such a NAC reconstruction after successful implant-based breast reconstruction by the senior author. The minimum follow-up time was 1 year. No significant surgical complications have been observed in their series of 30 patients, and only a minor office procedure was performed subsequently in 6 patients (4 unilateral and 2 bilateral) to improve the shape of the reconstructed nipple. During a minimum of a 1-year follow-up period, outcomes with the authors' technique in 30 patients are satisfactory; good size, shape, and projection of the reconstructed nipple are maintained. The long-term outcome of NAC reconstruction after implant-based breast reconstruction can be optimized with their modified skate flap by using all available flap tissue and with the addition of derma-fat grafts. The authors' technique can be used safely for NAC reconstruction after implant-based breast reconstruction with good outcome and high patient satisfaction.

Editorial Decision date: December 11, 2020; online publish-ahead-of-print February 23, 2021.

Nipple-areola complex (NAC) reconstruction is an important part of breast reconstruction and serves as an aesthetic highlight to breast reconstruction. Without NAC reconstruction, the absence of a visual central papule gives the impression that breast reconstruction is incomplete. Therefore, NAC reconstruction is an important component of breast reconstruction and should be offered to all patients after breast reconstruction. It is an integral part of breast reconstruction, as both patients and plastic surgeons view it as a marker for the completion of breast reconstruction.<sup>1</sup> In addition, NAC reconstruction is shown to

improve the psychosocial and sexual well-being in women after breast cancer treatment based on self-reported patient outcomes.<sup>2</sup>

---

From the Division of Plastic Surgery, Department of Surgery, University of California Davis Medical Center, Sacramento, CA.

**Corresponding Author:**

Dr Lee L. Q. Pu, Division of Plastic Surgery, Department of Surgery, University of California at Davis, 2221 Stockton Blvd., Suite 2123, Sacramento, CA 95817, USA.  
E-mail: [llpu@ucdavis.edu](mailto:llpu@ucdavis.edu)

Although several techniques for NAC reconstruction have been described in the literature, the long-term outcome after any type of NAC reconstruction remains less than satisfactory, especially following implant-based breast reconstruction.<sup>3-6</sup> In general, NAC reconstruction may be performed effectively based on autologous breast reconstruction since there is adequate local soft tissue for reconstruction. However, for alloplastic breast reconstruction, the NAC reconstruction may present a challenge due to a lack of tissue over the breast implant to recruit for papule creation.<sup>4</sup> In addition, the mastectomy scar over the breast mound may also impact the location and outcome of the NAC reconstruction.

In this report, we describe our modified skate flap technique, for NAC reconstruction in an implant-based breast reconstruction. We emphasize the preservation of maximal dermal tissues from the skate flap. In addition, derma-fat grafts, harvested from the full-thickness skin graft site, are added to the reconstructed nipple to maintain long-term size, shape, and projection of the reconstructed nipple. The clinical outcome following our described technique, and our patients stated satisfaction after NAC reconstruction, is also reported.

## METHODS

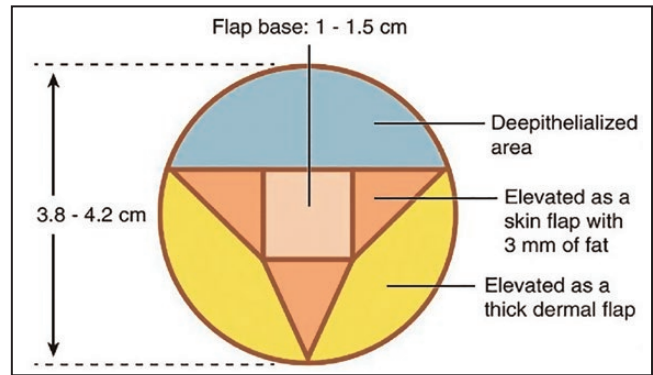
### Preoperative Considerations

NAC reconstruction is indicated for all patients after their implant-based breast reconstruction is completed. In general, the timing of NAC reconstruction is 2 to 3 months after primary or secondary breast reconstruction, and once no major revisions are indicated for the reconstructed breast in terms of size, shape, or position. If radiation has been performed on the reconstructed breast, we prefer to postpone the NAC reconstruction for 1 year. This allows the radiation damage to the breast skin to subside so that the overall complication of NAC reconstruction, such as delayed wound healing, can be minimized. If the radiation changes over the reconstructed breast have not been resolved, or if there are other soft tissue concerns, the timing of NAC reconstruction can further be postponed.

The location of the mastectomy scar over the reconstructed breast can be problematic because it may interfere with the new nipple position over the reconstructed mound. Ideally, the new nipple position should be at the highest projecting point of the breast mound. However, it also can be placed higher or lower than the peak of the breast mound—although a lower placement of the new nipple is preferred, as to avoid a high-riding appearance of the reconstructed nipple.

### Surgical Technique

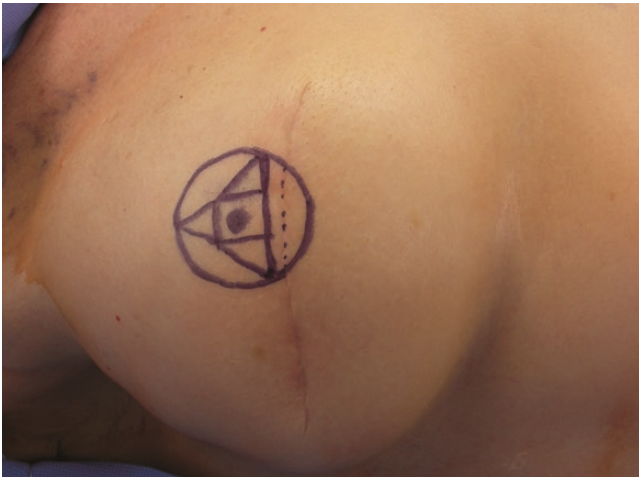The base of the flap is designed between 1 and 1.5 cm and the diameter of the new areola is 3.8 or 4.2 cm depending



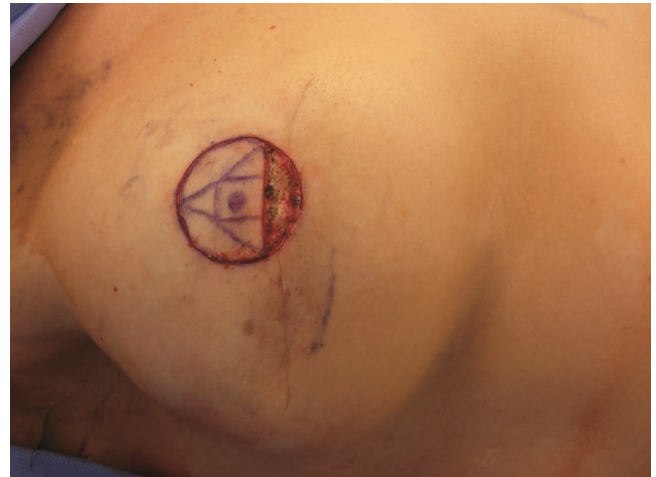**Figure 1.** A schematic diagram showing the preoperative marking and design of our modified skate flap.

on the expected final size and projection of the reconstructed nipple (Figure 1). The design of our modified skate flap can be orientated either superiorly or inferiorly to accommodate the location of the mastectomy scar (Figure 2). The upper or lower third of the skin within the designed areolar circle is de-epithelialized (Figure 3). A thick dermal flap from both sides is then quickly raised using a scalpel to the designed lines. Next, 3 true triangular adipocutaneous flaps each with adequate fat are then carefully raised with scissors but the base of the skate flap is carefully preserved (Figure 4). Within the base of the flap, each triangular arm is then elevated and brought centrally, with attention to carrying adequate fat under the central adipocutaneous base for a reliable blood supply. Both medial and lateral skin flap wings are approximated at the base of the reconstructed nipple with 5-0 vicryl suture, if the skate flap is based superiorly, and the central triangular skin flap is then brought down to join the first approximation also with 5 vicryl suture. Each side of the skin flap can be approximated at the dorsum of the reconstructed nipple and a 180 degree opposite if the skate flap is based inferiorly (Figure 5). At this point, excess skin in each corner is marked and de-epithelialization is performed (Figure 6). In this way, additional dermal-cutaneous tissue can be internalized to add projection of the reconstructed nipple. In general, the size of a reconstructed nipple with our technique is initially greater than 1 × 1 cm and projection greater than 1 cm after immediate reconstruction (Figure 7).

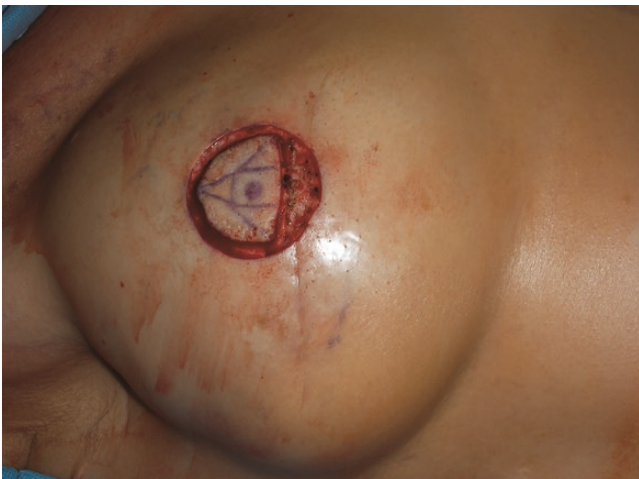The skin graft for areolar reconstruction can be harvested from any location in which the patient has a previous scar. However, the authors prefer to harvest a full-thickness skin graft from the suprapubic area or within the inguinal crease. In addition, derma-fat grafts can be harvested from the same location of the skin graft donor site. A 3.8- or 4.2-cm cookie cutter is used to outline the full-thickness skin graft site. A full-thickness skin graft is then harvested and defatted. Within the planned ellipsoid excision of the full-thickness skin graft, derma-fat graft (4 × 3 × 3 mm) can



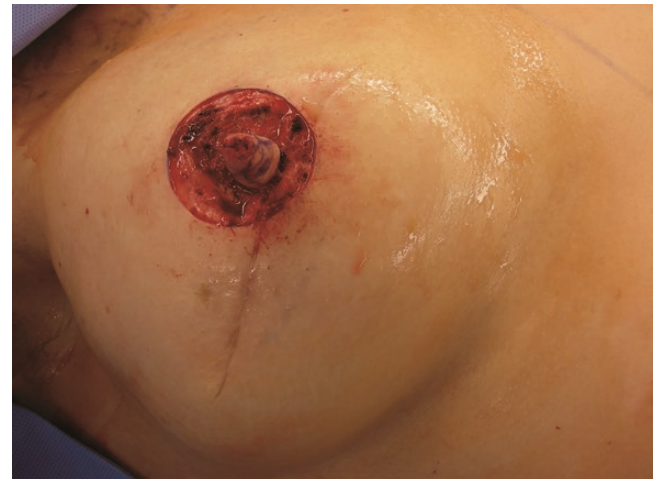**Figure 2.** An intraoperative view of a 59-year-old woman (Figures 2-10 are all from the same patient) showing the design of our modified skate flap. In this case, the design of the flap is based inferiorly to accommodate the location of the mastectomy scar.



**Figure 3.** Completion of de-epithelialization of the inferiorly based skate flap.



**Figure 4.** Completion of adjacent skin flap dissection to the designed lines and 3 triangular true adipo-cutaneous flaps elevation except for the base of the skate flap in the center before it is elevated.



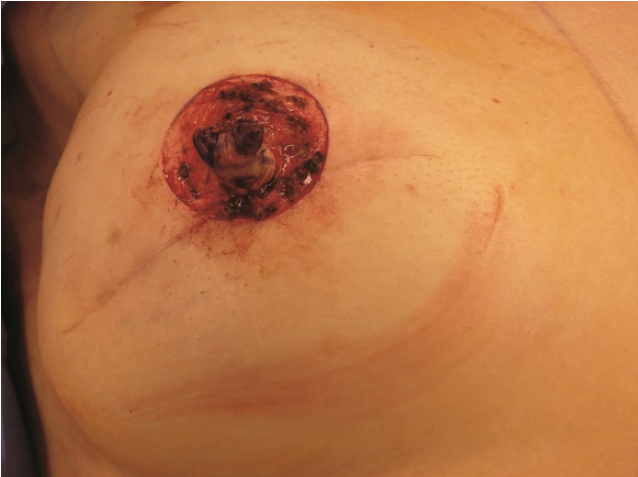**Figure 5.** Completion of the elevated skate flap and approximation of the medial and lateral skin flaps.

be taken after de-epithelialization of the excess triangles (Figure 8).

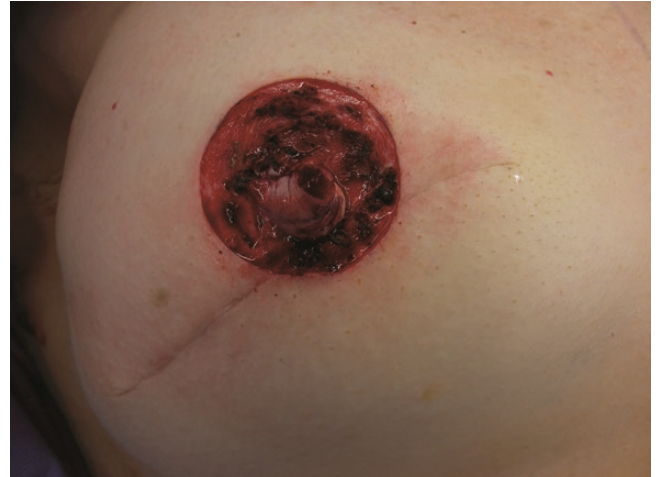Derma-fat graft can be inserted into the reconstructed nipple, before its final closure, to add additional projection. Two derma-fat grafts are placed inside each reconstructed nipple freely without fixation and the skate flap opening at each corner is then closed with a 5-0 chromic suture (Figure 9). We find that 2 pieces are needed for each reconstructed nipple, and optimal projection is achieved with this approach. The readied skin graft is then placed around the reconstructed nipple, through an appropriate opening centrally, to form the new areola, and both inner and outer

edges closed with absorbable suture. The donor site incision is closed in 2 layers accordingly (Figure 10). At the end of the procedure, the reconstructed nipple is protected with a nipple protector, and the areolar skin graft is immobilized with steri-strips. An edited video for the procedure is included (Video).

Postoperatively, the nipple protector and steri-strips are removed in 7 days. Afterward, the reconstructed nipple and areola skin graft is covered with daily Xeroform dressing for an additional 2 weeks. The time for complete healing of NAC reconstruction can be achieved in 2 to 3 weeks.



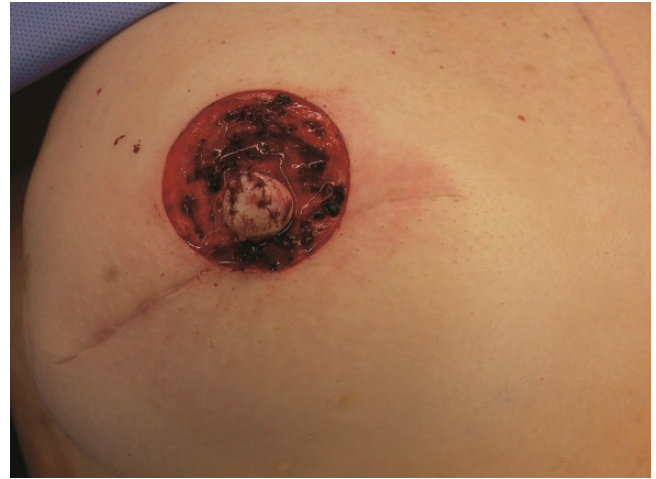**Figure 6.** Near completion of closing the skate flap. Two corners (marked in blue) of the “excess” skin in the reconstructed nipple will be reserved.



**Figure 7.** An intraoperative view showing completion of the de-epithelized skins on both corners. They are inserted into the flap to add more tissues for the nipple reconstruction.



**Figure 8.** Two harvested and prepared derma-fat grafts, each about  $4 \times 3 \times 3$  mm.



**Figure 9.** Completion of the reconstructed nipple after insertion of derma-fat grafts.

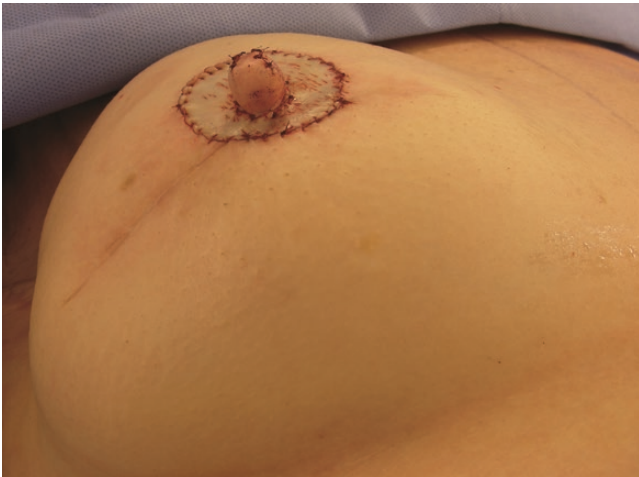## Patients

Between August 2010 and July 2018, a total of 30 female patients with a mean age of 52 years old (range from 36 to 70 years) underwent a NAC reconstruction after successful implant-based breast reconstruction by the senior author. Among them, 21 patients had bilateral NAC reconstructions and 9 patients had a unilateral NAC reconstruction. Thus, a total of 51 NAC reconstructions were performed. The surgical outcomes, including patient satisfaction and postoperative complications, were retrospectively reviewed by clinical documentation and postoperative photography for each patient. The study was approved by the University of California Davis Medical Center Institutional Review Board. The minimum follow-up time was 1 year, with a range of 1 to

8 years post-NAC reconstruction. Photographs were taken at the follow-up visit. Each patient was asked whether she felt satisfactory about the long-term result after NAC reconstruction in terms of size, shape, and projection of her reconstructed nipples. Answers were documented in the chart.

## RESULTS

No surgical complications that required reoperation were observed in this series during the follow-up period. Adequate size, shape, and projection of each reconstructed nipple are well maintained. Twenty-four patients (80%) reported feeling satisfactory about their



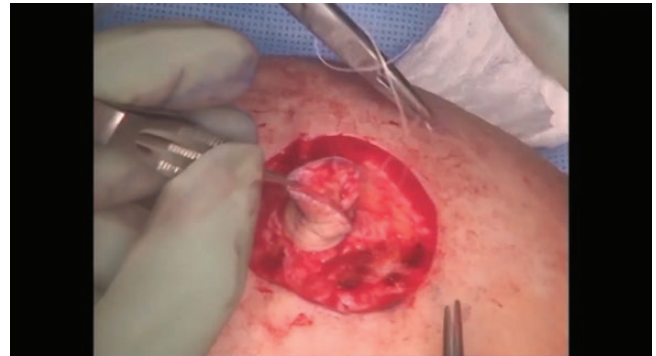**Figure 10.** Immediate result after completion of the nipple reconstruction and areolar skin grafting.

nipple reconstruction in terms of the size, shape, and projection. Six patients (20%, 4 unilaterally and 2 bilaterally) reported feeling concerned about the shape of their reconstructed nipples due to some degree of excess skin that developed over the reconstructed nipple. These 6 patients subsequently underwent minor in-office revisions or combined with additional revision to the breast mound in the operating room. Of note, these patients objectively maintained both adequate size and projection of their reconstructed nipples. The excess skin was easily managed by simple de-epithelization, and subsequent skin edge re-approximation for wound closure (case 3). After revision, the shape of each reconstructed nipple improved without compromising the blood supply to the reconstruction. After revision, all 30 patients (100%) in this series report feeling satisfactory about their final reconstructed nipples with maintained good size, shape, and projection although the objective measurement was not performed. Minimal changes are noticed in those patients who were followed longer than 1 year after a NAC reconstruction with our technique.

## Case Examples

### Case 1

A 39-year-old woman completed successful bilateral breast reconstructions with silicone implants (Immediate, 2-stage). Our refined modified skate flap, with insertion of 2 derma-fat grafts, was performed. Her postoperative course was uneventful. The patient is quite happy with the overall appearance of her NAC reconstruction. At 1-year follow-up, adequate size, shape, and projection of the bilateral reconstructed nipples have been well maintained (Figure 11A-C).



**Video.** Watch now at <http://academic.oup.com/asjopenforum/article-lookup/doi/10.1093/asjof/ojab004>

### Case 2

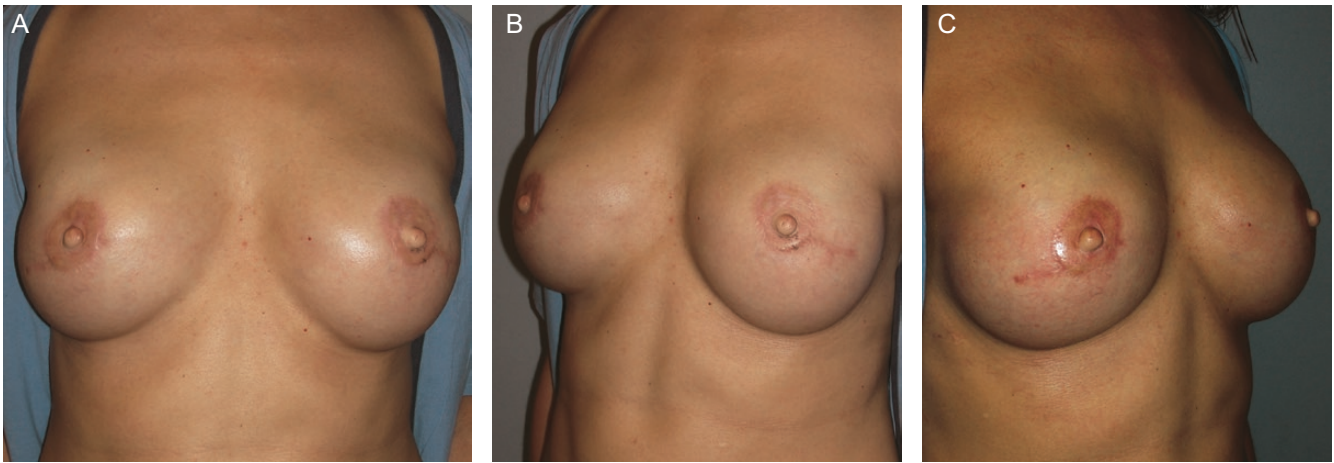
A 47-year-old woman completed successful bilateral breast reconstructions with silicone implants (Immediate, 1-stage). Our refined modified skate flap, with insertion of 2 derma-fat grafts, was performed. Her postoperative course was also uneventful. The patient is quite happy about the overall outcome of her NAC reconstruction. At her 10-month follow-up, good size, shape, and projection of each reconstructed nipple are noted (Figure 12A-C). At her 10-year follow-up, good size, shape, and projection of each reconstructed nipple have been reasonably well maintained (Figure 13A-C).

### Case 3

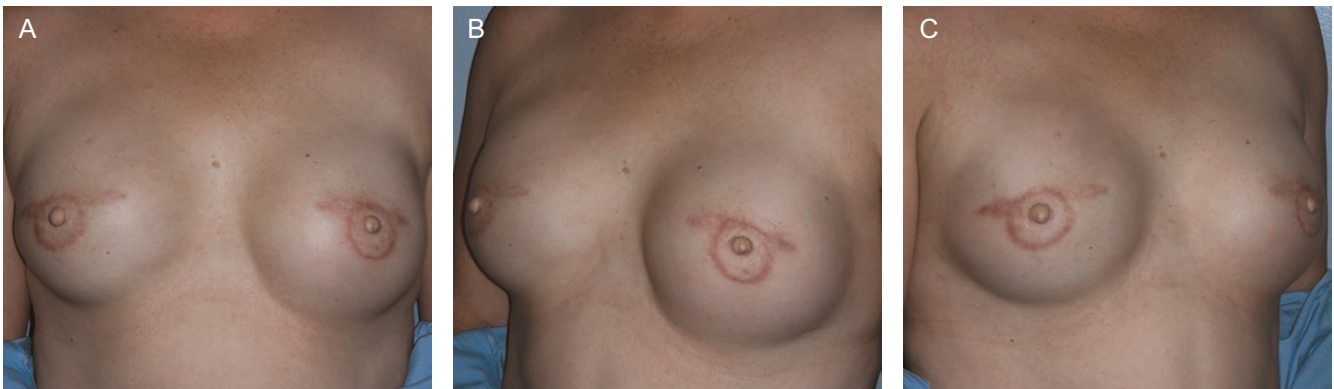A 60-year-old woman completed successful bilateral breast reconstruction with silicone implants by another surgeon (Delayed, 2-stage). Our refined modified skate flap, with insertion of 2 derma-fat grafts, was performed. Her postoperative course was also uneventful. During at early follow-up, the patient reported concerns about the shape of both her reconstructed nipples (Figure 14A). Both reconstructed nipples were revised at 8 months after her initial NAC reconstruction. The revision was simply performed by de-epithelized marked excess skin and simple skin edge approximation in the dorsal aspect of each reconstructed nipple (Figure 14B). After revision, she was pleased with the outcome of her reconstructed nipples. At her 4-year follow-up (3.5 years after revision), the size, shape, and projection of the bilateral reconstructed nipples are well maintained (Figure 14C).

## DISCUSSION

Implant-based breast reconstruction remains commonly used after mastectomy. While NAC reconstruction



**Figure 11.** Results at 1-year follow-up with anteroposterior (AP) (A) and oblique views (B and C) in a 39-year-old woman. The size, shape, and projection of the reconstructed nipple on each side are well maintained.



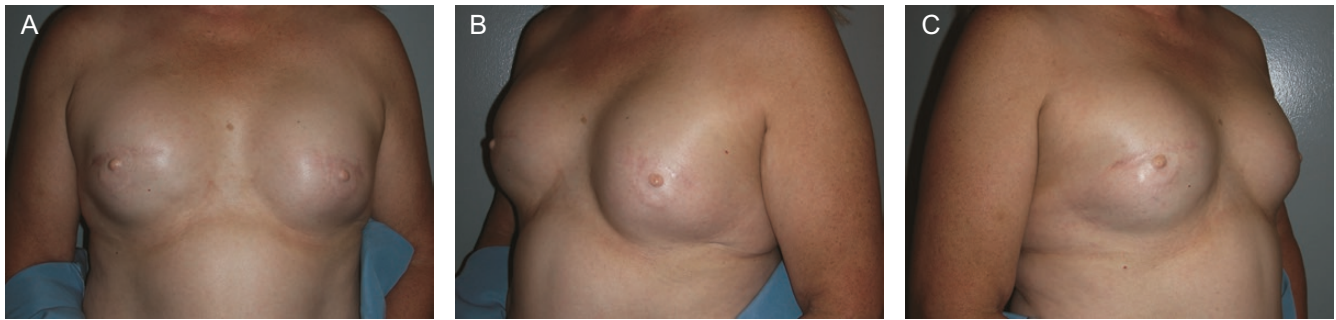**Figure 12.** Results at 10 months follow-up with AP (A) and oblique views (B and C) in a 47-year-old woman (Figures 12 and 13 are from the same patient). Good size, shape, and projection of each reconstructed nipple are well maintained.

represents a final stage in breast reconstruction, due to relatively thin mastectomy skin flaps, NAC reconstruction can be challenging for plastic surgeons in alloplastic-based setting. Long-term wise, the reconstructed NAC following implant-based reconstruction may be less than satisfactory to both patients and surgeons, often due to loss of papule projection and decrease in the overall size. Although several “new” techniques have been reported recently, the long-term outcomes following those techniques remain questionable and their reoperation rates including revision or redo NAC reconstruction also remain unknown.<sup>7-10</sup>

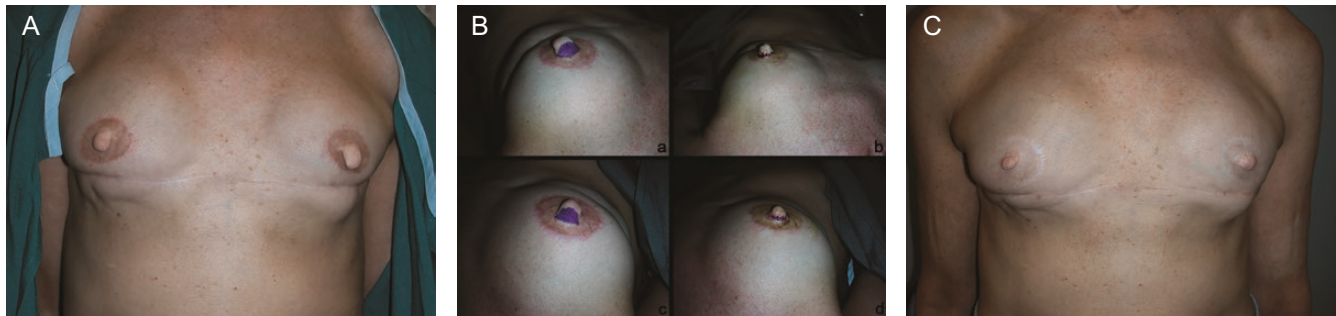
Several less popular but revised techniques for NAC reconstruction, such as the modified C-V flap or the double-opposing periareolar flap, have been described recently.<sup>7,10,11</sup> However, all NAC reconstructions lose a significant degree of projection over time and satisfactory long-term result is poor, especially after implant-based breast reconstruction. Several factors are identified which

contribute to the loss of nipple projection after reconstruction over time. These factors are likely multifactorial and include external pressure, lack of structural support, fat necrosis, and cicatricial contracture.<sup>11</sup> Therefore, utilizing more living tissue and/or adding free derma-fat grafts may potentially provide more structural support to overcome these potential factors.

In our series, adequate size, shape, and projection of each reconstructed nipple were well maintained, at a minimum of 1-year follow-up. Twenty-four patients (80%) were satisfied regarding their reconstructed nipples in terms of the size, shape, and projection. Six patients (20%, 4 unilateral and 2 bilateral) had a concern about the shape of their reconstructed nipples due to some degree of excess skin in the early postoperative period. This subgroup subsequently underwent a minor revisionary procedure to address the excess skin, with all patients reporting improvement in satisfaction afterward. In spite of the excess



**Figure 13.** Results at 10 years follow-up with AP (A) and oblique views (B and C) in the same patient. The size, shape, and projection of each reconstructed nipple are still reasonably well maintained.



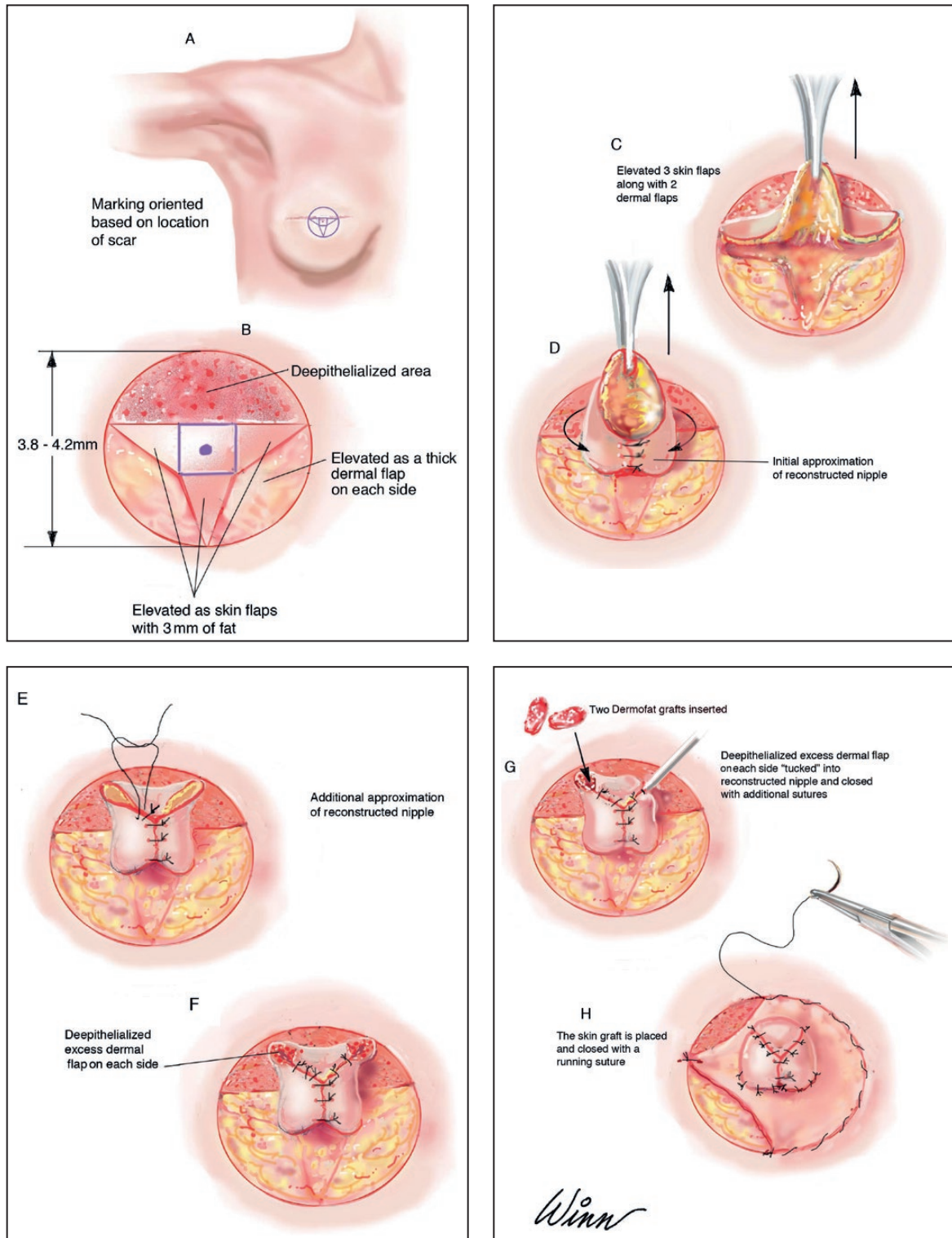
**Figure 14.** (A) Results at 8 months after initial reconstruction with noted excess skin in each reconstructed nipple in a 60-year-old woman. (B) Intraoperative views show the results before and immediately after revision. (C) Results at 3 years and 4 months after revision (4 years after the initial reconstruction). The size, shape, and projection of each reconstructed nipple are still well maintained.

skin, these nipples possessed adequate size and projection. After the simple revision procedure, all 30 patients (100%) in this series reported satisfactory outcomes of their nipple reconstruction in terms of size, shape, and projection. It remains unknown whether our revision rate would be appropriate since there are no equivalent data available from the reported series for comparison.<sup>3-8</sup> Clinical photographs of the reconstructed nipples show maintenance of adequate shape, size, and projection. The final and long-lasting projection of each reconstructed nipple appears to be adequate (Cases 1, 2, and 3).

In contrast to the standard skate flap technique,<sup>1</sup> all available soft tissue is used in our modified technique for nipple reconstruction (Figure 1). Besides the de-epithelized segments, no extra flap tissue is discarded, and additional dermal tissues, with an independent blood supply, are used for the nipple reconstruction. This ensures the best possible result by recruiting additional living flap tissue into the reconstruction (Figure 8). In addition, placement of derma-fat grafts may also play a role in maintaining good long-term projection with no additional donor site for the patient. Derma-fat graft, or Alloderm, has been used by others to improve the projection of the reconstructed nipple in primary or secondary reconstruction.<sup>11-13</sup> In our

experience, 20% of our nipple reconstructions developed some degree of excess skin once completely healed. This may be because less skin is removed during the initial nipple reconstruction by using our modified skate flap technique. However, this issue can be easily remedied by de-epithelizing the portion of the excess skin and re-approximating the de-epithelized skin edges in an office setting (Figure 14B). Once the reconstructed nipple has healed, its size, shape, and projection can be maintained to approximately 4–5 mm without significant changes after 1 year (Cases 2 and 3). We believe that our new and modified technique for a NAC reconstruction described in the study may result in a relatively well-maintained projection as well as the size and shape of the reconstructed nipple and can be a preferred technique of choice for an implant-based breast reconstruction.

Our modified skate flap with the addition of derma-fat grafts will provide patients with a durable and well-maintained nipple projection (Figure 15). We believe that the reconstructed full-thickness skin graft areola may be better in appearance than simple skin tattooing and more cost-effective. However, one drawback is longer operative time and minor wound healing delay around the skin graft site. Despite this, minor delayed healing is treated primarily



**Figure 15.** (A-H) Schematic diagrams showing the senior author's technique when the design of the flap based superiorly.

with local wound care without additional skin grafting in the senior author's practice. A full-thickness skin graft donor site will result in an additional scar. Fortunately, our patients often have excess skin, existing scar, or a dog-ear

somewhere on their body—to harvest a full-thickness skin graft is usually not a problem and is well tolerated.

We prefer to reconstruct the areolar circle with a full-thickness skin graft. A well-healed areolar skin graft site



is more mimic to a native areola with a more natural definition of its border and an above adjacent skin level's appearance. In addition, postoperative skin tattooing to the skin grafted areolar circle or reconstructed nipple is not necessary in most of the Caucasian women from the patient's standpoint of the view in the senior author's practice. For dark skin women, the NAC skin tattooing is performed 1 year after the completion of their reconstructions by professional tattoo specialists.

A NAC reconstruction in an implant-based reconstruction is particularly challenging for plastic surgeons since there is not enough tissue over the breast implant that can be used for a nipple reconstruction with any techniques. Although a skate flap or a C-V flap is commonly performed by most of the plastic surgeons for a nipple reconstruction, the long-term result from either type of reconstruction has not been good. Based on the authors' observation from other surgeons' result, it is difficult to maintain even any meaningful projection and shape of a reconstructed nipple. No more available tissue can be used to reconstruct a nipple is a common statement for such a poor result. At the present time, an optimal and reliable technique for an implant-based nipple reconstruction that may satisfy both patients and surgeons during a long-term follow-up has not been described in the literature. Any technique that can potentially incorporate more available tissues for a nipple reconstruction in an implant-based reconstructed breast may be a solution.

A "Half-Dome" technique for a NAC reconstruction following implant-based breast reconstruction is described as a useful modification of the C-V flap. However, the average maintained nipple projection is only 2 mm at 12 months.<sup>7</sup> A novel triple flap design for NAC reconstruction is reported, but again reported projection is only 1.6 mm (range 0-3 mm) in 12 months.<sup>8</sup> A new dermal fat flap for NAC reconstruction following implant-based breast reconstruction in radiated patients is also reported with an average projection of 3.3 mm after 12 months.<sup>9</sup> Furthermore, an immediate nipple reconstruction with a modified C-V flap during implant and tissue expander exchange has been evaluated to possibly provide satisfactory outcome compared with conventional delayed nipple reconstruction with the same technique.<sup>10</sup> A keyhole flap can also be utilized for a NAC reconstruction but it is used primarily after autologous breast reconstructions. However, the long-term outcome with this technique for NAC reconstruction after implant-based reconstruction remains unclear.<sup>14</sup>

The limitations of this report include the retrospective nature of the study design and relatively small clinical series with a single surgeon. In addition, no systematic objective measurement for long-term nipple projection was conducted. Without comparative measurements, it remains

unclear what percentage of nipple projection is maintained with our technique for NAC reconstructions. However, patient-reported satisfaction after NAC reconstruction, with a minimal 1-year follow-up, may also represent a valid evaluation of long-term outcome in combination with the surgeon's assessment after a NAC reconstruction with our technique.

## CONCLUSIONS

The long-term outcome of NAC reconstruction after implant-based breast reconstruction can be optimized with our modified skate flap by using all available flap tissue and with the addition of derma-fat grafts. Our technique can be used safely for NAC reconstruction after implant-based breast reconstruction with a good outcome. Our long-term results are satisfactory to both patients and surgeons. However, further large clinical series may be needed to confirm the efficacy of our technique.

## Disclosures

The authors declared no potential conflicts of interest with respect to the research, authorship, and publication of this article.

## Funding

The authors received no financial support for the research, authorship, and publication of this article.

## REFERENCES

1. Sisti A, Grimaldi L, Tassinari J, et al. Nipple-areola complex reconstruction techniques: a literature review. *Eur J Surg Oncol.* 2016;42(4):441-465.
2. Bykowski MR, Emelife PI, Emelife NN, Chen W, Panetta NJ, de la Cruz C. Nipple-areola complex reconstruction improves psychosocial and sexual well-being in women treated for breast cancer. *J Plast Reconstr Aesthet Surg.* 2017;70(2):209-214.
3. Losken A, Mackay GJ, Bostwick J 3rd. Nipple reconstruction using the C-V flap technique: a long-term evaluation. *Plast Reconstr Surg.* 2001;108(2):361-369.
4. Shestak KC, Gabriel A, Landecker A, Peters S, Shestak A, Kim J. Assessment of long-term nipple projection: a comparison of three techniques. *Plast Reconstr Surg.* 2002;110(3):780-786.
5. Zhong T, Antony A, Cordeiro P. Surgical outcomes and nipple projection using the modified skate flap for nipple-areolar reconstruction in a series of 422 implant reconstructions. *Ann Plast Surg.* 2009;62(5):591-595.
6. Otterburn DM, Sikora KE, Losken A. An outcome evaluation following postmastectomy nipple reconstruction using the C-V flap technique. *Ann Plast Surg.* 2010;64(5):574-578.
7. Chen W, Fishman JE, de la Cruz C. Nipple areola complex reconstruction with the "half-dome" technique following

- implant-based breast reconstruction. *Ann Plast Surg.* 2019;82(6):614-617.
8. Krogsgaard SHH, Carstensen LF, Thomsen JB, Rose M. Nipple reconstruction: a novel triple flap design. *Plast Reconstr Surg Glob Open.* 2019;7(5):e2262.
  9. Rem K, Al Hindi A, Sorin T, Ozil C, Revol M, Mazouz Dorval S. Nipple reconstruction after implant-based breast reconstruction in radiated patients: a new safe dermal flap. *J Plast Reconstr Aesthet Surg.* 2016;69(5):617-622.
  10. Hong KY, Kim YE, Minn KW, Jin US. Immediate nipple reconstruction during implant-based breast reconstruction. *Aesthetic Plast Surg.* 2017;41(4):793-799.
  11. Gougoutas AJ, Said HK, Um G, Chapin A, Mathes DW. Nipple-areola complex reconstruction. *Plast Reconstr Surg.* 2018;141(3):404e-416e.
  12. Eo S, Kim SS, Da Lio AL. Nipple reconstruction with C-V flap using dermofat graft. *Ann Plast Surg.* 2007;58(2):137-140.
  13. Garramone CE, Lam B. Use of AlloDerm in primary nipple reconstruction to improve long-term nipple projection. *Plast Reconstr Surg.* 2007;119(6):1663-1668.
  14. Chen JI, Cash CG, Iman AH, Spiegel AJ, Cronin ED. Keyhole flap nipple reconstruction. *Plast Reconstr Surg Glob Open.* 2016;4(5):e703.