Observational Study

Medicine®

OPEN

Clinical outcomes of medial collateral ligament injury in total knee arthroplasty

Xiaomeng Wang, MD, Huixin Liu, MD, Pengkai Cao, MD, Chang Liu, MD, Zhenyue Dong, MD, Jianchao Qi, MD, Fei Wang, DD*

Abstract

Intraoperative injury to the medial collateral ligament (MCL) during total knee arthroplasty (TKA) is a rare but severe complication. The main treatment methods are primary repair and revision with a more constrained implant; however, the clinical outcomes of primary reconstruction without a constrained implant have rarely been reported.

A retrospective study was performed to evaluate the prevalence of iatrogenic injury to the MCL during primary TKA, and to report the clinical outcomes of MCL reconstruction without the use of a constrained device.

A total of 1749 patients (2054 knees) underwent primary TKA between 2007 and 2013 and were retrospectively evaluated. Seventeen patients (0.83%) experienced an MCL injury intraoperatively, and the remaining 1732 patients (2037 knees) were considered as the controls. We attempted to reconstruct the MCL with an unconstrained prosthesis in all patients. The Knee Society Score (KSS) was used to evaluate knee function after an average 51-month follow-up (range, 36–72 months).

No patients were lost during the follow-up period. In the MCL injury group, the mean KSS was 84.7 for function and 87.7 for pain, while the scores were 87.9 and 90.6, respectively, in the control group. No patient treated with MCL reconstruction without increased prosthetic constraint experienced knee instability requiring revision.

MCL reconstruction without a constrained implant achieved excellent results for MCL injury during TKA.

Level of Evidence: Level IV, therapeutic study.

Abbreviations: KSS = Knee Society Score, MCL = medial collateral ligament, TKA = total knee arthroplasty.

Keywords: iatrogenic injury, instability, medial collateral ligament, reconstruction, total knee arthroplasty

1. Introduction

Medial collateral ligament (MCL) injury is one of the most severe complications associated with postoperative function after total knee arthroplasty (TKA), although it reportedly only occurs in 0.77% to 2.7% of cases.[1–3] The integrity of the MCL is crucial for the proper function and longevity of nonconstrained TKA.[4–8] Loss of the MCL leads to instability and is the most common cause of short-term failure of TKA.[9] Therefore, surgical treatment of MCL injury may be necessary to prevent the pathologic changes associated with chronic medial knee instability.

The choice of operation types to repair MCL injury include primary repair, augmentation, or use of a constrained knee prosthesis.[1,10,11] Some authors have reported successful treatment of intraoperative MCL injury by direct repair, augmentation, and the use of nonconstrained prostheses and/or thicker polyethylene inserts,[1,11,12] while others have advocated the use of constrained arthroplasty components without primary soft tissue repair or reconstruction.[13,14] However, constrained arthroplasty application could decrease the life of the prosthesis,[15] and a more constrained knee prosthesis would cause bone loss and make revision difficult. The treatment choices of nonconstrained prostheses and direct repair, augmentation, or thicker polyethylene inserts fail to restore the ligament tension and therefore affect the recovery of postoperative function, leading to a lower Knee Society Score (KSS) and a higher revision surgery rate.[3,15–17] The most likely explanation for this is the low healing potential of the MCL when its mid-substance is disrupted, which would not restore ligament strain.

In our clinical practice, double-bundle autograft MCL ligament reconstruction is used to restore the function of the MCL and is not affected by the MCL healing ability. This also avoids using constrained components and would not cause bone loss or revision difficulty. The purpose of the present study was to retrospectively evaluate the prevalence of iatrogenic MCL injury in primary TKA and determine the clinical outcomes of primary double-bundle MCL reconstruction with the semitendinosus ligament without the use of constrained components.

Editor: Giovanni Tarantino.

We declare that we have no financial and personal relationships with other people or organizations that can inappropriately influence our work; there is no professional or other personal interest of any nature or kind in any product, service, and/or company that could be construed as influencing the position presented in, or the review of, the manuscript entitled.

This material has not been published and is not under consideration elsewhere. The study was approved by the medical ethics committees of the Third Hospital of Hebei Medical University.

The Third Hospital of Hebei Medical University, Shijiazhuang, Hebei, China.

* Correspondence: Fei Wang, 139 Ziqiang Road, Shijiazhuang, 050051 Hebei, China (e-mail: doctorwf@yeah.net).

Copyright © 2017 the Author(s). Published by Wolters Kluwer Health, Inc. This is an open access article distributed under the terms of the Creative Commons Attribution-NonCommercial-ShareAlike 4.0 License, which allows others to remix, tweak, and build upon the work non-commercially, as long as the author is credited and the new creations are licensed under the identical terms.

Medicine (2017) 96:30(e7617)

Received: 6 December 2016 / Received in final form: 21 June 2017 / Accepted: 10 July 2017

http://dx.doi.org/10.1097/MD.0000000000007617

2. Methods

Institutional Review Board approval was obtained before study commencement. The records from 1749 patients (2054 knees) diagnosed with global arthrosis of the knee were retrospectively reviewed; these patients underwent TKA with a Link Gemini MK II (cruciate-retaining implant) from 2007 to 2013. Of these 2054 knees, 17 (0.83%) experienced an intraoperative iatrogenic MCL injury. Patients with severe valgus deformity (>30°), precedent injury of the MCL, previous knee surgery, or insufficient preoperative data were excluded. Preoperatively, no patient had any knee laxity or instability in the coronal plane detected during clinical examination.

Demographic and clinical data were collected preoperatively, including age, height, weight, body mass index, and KSS. There were 4 males and 13 females, with an average age of 63 years (range, 55–72 years) and an average body mass index of 34.4 kg/m^2 (range, 29.1–50.7 kg/m^2). The preoperative diagnosis was osteoarthritis in 15 patients, and inflammatory arthritis in 2 patients. The minimum follow-up was 36 months (average, 51 months; range, 36–72 months). Postoperative follow-up included imaging diagnosis in every case. No patients were lost to follow-up, but 1 patient died owing to cardiac disease. No patients were recalled specifically for this study; all data were obtained from the medical records.

All surgeries were performed by 1 surgeon (F.W.). A standard medial parapatellar approach was used, and a standard medial soft tissue release was performed with a curved osteotome to avoid disrupting the insertion of the MCL on the tibia. The pes anserine tendons were not released. The etiology of MCL disruption was transection in 12 cases, and avulsion of the MCL from the formal metaphysis in 5 cases. Each MCL injury was confirmed by the senior surgeon by exposure and direct visualization of the ligament mid-substance or insertion (Fig. 1).Once trial implants established that the reconstruction could obtain good opposition with appropriate tension, the femoral, tibial, and final polyethylene components were implanted.

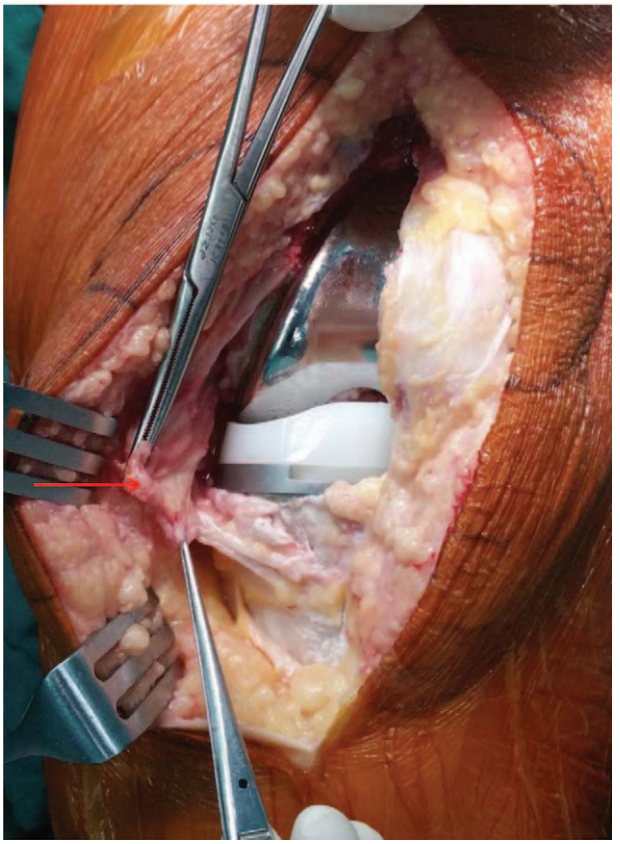

Figure 1. The etiology of MCL disruption was transection (as indicated by the arrows).

2.1. Surgery

For the implants, all femoral cuts were made using intramedullary femoral instrumentation and tibial cuts were made using extramedullary tibial instrumentation, with as little bone resection as possible. The Whiteside line and the biepicondylar line were used as femoral references. The flexion and extension gaps were then checked. The tibial cut was made with a slope of 5° to 7°, using the 2 mm guide on the affected side. The same cruciate-retaining implant (LINK, Hamburg, Germany, Gemini MK II) was used for all patients.

2.2. Harvesting of the semitendinosus tendon

The semitendinosus tendon was harvested by extending the existing skin incision utilized in the primary TKA by a couple of centimeters. Dissection was made down medially to the sartorius muscle fascia. The fascia was then incised longitudinally along the hamstring fibers between the gracilis and the semitendinosus tendons. As they usually adhere to the fascia, the tendons were carefully isolated to avoid damaging the fascia. The length and diameter of both single and double strands were then measured.

2.3. Ligament reconstruction: tibial and femoral tunnel preparation

The superficial MCL femoral attachment is located approximately 1 cm anterior and distal to the adductor tubercle, and consists of anterior vertical and oblique posterior bundles that coalesce with the anterior tibia approximately 4.5 cm distal to the medial joint line.[18] Care was taken to protect the infrapatellar branch of the saphenous nerve. The soft spot between the anteromedial and posteromedial parts of the knee was peeled off to expose the proximal tibia. The anterior tibial insertion was taken to be located 1.5 cm lateral from the medial tibial edge and 4.5 cm distal to the tibia plateau; the posterior tibial insertion was located 2.0 cm distal to the tibial plateau. A 2.0-mm Steinmann pin was drilled from the site of the anterior bundle to the site of the posterior bundle, and the tibial tunnel was then drilled with the guide pin according to the measured diameter of the single-strand autograft (4.5–5 mm). The femoral insertion of the MCL was positioned at the medial femoral epicondyle. An isometric test was done to observe the rotatory center of the knee. A guide pin was then drilled into the rotatory center, which was parallel with the joint line along the epicondylar axis and into the lateral femoral condyle; a femoral tunnel 2.5 to 3 cm in depth was then drilled with the guide pin according to the measured diameter of the double-strand autograft (7–8 mm) (Fig. 2).

2.4. Graft passage and fixation

One free end of the allograft was passed through the tibial tunnel (Fig. 3A,B), and the 2 free ends were then pulled into the femoral tunnel under the fascia and the saphenous nerve. The length of the allograft was measured before the redundant graft was cut off. The 2 free ends were 2.5 cm longer than the distance from the

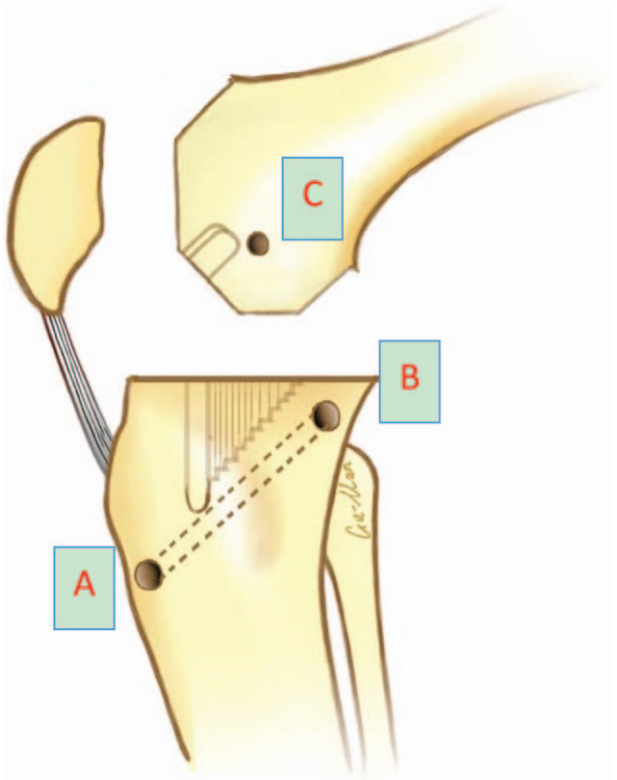

Figure 2. (A) The tibial anterior bundle insertion of MCL was selected at the place that 1.5 cm lateral from the medial tibial edge and 4.5 cm below the tibia plateau. (B) The tibial posterior bundle insertion is selected at 1.5 mm lateral of the medial tibia edge and 2.0 cm below the tibia plateau. (C) The femoral insertion MCL at the medial femoral epicondyle.

tibial tunnel to the femoral tunnel. The free ends were sutured at 2.5 cm and were then passed into the femoral tunnel with a pull-through technique and fixed with a bio-interference screw (the same size as the femoral tunnel) (Fig. 4). The screw was tightened with the knee at 30° of flexion with varus stress and neutral rotation. The 2 tibial bundles of the graft were sutured into the soft tissue with PDSII (polydioxanone) synthetic absorbable suture (Fig. 5A,B).

2.5. Rehabilitation protocol and follow-up

Postoperatively, a hinged knee brace was used to protect the MCL reconstruction. During the first 3 weeks, 50% bodyweight-bearing was permitted, and the knee was protected with a long-hinged knee brace allowing 30° to 90° of motion. From 3 to 6 weeks, the patients were instructed to perform active range of motion exercises at least twice a day, and weight-bearing was permitted within the limits of each patient's tolerance. The brace was continued for 6 weeks, until the knee demonstrated stability under passive valgus stress.

The followed-up time points were 2 weeks, 4 weeks, 12 weeks, 1 year, and 2 years. All patients completed the KSS and radiographs evaluation. For consistency, all the radiographs were evaluated by the same surgeon. According to the study by Lee and Lotke,[2] we obtained pain scores on the basis of evaluation of pain, range of motion, and knee stability. Functional scores were obtained by evaluating the walking distance, the ability to go up and downstairs, and whether gaitaides were required for ambulation. No patient underwent revision. The minimum clinical and radiographic follow-up period was 36 months (average, 51 months; range, 36–72 months). Radiographs were reviewed by the author (F.W.) to detect any loosening or radiographic changes.

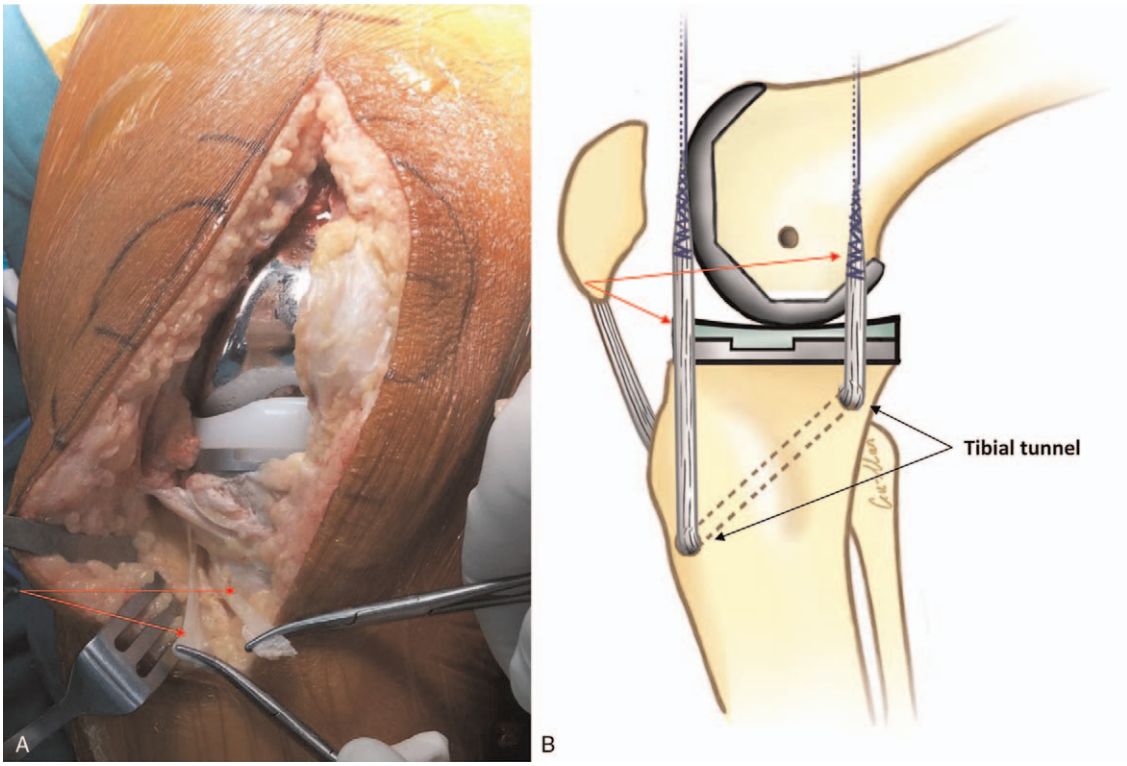

Figure 3. Two free ends of the allograft (red arrow) were then passed through the tibial tunnel (A,B).

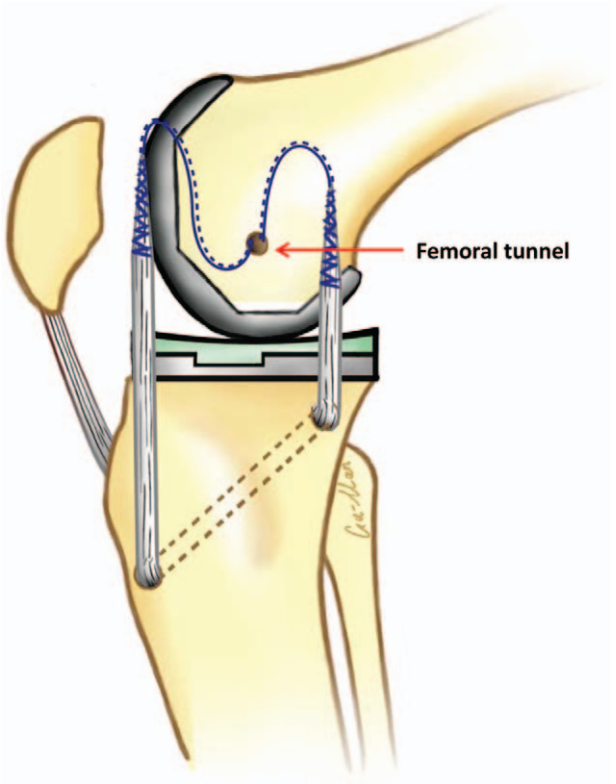

Figure 4. The free ends were sutured at 2.5 cm, and were then passed into the femoral tunnel.

In the same period, we obtained the clinical scores of patients who underwent primary TKA but did not have iatrogenic MCL disruption (1732 knees). By comparing the KSS and the clinical scores, we found that the KSS were normally distributed. For ensuring relative homogeneity of variance, we also performed a Levene test. The Student *t* test was used to compare the KSS for pain and function of patients with MCL injury managed with autograft ligament reconstruction with those of the control group.

Table 1

Comparison of demographic and clinical variables for patients and controls.

	MCL injury (N = 17)	Controls (N = 1732)	*P*
Female n (%)	13 (17)	1445 (1732)	.44
BMI, kg/m^2	34.4 ± 4.5	34.6 ± 4.5	.84
Age, y	63.0 ± 4.2	60.7 ± 7.4	.20
RA/OA	2/15	122/1610	.11

BMI = body mass index, MCL = medial collateral ligament, OA = osteoarthritis, RA = rheumatoid arthritis.

3. Results

In our series of 2054 TKAs, 17 knees (0.83%) experienced intraoperative MCL disruption. There were no significant differences in demographic and comorbidity data of the patients with MCL injury versus control patients (Table 1).

A review of the operative reports confirmed that the MCL injury was mid-substance transection in 12 knees and avulsion of the femur in 5 knees. All 12 cases with a mid-substance MCL injury resulted from direct injury from either the oscillating saw blade while performing the tibial cut or one of the sharp instruments used to lift the medial subperiosteum. Fixed bearing TKA with a cemented, fixed, cruciate-retaining implant was performed in all patients.

No patients were lost to follow-up, and no patient experienced postoperative knee instability. Physical examinations found that

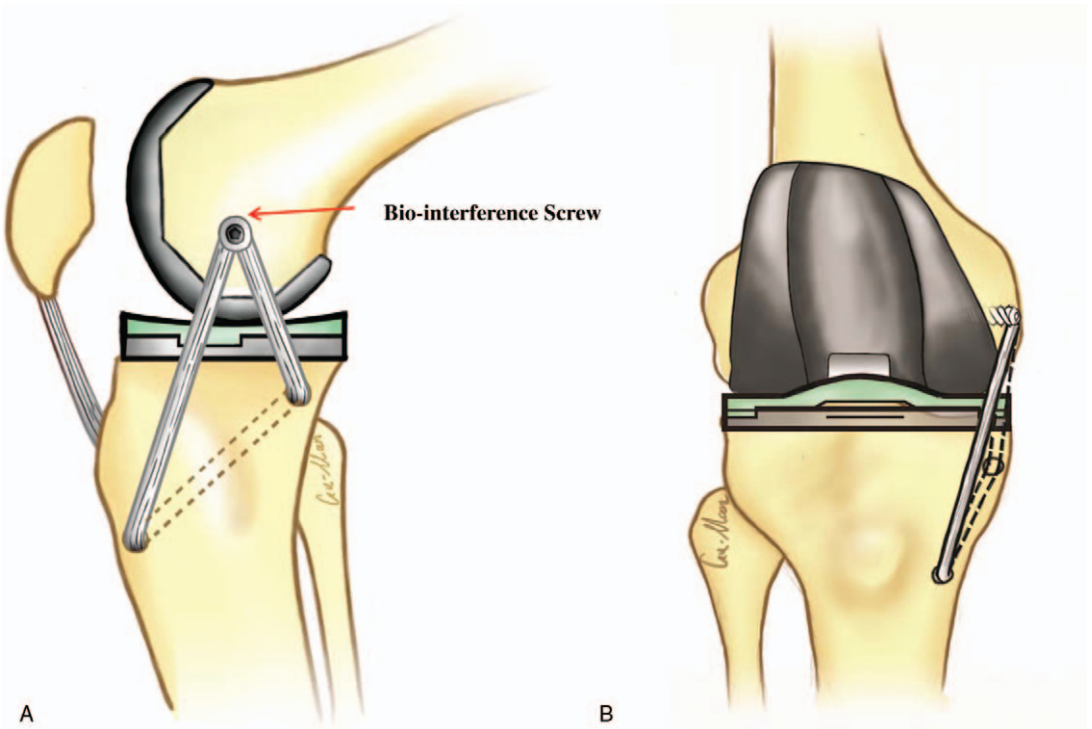

Figure 5. A lateral view of the knee model. (A) A front view of the knee model. (B) Once trial implants were established that the reconstruction could obtain good opposition with appropriate tension, the femoral, tibial, and final polyethylene components were implanted.

Table 2

Clinical results after intraoperative medial collateral ligament (MCL) injury.

Clinical outcome	Study group MCL injury (n = 17)	Control group No MCL injury (n = 1732)	P
KS pain	87.7 ± 6.2	90.6 ± 6.9	.08
KS function	84.7 ± 5.9	87.9 ± 7.6	.08

KS = Knee Society, MCL = Medial collateral ligament.

no patient had laxity in the coronal plane in either 30° of flexion or full extension. All patients were able to walk without an assisting device at the time of the last follow-up, and none underwent revision arthroplasty.

For the 17 patients with MCL injury, the average KSS for pain and function was 87.7 and 84.7 points, respectively. Both of these scores were lower than the average pain and function scores of 90.6 and 87.9 points, respectively, for the 2037 control knees that did not obtain MCL injury during primary TKA ($P = .08$ for pain, and $P = .08$ for function) (Table 2).

4. Discussion

Multiple studies have demonstrated that the MCL is the primary medial stabilizer of the knee resisting valgus loading, the secondary stabilizer against excessive external tibial rotation, and is also essential for providing stability during valgus stress and external rotation stress after TKA.[19–22] Because of the rarity of MCL injury during TKA, this complication is often unrecognized and rarely discussed. The current literature reports MCL rupture rates of 0.77% to 2.7% [15–17]; therefore, the MCL rupture rate in 2054 knees that underwent TKA in our institution in a 6-year period was relatively low (0.83%).

Failure to repair MCL injury or to change the type of prosthesis to a more constrained design results in marked risks of knee instability, asymmetric accelerated polyethylene wear, and extremely early loosening.[6,23] Therefore, the method chosen to treat MCL injury markedly affects the outcome. However, the most appropriate method is still debatable; some recent studies have used constrained designs with good results, while some opt for augmentation or primary implants with repairs.[1,6,7,12,24–26] Although the easiest way to treat iatrogenic MCL injury during TKA is to place a revision implant, this may not be the best option for relatively young active patients, as it results in larger bone cuts to accommodate the implants size. We consider that more constrained designs decrease implant longevity and wear.[23]

Although several studies have reported successful treatment of iatrogenic disruptions of the MCL without using a constrained implant by either repair or augmentation with a thicker polyethylene insert,[1,11,12] it has also been confirmed that conservative management of MCL injuries may result in high rates of instability, which then requires revision surgery.[3,15] Major difficulties owing to MCL disruptions include failure of primary repair or the requirement for conservative treatment in the segment of the MCL to the rim of the joint. In particular, there will be a lower healing potential when the mid-substance of MCL is disrupted. Furthermore, the taller tibial polyethylene may potentially fracture owing to the additional stresses placed on it, be an additional source of polyethylene wear, require release of the lateral compartment, and raise the joint rim, leading to kinematic imbalance and postoperative pain.

A previous study found that the use of increased constraint when MCL injury is recognized frequently leads to satisfactory clinical outcomes, with KSS similar to patients undergoing primary TKA.[15] There are also some reports that patients with MCL repair achieved a KSS of over 90; for example, Leopold et al[1] reported an average KSS of 93 for 16 knees treated with posterior cruciate-sparing prosthesis and repair. Increasing the thickness of the polyethylene alone reportedly achieved an average KSS of 91.[12] We found that patients with iatrogenic MCL injuries had similar mean pain and function KSSs compared with patients without MCL injuries treated with primary TKA. This indicates that reconstruction of the injured MCL and a more restrained rehabilitation program will result in the same good functional results achieved by those undergoing primary TKA without MCL injury.

We think that reconstructing the MCL and retaining the thickness of the polyethylene is the best way to treat intraoperative MCL rupture. Adravanti et al [27] described a surgical approach to restore knee joint stability in MCL deficiency via a reconstructive technique using the semitendinosus tendon to reconstruct the vertical fibers of the superficial MCL. However, the superficial MCL femoral attachment is approximately 1 cm anterior and distal to the adductor tubercle, and consists of anterior vertical and oblique posterior bundles that coalesce with the anterior tibia approximately 4.5 cm distal to the medial joint line.[28] Hence, we adopt the method of double-bundle MCL reconstruction. We favor using a posterior cruciate-sparing implant in routine primary TKA. As described in the previous studies, the posterior cruciate ligament is the secondary functional stabilized structure for valgus stress in the coronal plane. We considered that the high proportion of posterior cruciate-sparing implants in our study may have a positive effect on the results.[29,30]

Our point of view differs from some previous studies. In our opinion, an autograft ligament reconstruction is a better choice than a more constrained implant or a primary repair. While the use of an autograft increases the cost of the procedure, it is likely to be less expensive than the use of more constrained implants or an allograft. Autograft MCL reconstruction requires 1 interference screw, which costs 1000 USD; in contrast, an allograft ligament reconstruction will result in greater expenses (2000 USD), and use of a constrained prosthesis will result in greater expenses and less chance of rebuilding. Although the use of an autograft is better than other methods, it may increase the operation time, and at least in theory, lead to periprosthetic fracture at the femoral condyle because of the autograft fixation. In addition, the long-term risks need to be evaluated by the further studies. However, no fractures occurred in our study.

The purpose of this study was to verify whether good to excellent KSS could be obtained by reconstructing the MCL and using an unconstrained implant. Excellent results were achieved with primary reconstruction alone. The present study had some inevitable limitations. The sample size was small owing to the rarity of the complication being studied. However, our sample size is in accordance with similar reports in the literature. Different subtypes of MCL injuries were not analyzed separately owing to the small sample size. Another limitation is the relatively short minimum follow-up period of 36 months, which may not account for failures occurring after this period and may thus have underestimated the failure rate of this technique. Furthermore, there was no precise objective technique used to measure joint stability; to our knowledge, there has been no established normal range of coronal plane stability to allow for an objective measurement. Physical examination with the knee in full extension and in 30° of flexion indicated that the knee stability

of patients in the present series appeared similar to that of other patients who underwent primary TKA without MCL injury.

5. Conclusion

Direct reconstruction of the superficial MCL and postoperative protocol alterations without the use of constrained implants can provide a stable reconstruction with good medium-term results in selected patients. In our small series of 17 MCL disruptions during TKA, primary reconstruction yielded good medium-term results. Larger, more generalizable studies are needed to determine whether patients will continue to do well with this technique.

References

[1] Leopold SS, McStay C, Klafeta K, et al. Primary repair of intraoperative disruption of the medical collateral ligament during total knee arthroplasty. J Bone Joint Surg Am 2001;83:86–91.
[2] Lee GC, Lotke PA. Management of intraoperative medial collateral ligament injury during TKA. Clin Orthop Relat Res 2011;469:64–8.
[3] Siqueira MB, Haller K, Mulder A, et al. Outcomes of medial collateral ligament injuries during total knee arthroplasty. J Knee Surg 2016; 29:68–73.
[4] Cameron HU, Hunter GA. Failure in total knee arthroplasty. Mechanisms, revisions, and results. Clin Orthop Relat Res 1982; 170: 141.
[5] Giori NJ, Lewallen DG. Total knee arthroplasty in limbs affected by poliomyelitis. J Bone Joint Surg Am 2002;84:1157.
[6] Naudie DDR, Rorabeck CH. Managing instability in total knee arthroplasty with constrained and linked implants. Instr Course Lect 2004;53:207.
[7] Sculco TP. Total condylar III prosthesis in ligament instability. Orthop Clin North Am 1989;20:221.
[8] Whiteside LA. Correction of ligament and bone defects in total knee arthroplasty of the severely valgus knee. Clin Orthop Relat Res 1993;288:234.
[9] Lombardi AVJr, Berend KR, Adams JB. Why knee replacements fail in 2013: patient, surgeon, or implant? Bone Joint J 2014;96-B(11 Suppl A):101–4.
[10] Hartford JM, Goodman SB, Schurman DJ, et al. Complex primary and revision total knee arthroplasty using the condylar constrained prosthesis: an average 5 year follow up. J Arthroplasty 1998;13:380.
[11] Jung KA, Lee SC, Hwang SH, et al. Quadriceps tendon free graft augmentation for a midsubstance tear of the medial collateral ligament during total knee arthroplasty. Knee 2009;16:479–83.
[12] Koo MH, Choi CH. Conservative treatment for the intraoperative detachment of medial collateral ligament from the tibial attachment site during primary total knee arthroplasty. J Arthoplasty 2009;24:1249–53.
[13] Favorito PJ, Mihalko WM, Krackow KA. Total knee arthroplasty in the valgus knee. J Am Acad Orthop Surg 2002;10:16.
[14] Whiteside LA. Soft tissue balancing. The knee. J Arthroplasty 2002;17 (Suppl 1):23.
[15] Lee GC, Lotke P. Management of intraoperative medial collateral ligament injury during TKA. Clin Orthop Relat Res 2011;469:64–8.
[16] Dragosloveanu S, Cristea S, Stoica C, D C. Outcome of iatrogenic collateral ligaments injuries during total knee arthroplasty. Eur J Orthop Surg Traumatol 2014; 24:1499–1503.
[17] Shahi A, Tan TL, Tarabichi S, et al. Primary repair of iatrogenic medial collateral ligament injury during TKA: a modified technique. J Arthroplasty 2015; 30:854–857.
[18] Dong JT, Chen BC, Men XQ. Application of triangular vector to functionally reconstruct the medial collateral ligament with double-bundle allograft technique. Arthroscopy 2012;28:1445–53.
[19] Grood ES, Noyes FR, Butler DL, et al. Ligamentous and capsular restraints preventing straight medial and lateral laxity in intact human cadaver knees. J Bone Joint Surg Am 1981;63-A:1257–69.
[20] Warren RF, Marshall JL. Injuries of the anterior cruciate and medial collateral ligaments of the knee. A long-term follow-up of 86 casespart II. Clin Orthop 1978;136:198–211.
[21] Whiteside LA, Saeki K, Mihalko WM. Functional medial ligament balancing in total knee arthoplasty. Clin Orthop Relat Res 2000;380:45–57.
[22] Saeki K, Mihalko WM, Patel V, et al. Stability after medial collateral ligament release in total knee arthoplasty. Clin Orthop Relat Res 2001;392:184–9.
[23] Lachiewicz P, Soileau E. Ten year survival of and clinical results of constrained components in total knee arthroplasty. J Arthroplasty 2006;21:803.
[24] Krackow KA, Jones MM, Teeny SM, et al. Primary total knee arthroplasty in patients with severe varus deformity. A comparative study. Clin Orthop Relat Res 1991;273:19.
[25] Luring C, Hunter T, Perlick L, et al. The effectiveness of sequential medial soft tissue release on coronal alignment in total knee arthroplasty using a computer navigation model. J Arthroplasty 2006;21:428–34.
[26] Lee GC, Lotke PA. Management of intraoperative medial collateral ligament injury during tka. Clin Orthop Realt Res 2011;469:64–8.
[27] Adravanti P, Dini F, Calafiore G, et al. Medial collateral ligament reconstruction during TKA: a new approach and surgical technique. Joints 2016;3:215–7.
[28] Miyamoto RG, Bosco JA, Sherman OH. Treatment of medial collateral ligament injuries. J Am Acad Orthop Surg 2009;17:152–61.
[29] Barton TM, Torg JS, Das M. Posterior cruciate ligament insufficiency. A review of the literature. Sports Med 1984;1:419–34.
[30] Kannus P, Bergfeld J, Jarvinen M, et al. Injuries to the posterior cruciate ligament of the knee. Sports Med 1991;12:110–31.