

Monitoring of fracture healing by electrical conduction: A new diagnostic procedure

Shanmugasundaram Kumaravel, Sundaram S¹

ABSTRACT

Background: Electrical stimulation of fractures has been reported to enhance fracture healing. X-rays are normally used to assess union of fractures. Electrical conduction is not tried as a tool to study fracture healing. The current study focuses on electrical conduction as a diagnostic tool to assess fracture healing and new bone formation. The aim was to find if electrical resistance across the fracture can be used as a tool to study fracture healing which can be verified with simultaneous radiographs.

Materials and Methods: A prospective study was conducted where 12 open fractures of tibia, including two with bone defects were evaluated. They were debrided and four-carbon ring Ilizarov external fixators were applied. Their healing was followed with clinical assessment and periodical X-rays till the endpoint of fracture union and then the rings were removed. In addition, all these cases also had application of electrical voltage in the range of 0.1–1.0 V DC in 0.1 V increments, across the two wires on either side of fracture. The output current was recorded by an ammeter connected in series. Resistance calculated for various voltages was plotted as a graph for the period of fracture treatment and the characteristics were studied. This graph was compared with the appearance of new bone in the X-rays.

Results: In all cases, when the above graph stabilized, in the consecutive recordings, the X-rays showed healing (bridging callus) matching the curve and the patient was able to load the limb. The time of stabilization of this graph for a specific voltage was different in individual cases. However, for a given case, the resistance characteristics were the same for the entire voltage range of 0.1–1.0 V.

Conclusion: If the resistance versus day curve stabilizes on the consecutive recordings, we can predict that the fracture is in the process of healing. This stabilization period also matched the patients' ability to comfortably load the limb and also the radiographs which showed bridging callus (healing). If this is used as a positive criterion for fracture healing in future, the radiation exposure by X-rays shall be less.

Key words: Carbon-Ilizarov rings, DC voltage, fracture healing, resistance, X-rays

INTRODUCTION

Progress of fracture healing is assessed clinically and with periodical X-rays. Repeated X-rays can be a source of health hazard.¹⁻³ X-rays are not fully reliable because interpretation is highly dependent on experience with relatively poor interobserver and intraobserver reliability and partly because of the lack of an accepted

definition of radiographic union.^{4,5} Alternate methods like ultrasound cause *in vitro* cell organelle destruction in human fibroblast.⁶ In practice, the ultrasound beam achieved is not perfect. Degradation of ultrasound and its variability from patient to patient are limitations to its diagnostic use. When cells in suspension are exposed to ultrasound both at diagnostic and therapeutic levels, they show changes in DNA and surface membrane behaviors. There is no place for quick ultrasound for immediate inference. Extreme ultrasound powers can produce regions of such a low pressure during the rarefaction phase of the cycle that dissolved gases, especially nitrogen, can come out of the solution or water producing microbubble that pulsate in the sound field. This process called cavitation can cause mechanical damage to the tissue and can even cause ionization.⁷ The probe of ultrasound cannot be moved between Ilizarov rings. In an ultrasound image, new vessels may mimic new bone.^{8,9} Methods like quantitative computed tomography (CT) and radionuclide scan are costly and also involve radiation.¹⁰⁻¹³ Electrical stimulation of fractures has been reported to enhance fracture healing.¹⁴⁻¹⁷ Electrical conduction has not tried as a tool to study fracture

Department of Orthopaedic Surgery, Government Thanjavur Medical College,
¹Department of Electrical Engineering, SASTRA University, Thanjavur, Tamil Nadu, India

Address for correspondence: Dr. Shanmugasundaram Kumaravel,
 78, Kumaraguruparar Street, Ezhil Nagar, Municipal Colony, Thanjavur, India - 613 004.
 E-mail: drskumaravel@gmail.com

Access this article online	
Quick Response Code:	Website: www.ijoonline.com
	DOI: 10.4103/0019-5413.97260

healing. In the references cited, only therapeutic aspects were detailed.¹⁴⁻¹⁷

We hypothesized that if there was a change in the chemical composition from the fracture hematoma to hard callus, then there must be a change in the electrical behavior across the fractured bone also.

A study on skin wound healing found there was stabilization of electrical potentials recorded across the wound after an initial irregularity as the skin wound regained strength.¹⁸ Bioelectric potentials after fracture of the tibia in rats were found to stabilize from an initial irregularity. This irregularity was attributed to the cellular and vascular processes in the early callus formation.¹⁹ The same suggestion was applied to fractured human bones in our study. Few earlier works on limited number of cases (two to four cases) indicated that stabilization of current is an evidence of healing as confirmed by X-rays which is the common contemporary method.²⁰⁻²³ The present work is an attempt to study the change in resistance across the fractured limb as healing of fracture proceeded in 12 patients. To find if studying a change in resistance measured across fractured limbs can be used as a tool to study fracture healing which can be verified with simultaneous radiographs.

MATERIALS AND METHODS

A prospective clinical study was done after obtaining due ethical committee clearance. 12 patients with open fractures of tibia, 10 men and 2 women with age ranged from 15 to 70 years were included in the analysis. The tibia was chosen because it is a common bone to get injured in road accidents. Open fractures are more common in this bone and Ilizarov methodology could be followed. Ilizarov methodology was chosen as there will not be any conducting material if carbon rings were used. Ten fractures were in the upper third–middle third junction. Remaining two cases were having bone defects in the middle third. All the wounds were in the range of 2–8 cm [Figure 1]. Of the two bone gap patients, the first one was having an open fracture with a 7-cm bone loss and the second patient had a 5-cm bone loss. Both these patients needed a rod-type external fixator and a medial gastrocnemius flap initially before being taken up for this study. These two patients needed internal bone transport. Three other cases needed skin grafting. Rest of the seven cases did not need any soft tissue cover. The fractures were in different pattern most of them were oblique with comminution. All patients were explained the nature of surgery and they consented for application of DC voltage. Under spinal anesthesia, the open fractures were debrided, reduced under direct vision, and fixed with carbon Ilizarov external fixator using the

regular Ilizarov K-wires of 1.8 mm as shown in Figure 1. This Ilizarov construct consisted of four carbon rings of 180 mm internal diameter which were connected with each other using regular stainless steel threaded rods and nuts. Initially, X-rays were taken to ascertain the position of fracture fragments and wires. In all these 12 cases, assessment of healing was also done clinically and by periodical X-rays till the endpoint of fracture union, and then the rings were removed. In addition, all these cases had application of DC voltage across the fractured limb as shown in Figures 1–4.

The application of DC voltage and recording of the current

The DC voltage generator Scientech® shown in Figure 4 works with an input domestic current of 220 V with a 5 A fuse. It is capable of generating a range of DC voltage between 0.1 and 1 V. This was connected in series with an ammeter (EIC Meters Private Limited, Bangalore - 560062, India) along with the wires that were passed above and below the fracture. Across the two wires on either side of fracture, a direct voltage from a DC voltage generator (Scientech Technologies [P] Ltd, Indore, 452010 India) was applied as shown in Figures 1–4. The current output was recorded as the voltage was increased in 0.1 V increments. When an initial voltage of 0.1 V DC was given, the current recorded with an ammeter was in milliamperes (mA). Then, the voltage was increased by 0.1 V, i.e. to 0.2 V DC, and the current was recorded. The same was repeated for voltages in increments of 0.1 V up to 1.0 V and the resultant current was measured. Thus, the voltage was kept constant for all the cases and the current output was measured. The entire time taken to record current output for a single patient (from 0.1 to 1.0 V) was 20 seconds.

Resistance calculated for various voltages was plotted as a graph for the period of fracture treatment and the characteristics were studied. There are 10 curves for each patient, i.e. from 0.1 to 1.0 V. For illustrating a sample recording with 0.7 V was taken and shown in the figures. Initially, one anteroposterior and one lateral X-ray were taken every 2 weeks when the patient came for a visit. Later, we found that cessation of oscillations in the resistance versus days graph for a fixed voltage matched the healing in X-rays. Hence, in our last 6 cases, we reduced the number of X-rays and waited for the resistance versus days graph to stabilize without any oscillation and X-rays were later taken to confirm the healing. The electrical resistance versus days of treatment graph was compared with the appearance of new bone in the X-rays, which is the common method at present. The frequency of recording was more during the inpatient period. The electrical output recording was done whenever the patient came for followups. When there was corticotomy for bone transport, there were two sites for current recording as in cases 4 and 5, i.e. the fracture and corticotomy site.




Figure 1: A patient having open fracture of tibia with an Ilizarov fixator of rings of 180-mm internal diameter connected to each other with threaded rods and nuts. Across two wires on either side of the fracture, a direct voltage from a DC voltage generator was applied through two crocodile clips

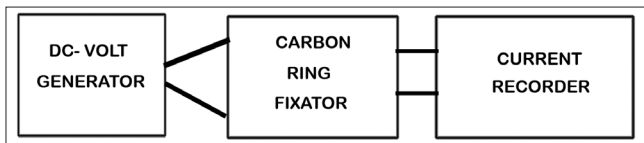


Figure 3: Experimental setup of the assembly

The resistance was calculated for each patient using the formula $V/I = R$, i.e. voltage in V/current in mA $\times 0.0001 = R$ in Ohms.

The resistance was plotted against days of treatment and the pattern of curve was compared with the fracture healing in X-rays.

All the 12 cases were available till the fracture united which is the endpoint of the study and had all the X-rays and could be compared with electrical stimulation. There was no discomfort while applying the DC voltage. The distances between the rings were constant in all these cases except in cases 4 and 5 which had corticotomy.

RESULTS

One sample calculation of resistance and the resultant graph for a case is given in Table 1 and the resultant graph is shown in Figure 5.

In all the 12 cases, when the resistance versus days graph did not show any oscillations, the X-rays showed healing. In these cases studied, the resistance fluctuated during the healing phase and became stable when the fracture was healed. The stability at 0.7 V at fracture healing was different in individual cases. Also, for a given case, the resistance

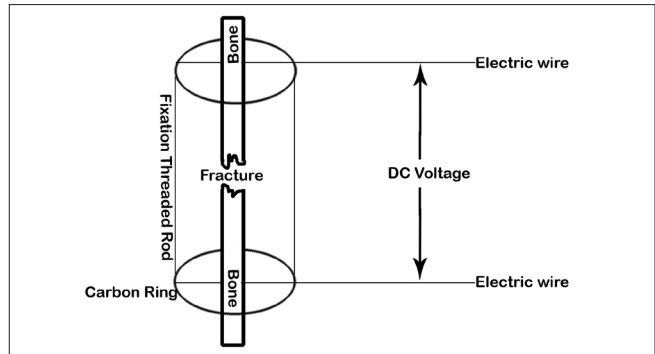


Figure 2: Line diagram showing the fracture and application of DC volt




Figure 4: The DC voltage generator and the ammeter used (A is ammeter, V is voltage generator, F is fine adjustment, # indicates the wires that proceed to the leads across the fracture)

Table 1: Current output for a fixed volt of 0.7 and the resistance as the days proceeded for patient no. 1

Days	V	Current in mA	Resistance in Ω
0	0.7	0	0
1	0.7	470	0.001489
8	0.7	520	0.001346
9	0.7	390	0.001795
10	0.7	650	0.001077
11	0.7	560	0.00125
12	0.7	450	0.001556
13	0.7	540	0.001296
14	0.7	610	0.001148
15	0.7	590	0.001186
16	0.7	410	0.001707
17	0.7	500	0.0014
18	0.7	440	0.001591
19	0.7	450	0.001556
20	0.7	580	0.001207
21	0.7	490	0.001429
22	0.7	470	0.001489
37	0.7	490	0.001429
51	0.7	490	0.001429
70	0.7	490	0.001429

characteristics were the same for all voltage ranges. The resultant resistance calculated was in the range of $10^{-3} \Omega$.

The above illustrated reading [Table 1] is for our first patient. He had a recording on the first postoperative day to find the starting reading. After a week, daily recordings were done for him up to 22 days. Then, this patient was discharged. Later, when each time the patient presented himself for review, then voltage was applied and reading was taken, i.e. at 37, 51, and 70 days, and was compared with X-rays taken during these visits.

In those cases (cases 4 and 5) which had bone transport, when the distance between the rings was altered, there were oscillations with spikes. However, the spikes were less in case of graphs constructed out of recording across the corticotomy site in both these cases even during the initial stages of transport. The resistance versus days curves of one such case is illustrated in Figures 4 and 5. This may be due to the regular cut made surgically with a gigli saw. This is not so in case of fracture site recording of both these cases which share the irregularity as in other cases during the initial period of treatment.

Figure 5 shows a representative variation in resistance with days for the patient shown in Figure 1, whose data are shown in Table 1, for a sample voltage of 0.7 V only. The resistance was initially irregular and stabilized after 37 days. Clinical examination and X-rays also indicated that the fracture has started to unite after 37 days. The expanded graph and the serial X-rays taken alongside are shown in Figure 6. It shows the stabilization of resistance and matched the healing process as evidenced by new bone formation in the X-rays [Figure 6]. Similar results were obtained for fractures which

were subjected to electrical conduction. The stabilization days differed based on the nature of fracture, but were confirmed with X-rays. Figure 7 shows the same patient's X-ray after the ring removal, showing healing of the fracture.

Table 2 shows the details of the cases treated with carbon ring fixator and followed up clinically, with X-rays, and by electrical stimulation. The routine nature of using X-rays in current practice is to see for signs of healing, and if necessary to intervene. For the first six cases, the X-rays were taken every 2 weeks. As we observed that the resistance to electrical conduction was stable when the fracture healed, the protocol was changed. For the later six cases, X-rays were obtained only when the resistance was stabilized. We waited for the resistance versus days curve to stabilize without any oscillation and X-rays were later taken to confirm the healing.

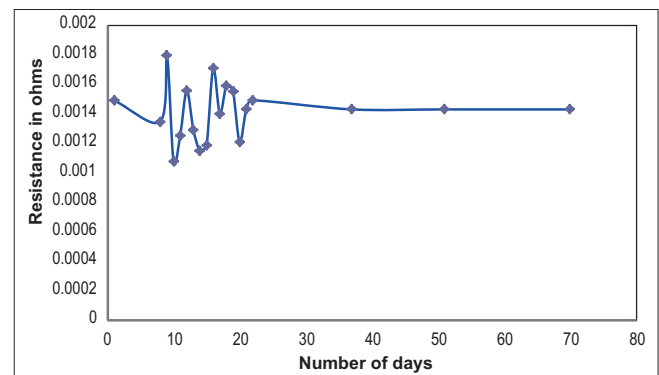


Figure 5: Resistance versus days curve for a fixed voltage of 0.7 V for patient 1

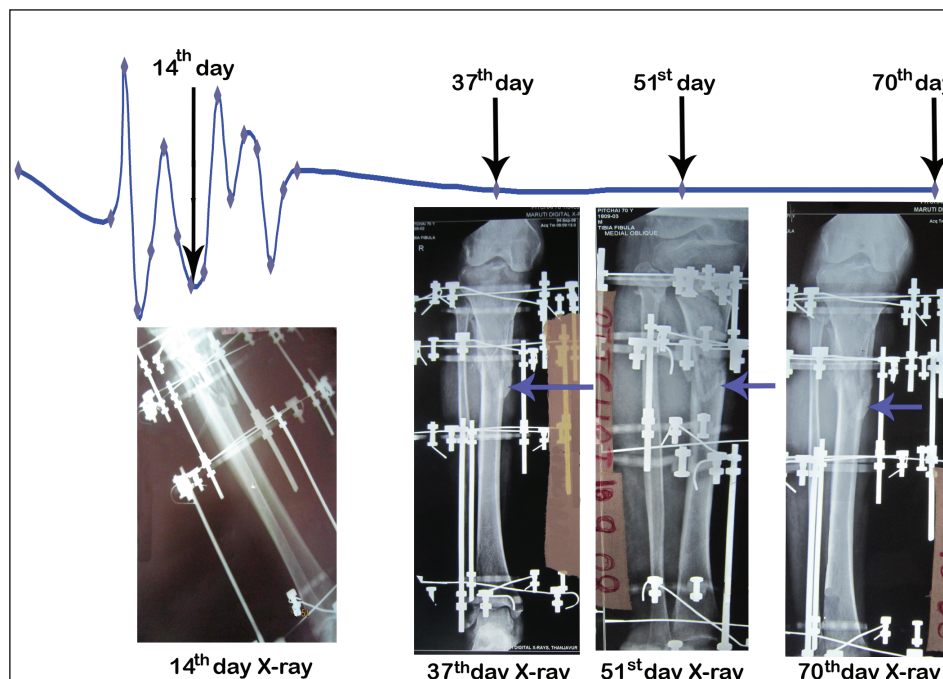
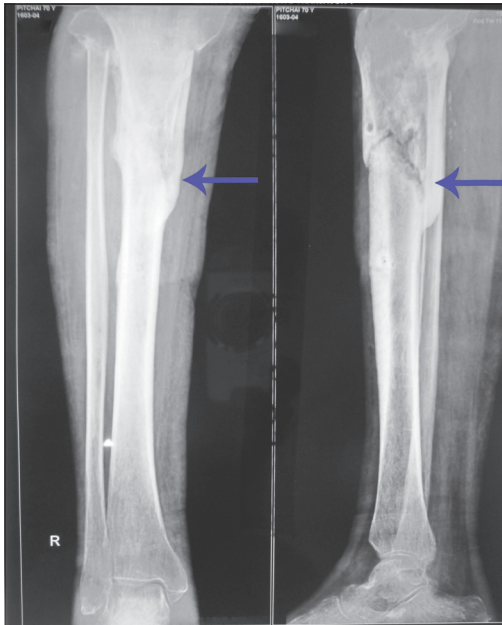


Figure 6: Progressive X-rays with the number of days of Patient 1 with blue arrow marking

Table 2: Cases treated with Ilizarov rings or bone transport, followed up with X-rays, clinical assessment, and electrical conduction, and the number of X-rays needed

Age	Sex	Diabetic status	Number of X-rays
60	M	N	18
35	M	N	12
55	M	Y	12
25	M	N	24
39	M	N	20
19	M	N	10
50	M	N	14
40	F	N	6
30	M	N	20
30	M	N	10
30	M	N	8
40	F	N	8
			180/12 = 15

M - Male, F - Female, N - Not a diabetic, Y - Diabetic

**Figure 7:** The patient's X-ray (AP and lateral views) after the removal of ilizarov fixator. The site of original fracture has now healed (arrow)

DISCUSSION

It was observed that at the same time when the resistance stabilized, i.e. in the resistance versus day graph when the curve did not have any oscillation in the consecutive recordings, the patient was able to walk comfortably loading the limb and the radiographs also showed signs of healing, matching the curve. The new finding is that stabilization of electrical conduction across the fracture indicates fracture healing. This is evident by an increase in resistance and flattening of the curve in all the cases studied. Once the stabilization of resistance was noted, X-rays were taken confirming the healing and the rings were then removed. It is obvious from Table 2 that the average number of X-ray

views required is 15. The number of X-rays for following similar cases treated with bone transport by other workers is 30 X-ray views per patient.²⁴ This indicates that nearly 2 times less X-rays are required for the fractures monitored by electrical conduction. The minimum effective dose to produce each view of leg X-ray is 1.54 μSv .²⁵ The average effective dose ($1.54 \mu\text{Sv} \times 15$) = 23.1 μSv . Apart from the X-rays taken for fracture assessment, there are other unavoidable investigations like CT brain or thorax, if the patient's condition warrants. These may cause further exposure to radiation. The maximum allowable radiation dosage for individual organ, for persons other than radiation worker, per year is 50 mSv; for the lens, it is 15 mSv per year and anything more than this will cause cataract.²⁶ Unlike the drugs which are metabolized within few days or weeks, the half-life of radiation is longer.

From a therapeutic aspect, electrical stimulation with direct and alternate current was found to be useful in healing of nonunions.¹⁴⁻¹⁷ However, some encourage further research to elucidate intracellular chemical pathways responding to these stimulations.¹⁵

From a diagnostic point of view, there is no literature barring a few recent works¹⁸⁻²⁰ on using electrical conduction as a way to monitor the healing of fractures. These studies showed that electric current recorded across a fractured bone when plotted with relation to days stabilized as the fracture healed. Regeneration process of cells may have an engineering control system like mechanism allowing small currents to act as signals.²⁷ Bone collagen fibers, when sliding past each other, are believed to produce a piezoelectric effect by shearing force.²⁸ When electric potentials were recorded near healing skin wounds, the potentials passed into stages of maximal strength and voltage which gradually fell down to a baseline, i.e. asymptotic.¹⁸ This initial irregularity was also reported by another worker, which was possibly attributed to cellular and vascular processes in the early phase of callus formation.¹⁹ Our study also had similar irregularities in resistance to current passage when the tissues were in early stage of healing which stabilized to a flat line when the bone healed.

In this study, at this point of time, there is difficulty in insulating the soft tissues from conducting. Hence, it can be considered as a conduction study across the fractured limb. In the present study, the issue is where actually the electrical conduction is taking place. To appreciate this, an example of an ECG may be considered. The ECG leads are kept on the chest wall and not directly on the heart and the resultant wave is inferred to have arisen from the heart. This is only because the pattern of waves matches the contraction of heart, e.g. p wave synchronizing with atrial contraction.

Likewise, if the conductivity of other tissues except the bone is assumed to be the same before and after healing, then the dynamically changing tissue is only the fractured bone as evaluated by clinical examination and radiology. Hence, these changes observed in the graph constructed with resistance versus days for definite voltage should have arisen from events in the healing of fracture tissue only. However, there is no study on electrical stimulation on acute fractures.

As we see that there are different tracings in each graph, it is evident that we are not taking a particular reading of resistance as the endpoint. Instead, the changes in the resistance were correlated with radiological signs of healing as the endpoint, i.e. the stability of recording is taken as the endpoint of healing which is correlated with radiological evidence of healing.

In vitro and *in vivo* studies were done earlier in intact animal bones to measure conductivity and suggested that tissue fluids in bone may influence the electrical conduction in live bone.²⁹ Another similar work on electrical conduction in live human bone revealed ohmic dependence under 1 volt and more than 1 volt showed electrolysis.³⁰

CONCLUSION

At present, it can be said that in the resistance versus days curve, if there is stabilization or no oscillations on the consecutive recordings, we can predict that the fracture is in the process of healing. This study leads to the conclusion that stabilization of electric resistance can be a positive criterion for fracture healing in future, and when electrical conduction is used to monitor fracture healing, there is lesser exposure to hazardous X-rays.

REFERENCES

- Goldstone K, Yates SJ. Radiation issues governing radiation protection and patient doses in diagnostic imaging, In: Adam A, Dixon AK, editors, Grainger and Allison's Diagnostic radiology, 5th ed, Philadelphia: Churchill Livingstone/Elsevier; 2008 page 159.
- Keshwar TS, Goshal S. Short and Long Term Effects of Radiation Exposure, In: Radiological protection of patients in medical application of ionizing radiation, In: Sukla AK, Editor, India: Published by the National Academy of Medical Sciences; 2003. p. 118-38.
- Ravichandran R. Reference Radiation Levels for Radiological Procedures. In: Radiological protection of patients in medical application of ionizing radiation, In: Sukla AK, Editor, India: Published by the National Academy of Medical Sciences; 2003. p.139-46.
- McClelland D, Thomas PB, Bancroft G, Moorcraft CI. Fracture healing assessment comparing stiffness measurements using radiographs. Clin Orthop Relat Res 2007;457:214-9.
- Matsushita T, Cornell CN. Biomechanics of bone healing, Editorial comment. Clin Orthop Relat Res 2009;467:1937-8.
- De Deyne PG, Kirsch-Volders M. *In vitro* effects of therapeutic ultrasound on the nucleus of human fibroblasts. J Phys Ther 1995;75:629-34.
- Cosgrove DO, Meire HB, Lim A, Eckersley RJ. Ultrasound, general principles. In: Adam A, Dixon AK, editors, Grainger and Allison's Diagnostic radiology, 5th ed, Philadelphia: Churchill Livingstone/Elsevier; 2008. p. 61.
- Cosgrove Do, Meire HB, Lim A, Eckersley RJ. Ultrasound, general principles. In: Adam A, Dixon AK editors, Grainger and Allison's Diagnostic radiology, 5th ed, Philadelphia: Churchill Livingstone/Elsevier; 2008. p. 73-4
- Aronson J. Biology of Distraction Osteogenesis, In: Kulkarni GS, editor, Text book of Orthopaedics and Trauma Page 1506, 1st ed, New Delhi: Jaypee Brothers; 1999.
- O'Reilly RJ, Cook DJ, Gaffney RD, Angel KR, Paterson DC. Can serial scintigraphic studies detect delayed fracture union in man? Clin Orthop Relat Res 1981;160:227-32.
- Segerman D, Kenneth A. Miles Radio nucleotide imaging - General principles, In: Adam A and Dixon AK editors, Grainger and Allison's Diagnostic radiology, 5th ed, Philadelphia: Churchill Livingstone/Elsevier; 2008. p. 129.
- Adams JE. Metabolic and Endocrine Skeletal Disease, In: Adam A, Dixon AK editors, Grainger and Allison's Diagnostic radiology, 5th edn. Philadelphia: Churchill Livingstone/Elsevier; 2008. p. 1095.
- Aronson J. Biology of Distraction Osteogenesis: In: Kulkarni GS, editor, Text book of Orthopaedics and Trauma 1st ed, New Delhi: Jaypee Brothers; 1999. p. 1507.
- Kuzyk PR, Schemitz EH. The science of electrical stimulation therapy for fracture healing. Indian J Orthop 2009;43:127-31.
- Connolly JF. Selection, Evaluation and Indication of electrical stimulation of ununited Fractures. Clin Orthop Relat Res 1981; Nov- Dec 161:39-53.
- Osterman AL, Bora FW Jr. Electrical stimulation applied to bone and nerve injuries in the upper extremity. Orthop Clin North Am 1986;17:353-64.
- De Haas WG, Watson J, Morrison DM. Non-invasive treatment of ununited fractures of the tibia using electrical stimulation. J. Bone Joint Surg Br 1980;62:465-70.
- Burr HS, Taffel M, Harvey SC. An electrometric study of the healing wound in man. Yale J Bio Med 1940;12:483-5.
- Lopez-Duran Stern L, Yageya J. Bioelectric potentials after fracture of the tibia in rats. J Acta Orthop Scand 1980;51:601-8.
- Kumaravel S, Sundaram S. Fracture healing by electric stimulation. Biomed Sci Instrum 2009;45:191-6.
- Kumaravel S, Sundaram S. A Feasibility study on monitoring of fracture healing by electric stimulation-A study on 2 tibial fracture cases. Int J Eng Sci Technol 2010;2:4083-7.
- Kumaravel S, Sundaram S. Monitoring of healing of stable fractures by electric stimulation' international. J Eng Tech Sci 2011;2:169-73.
- Kumaravel S, Sundaram S. The use of electric stimulation as a diagnostic tool to assess fracture healing and new bone formation. J Theor Appl Inf Technol 2011;33:205-13.
- Schiedel FM, Buller TC, Rödl R. Estimated patient dose and associated radiological risk from limb lengthening. Clin Orthop Relat Res 2009;467:1023-7.
- Ravichandran R. Reference radiation levels for radiological procedures. In: Radiological protection of patients in medical application of ionizing radiation, In: Sukla AK, Editor, India: Published by the National Academy of Medical Sciences; 2003.

- p. 144.
26. Goldstone K, Yates SJ. Radiation issues governing radiation protection and patient doses in diagnostic imaging. In: Adam A, Dixon AK, editors, Grainger and Allison's Diagnostic radiology, 5th ed, Philadelphia: Churchill Livingstone/Elsevier; 2008. p. 162.
 27. Becker RO. The bioelectric factors in the amphibian limb regeneration. *J Bone Joint Surg Am* 1961;43:643-56.
 28. Fukuda E, Yasuda I. On the Piezzo electric effect of bone. *J Physiol Soc Japan* 1957;12:1158-62.
 29. Tzukert A, Leviner E, Mahler Y, Shoshan S. Electroconductivity of bone *in vitro* and *in vivo*. *Clin Orthop Relat Res* 1983;179:270-4.
 30. Liboff AR, Rinaldi RA, Lavine LS, Shamos MH. On electrical conduction in living bone. *Clin Orthop Relat Res* 1975;106:330-5.

How to cite this article: Shanmugasundaraml K, Sundaram S. Monitoring of fracture healing by electrical conduction: A new diagnostic procedure. *Indian J Orthop* 2012;46:384-90.

Source of Support: Nil, **Conflict of Interest:** None.