

## CASE REPORT

# Presumed antiphospholipid syndrome and thrombotic thrombocytopenic purpura: An infrequent association

Hallie Hanna Dolin<sup>1</sup> | Mark Dziuba<sup>2</sup> | Scott M. Pappada<sup>2</sup> | Thomas John Papadimos<sup>1,2,3</sup> 

<sup>1</sup>Department of Medical Microbiology and Immunology, University of Toledo College of Medicine and Life Sciences, Toledo, OH, USA

<sup>2</sup>Department of Anesthesiology, University of Toledo College of Medicine and Life Sciences, Toledo, OH, USA

<sup>3</sup>Department of Anesthesiology, The Ohio State University Wexner Medical Center, Columbus, OH, USA

## Correspondence

Thomas J. Papadimos, Department of Anesthesiology, University of Toledo College of Medicine and Life Science, 3000 Arlington Avenue, Toledo, OH, 43614, USA.

Email: Thomas.Papadimos@Utoledo.edu

## Abstract

Antiphospholipid syndrome (APS) is an autoimmune disease that demonstrates antiphospholipid antibodies that cause hypercoagulability and leads to venous and arterial thrombosis. Autoantibodies to a disintegrin-like and metalloprotease with thrombospondin type I motif, member 13 (ADAMTS 13) play a role in the microthrombosis of thrombotic thrombocytopenic purpura in APS patients.

## KEY WORDS

ADAMTS13, antiphospholipid syndrome, disintegrin-like and metalloprotease, thrombotic thrombocytopenic purpura

## 1 | INTRODUCTION

In the differential diagnosis of antiphospholipid syndrome (APS), the recognition and development of thrombotic thrombocytopenic purpura (TTP) becomes challenging. Autoantibodies to a disintegrin-like and metalloprotease with thrombospondin type I motif, member 13 (ADAMTS-13) plays a role in the microthrombosis of TTP in APS. Here we present such a case.

Antiphospholipid syndrome is an autoimmune condition characterized by production of antiphospholipid antibodies, leading to a hypercoagulable state and subsequent arterial and venous thromboses. The diagnosis requires fulfillment of symptomatic and laboratory diagnostic criteria. Symptomatic criteria include at least one previous thrombotic event or recurrent pregnancy issues, such as miscarriage prior to 10 weeks' gestation or fetal death after this point. Laboratory criteria consist of two measurements, each taken at least 12 weeks apart, of lupus anticoagulant, anticardiolipin antibody, or

anti- $\beta_2$  glycoprotein I ( $\beta_2$ GPI) antibody.<sup>1,2</sup> Like many other autoimmune diseases, APS is largely female-specific, and the disease is most commonly found in systemic lupus erythematosus (SLE) patients, although APS can also occur as the result of different diseases or even independently; the shared mechanisms between APS and SLE have not been fully studied.<sup>2</sup>

Antiphospholipid syndrome autoantibodies are present in 41% of women with SLE, although 1%-5% of all women are found positive for these antibodies without associated symptoms or pathology.<sup>3</sup> APS contributes to a significant percentage of repeated miscarriages, as the antibodies are found in more than 15% of women who experience recurrent pregnancy loss.<sup>3,4</sup> In addition to the pregnancy/birthing complications that are part of the diagnostic criteria, APS patients are at risk for severe thrombotic events, including venous thromboembolism and ischemic stroke, even if time has passed and they no longer qualify for the diagnosis.<sup>5,6</sup>

In a differential diagnosis of APS, the diagnosis and development of TTP becomes challenging (Table 1).

**TABLE 1** Thrombotic microangiopathic antiphospholipid syndrome differential diagnoses

|                                   | TTP            | Catastrophic APS | HUS       | HELLP Syndrome |
|-----------------------------------|----------------|------------------|-----------|----------------|
| Clinical manifestations           |                |                  |           |                |
| Fever                             | ++             | +/-              | +         | --             |
| CNS involvement                   | +++            | ++               | +         | --             |
| Renal involvement                 | +              | ++               | +++       | --             |
| Hepatic involvement               | --             | +                | --        | +              |
| Laboratory features               |                |                  |           |                |
| Thrombocytopenia                  | +++            | ++               | +         | +              |
| Microangiopathic hemolytic anemia | +              | +                | +         | +/-            |
| ADAMTS-13 activity                | Very decreased | ???              | decreased | decreased      |
| Therapy                           |                |                  |           |                |
| Anticoagulation                   | --             | +                | --        | --             |
| Steroids                          | --             | +                | --        | --             |
| IVIg                              | --             | +                | --        | --             |
| Plasma exchange                   | +              | +                | +         | +              |

Autoantibodies to a disintegrin-like and metalloprotease with thrombospondin type I motif, member 13 (ADAMTS 13) can play a role in the development of microthrombosis in TTP patient with APS. TTP occurs because of an occlusive microangiopathy (and has less renal impairment, consumption-related thrombocytopenia and central nervous system symptoms and complications), while APS occurs across all vessel sizes. There are often difficulties in the establishment of a differential diagnosis regarding these two entities.<sup>7,8</sup> Here we present a case where APS and ADAMTS-13 resulted in TTP.

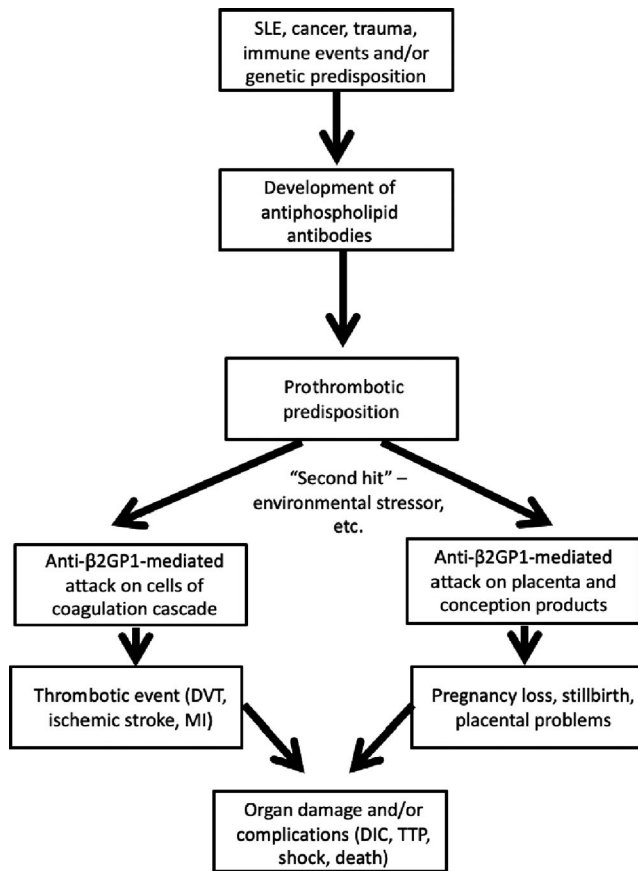
## 2 | CLINICAL REPORT

A 27-year-old African-American female was admitted to the critical care service with malignant hypertension and shortness of breath of 48 hours duration. She had also experienced severe swelling of the lower extremities for 2 weeks previous. In addition, the patient noted mild rectal bleeding for an unspecified time period. The patient received a diagnosis of SLE at the age of 13 with lupus nephritis, undergoing a kidney biopsy in 2012. Her medical history also included asthma, two miscarriages (occurring at approximately 10 weeks of gestation in 2014 and 2017—patient had no live births), an APS diagnosis, a diagnosis of heart failure in October 2017, and an ischemic stroke in December 2017. She had previously been found positive for anticardiolipin antibody, antinuclear antibody, and anti- $\beta_2$  glycoprotein I antibody. However, she tested positive for none of these antibodies on admission. At the time of her miscarriage, in 10/2017 her anti- $\beta_2$  glycoprotein I IgA was 144.7 Standard A Units (<20 SAU being normal), and in 5/2014 her anti- $\beta_2$  glycoprotein I

IgA was 56 SAU. There were no follow-up levels checked at 12 weeks regarding the initial anti- $\beta_2$  glycoprotein I IgA findings in both timelines. Also, a Coombs test was not done. Her medications included mycophenolate mofetil, hydroxychloroquine, labetalol, isosorbide, and prednisone.

Her vital signs were blood pressure 204/131 mm Hg, respiratory rate 21/minute, and pulse 91 beats/minute. The patient's BMI was 39.35 kg/m<sup>2</sup>. Blood tests measured hemoglobin 5.5 mg/dL, hematocrit 16.1%, white blood cells  $2.8 \times 10^9/L$ , platelets  $48\,000 \times 10^9/L$ , haptoglobin < 30 mg/dL, D-dimer 7884 mcg/L, fibrinogen 182 mg/dL, LDH 432 U/L, and creatinine 1.43 mg/dL, later rising to 2.32 mg/dL. Schistocytes were present on blood smear. The patient's computed tomogram of her head revealed no evidence of current hemorrhage, but a remote basal ganglia encephalomalacia was identified, consistent with a previous stroke. Chest X-ray showed mild pulmonary edema, although the electrocardiogram was normal. Renal ultrasound (US) and transthoracic echocardiogram were negative. Additional blood testing showed an ADAMTS13 inhibitor level of 0.8 inhibitor units (normal < 0.5 inhibitor units) and ADAMTS13 activity of 35% (normal > 67%), indicating specific activity against this particular metalloprotease.

US of the patient's lower limbs revealed bilateral deep venous thromboses (DVT), and she was started on intravenous (IV) heparin. She also received nicardipine IV for elevated BP and was diuresed with butenamide. Methylprednisolone was added at 250 mg/d. She received plasmapheresis within 24 hours of admittance, and daily, until platelets reached levels  $> 150\,000 \times 10^9/L$ . The patient's IV nicardipine was transitioned to IV labetalol, oral (PO) nifedipine XL, and PO hydralazine for continued blood pressure regulation. IV



**FIGURE 1** Flow diagram of prothrombotic predisposition and “second hit” stressors leading to the pathophysiology of thrombocytopenic purpura (TTP) through Antiphospholipid syndrome (APS)

heparin was transitioned to coumarin PO. Methylprednisolone IV was transitioned to 1 mg/kg/d of prednisone PO until platelets normalized. Aspirin to prevent further ischemic stroke was not part of her preadmission regimen, nor was it administered upon admission in light of her extremely low platelet count (direct inhibitory effects of aspirin on normal platelet aggregation). Nonetheless, aspirin for these purposes was started upon discharge. Her acute kidney injury resolved with anticoagulation, and she was discharged from the hospital with DVT resolution. However, 6 months later, the patient expired outside of the hospital. Whether her death was a result of complications from the hospital stay described in this case report is unknown.

### 3 | DISCUSSION

While the outcome of this patient may not have been altered, the lack of measurements of her anti- $\beta$ 2 IgA glycoprotein-I antibody 12 weeks part contributed to a more challenging diagnostic picture. The lost opportunities for further antibody testing, after her elevated levels of anti- $\beta$ 2 IgA glycoprotein-I

antibody in May 2014 and October 2017 (both instances around the time of her miscarriages), may have been relevant clinically to her diagnosis. While her APS antibody titers were negative upon this admission, such a finding was probably secondary to her ongoing treatment with the immunosuppressive mycophenolate mofetil, corticosteroids, and hydroxychloroquine. Although there were no follow-up laboratory results regarding anti- $\beta$ 2 IgA glycoprotein-I antibody 12 weeks apart in 2014 and 2017, it is difficult to accept that APS, which causes hypercoagulability that can lead to venous and arterial thrombosis through ADAMTS13 autoantibodies, did not play an important role in the development of microthrombosis and TTP in this patient.

When instructing medical students and residents, teachers and mentors should explain that there are two clinical situations in which APS should be considered: (a) Young patients have any unexplained arterial or venous event, and (b) adverse outcomes to pregnancy, specifically fetal death after 10 weeks of gestation, severe preeclampsia or placental insufficiency causing a premature delivery, or multiple pregnancy losses that occur before 10 weeks of gestation. If either of these two scenarios presents to the practitioner and patient also demonstrated valvular heart disease, livedo reticularis, or central nervous system findings such as lesions within the white matter or deficits in cognition, then APS should be suspected. Furthermore, laboratory findings such as thrombocytopenia that cannot be explained, coagulation abnormalities, or a history of a false-positive test for syphilis (the rapid plasma reagin test and Venereal Disease Research Laboratory test use cardiolipin) should lead to further investigation.

The mechanism of APS involves development of autoantibodies against negatively charged phospholipids, in particular  $\beta$ 2GPI, a cell-surface molecule present on the surface of cells that participate in coagulative processes. APS antibody-mediated attack on these proteins is a factor in the prothrombotic state characteristic of the disease.<sup>9</sup> A “two-hit hypothesis” has been proposed for APS-induced thrombotic events, namely that APS antibodies themselves are responsible only for the prothrombotic state and that environmental or bodily stressors provide the second hit necessary for a clinical event.<sup>10</sup> In addition, this protein and others directly affected by APS are present on the surface of the placenta and other products of conception, suggesting a potential mechanism by which APS leads to pregnancy complications and loss.<sup>9</sup> All of these targets lead to the multi-organ manifestations of the disease and the development of TTP through APS (Figure 1).

The patient had confounding factors related to her pathophysiologic basis of disease that complicated the diagnostic efforts: (a) The nature of her TTP symptoms that posed a risk to her well-being, (b) the contribution of her malignant hypertension to her microangiopathic hemolysis and renal failure, and (c) the SLE may have contributed to the observed

TTP through acquired inhibition of ADAMTS13, consistent with her testing. ADAMTS13 can be found in the ninth chromosome (9q34).<sup>11</sup> Generally, even low levels of ADAMTS13 can be linked to arterial thrombi, myocardial infarction, and cerebrovascular disease.<sup>11,12</sup>

Thrombocytopenic purpura alone is not specifically stated to be a risk for DVT in current medical practice, but the prothrombotic nature of the disease necessitates acknowledgment that this may occur. The known risk of TTP and thrombotic events, even in seronegative APS patients, necessitates prophylactic treatment of this condition. Ultimately, TTP was determined to be the correct diagnosis due to her high levels of ADAMTS13 inhibitor and low levels of ADAMTS13 activity. Although antibodies against ADAMTS13 were not tested for, the evidence of serum resistance to the activity of the metalloprotease was considered specific enough to make the diagnosis. The mildly decreased ADAMTS activity and positive ADAMTS13 inhibitor can be observed in idiopathic TTP, and here are suggestive of TTP.

Thrombocytopenic purpura can be induced by APS. In these cases, ADAMTS13 antibodies develop, which disallow the function of this metalloprotease and facilitate a pathological state.<sup>13</sup> TTP results from subsequent lack of metalloprotease activity within the vasculature, leading to lack of regulation of the clotting cascade and resultant clots within small vessels.<sup>14</sup> Shear force within the vessels can fragment blood cells, leading to schistocytes and deficiency in homeostatic cells and proteins.<sup>13</sup> Further clotting, ischemic gangrene, disseminated intravascular coagulation, and death can result if this is not treated in a timely fashion.<sup>14,15</sup>

Risk factors for mortality in TTP include age and renal dysfunction, which are already present in patients with SLE.<sup>16</sup> TTP is treatable, as are SLE and APS, but a combination of these diseases can enhance poor patient outcomes, regardless of therapeutic efforts.<sup>17</sup> Antibodies to ADAMTS13 play an important role in the pathophysiology of thrombotic events in patients already diagnosed with APS and increase the risks of an already life-threatening disease.<sup>17</sup>

Given the nature and potential complications of TTP, it must be expeditiously considered within the differential diagnosis and treated as soon as possible with anticoagulants, steroids, and plasmapheresis.<sup>17</sup> This is in addition to methods such as antibiotics, blood transfusion, mechanical ventilation, and dialysis if organ-specific or septic complications are present. It is imperative that clinicians follow up on elevated lupus anticoagulant, anticardiolipin antibody, or anti- $\beta_2$  glycoprotein I ( $\beta_2$ GPI) antibodies at 12 weeks after initial elevated findings in order to secure an appropriate APS diagnosis. Follow-up, suspicion, and vigilance are of paramount importance for health care providers, especially when considering a pathway to TTP via ADAMTS13 through APS.

## 4 | CONCLUSION

Antiphospholipid syndrome (APS) is a common complication associated with systemic lupus erythematosus (SLE), with APS antibodies occurring in nearly half of SLE patients. While thrombotic thrombocytopenic purpura (TTP) is a rare further complication of this disease state, its severity necessitates prompt and aggressive treatment for all suspected cases.

## ACKNOWLEDGMENT

We thank the patient for her cooperation and permissions during her hospitalization.

## CONFLICT OF INTEREST

The authors have no conflict of interest to declare.

## AUTHOR CONTRIBUTIONS

HHD: wrote the majority of the manuscript and reviewed the laboratory findings. MD: cared for the patient, edited, and revised the manuscript. SMP: edited, revised the manuscript and contributed perspectives. TJP: conceived the case report, reviewed and selected the laboratory reports, critically revised and edited the manuscript, and cared for the patient. All authors gave final approval for the version to be published.

## ORCID

Thomas John Papadimos  <https://orcid.org/0000-0002-4024-227X>

## REFERENCES

1. Lim W. Antiphospholipid antibody syndrome. *Hematology Am Soc Hematol Educ Program* 2013; <http://asheducationbook.hematologylibrary.org/content/2013/1/675.long>, accessed April 30, 2019.
2. Miyakis S, Lockshin MD, Atsumi T, et al. International consensus statement on an update of the classification criteria for definite antiphospholipid syndrome (APS). *J Thromb Haem.* 2006;4(2):299-306.
3. Brock CO, Brohl AS, Običan SG. Incidence, pathophysiology, and clinical manifestations of antiphospholipid syndrome. *Birth Defects Res C Embryo Today.* 2015;105(3):201-208.
4. Al Jameil N, Tyagi P, Al SA. Incidence of anticardiolipin antibodies and lupus anticoagulant factor among women experiencing unexplained recurrent abortion and intrauterine fetal death. *Int J Clin Exp Pathol.* 2015;8(3):3204-3209.
5. Lim W, Crowther MA, Eikelboom JW. Management of antiphospholipid antibody syndrome. *JAMA.* 2006;295(9):1050-1057.
6. Medina G, Briones-García E, Cruz-Domínguez MP, Flórez-Durante OI, Jara LJ. Antiphospholipid antibodies disappearance

- in primary antiphospholipid syndrome: thrombosis recurrence. *Autoimm Rev.* 2017;16(4):352-354.
7. de Carvalho JF, Freitas CA, Lima I, Leite CC, Lage LV. Primary antiphospholipid syndrome with thrombotic thrombocytopenic purpura: a very unusual association. *Lupus.* 2009;18(9):841-844.
  8. Viner M, Murakhovskaya I. A rare combination of thrombotic thrombocytopenic purpura and antiphospholipid syndrome. *Blood Coagul Fibrinolysis.* 2017;28(5):411-415.
  9. Meroni PL, Borghi MO, Raschi E, Tedesco F. Pathogenesis of antiphospholipid syndrome: understanding the antibodies. *Nature Reviews Rheum.* 2011;7:330-339.
  10. Bordin G, Boldorini R, Meroni PL. The two hit hypothesis in the antiphospholipid syndrome: acute ischaemic heart involvement after valvular replacement despite anticoagulation in a patient with secondary APS. *Lupus.* 2003;12:851-853.
  11. Levy GG, Motto DG, Ginsburg D. ADAMTS13 turns 3. *Blood.* 2005;106(1):11-17.
  12. April T. Advances in the pathogenesis, diagnosis, and treatment of thrombotic thrombocytopenic purpura. *J Am Soc Nephrol.* 2003;14(4):1072-1081.
  13. Habe K, Wada H, Matsumoto T, et al. Plasma ADAMTS13, von willebrand factor (VWF), and VWF propeptide profiles in patients with connective tissue diseases and antiphospholipid syndrome. *Clin App Thromb/Haem.* 2017;23(6):622-630.
  14. Hanna RM, Hanna M, Larson B, Lopez EA, Wilson J, Hendifar A. Thrombotic microangiopathy due to catastrophic antiphospholipid antibody syndrome confirmed on skin biopsy and treated with eculizumab. *J Onco-Nephrol.* 2017;1(2):e1-e7.
  15. Fritsma GA, Southern DK. Hematologic effects of thrombophilia. *Clin Lab Sci.* 1998;11(4):233-238.
  16. Pham HP, Cao W, Williams LA, et al. Predictors for In-hospital mortality in patients with autoimmune thrombotic thrombocytopenia purpura (TTP): a single center experience. *Blood.* 2016;128:3853.
  17. Scully M, Hunt BJ, Benjamin S, et al. Guidelines on the diagnosis and management of thrombotic thrombocytopenic purpura and other thrombotic microangiopathies. *British J Haem.* 2012;158(3):323-335.

**How to cite this article:** Dolin HH, Dziuba M, Pappada SM, Papadimos TJ. Presumed antiphospholipid syndrome and thrombotic thrombocytopenic purpura: An infrequent association. *Clin Case Rep.* 2019;7:1984–1988. <https://doi.org/10.1002/ccr3.2416>