



Case series

Intra-operative enteroscopic polypectomy—An innovative hybrid approach using straight sticks

Nidhisha Sadhwani^{a,*}, Ajay Bhandarwar^a, Eham Arora^a, Raj Gajbhiye^b, Waqar Ansari^a, Amol Wagh^a, Prashant Rahate^c, Jasmine Agarwal^a

^a Department of General Surgery, Grant Medical College & Sir JJ Group of Hospitals, Mumbai, India

^b Department of General Surgery, Government Medical College & Hospital, Nagpur, India

^c Seven Star Hospital, Nagpur, India

ARTICLE INFO

Keywords:

Enteroscopy
Peutz-Jeghers syndrome
Minimally invasive surgery
Small bowel polyps
Intussusception
Intestinal obstruction

ABSTRACT

Background: Peutz-Jeghers Syndrome (PJS) is an uncommon intestinal polyposis disorder. Bowel obstructions are a recurring problem in PJS and as many as 50% of these patients require surgery. The current standard of care for these patients is to perform a flexible enteroscopic polypectomy. The traditional push-pull enteroscopy however, might be unavailable or unsuitable in an emergency setting. Alternatively, repeated laparotomies with multiple small bowel resections can lead to short bowel syndrome.

Methods: In our series, we describe an innovative technique where a short midline laparotomy permitted sufficient access to reduce the intussusception(s) and perform a bowel walk. Rigid laparoscopic instruments were introduced within the small bowel lumen via enterotomies, to perform polypectomies along the entire small bowel length. This precludes the need for small bowel resections which can thwart the development of short bowel syndrome.

Results: Two patients with PJS presenting with acute small bowel obstruction underwent surgery using the described approach. Another two patients with PJS having multiple intussusceptions on CT underwent an elective prophylactic polypectomy using the same approach. We were able to run the bowel in its entirety and a maximum of 41 polyps were retrieved from the port site enterotomy. The operating times were modest and no unique complications pertaining to this technique were encountered.

Conclusion: Small bowel polypectomy using rigid instrumentation employing a limited midline laparotomy is an attractive option for both emergency and elective settings in patients with PJS.

1. Introduction

Peutz-Jeghers syndrome (PJS) is an uncommon autosomal dominant condition caused by a germline mutation in serine threonine kinase-11 tumor suppressor gene with prevalence ranging from 1 in 50,000 to 2,00,000 live births [1]. It is characterised by multiple gastro-intestinal polyps mainly involving the small intestine, and muco-cutaneous hyperpigmentation at the vermillion border of the lips. The jejunum-ileum is the most frequent site of polyps, followed in order, by the colo-rectum, stomach and the duodenum. Polyps can appear in the 1st decade of life and may be the lead point of an intussusception, which is often just a transient intestinal telescoping without any clinical sequelae [2,3]. However, almost half of all cases need surgery for unrelenting intestinal obstruction. Intestinal obstructions are a recurring problem in PJS

where multiple surgeries with repeated bowel resections produces short bowel syndrome (SBS) in as many as 25% of these cases [4]. Polyps larger than 1 cm are at a risk of malignant conversion. Prophylactic polypectomy should thus be performed for sizeable small bowel polyps to reduce the risk of malignancy and other polyp-related complications like mechanical bowel obstruction. Current practices for dealing with patients of intestinal polyposis are to perform an enteroscopic polypectomy or a laparotomy with multiple small bowel resections. Traditional flexible push-pull enteroscopy for polypectomy has several limitations – it is technically demanding, time-consuming, cannot be passed across the entire length of small bowel, and is largely unsuitable in an emergent setting with multiple intussusceptions. In a patient who is undergoing a laparotomy for acute bowel obstruction, there presents a precious opportunity to screen the entire length of small bowel, perform

* Corresponding author at: Dept. of General Surgery, 6th Floor, Hospital Building, JJ Hospital Campus, Byculla, Mumbai 400008, India.

E-mail address: sadhwani.nidhisha@gmail.com (N. Sadhwani).

<https://doi.org/10.1016/j.ijscr.2021.106102>

Received 28 April 2021; Received in revised form 6 June 2021; Accepted 7 June 2021

Available online 16 June 2021

2210-2612/© 2021 The Authors. Published by Elsevier Ltd on behalf of IJS Publishing Group Ltd. This is an open access article under the CC BY-NC-ND license

(<http://creativecommons.org/licenses/by-nc-nd/4.0/>).

prophylactic polypectomies, possibly avoiding bowel resections. In this paper, we describe how enteroscopic polypectomy can be performed using “straight sticks” i.e. rigid laparoscopic instruments, in patients with PJS undergoing a laparotomy for acute bowel obstruction. This technique can help trim the polyp burden and thereby help reduce subsequent intussusceptions, re-laparotomies, bowel resections and SBS.

2. Materials and methods

2.1. Patient details

Two patients with PJS presenting with acute small bowel obstruction underwent a short midline laparotomy with polypectomy as described below. The first patient was a 28-year-old man who had two jejuno-jejunal intussusceptions. The second patient was a 38-year-old man with multiple small bowel intussusceptions on his contrast enhanced CT scan. The classical muco-cutaneous hyperpigmentation was seen in both these patients, as shown in Fig. 1. On eliciting the history, we found out that the siblings of our second patient also suffered from PJS. They had suffered repeated intussusceptions on scans with large polyps which were being managed conservatively. They underwent an elective polypectomy using the same approach due to the unavailability of flexible endoscopy at our centre.

2.2. Operative procedure

A short midline laparotomy was performed. The entire bowel was run and sites of intussusception identified, as seen in the accompanying Video S1. The intussusceptions were reduced by gently milking the intussusceptum out of the distal segment (Fig. 2). The bowel was palpated along its length to locate sizeable intra-luminal polyps (Fig. 3). Variably sized polyps were present from the duodeno-jejunal (DJ)

flexure to the ilio-caecal (IC) junction. An enterotomy was created midway between the DJ flexure and the IC junction with a purse string suture around it (Fig. 4). A 10 mm laparoscopic trocar was introduced through this enterotomy while tightening the purse-string around it. Atraumatic bowel clamps were applied near the DJ flexure and distal to the port. Carbon dioxide was insufflated at a pressure of 2 mmHg in the small bowel segment at a flow rate of 4 l/min (Fig. 5). Two 5 mm working ports were introduced via small enterotomies on either side of the camera port (Fig. 6). The entire bowel length is scanned endoscopically from the site of port insertion up to the DJ flexure (Fig. 7). Advancement is facilitated by telescoping the bowel like a sleeve onto the rigid laparoscope (Fig. 8). Polyps, when encountered, were excised using ultrasonic shears (Fig. 9). The monopolar snares commonly used for endoscopic polypectomy carry the disadvantage of possible direct coupling, thereby risking damage to the adjacent bowel wall (Fig. 10). The usage of ultrasonic shears helps prevent this while also limiting lateral thermal spread [5]. Once the DJ flexure was reached, the bowel was unsleeved over the scope and the scope redirected towards the IC junction. The bowel clamps were now applied proximal to the ports and at the IC junction. The remainder of the procedure was repeated as earlier. The ports were then pulled and the disconnected polyps were milked towards the 10 mm enterotomy and retrieved through it (Figs. 11, 12). At the end of the procedure, enterotomies were closed with polydioxanone sutures. The highest polyp yield within our small group was 41 from a single patient. This study is registered with a research registry. UIN - researchregistry6816.

3. Results

We operated on 4 patients with PJS using this approach. Two of them presented with acute small bowel obstruction in their 3rd and 4th decade of life. Two patients, both in their 2nd decade underwent an

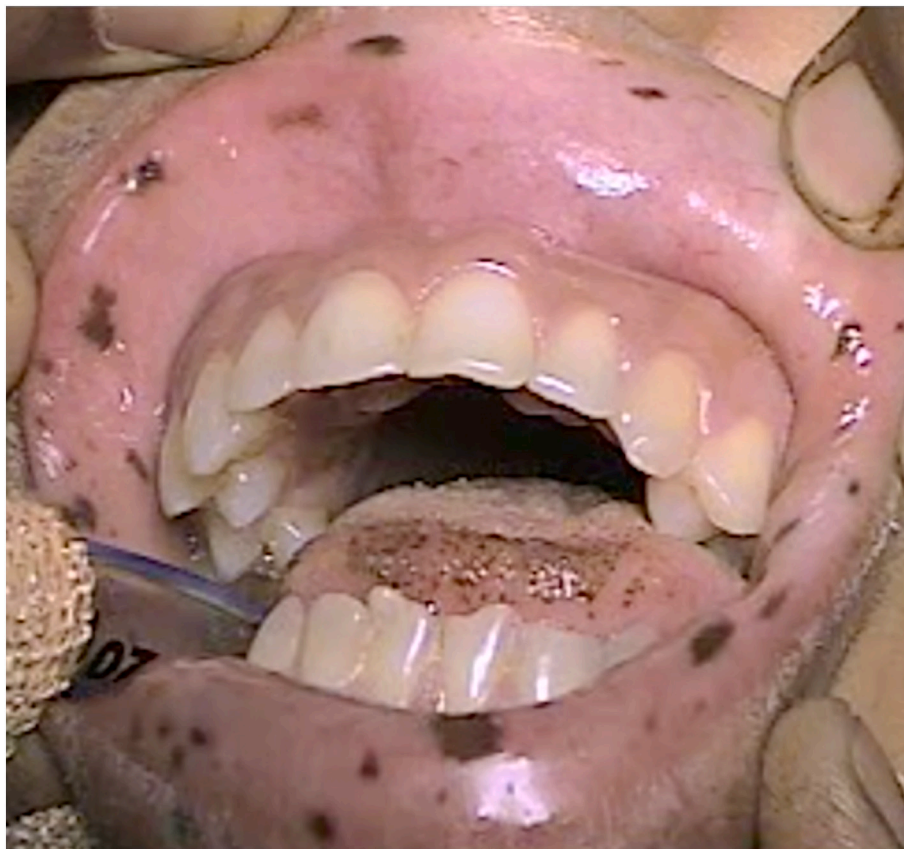

Fig. 1. Muco-cutaneous hyperpigmentation in a patient with Peutz-Jeghers Syndrome.

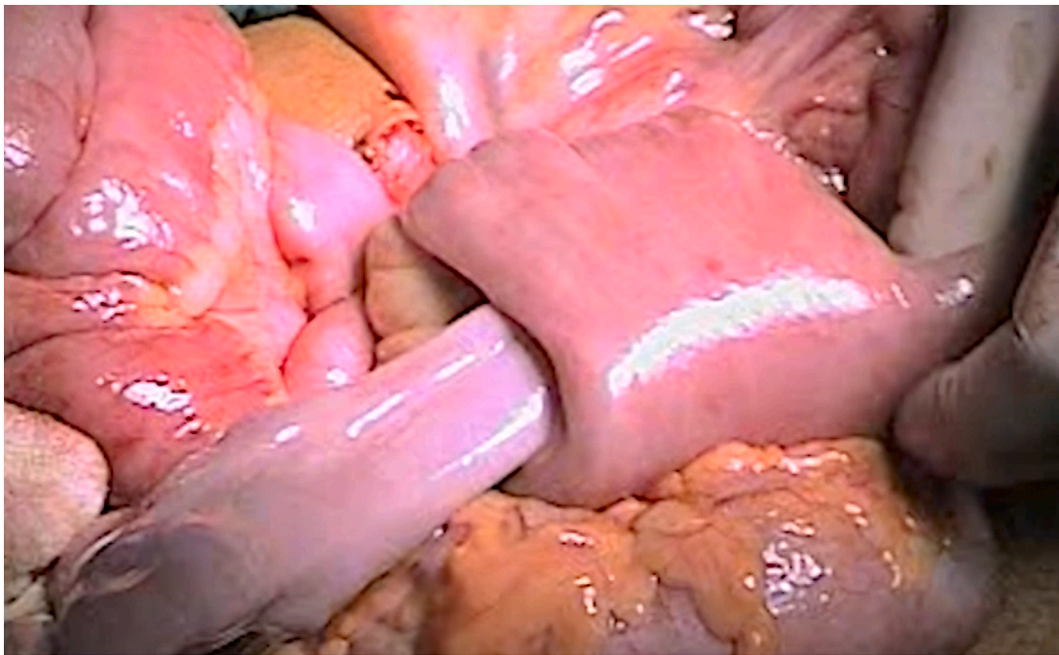


Fig. 2. Milking the intussusceptum out.

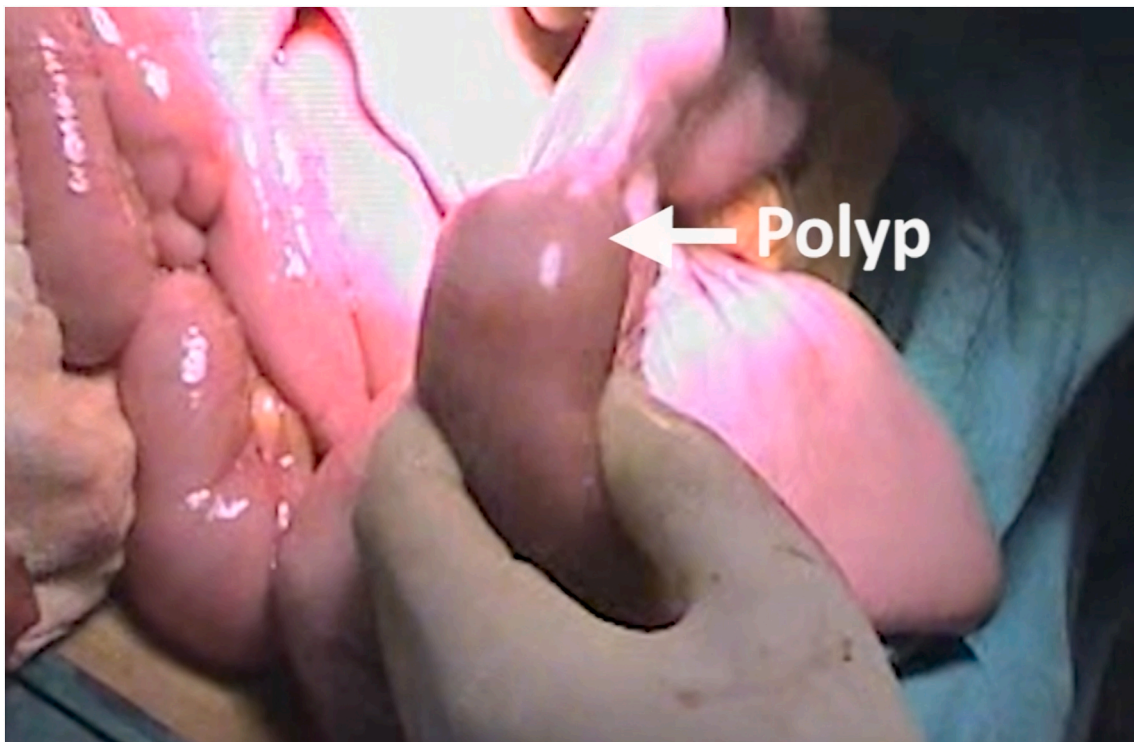


Fig. 3. At laparotomy of a case of Peutz-Jeghers Syndrome with acute small bowel obstruction, polyps are confirmed to be the lead point of intussusception.

elective prophylactic polypectomy using the same approach. An average of 38 polyps was retrieved, the largest number being 41. These polyps were retrieved through the port site. In none of these cases did we need additional enterotomies to retrieve the polyps. Histopathological examination of the polyps revealed hamartomatous changes. Diet was resumed as soon as the small bowel function returned. Average duration of hospital stay was 4 days. We noted two complications (1 paralytic ileus, 1 suture site abscess) in these cases which are classified as Grade I according to the Clavien-Dindo classification. (See [Table 1](#).)

4. Discussion

Most small bowel tumors are benign. Polyps are adenomatous in Lynch syndrome and familial adenomatous polyposis (FAP), and hamartomatous in Peutz-Jeghers syndrome (PJS). Polyps in patients with FAP or Lynch syndrome are at a significant risk of malignant conversion [6,7]. Prophylactic polypectomy is therefore indicated for all adenomatous polyps. Malignant transformation of polyps in PJS is rare, even though the hamartoma-adenoma-carcinoma progression has been

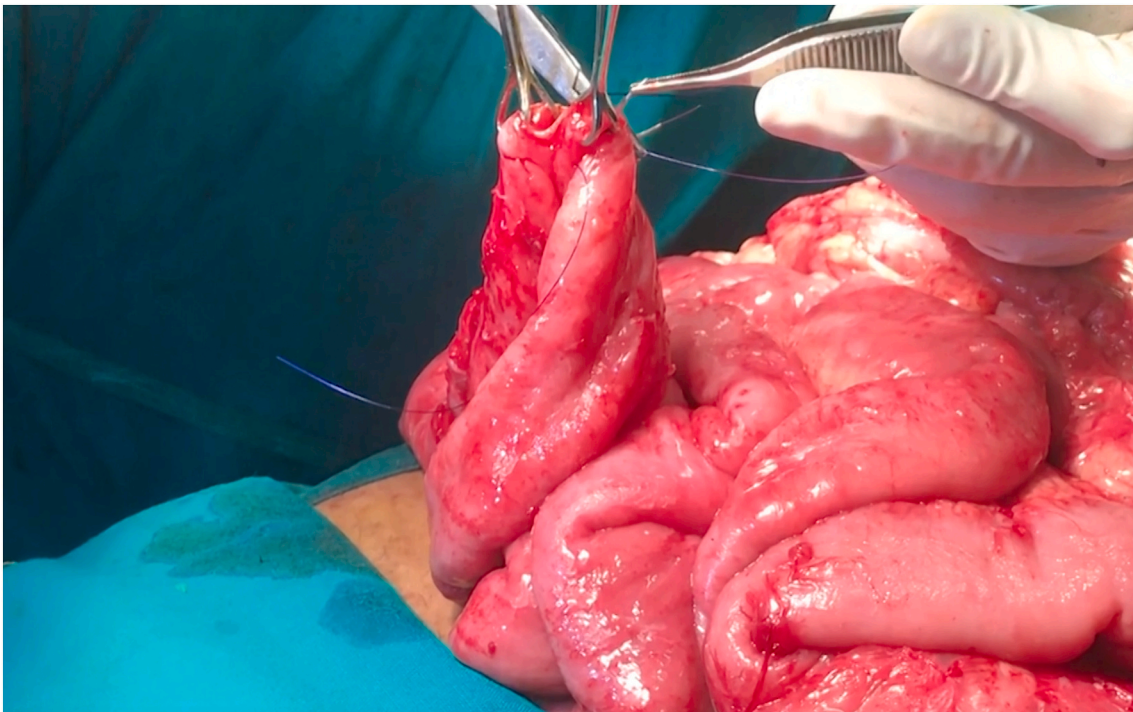


Fig. 4. The 10 mm enterotomy for the camera port is created mid-way between the duodeno-jejunal flexure and the ileo-colic junction, secured with a purse string suture around it.

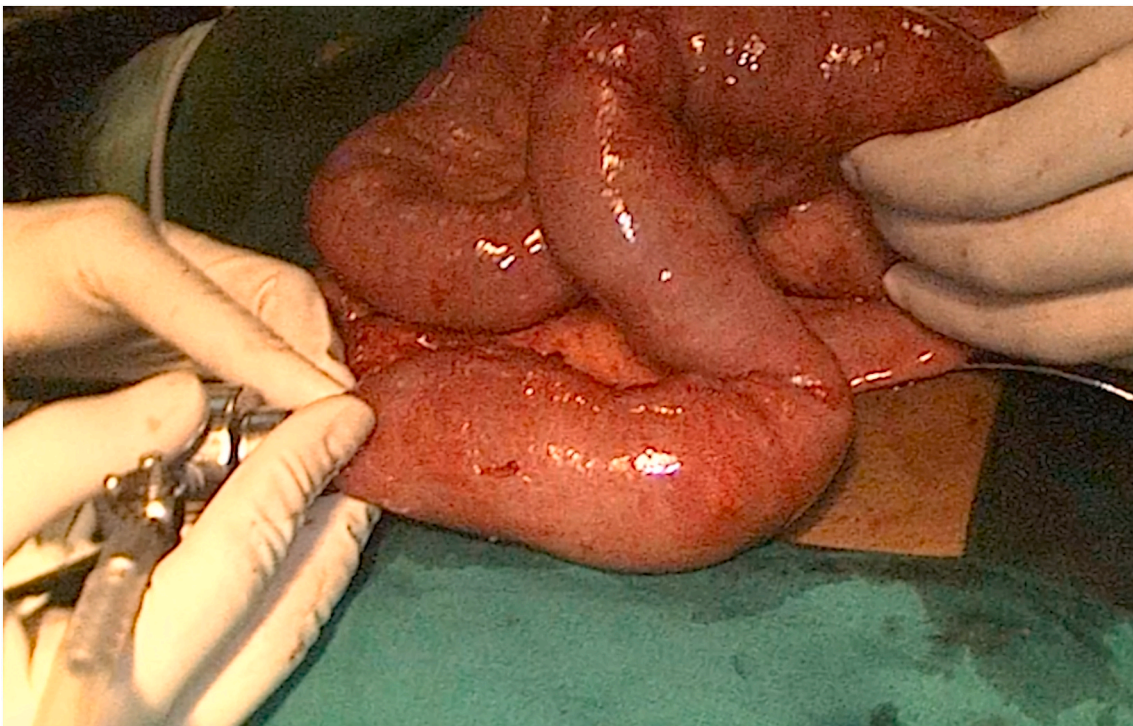


Fig. 5. Carbon dioxide insufflation in the bowel loop, till the DJ flexure.

described in them. The small bowel, stomach, colon, pancreas and extra-intestinal organs such as Sertoli cells, breast and ovaries are at a risk of cancer in patients with PJS. Ultimately, the risk of malignant conversion within a polyp is linked to its dimensions. Ohmiya et al. observed that in PJS, polyps greater than 1.5 cm in size could harbour an adenomatous component [8].

The most recently published surveillance protocols for PJS suggest a baseline endoscopy to be performed at the age of 8 years [9] (Fig. 13). In patients with polyps, a prophylactic polypectomy is recommended for polyps which are symptomatic, rapidly growing, or are asymptomatic but more than 1 cm in size, to prevent mechanical complications and prune the risk of malignancy [10–12]. The guidelines recommend intra-

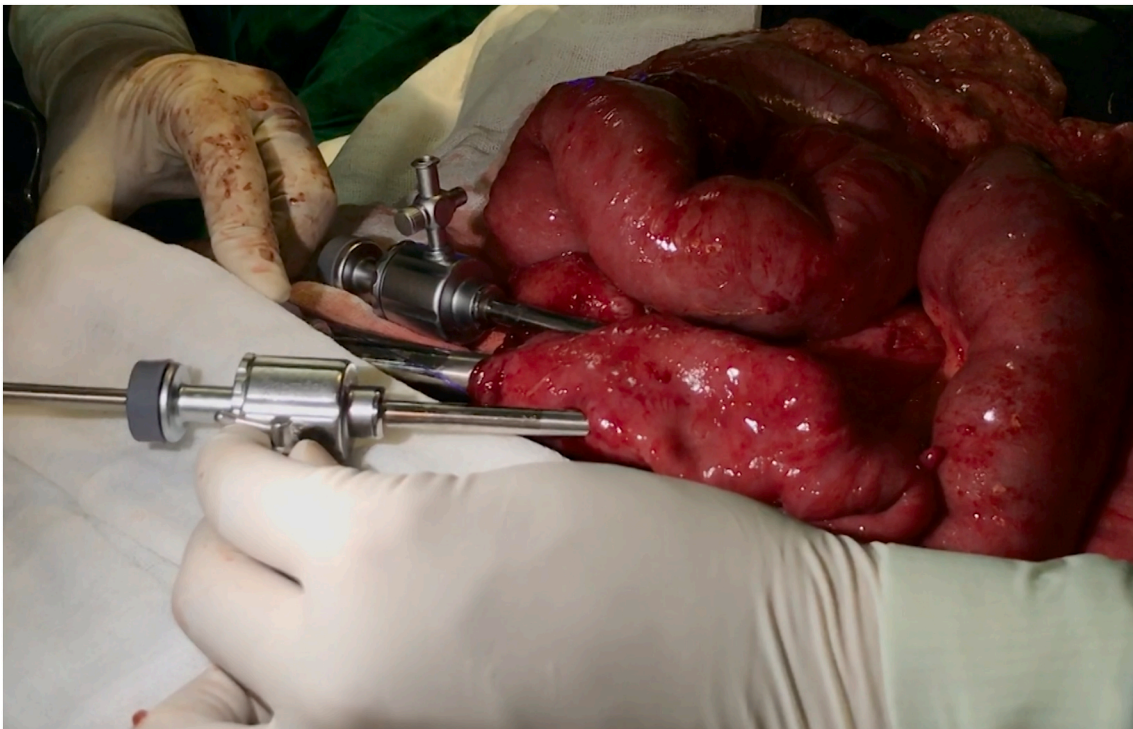


Fig. 6. Final position of the three ports.

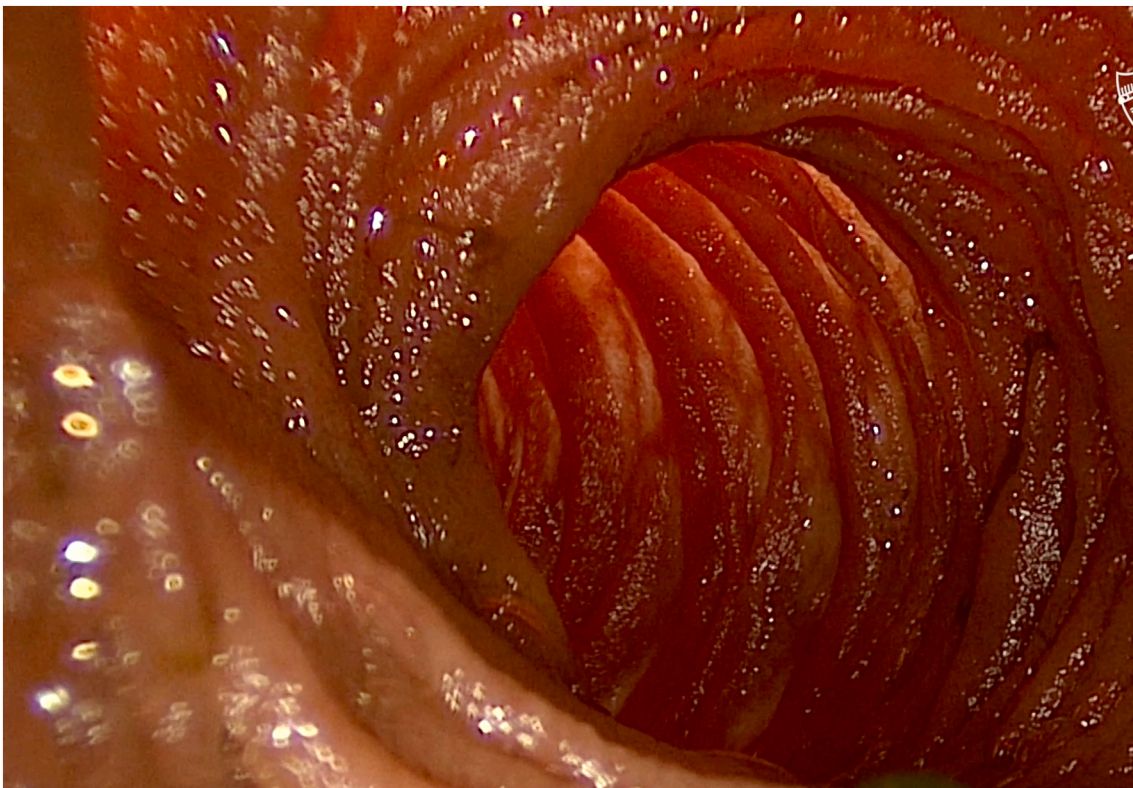


Fig. 7. Intra-luminal view of the bowel as seen through the scope.

operative enteroscopic polypectomy in both elective and emergent situations. The evidence regarding the usage of push-enteroscopy for prophylactic polypectomy in these patients is sparse [13,14].

Various techniques of enteroscopy are currently in use, viz:

- Push/pull enteroscopy: This procedure is performed with a specifically designed enteroscope or by using a colonoscope, with or without an overtube. Prophylactic snare polypectomy is routinely performed in PJS using traditional push/pull enteroscopy. This

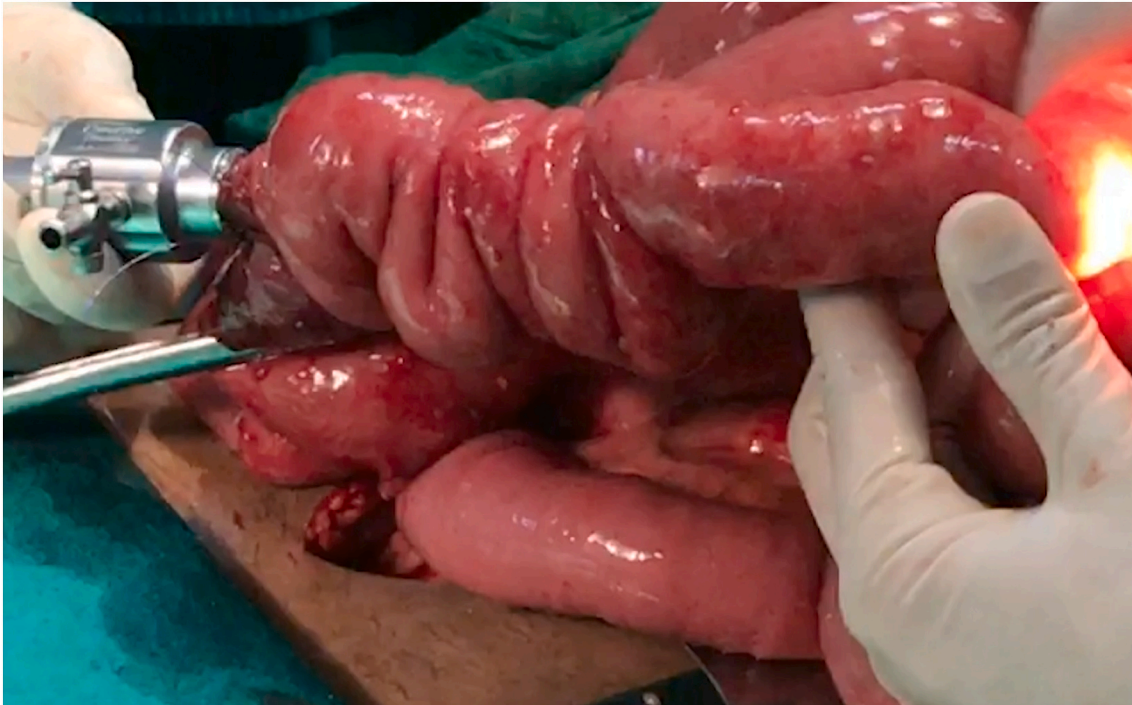

Fig. 8. Sleeving the small bowel over the rigid laparoscope.

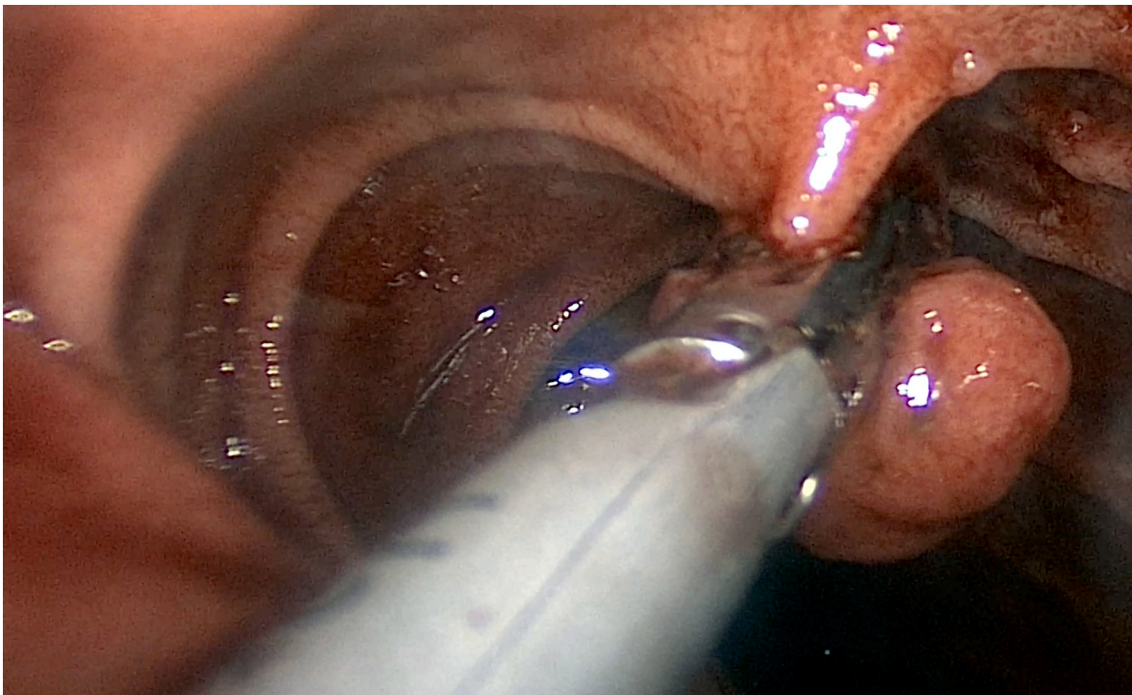


Fig. 9. Division of polyp base using ultrasonic shears.

reduces the risk of malignant transformation within enlarging polyps or subsequent acute bowel obstruction, with minimum morbidity. However, the intervention is not without its challenges.

- Endoscopic examination of the entire small bowel is difficult as push type enteroscope cannot reach the distal small bowel.
- Bulky polyps with a thick stalk may not be amenable to resection by snares.

- In patients with a history of prior laparotomies, advancement of the endoscope is difficult owing to post-operative inter-bowel adhesions.
- Inspection of the serosal surface is not possible to look for tears, perforations.
- The procedure is technically demanding, time consuming
- The procedure is generally not suitable in emergent situations.
- Device-assisted enteroscopy (double-balloon/push-pull enteroscopy, single-balloon enteroscopy, and spiral enteroscopy): Deeper

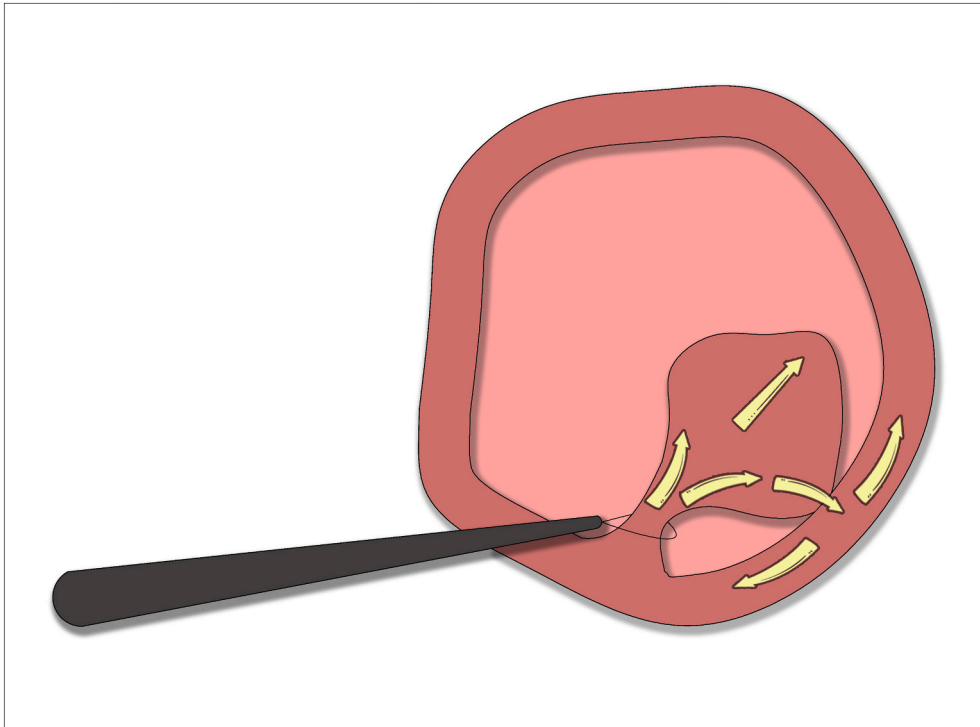


Fig. 10. The use of monopolar energy in snares for polypectomy can produce inadvertent damage to adjacent healthy bowel wall as a result of direct coupling. This is particularly challenging in larger polyps.

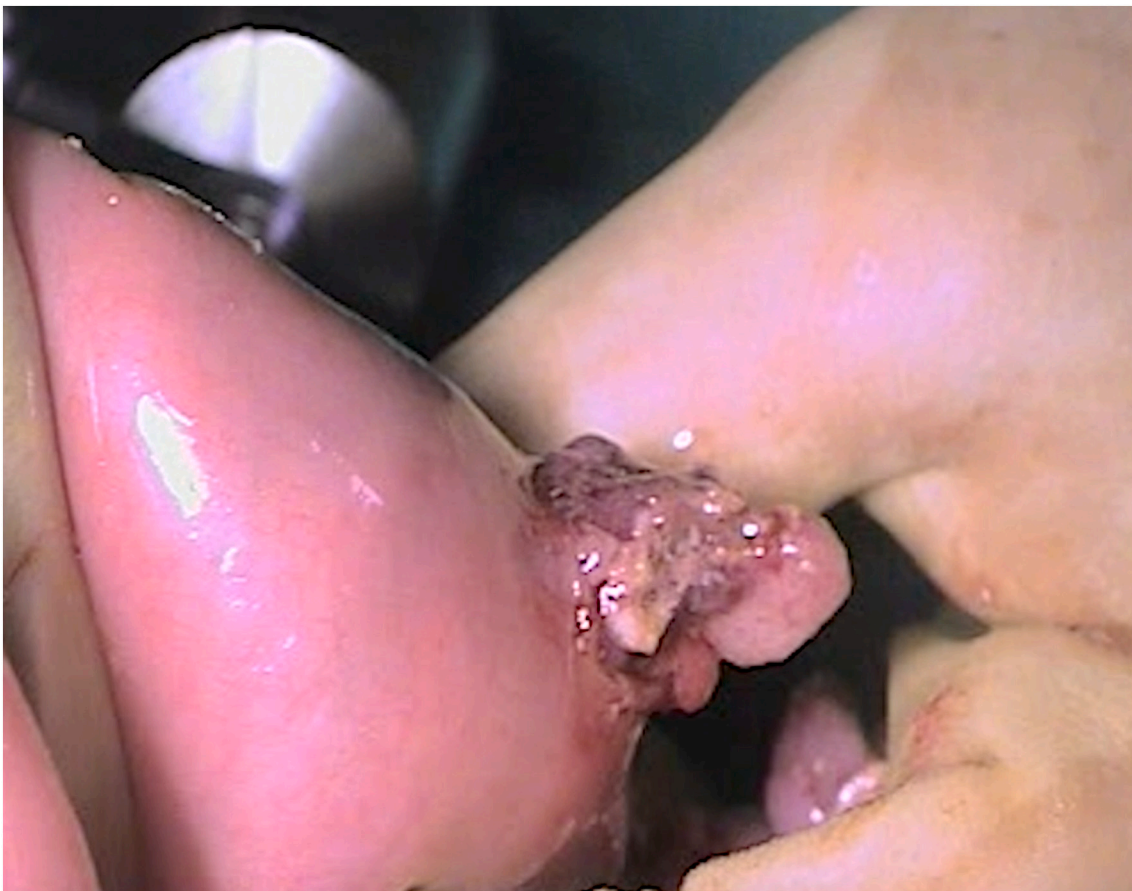

Fig. 11. Retrieval of polyps through the 10 mm camera-port enterotomy.

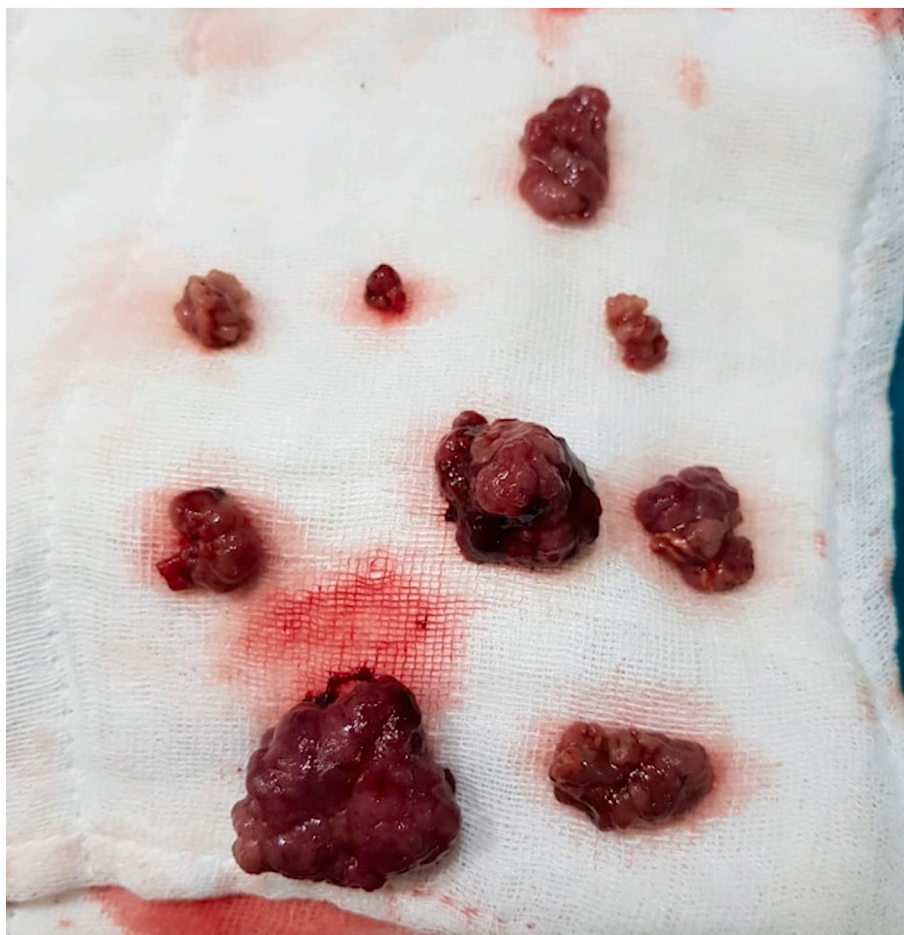

Fig. 12. A photograph of retrieved polyps extracted from the enterotomy for the 10 mm camera-port.

Table 1

Outcomes of enteroscopic polypectomy with rigid instruments at our institute.

Number of patients:	4
Highest number of polyps retrieved:	41
Mean operative time:	126 min
Mean estimated blood loss	292 ml
Average hospital stay	4 days
Post-operative complications	
Paralytic ileus	1
Suture site abscess	1

evaluation of the small bowel can be accomplished with enteroscopes coupled with a specialized overtube apparatus. The procedure can be performed via an antegrade approach (via the mouth) or via a retrograde approach (via the anus). Due to the limited working length of these endoscopes, transoral and transrectal routes are less likely to achieve full visualisation of small intestine. There might be a failure to reach the terminal ileum. Prior history of a laparotomy, extensive adhesions, patients presenting with a strangulated bowel, preclude its use.

- Intra-operative enteroscopy: An endoscope is inserted per orally, anally or via an enterotomy and is guided through the small bowel with surgical assistance (laparoscopy/laparotomy). The 'clean sweep' technique is a widely accepted procedure these days for clearing the entire bowel [15]. Major indications for intraoperative enteroscopy are: obscure gastrointestinal bleeding (in patients with negative gastroscopy, push-enteroscopy, and colonoscopy), focal pathology of the small intestine (beyond the reach of the push-

enteroscopy or colonoscopy), vague findings in small bowel follow-through scans, suspected malignant tumors of the small bowel, Crohn's disease and in patients with PJS for prophylactic polypectomy. An enterotomy offers the best access for inspecting the whole length of the small bowel as trans-anal and transoral routes offer incomplete inspection. In a study by Schulz & Schmidt, it was reported that the incidence of mucosal and serosal tears in intraoperative enteroscopy, due to extensive pleating of the bowel on a flexible endoscope by transoral or trans-anal routes was as high as 52%. Intraoperative complications were reported to be 3%, post-operative complications 26% and 30-day mortality in 6% of cases [16]. The usage of a trans-abdominal flexible endoscope through an enterotomy however can be tedious and time consuming.

Nearly 50% of patients with PJS eventually present with intussusception requiring surgery. 1 in 4 of these surgeries is performed for recurrent obstruction [4]. Repeated bowel resections can eventually lead to SBS. When a patient with PJS presents in an emergency, we have two available options for a small bowel polypectomy: resection of the involved bowel segments or an enteroscopic polypectomy.

For a patient of PJS presenting with acute bowel obstruction at a centre where flexible enteroscopy is unavailable, a limited laparotomy allows adequate access to the small bowel with reduction of the intussusception. Here, detection of intra-luminal polyps is largely by palpation with subsequent resection of involved segments. This technique is crude and imprecise. The enteroscopic polypectomy in these patients can be easily achieved by using rigid laparoscopic instrumentation. This technique is advantageous as:

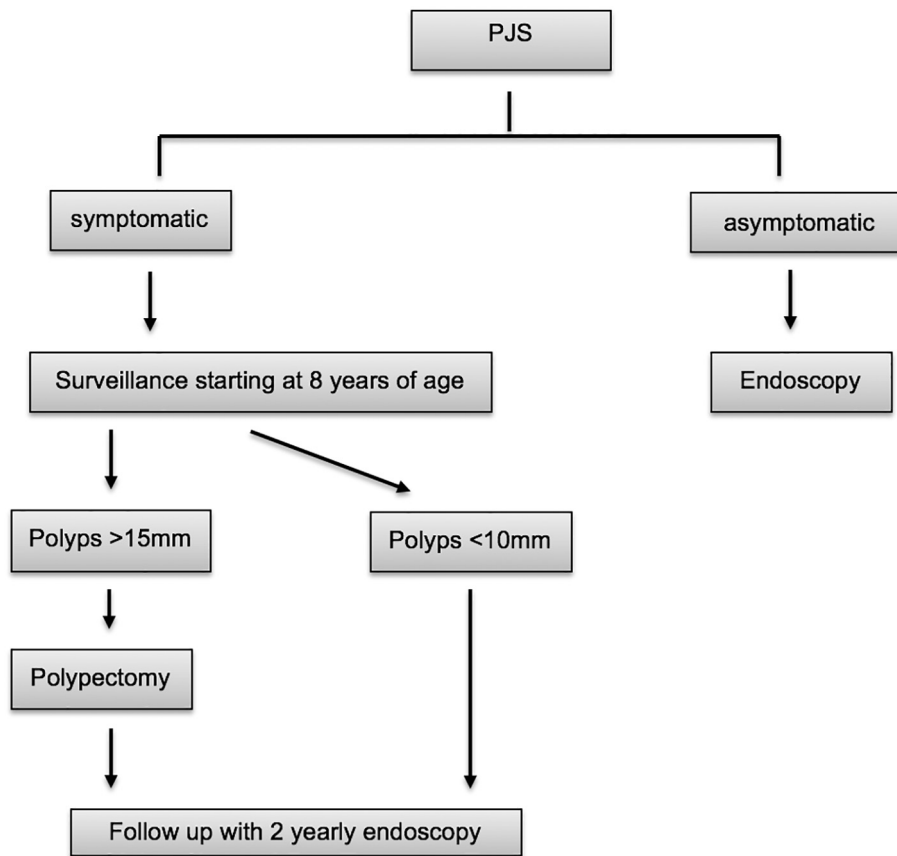


Fig. 13. Surveillance protocol for patients of Peutz-Jeghers Syndrome (Adapted from Torroni F. Conservative approach in Peutz-Jeghers syndrome: Single-balloon enteroscopy and small bowel polypectomy. *World J Gastrointest Endosc.* 2014;6(7):318. doi:<https://doi.org/10.4253/wjge.v6.i7.318>).

- It allows a relatively unhindered access to polyps along the entire length of small bowel.
- In a patient population which is likely to undergo multiple surgical interventions, it has the potential to forestall bowel resections and diminish the risk of short bowel syndrome.
- An additional advantage is the ability to perform the procedure without requiring expertise beyond the operating surgical team.
- The polypectomy snares used in traditional enteroscopic polypectomies using flexible scopes can cause post-polypectomy syndrome and bowel injury due to unintentional direct coupling. This is overcome by usage of ultrasonic energy devices used in our technique [17]

Enteroscopic polypectomy using flexible endoscopes is the current standard of care for small bowel polyps in PJS. However, given its limited availability in general, and challenges in an acute intussusception, its role is limited in an emergent setting. Even when the conditions are ideal, one may be unable to scan the entire small bowel length and the retrieval of bulky polyps is challenging. When resources are limited, or when faced with an acute obstruction, using straight sticks to scan the bowel delivered via a limited laparotomy is an easy and attractive surgical option (Fig. 14). While not a truly minimally invasive, this technique significantly reduces the “amount” of surgery performed, with acceptably good outcomes. We believe it has a role to play in the continuing surgical management of PJS cases.

5. Conclusion

Based on our limited but encouraging initial experience, we propose that intra-operative enteroscopic polypectomy using rigid laparoscopic instruments (straight sticks) introduced via a limited laparotomy is a

viable surgical option in both elective and emergent settings in cases with intussusceptions from intestinal polyps. The approach is economical on both resources and skill, and can be safely performed even at smaller centres.

The work has been reported in line with the PROCESS 2020 criteria [18].

Provenance and peer review

Not commissioned, externally peer-reviewed.

Supplementary data to this article can be found online at <https://doi.org/10.1016/j.ijscr.2021.106102>.

Précis

Flexible enteroscopy may not be a feasible therapeutic option in hereditary intestinal polyposis with mechanical bowel obstruction. In our innovative technique, a limited laparotomy permits reduction of the intussusception, with clearance of polyps using rigid laparoscopic instruments introduced via enterotomies to achieve complete polyp clearance within the small bowel.

Funding

No financial support was received for this study.

Ethical approval

This study was declared exempt by the ethics committee.

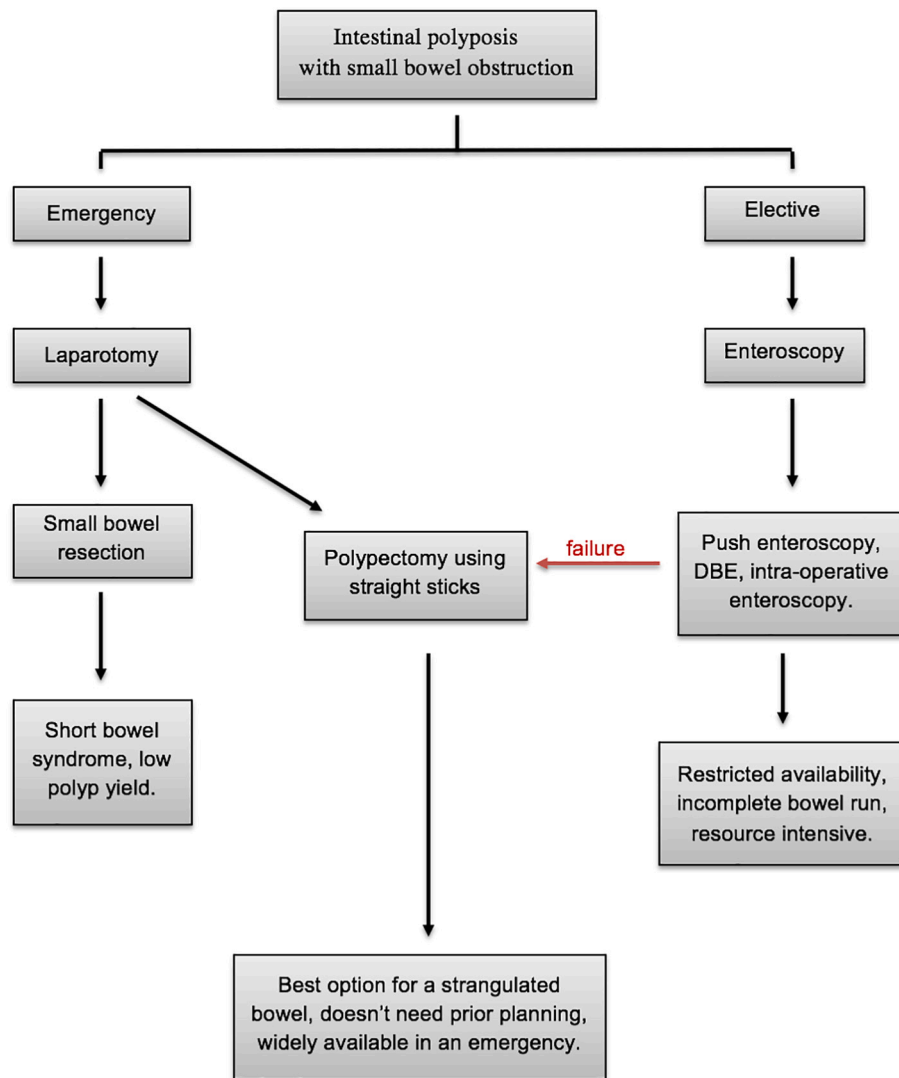


Fig. 14. Our management algorithm for patients with intestinal polyposis presenting with acute small bowel obstruction.

Consent

Written informed consent was obtained from the patient for publication of this case report and accompanying images. A copy of the written consent is available for review by the Editor-in-Chief of this journal on request.

Author contribution

Dr. Ajay Bhandarwar helped formulate the study design, in the data analysis and the writing of the manuscript.

Dr. Nidhisha Sadhwani helped write the manuscript.

Dr. Eham Arora helped formulate the study design, reviewed the literature and helped in the writing of the manuscript.

Dr. Waqar Ansari, Dr. Raj Gajbhiye, Dr. Prashant Rahate helped design the study, collect the data and interpret the data.

Dr. Amol Wagh helped with the data collection, literature review and writing of the manuscript.

Dr. Jasmine Agarwal helped in the data collection and writing of the manuscript.

Registration of research studies

None.

Guarantor

Dr. Ajay Bhandarwar.

Declaration of competing interest

Dr. Nidhisha Sadhwani presented this series at the SAGES meeting held at Baltimore, Maryland, USA in April 2019, winning the SAGES Go Global Award.

Dr. Eham Arora has received honoraria for speaking engagements from Johnson & Johnson Pvt. Ltd., India. He is a partner in HerniaCAT Surgical Radiology Inc.

The remaining authors state that they have no conflicts of interest to disclose.

References

- [1] H. Jeghers, V.A. McKusick, K.H. Katz, Generalized intestinal polyposis and melanin spots of the oral mucosa, lips and digits; a syndrome of diagnostic significance, *N. Engl. J. Med.* 241 (26) (1949) 1031–1036, <https://doi.org/10.1056/NEJM194912292412601>.
- [2] T.R. Foley, T.J. McGarrity, A.B. Abt, Peutz-Jeghers syndrome: a Clinicopathologic survey of the “Harrisburg family” with a 49-year follow-up, *Gastroenterology* 95 (6) (1988) 1535–1540, [https://doi.org/10.1016/S0016-5085\(88\)80074-X](https://doi.org/10.1016/S0016-5085(88)80074-X).
- [3] Y. Matsumoto, N. Manabe, S. Tanaka, et al., Small-intestinal Peutz-Jeghers polyps resected by endoscopic polypectomy with double-balloon enteroscopy and removal

- confirmed by ultrasonography, *Dig. Dis. Sci.* 51 (12) (2006) 2337–2340, <https://doi.org/10.1007/s10620-006-9381-0>.
- [4] J. Utsunomiya, H. Gocho, T. Miyanaga, E. Hamaguchi, A. Kashimure, Peutz-Jeghers syndrome: its natural course and management, *Johns Hopkins Med. J.* 136 (2) (1975) 71–82.
- [5] I. Alkatout, T. Schollmeyer, N.A. Hawaldar, N. Sharma, L. Mettler, Principles and safety measures of electrosurgery in laparoscopy, *J. Soc. Laparoendosc. Surg.* 16 (1) (2012) 130–139, <https://doi.org/10.4293/108680812X13291597716348>.
- [6] J.J. Koornstra, Small bowel endoscopy in familial adenomatous polyposis and lynch syndrome, *Best Pract. Res. Clin. Gastroenterol.* 26 (3) (2012) 359–368, <https://doi.org/10.1016/j.bpg.2012.01.022>.
- [7] J.J. Koornstra, J.H. Kleibeuker, H.F. Vasen, Small-bowel cancer in Lynch syndrome: is it time for surveillance? *Lancet Oncol.* 9 (9) (2008) 901–905, [https://doi.org/10.1016/S1470-2045\(08\)70232-8](https://doi.org/10.1016/S1470-2045(08)70232-8).
- [8] N. Ohmiya, M. Nakamura, H. Takenaka, et al., Management of small-bowel polyps in Peutz-Jeghers syndrome by using enteroclysis, double-balloon enteroscopy, and videocapsule endoscopy, *Gastrointest. Endosc.* 72 (6) (2010) 1209–1216, <https://doi.org/10.1016/j.gie.2010.08.018>.
- [9] F. Torroni, Conservative approach in Peutz-Jeghers syndrome: single-balloon enteroscopy and small bowel polypectomy, *World J. Gastrointest. Endosc.* 6 (7) (2014) 318, <https://doi.org/10.4253/wjge.v6.i7.318>.
- [10] M. Sulbaran, E. de Moura, W. Bernardo, et al., Overtube-assisted enteroscopy and capsule endoscopy for the diagnosis of small-bowel polyps and tumors: a systematic review and meta-analysis, *Endosc. Int. Open* 04 (02) (2016) E151–E163, <https://doi.org/10.1055/s-0041-108261>.
- [11] G. Rahmi, Small bowel polypectomy by double balloon enteroscopy: correlation with prior capsule endoscopy, *World J. Gastrointest. Endosc.* 5 (5) (2013) 219, <https://doi.org/10.4253/wjge.v5.i5.219>.
- [12] H. Gao, M.G. van Lier, J.W. Poley, E.J. Kuipers, M.E. van Leerdam, P.B. Mensink, Endoscopic therapy of small-bowel polyps by double-balloon enteroscopy in patients with Peutz-Jeghers syndrome, *Gastrointest. Endosc.* 71 (4) (2010) 768–773, <https://doi.org/10.1016/j.gie.2009.11.005>.
- [13] Y.L. Jiang, Z.Y. Zhao, B.R. Li, et al., Early screening the small bowel is key to protect Peutz-Jeghers syndrome patients from surgery: a novel mutation c.243delG in STK11 gene, *BMC Gastroenterol.* 19 (1) (2019), <https://doi.org/10.1186/s12876-019-0987-z>.
- [14] R.A. de Latour, S.M. Kilaru, S.A. Gross, Management of small bowel polyps: a literature review, *Best Pract. Res. Clin. Gastroenterol.* 31 (4) (2017) 401–408, <https://doi.org/10.1016/j.bpg.2017.06.003>.
- [15] F. Li, N. Mehta, D. Liska, et al., Combined endoscopic and surgical management of small-bowel polyposis in a patient with Peutz-Jeghers syndrome, *Endoscopy* (2019), <https://doi.org/10.1055/a-1011-4122>. September.
- [16] H.J. Schulz, H. Schmidt, Intraoperative Enteroscopy, *Gastrointest. Endosc. Clin. N. Am.* 19 (3) (2009) 371–379, <https://doi.org/10.1016/j.giec.2009.04.011>.
- [17] B.J. Dunkin, C.D. Lyons, Electrosurgical energy in gastrointestinal endoscopy, in: *The SAGES Manual on the Fundamental Use of Surgical Energy (FUSE)*, Springer New York, 2012, pp. 107–121, https://doi.org/10.1007/978-1-4614-2074-3_6.
- [18] R.A. Agha, C. Sohrabi, G. Mathew, T. Franchi, A. Kerwan, N. O'Neill, for the PROCESS Group, The PROCESS 2020 guideline: updating consensus Preferred Reporting Of CasE Series in Surgery (PROCESS) guidelines, *Int. J. Surg.* 84 (2020) 231–235.