




Since January 2020 Elsevier has created a COVID-19 resource centre with free information in English and Mandarin on the novel coronavirus COVID-19. The COVID-19 resource centre is hosted on Elsevier Connect, the company's public news and information website.

Elsevier hereby grants permission to make all its COVID-19-related research that is available on the COVID-19 resource centre - including this research content - immediately available in PubMed Central and other publicly funded repositories, such as the WHO COVID database with rights for unrestricted research re-use and analyses in any form or by any means with acknowledgement of the original source. These permissions are granted for free by Elsevier for as long as the COVID-19 resource centre remains active.



## Management of acute aortoiliac arterial thrombosis in patients with the novel coronavirus disease 2019: A case series and systematic review of the literature



Steven Tohmasi, Nii-Kabu Kabutey, Shelley Maitheh, Samuel L. Chen, Isabella J. Kuo, Carlos E. Donayre, Roy M. Fujitani, Anthony H. Chau\*

University of California, Irvine Medical Center, Division of Vascular and Endovascular Surgery, Department of Surgery, Orange, CA, United States

### ARTICLE INFO

#### Keywords:

Aortic thrombus  
Corona virus  
COVID  
Limb ischemia  
Thromboembolism  
Aortoiliac  
Iliac thrombus

### ABSTRACT

**Objectives:** Venous thrombosis has been widely described in the setting of severe acute respiratory syndrome coronavirus 2 (SARS-CoV-2) infection; however, arterial thrombosis has rarely been reported. This study aims to assess the incidence, risk factors, interventions, and outcomes of acute aortoiliac arterial thrombosis in patients with active SARS-CoV-2 infections.

**Methods:** We present seven SARS-CoV-2-positive patients from our institution who acutely developed thrombi in the aortoiliac arterial system (7/2020-1/2021). A systematic review of the literature on aortoiliac arterial thrombosis in patients with SARS-CoV-2 infections in accordance with the Preferred Reporting Items for Systematic Reviews and Meta-Analyses guidelines was also performed. The available data from all reported cases in the literature and at our institution were analyzed.

**Results:** Thirty published articles and journal correspondences, including 52 patients, were reviewed and analyzed in addition to our institution's 7 cases. In total, 59 SARS-CoV-2-positive patients were found to have acute aortoiliac thrombosis. The abdominal aorta was the most frequent location for the development of a thrombus. Baseline demographics and medical comorbidities were not significantly different between the symptomatic and asymptomatic cohorts. Seventy-one percent of patients were symptomatic (lower limb ischemia: 75.0%, renal infarction: 20.0%, stroke: 12.5%, mesenteric ischemia: 10.0%). All patients with thrombus involving the ascending aorta, aortic bifurcation, or iliac artery developed thromboembolic or ischemic complications. All patients received systemic anticoagulation. Fifty-three percent of all patients were managed medically. Ninety-four percent of the asymptomatic patients were managed medically. One asymptomatic patient underwent endovascular aspiration of a mobile thrombus. Three (23.1%) deaths occurred in the asymptomatic cohort from hypoxic respiratory failure. Fourteen (36.8%) deaths occurred in the symptomatic cohort. The in-hospital mortality rate was 33.3% overall and 43.8% for patients with thrombi involving more than one aortoiliac segment.

**Conclusions:** The presence of thrombi in the aortoiliac arterial system appears to be a poor prognostic indicator for patients with active SARS-CoV-2 infections. Medical management of patients with asymptomatic aortoiliac thrombi may be considered. The presence of thrombi involving the ascending aorta, aortic bifurcation, or iliac artery may warrant consideration for operative intervention due to the risk for thromboembolic or ischemic complications. Further study is needed to fully delineate the risk factors, optimal treatment, and outcomes of arterial thrombosis in the setting of SARS-CoV-2 infection.

### Introduction

As of September 2021, there were approximately 44 million cases of coronavirus disease-2019 (COVID-19) with nearly 700,000 deaths in the United States alone [1]. While national masking and vaccination efforts have aided in slowing the effects of the pandemic, there continues to

be a surge in case numbers due to variants of severe acute respiratory syndrome coronavirus 2 (SARS-CoV-2). It is well-known that COVID-19 can be asymptomatic or lead to severe systemic disease characterized by hypoxemic respiratory failure, shock, and multi-organ system failure requiring mechanical ventilation and prolonged hospitalization.

There has been substantial evidence for hypercoagulability, venous thrombosis, and venous thromboembolism in COVID-19 [2-11]. How-

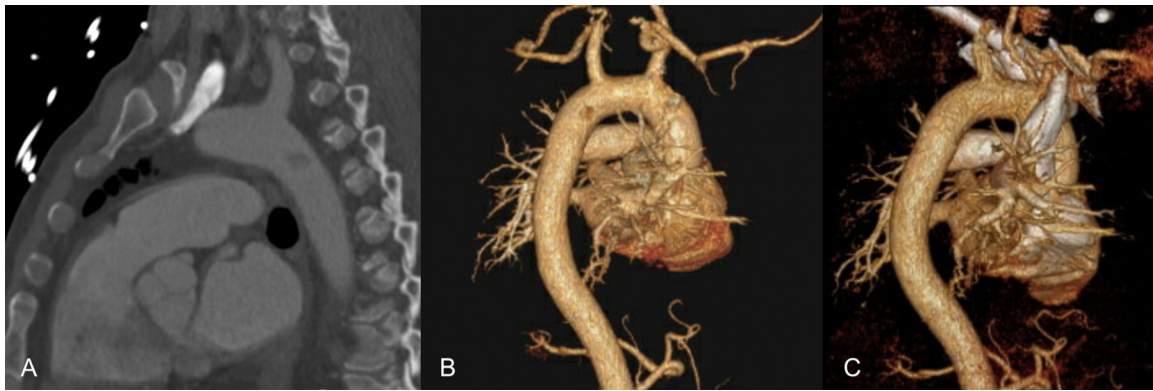
\* Corresponding author at: University of California, Irvine Medical Center, Division of Vascular and Endovascular Surgery, Department of Surgery, 3800 Chapman Avenue, Suite 6200, Orange, CA 92868, United States.

E-mail address: [achau11@hs.uci.edu](mailto:achau11@hs.uci.edu) (A.H. Chau).

<https://doi.org/10.1016/j.avsurg.2022.100105>

Received 7 June 2022; Received in revised form 27 June 2022; Accepted 30 June 2022

2772-6878/© 2022 The Author(s). Published by Elsevier Inc. This is an open access article under the CC BY license (<http://creativecommons.org/licenses/by/4.0/>)



**Fig. 1.** (A) Computed tomography angiography (CTA) demonstrating a mobile mural thrombus in the proximal descending thoracic aorta, just below the left subclavian artery takeoff. (B) CTA with three-dimensional vascular reconstruction re-demonstrating the thrombus location. (C) CTA with three-dimensional vascular reconstruction following percutaneous aspiration thrombectomy of the thrombus demonstrating no evidence of any residual thrombus.

ever, arterial thrombosis and thromboembolism are rarely reported in the literature on COVID-19. In this report, we therefore present seven SARS-CoV-2-positive patients who presented to our institution from July 2020 to January 2021 with acute thrombosis of the aortoiliac arterial system and discuss their management. We also conduct a systematic review of the early literature to assess and consolidate the available data on the incidence, risk factors, anatomical distribution, interventions, and outcomes of acute aortoiliac arterial thrombosis in patients with COVID-19.

### Case Series

#### Case One

A 61-year-old male with history of hypertension (HTN) and tobacco usage presented to the emergency department (ED) with shortness of breath and tested positive for COVID-19. Computed tomography angiography (CTA) revealed extensive ground glass opacities with diffuse patchy consolidations and a 1.4 cm mobile mural thrombus in the proximal descending thoracic aorta, (Fig. 1A and B). The patient was started on a therapeutic dose of enoxaparin and admitted to the intensive care unit. Given the mobile nature of the aortic thrombus, percutaneous aspiration thrombectomy was performed using the AngioVac (AngioDynamics, Latham, New York) system. CTA performed four days later revealed no evidence of any residual thrombus or filling defect in the aorta (Fig. 1C). During the remainder of the patient's hospital course, he continued to have dyspnea with exertion and poor exercise tolerance. At the time of discharge, the patient was started on a three-month course of apixaban for his thrombotic event. At one-month follow-up, the patient was recovering well with markedly improved respiratory function and chest X-ray findings.

#### Case Two

An 81-year-old male with history of coronary artery disease (CAD), peripheral arterial disease (PAD), diabetes mellitus (DM), and HTN presented with altered mental status, shortness of breath, and bilateral lower extremity claudication and weakness. Rapid nasopharyngeal testing was positive for SARS-CoV-2 infection. Prior to presentation, the patient was taking aspirin, clopidogrel and rivaroxaban as prescribed by his cardiologist. In the ED, the patient had undetectable pedal Doppler signals on the right. CTA revealed occlusion of the right common, internal and external iliac arteries, with distal reconstitution at the level of the common femoral artery (CFA). There was also occlusion of the right anterior tibial (ATA) and dorsalis pedis (DPA) arteries. On the left, the external iliac artery (EIA) was occluded and reconstituted at the level

of the CFA (Fig. 2). Distally, the left posterior tibial artery (PTA) was occluded. The patient was admitted to the hospital and started on therapeutic heparin. The etiology of his thrombotic condition was considered to be SARS-CoV-2-related thrombophilia. The patient underwent surgical revascularization with right aortoiliac embolectomy, right superficial femoral artery (SFA) embolectomy, and right CFA angioplasty. Following the completion of the case, the patient's ankle-brachial index improved from undetectable prior to surgery to 0.5 on the right. He was discharged four days later with instructions to continue his home doses of aspirin, clopidogrel, and rivaroxaban. The patient was seen in clinic one month later at which time his lower extremity symptoms had improved.

#### Case Three

A 67-year-old male with history of DM, HTN, and CAD was admitted to the hospital from a correctional facility for shortness of breath and left lower extremity pain. He was found to be positive for COVID-19 with multifocal pneumonitis. He also had a pulseless left leg with rest pain and paresthesias. CTA demonstrated multifocal floating thrombi in his descending thoracic aorta and abdominal aorta, as well as occlusion of the left popliteal artery with contiguous occlusion of the tibioperoneal trunk, PTA, and partial occlusion of the peroneal artery (Fig. 3). He was taken emergently for revascularization of his left leg, with possibility of treating his aortic thrombi if there was evidence of active thromboembolization intraoperatively. He initially underwent an aggressive lower extremity thrombectomy from femoral, popliteal, anterior tibial and dorsalis pedis cutdowns with resultant pulsatile flow restored to the left foot. However, in the postoperative period, he re-occluded the distal ATA and DPA. He then returned to the operating room for endovascular stent-graft exclusion of his thoracic and infrarenal aortic thrombi as well as redo left ATA thromboembolectomy. He again had flow restored to his foot postoperatively; however, in the ensuing days, he developed acute coronary syndrome and pressor-dependent shock. While he recovered with no evidence of coronary thrombosis, the skin and soft tissue in his foot deteriorated significantly and his distal ATA was again noted to be occluded. He once more was taken back to the operating room for ATA thrombectomy resulting in restoration of a Doppler signal in his foot. However, the necrotic tissue at his foot ultimately progressed and given persistent fevers, a guillotine below-knee amputation (BKA) was performed. After medical optimization, he was taken back to the operating room for formal left BKA with closure. The patient was ultimately discharged on therapeutic enoxaparin and later transitioned to apixaban. CTA one month later demonstrated patency of the stent grafts without any evidence of residual thrombus.

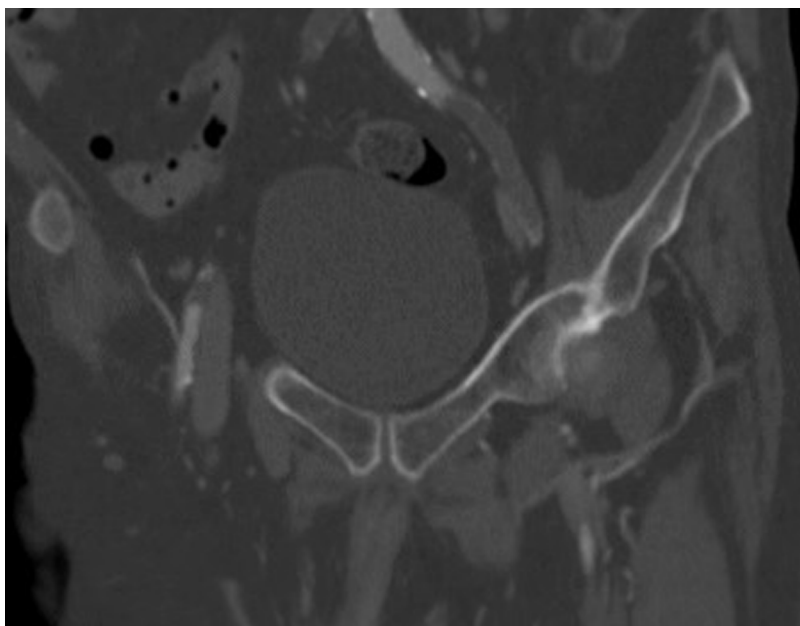


Fig. 2. Computed tomography angiography demonstrating acute occlusion of the left external iliac artery.

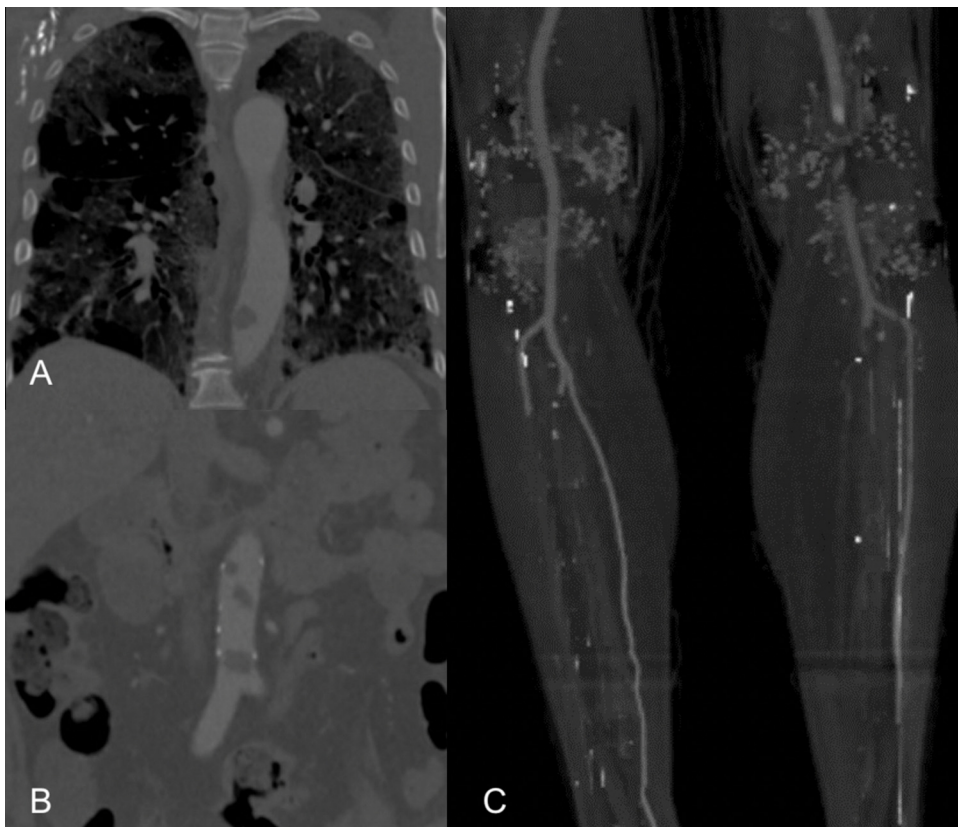


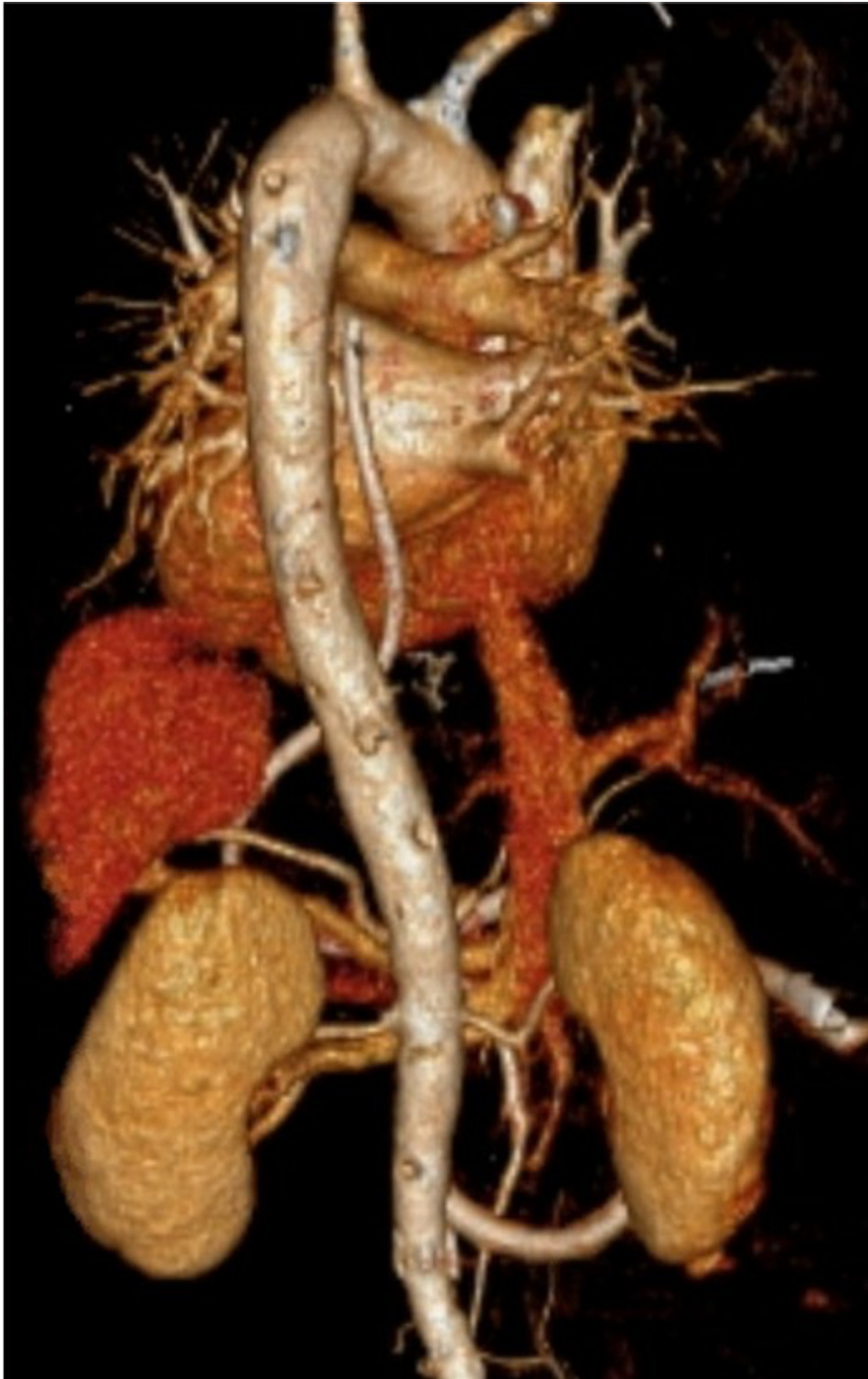Fig. 3. (A and B) Computed tomography angiography (CTA) demonstrating acute multifocal thrombus formation in the descending thoracic and abdominal aorta. (C) CTA demonstrating segmental occlusion of the left popliteal artery, occlusion of the tibioperoneal trunk and posterior tibial artery, as well as partial occlusion of the peroneal artery.

#### Case Four

A 64-year-old male with HTN and CAD was admitted with acute hypoxic respiratory failure from COVID-19 pneumonia. He was intubated and started on dexamethasone and remdesivir. During his hospitalization, he developed an acute non-ST elevation myocardial infarction and was started on therapeutic anticoagulation. The patient was scheduled for cardiac catheterization; however, prior to the procedure, he was noted to have a mottled and cold right lower extremity. The

vascular surgery service was consulted for evaluation of acute limb ischemia. CTA revealed multiple aortic thrombi in the ascending aorta, proximal arch, descending aorta, and infrarenal aorta (Fig. 4). The patient also had complete occlusion of the right popliteal artery with distal reconstitution. There was also complete occlusion of right AT, peroneal and PT arteries with no contrast flow into the foot. The patient was taken to the operating room where Fogarty thromboembolectomies of the right popliteal and posterior tibial arteries were performed with subsequent return of a detectable PTA Doppler signal. Four compart-





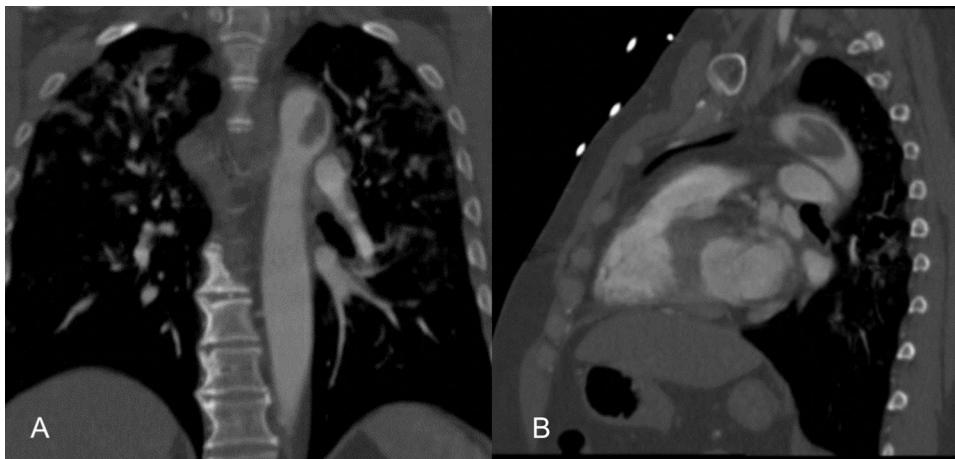
**Fig. 4.** Computed tomography angiography with three-dimensional vascular reconstruction demonstrating multiple aortic thrombi in the ascending aorta, proximal arch, descending aorta, and infrarenal aorta.

ment fasciotomies were also performed. Postoperatively, the patient developed shock requiring hemodynamic support with vasopressors. On postoperative day one, he was found to have new cerebral infarctions. The patient's family decided for comfort care and inpatient hospice. Life support was then removed, and the patient expired.

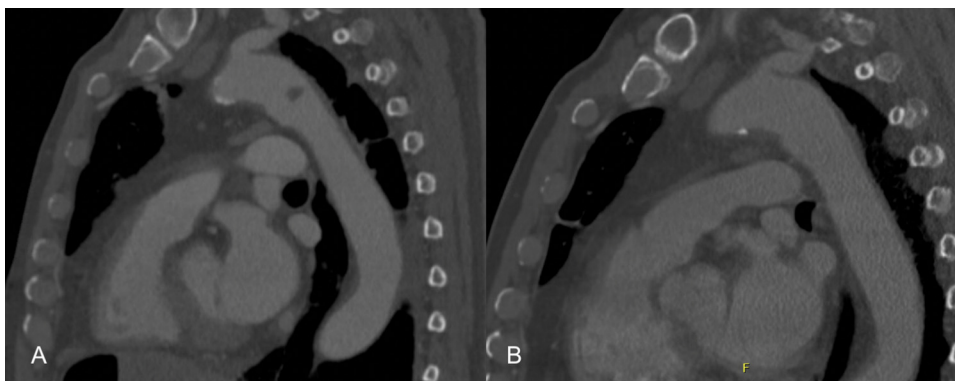
#### Case Five

A 53-year-old male with DM presented with altered mental status and tested positive for SARS-CoV-2 infection. CTA revealed bilateral

patchy ground glass opacities and consolidations in both lungs, consistent with COVID-19 pneumonia, as well as a non-occlusive free-floating mural thrombus in the distal aortic arch without extension into the great vessels (Fig. 5). A CT scan of the brain was also performed and revealed an acute ischemic stroke in the left centrum semiovale. Medical therapy was initiated with aspirin, atorvastatin, and therapeutic heparin. Given the location of the thrombus just distal to the great vessels, it was believed that the small-vessel ischemic event was more likely secondary to a viral-induced hypercoagulable state rather than thromboembolism. Over the subsequent few days, the patient's mental status improved with



**Fig. 5.** Coronal (A) and sagittal (B) views from a computed tomography angiography scan demonstrating a nonocclusive free-floating mural thrombus in the distal aortic arch.



**Fig. 6.** (A) Computed tomography angiography (CTA) revealing a 1.2 cm eccentric thrombus in the proximal descending aorta. (B) CTA performed two months following the initial scan demonstrating interval resolution of the thrombus with anticoagulation therapy.

medical management. Prior to discharge, a CTA was repeated which revealed no interval changes in the location or extent of the thrombus and no evidence of thromboembolization. The patient was transitioned to warfarin prior to discharge with plan to continue for anticoagulation therapy for 3 to 6 months. On follow-up, there was no evidence of residual thrombus on imaging 8 months following the initiation of anticoagulation.

#### Case Six

A 76-year-old male with CAD and HTN presented with fevers and dyspnea. Rapid nasopharyngeal testing was positive for SARS-CoV-2 infection. CTA revealed diffuse pulmonary ground glass opacities and a 1.2 cm eccentric thrombus in the proximal descending aorta (Fig. 6A). The patient was admitted for COVID-19 pneumonia and started on dexamethasone and remdesivir. Given the presence of an acute thrombotic event, the patient was initiated on systemic anticoagulation. CTA was repeated 3 days later and revealed no interval changes in the location or extent of the thrombus. As the patient remained asymptomatic, he was treated with anticoagulation therapy alone. He was transitioned to therapeutic enoxaparin to be continued as an outpatient for a duration for 3 months. The patient was seen in our outpatient clinic two months later at which time his respiratory status and oxygen requirement had improved. CTA at that time revealed interval resolution of the aortic thrombus (Fig. 6B).

#### Case Seven

A 55-year-old male who was diagnosed with COVID-19 pneumonia 3 weeks prior presented with paresthesias and mild pain in his right toes. He had been started on outpatient apixaban following his recent

hospitalization due to concern for SARS-CoV-2-related hypercoagulability. The patient reported that his symptoms started three weeks prior to his hospitalization for COVID-19. He did not have ischemic rest pain or skin changes on examination and both DPA pulses were palpable. CTA was performed and revealed a non-occlusive thrombus in the infrarenal abdominal aorta along with absence of contrast enhancement at the distal right PTA with some reconstitution at the plantar artery (Fig. 7). There were also bilateral patchy pulmonary opacities consistent with COVID-19 pneumonia. The patient was admitted and started on a therapeutic heparin for his thrombosis. His symptoms in the setting of an infrarenal aortic thrombus were concerning for potential microemboli showering to his digital arteries. In the subsequent days, his pain was well controlled and the numbness of his right toes was stable. The patient was discharged home on aspirin, clopidogrel, and apixaban. At 5-month follow-up, CTA revealed interval decrease in size of the infrarenal aortic thrombus. As such, we recommended continuing anticoagulation and antiplatelet agents for an additional 6 months with repeat CTA and clinic visit at that time.

#### Systematic Review of the Literature

##### Methods

A systematic review of the literature on acute aortoiliac arterial thrombosis in patients with SARS-CoV-2 infections from December 2019 to January 2021 was performed in accordance with the Preferred Reporting Items for Systematic Reviews and Meta-Analyses guidelines (Fig. 8). The Medline (PubMed interface) and Scopus databases were queried to identify studies eligible for inclusion. The electronic search was conducting using the following strategy: (coronavirus OR COVID-19) AND (aorta OR aortic OR aortoiliac OR iliac) AND (thrombus OR thrombosis OR thrombotic OR occlusion). Only articles in the English

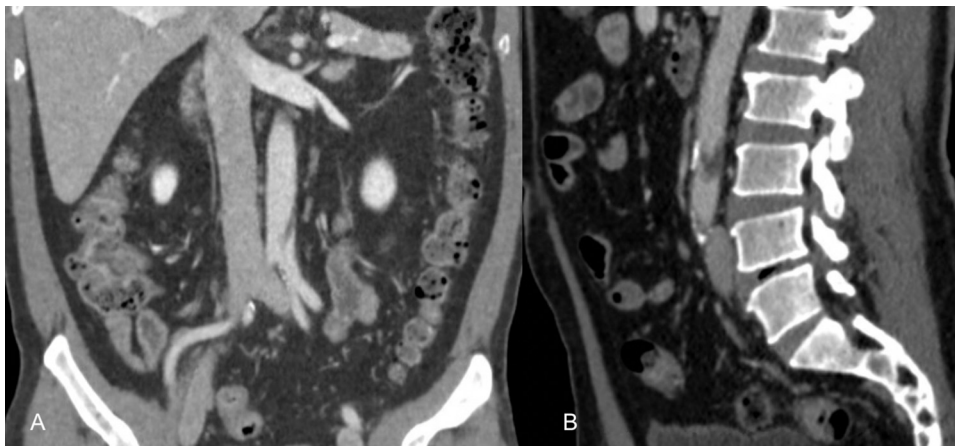


Fig. 7. Coronal (A) and sagittal (B) views from a contrast tomography angiography scan was demonstrating a non-occlusive thrombus in the infrarenal abdominal aorta.

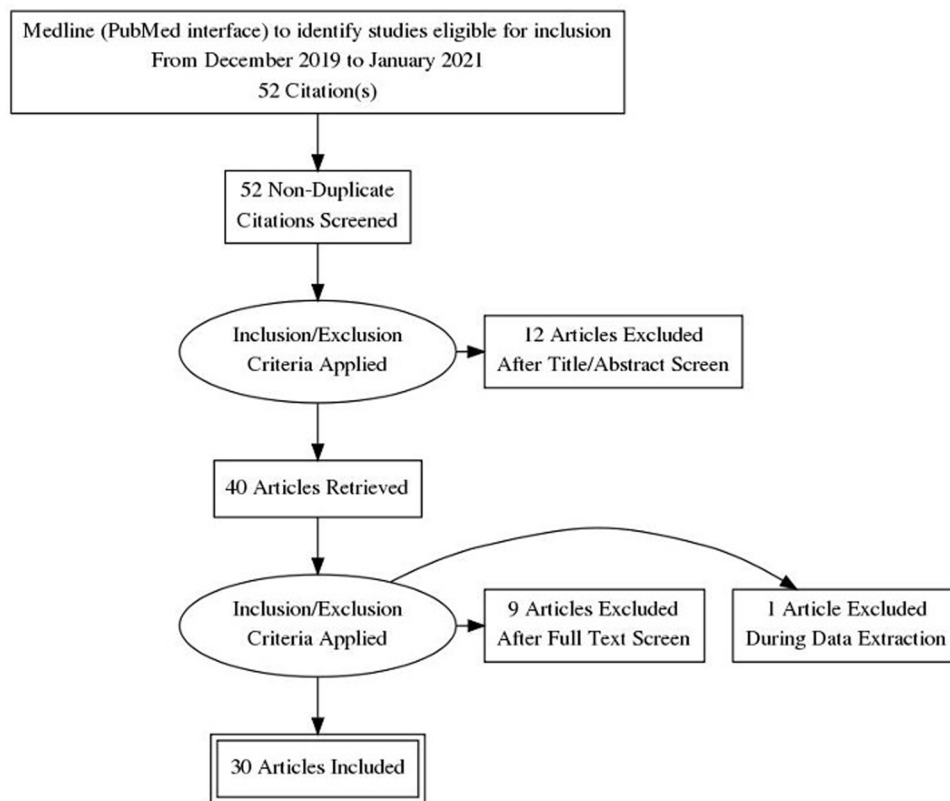


Fig. 8. Preferred Reporting Items for Systematic Reviews and Meta-Analyses Flow Diagram.

language were included. We then reviewed the bibliography of included studies to detect other potentially eligible articles to further extend our search.

The search results were first screened by title and abstract, with those of potential relevance selected for full-text review. Articles were eligible for inclusion if they met the following criteria: (1) were case reports/case series/imaging reports/retrospective studies/letters-to-journal-editors, (2) described patients with a confirmed COVID-19 diagnosis, (3) reported clear extractable data on aortoiliac arterial thrombotic complications. Data extraction was conducted by 2 independent reviewers. For each article, the following information was extracted: the surname of the first author, the type of study, sample size, demographic characteristics, medical comorbidities, anatomical location of the thrombi, other concurrent arterial or venous thrombosis, treatment, and mortality. Any variances arising during the data extraction process were resolved by a consensus among authors. The available data from

all reported cases in the literature and at our institution were extracted, pooled, and analyzed. The authors included imaging reports, letters-to-journal-editors, and concise clinical reports in the analysis due to the paucity of published articles on this topic.

During the analysis, all variables were coded as either present or absent. Descriptive statistics were performed for all variables. A Student t-test was used to compare continuous variables, and Chi-Square analysis was used to compare categorical variables. Categorical data were reported as percentages. All P-values were two-sided, with a statistical significance level of <0.05 selected. All missing data points were not imputed but treated as missing data. All analyses were performed with IBM SPSS Statistics for Windows (version 24, IBM Corp, Armonk, New York).

When sufficient information was available from the article, patients were divided based on the presence or absence of symptoms related to the presence of the aortoiliac thrombosis. Patients were considered



**Table 1**

Age, gender, and medical comorbidities of reported patients with aortoiliac arterial thrombosis in the setting of SARS-CoV-2 infection.

	All Patients	Valid n	Asymptomatic Patients	Valid n	Symptomatic Patients	Valid n	P-Value
Mean Age (Years)	64.2	58	63.7	15	64.2	40	0.87
Male Gender	48 (84.2%)	57	11 (73.3%)	15	34 (87.2%)	39	0.221
Hypertension	32 (60.4%)	53	7 (46.7%)	15	25 (65.8%)	38	0.2
Hyperlipidemia	12 (22.6%)	53	3 (20.0%)	15	9 (23.7%)	38	0.773
Diabetes Mellitus	13 (24.5%)	53	4 (26.7%)	15	9 (23.7%)	38	0.82
Prior Stroke or Transient Ischemic Attack	3 (5.7%)	53	1 (6.7%)	15	2 (5.3%)	38	0.842
Prior or Current Tobacco Use	10 (18.9%)	53	2 (13.3%)	15	8 (21.1%)	38	0.518
Peripheral Arterial Disease	3 (5.7%)	53	0 (0.0%)	15	3 (7.9%)	38	0.263
Coronary Artery Disease	8 (15.1%)	53	1 (6.7%)	15	7 (18.4%)	38	0.282
Atrial Fibrillation	3 (5.7%)	53	0 (0.0%)	15	3 (7.9%)	38	0.263
History of Deep Vein Thrombosis or Pulmonary Emboli	3 (5.7%)	53	0 (0.0%)	15	3 (7.9%)	38	0.263

**Table 2**

Aortoiliac arterial territories affected by acute thrombosis in the setting of SARS-CoV-2 infection.

	All Patients (n=59)	Asymptomatic Patients (n=16)	Symptomatic Patients (n=40)	P-Value
Ascending Aortic Thrombus	5 (8.5%)	0 (0.0%)	5 (12.5%)	0.138
Aortic Arch Thrombus	12 (20.3%)	7 (43.8%)	4 (10.0%)	0.004
Descending Aortic Thrombus	17 (28.8%)	10 (62.5%)	7 (17.5%)	0.001
Abdominal Aortic Thrombus	27 (45.8%)	2 (12.5%)	23 (57.5%)	0.002
Aortic Bifurcation/Iliac Artery Thrombus	20 (33.9%)	0 (0.0%)	20 (50.0%)	0
Concomitant Infrapopliteal Arterial Thrombosis	16 (27.1%)	0 (0.0%)	16 (40.0%)	0.003
Concomitant Infrapopliteal Arterial Thrombosis	13 (22.0%)	0 (0.0%)	13 (32.5%)	0.009

symptomatic if they developed signs of more distal arterial ischemia (ex. lower limb ischemia, renal infarction, and/or acute cerebral ischemia). Cerebral infarction attributed to ascending aorta or aortic arch thrombosis was determined in cases where a thrombus was located prior to the ostium of one of the great vessels.

## Results

The systematic review revealed thirty articles (17 case reports/series, 9 letters-to-journal-editors, 3 brief clinical imaging reports, and 1 retrospective study) detailing 52 SARS-CoV-2-positive patients with acute aortoiliac arterial thrombosis [12-41]. The available information from these cases were compiled and analyzed in addition to our institution's 7 cases. In total, 59 patients were included in the analysis.

The mean age of patients was 64.2 years (range: 33-85) and 84.2% of patients were males. Details regarding medical history was available for 53 (89.8%) of 59 patients, of which 32 (60.4%) had HTN, 12 (22.6%) had hyperlipidemia, 13 (24.5%) had DM, 3 (5.7%) had a prior stroke or transient ischemic attack, 10 (18.9%) had a history of tobacco usage, 3 (5.7%) had PAD, 8 (15.1%) had CAD, 3 (5.7%) had atrial fibrillation, and 3 (5.7%) had prior deep vein thrombosis or venous thromboembolism. As shown in Table 1, there was no significant difference in the age, gender, and medical comorbidities of patients in the symptomatic and asymptomatic cohorts (all  $P > 0.05$ ).

Of the 59 patients analyzed, 5 (8.5%) developed thrombus in the ascending aorta, 12 (20.3%) developed thrombus in the aortic arch, 17 (28.8%) developed thrombus in the descending aorta, 27 (45.8%) developed thrombus in the abdominal aorta, and 20 (34%) developed thrombus at the level of the aortic bifurcation and/or iliac arteries (Table 2). Sixteen (27.1%) patients had concomitant infrainguinal arterial thrombotic occlusions and 13 (22.0%) patients had concomitant infrapopliteal arterial thrombotic occlusions. All patients with concomitant infrainguinal and infrapopliteal occlusions developed signs of limb ischemia. Ten (16.9%) patients had evidence of a pulmonary embolism. Fifty-six (94.9%) patients had information regarding their clinical presentation and were separately analyzed in symptomatic and asymptomatic cohorts. Forty (71.4%) patients were symptomatic from the aortoiliac arterial thrombosis or an associated distal thrombotic occlusion (lower limb ischemia: 75.0%, renal infarction: 20.0%, stroke: 12.5%, mesenteric ischemia: 10.0%). The management strategies uti-

lized are detailed in Table 3. Fifty-three percent of all patients were managed medically. Forty-three percent of patients underwent surgical intervention for management of the aortoiliac arterial thrombus or an associated ischemic/thromboembolic complication. Eleven percent of patients underwent systemic or catheter-directed thrombolysis. All patients received systemic anticoagulation. Ninety-four percent of the asymptomatic patients were managed medically. One asymptomatic patient (Case 1) underwent endovascular aspiration of a mobile thrombus. The overall in-hospital mortality rate was 33.3%. The in-hospital mortality rate was 23.1% in the asymptomatic cohort (all from hypoxic respiratory failure) and 36.8% in the symptomatic cohort ( $P = 0.363$ ). The in-hospital mortality rate was 43.8% for patients with thrombi involving more than one aortoiliac segment.

### Ascending Aorta Cohort

Four (80.0%) of the five patients with thrombi involving the ascending aorta developed cerebral infarction attributed to arterial thromboembolism. While all patients with ascending aortic thrombi were symptomatic in this population, there was a lack of significance when compared with the asymptomatic group ( $P = 0.138$ ). Four (80%) patients were managed medically, and all patients received systemic anticoagulation. One (20%) patient with multifocal aortic thrombi required lower extremity arterial thromboembolism (Case 4). Two (40.0%) of patients in this group expired during their hospitalization.

### Aortic Arch Cohort

Sixty-four percent (7/11) of patients with thrombus in the aortic arch were asymptomatic, while 36% (4/11) were symptomatic. Two (18%) patients developed limb ischemia, two (18%) patients developed mesenteric or renal ischemia, and two (18%) patients developed cerebral infarction. Three (27%) symptomatic patients underwent an operation for thromboembolic disease resulting in limb or mesenteric ischemia. Of the 9 patients with mortality information available, 4 (44%) expired during their hospitalization. Of the patients who survived the index hospitalization and had follow-up information available (n=5), the thrombus had either reduced in size or resolved at the time of last follow-up in 4 (80%) patients with the use of systemic anticoagulation.

### Descending Aorta Cohort

10 (58.9%) patients with thrombus in the descending aorta were asymptomatic, while 7 (41.1%) were symptomatic. Of the 7 patients



**Table 3**  
Reported management strategies and in-hospital mortality for SARS-CoV-2-positive patients with acute aortoiliac arterial thrombosis.

	All Patients	Valid n	Asymptomatic Patients	Valid n	Symptomatic Patients	Valid n	P-Value
Managed Medically	29 (52.7%)	55	15 (93.8%)	16	14 (35.9%)	39	0
Received Systemic Anticoagulation	43 (100%)	43	14 (100%)	14	29 (100%)	29	-
Required an Operation	24 (42.9%)	56	1 (6.3%)	16	23 (57.5%)	40	0
Open Surgery	22 (91.7%)	24	0 (0.0%)	1	22 (95.7%)	23	-
Endovascular Therapy	5 (20.8%)	24	1 (100.0%)	1	4 (17.4%)	23	-
Received Thrombolytic Agents	6 (10.9%)	55	1 (6.3%)	16	5 (12.8%)	39	0.478
In-Hospital Mortality	17 (33.3%)	51	3 (23.1%)	13	14 (36.8%)	38	0.363

who developed thromboembolic or ischemic symptoms attributed to the thrombus, 2 developed mesenteric ischemia, 2 developed cerebral infarctions, 2 developed renal infarction, and 4 developed lower limb ischemia. Four patients in this cohort required surgical intervention, one of which was for asymptomatic disease (Case 1: aspiration thrombectomy of a mobile thrombus), and 1 patient required catheter-directed thrombolysis with subsequent ischemic small bowel resection for an embolic superior mesenteric artery occlusion. Twelve (70.1%) patients were managed with anticoagulation alone. Of the 14 patients with outcome information available, 3 (21.4%) patients expired during their hospitalization secondary to severe pneumonia and/or multiple end-organ damage.

#### Abdominal Aorta Cohort

23 (92.0%) patients with thrombus in the abdominal aorta developed symptoms, while 2 (8.0%) were asymptomatic ( $P = 0.002$ ). Twenty of the 23 symptomatic patients developed lower limb ischemia, while the other 3 cases developed renal infarction. Of these 20 patients, 12 had concomitant iliac artery thrombosis, 9 had associated concomitant infrainguinal arterial occlusions, and 8 had infrapopliteal arterial occlusions. Seventeen (68.0%) patients in this group underwent an operation to either treat the primary thrombus or an associated ischemic/thromboembolic complication. Fifteen patients underwent surgical thrombectomy, 2 patients underwent percutaneous stent-graft exclusion of thrombus, and 2 patients required axillobifemoral bypass construction. Of the 17 patients who underwent an operation, 7 (41.2%) expired during their hospitalization.

#### Aortic Bifurcation/Iliac Artery Cohort

All patients ( $n=20$ ) with a thrombus at the level of the aortic bifurcation and/or iliac artery developed acute lower limb ischemia. All patients received systemic anticoagulation and 15 patients underwent surgical treatment of the primary thrombus or an associated ischemic/thromboembolic complication. Thirteen patients underwent surgical thrombectomy, 2 patients underwent axillobifemoral bypass, and 1 patient underwent successful catheter-directed thrombolysis. The 4 patients who were managed medically all expired from severe systemic disease due to COVID-19 requiring vasopressor support. Four (21.1%) patients expired following an operation during their hospitalization, with only one dying from a major hemorrhage.

#### Discussion

This institutional case series and systematic review demonstrates that acute aortoiliac arterial thrombosis is a potentially fatal complication of SARS-CoV-2 infection. From our analysis, it appears that this complication primarily affects middle-aged males. Most patients in this analysis had a history of HTN, which is a known risk factor for vascular inflammation. However, statistical analysis failed to identify any comorbid conditions as a significant risk factor for developing symptomatic arterial thrombosis. Our analysis showed that the abdominal aorta was the most frequently reported location of thrombus formation. The overall in-hospital mortality rate was 33.3% and was even higher (43.8%) for patients with thrombi involving more than one aortoiliac segment,

suggesting that the presence of thrombi in the aortoiliac arterial system appears to be a poor prognostic indicator for patients with COVID-19.

The full mechanism of arterial thrombosis in COVID-19 remains unclear. Ackermann et al. conducted lung autopsies from patients who died from COVID-19 and found signs of severe endothelial injury associated with the presence of intracellular virus and disrupted cell membranes [42]. Histologic analysis of the pulmonary vessels showed widespread thrombosis with microangiopathy and perivascular T-cell infiltration [42]. Also of note, prior studies have shown that COVID-19 can cause derangements in coagulation parameters in critically ill patients including elevated D-dimer and fibrinogen levels, increased Factor VIII activity, low normal functional protein C activity, and increased von Willebrand factor activity [43-48]. Antiphospholipid antibodies can also occur in patients with COVID-19 [49-50]. These factors may play a role in COVID-19 associated hypercoagulability and the development of acute arterial thrombosis. In our institutional case series, no patient had a history of any inherited or acquired prothrombotic conditions outside of the viral-induced hypercoagulable state caused by SARS-CoV-2 infection.

Optimal anticoagulant dosing to reduce thrombosis in patients with COVID-19 has been investigated. It is generally accepted that all hospitalized adults with COVID-19 should receive pharmacologic thromboprophylaxis, unless there is a significant risk of bleeding present. Per the NIH COVID-19 Treatment Guidelines Panel, the use of anticoagulants for routine prevention of venous or arterial thrombosis in non-hospitalized patients with COVID-19 is not recommended [51]. For hospitalized, non-pregnant adults without evidence of venous thromboembolism, the Panel recommends against using anticoagulants to prevent arterial thrombosis outside of the usual standard of care for patients without COVID-19 [51]. The Panel also recommends against routinely continuing thromboprophylaxis for patients with COVID-19 after hospital discharge [51].

Patients with COVID-19 are typically evaluated using CT scans focused on the lungs. However, incidental findings of aortic thrombus warrant further investigation and treatment. In patients with signs of limb ischemia who test positive for COVID-19, we recommend that thoracoabdominal CTA be performed to evaluate for an aortoiliac thrombus as a potential embolic source. All patients who are diagnosed with an aortoiliac arterial thrombus should be started on systemic anticoagulation to prevent further thrombus propagation and reduce the risk for thromboembolism.

In our analysis, all but one asymptomatic patient was managed medically. One patient underwent endovascular aspiration of a mobile thrombus due to concern for a possible future embolic complication. As there were no cases of thrombosis-associated mortality in the asymptomatic cohort, medical management of patients with isolated asymptomatic aortoiliac arterial thrombi should be considered.

Patients who were symptomatic from their aortoiliac arterial thrombosis were most likely to develop limb ischemia. The majority (57.5%) of symptomatic patients required surgical intervention to either remove the primary thrombus or treat an associated ischemic/thromboembolic complication. It appears that those individuals who needed an operation were primarily those who developed lower limb ischemia in the setting of aortic bifurcation or iliac thrombi either by itself or associated with more proximal aortic thrombi. As such, this data suggests that lower

extremity ischemia is the most common etiology for intervening in patients with aortoiliac thrombi.

In our study population, all patients with thrombus involving the ascending aorta, aortic bifurcation, or iliac artery developed thromboembolic or ischemic complications. As such, thrombosis of these aortoiliac territories may warrant consideration for operative intervention to reduce the risk thromboembolic or ischemic events. Revascularization to treat acute limb ischemia due to thrombotic occlusion should be based on overall patient clinical status and survivability from their SARS-CoV-2 infection.

A major limitation of this study is that the data relies on a small number of articles, primarily single-institution case reports/series and journal correspondences. There is also inherent selection and publication bias among published reports, as many asymptomatic and uneventful cases may have gone unreported in the literature. Larger, well-designed prospective or retrospective studies are critically needed to confirm these findings and fully delineate the risk factors, optimal treatment, and outcomes of arterial thrombosis in the setting of SARS-CoV-2 infection.

Many questions remain unanswered regarding COVID-associated aortoiliac arterial thrombosis. Further research is required to better elucidate the arterial thrombotic mechanism, the ideal type and duration of anticoagulation therapy, and the indications for medical and surgical management of these thromboses. Investigation efforts should also focus on obtaining vascular biopsies at the time of surgery in these patients to identify potential biomarkers that may be associated endothelial activation/dysfunction. Due to the relatively low number of reported cases at our institution and in the published literature, it is difficult to definitively assert any correlation exists between the severity of COVID-19 infection and the development of arterial thrombosis. Additional studies using a prospective database should be conducted to evaluate whether the following factors increase risk for arterial thrombosis in patients with COVID-19: presence of consolidations on chest radiographs, leukocyte count, hemoglobin, lactate dehydrogenase, C-reactive protein, D-dimer, procalcitonin, need for hospital admission, need for high-flow oxygenation or ventilation, and need for intensive care unit stay. Furthermore, our early institutional series details seven patients who presented to our institution between July 2020 and late January 2021. As such, none of the seven reported patients had completed a full COVID-19 vaccination series. Additional research efforts should focus on the effects of vaccination on arterial and venous thrombosis in patients with COVID-19.

### Conclusion

Lower extremity ischemia is the most common etiology for intervening on patients with aortoiliac arterial thrombi. The presence of thrombi in the aortoiliac system appears to be a poor prognostic indicator for patients with COVID-19. Medical management of patients with isolated asymptomatic aortoiliac thrombi may be considered. The presence of thrombi involving the ascending aorta, aortic bifurcation, or iliac artery may warrant consideration for operative intervention due to the risk for thromboembolic or ischemic complications. Further study is needed to fully delineate the risk factors, optimal treatment, and outcomes of arterial thrombosis in patients with COVID-19.

### Statement of Authenticity

This manuscript has not been previously published or submitted elsewhere for publication. It will not be sent to another journal until a decision is made concerning publication by the *Annals of Vascular Surgery*.

### Meeting Presentations

This paper was presented during the Interactive Poster Session at the 2021 *Vascular Annual Meeting* in San Diego, California and during

Scientific Session III at the 36th *Western Vascular Society Annual Meeting* in Jackson Hole, Wyoming.

### Author Contributions

All authors made a substantial contribution to this work. ST, NKK, and AHC were involved in project conceptualization, data curation, formal analysis, manuscript composition, and review. ST and SM performed the data analysis. CED, IJK, and RMF were involved in the critical review of the manuscript for important intellectual content.

### Declaration of Competing Interest

The authors do not have any relevant conflicts of interest or sources of outside support to declare.

### References

1. COVID Data Tracker. *Centers for Disease Control and Prevention*; 2021 Retrieved from <https://covid.cdc.gov/covid-data-tracker/#data-tracker-home> Accessed on Sept 04.
2. Poissy J, Goutay J, Caplan M, et al. Pulmonary embolism in COVID-19 patients: awareness of an increased prevalence. *Circulation*. 2020;142:184–186.
3. Nahum J, Morichau-Beauchant T, Daviaud F, Echegut P, Fichet J, Maillat JM, Thierry S. Venous thrombosis among critically ill patients with coronavirus disease 2019 (COVID-19). *JAMA Network Open*. 2020;3(5):e2010478.
4. Middeldorp S, Coppens M, van Haaps TF, Foppen M, Vlaar AP, Muller MCA, Bouman CCS, Beenen LFM, Kootte RS, Heijmans J, et al. Incidence of venous thromboembolism in hospitalized patients with COVID-19. *J Thromb Haemost*. 2020;18:1995–2002.
5. Maatman TK, Jalali F, Feizpour C, Douglas 2nd A, McGuire SP, Kinnaman G, Hartwell JL, Maatman BT, Kreutz RP, Kapoor R, et al. Routine venous thromboembolism prophylaxis may be inadequate in the hypercoagulable state of severe coronavirus disease 2019. *Crit Care Med*. 2020;48:e783–e790.
6. Lodigiani C, Iapichino G, Carenzo L, Cecconi M, Ferrazzi P, Sebastian T, Kucher N, Studd JD, Sacco C, Alexia B, et al. Venous and arterial thromboembolic complications in COVID-19 patients admitted to an academic hospital in Milan, Italy. *Thromb Res*. 2020;191:9–14.
7. Llitjos JF, Leclerc M, Chochois C, Monsallier JM, Ramakers M, Auvray M, Merouani K. High incidence of venous thromboembolic events in anticoagulated severe COVID-19 patients. *J Thromb Haemost*. 2020;18:1743–1746.
8. Klok FA, Kruijff M, van der Meer NJM, Arbous MS, Gommers D, Kant KM, Kaptein FHJ, van Paassen J, Stals MAM, Huisman MV, et al. Incidence of thrombotic complications in critically ill ICU patients with COVID-19. *Thromb Res*. 2020;191:145–147.
9. Desborough MJR, Doyle AJ, Griffiths A, Retter A, Breen KA, Hunt BJ. Image-proven thromboembolism in patients with severe COVID-19 in a tertiary critical care unit in the United Kingdom. *Thromb Res*. 2020;193:1–4.
10. Bompard F, Monnier H, Saab I, Tordjman M, Abdoul H, Fournier L, Sanchez O, Lorut C, Chassagnon G, Revel MP. Pulmonary embolism in patients with Covid-19 pneumonia. *Eur Respir J*. 2020;56:2001365.
11. Artifoni M, Danic G, Gautier G, Gicquel P, Boutoille D, Raffi F, Neel A, Lecomte R. Systematic assessment of venous thromboembolism in COVID-19 patients receiving thromboprophylaxis: incidence and role of D-dimer as predictive factors. *J Thromb Thrombolysis*. 2020;50(1):211–216.
12. Le Berre A, Marteau V, Emmerich J, Zins M. Concomitant acute aortic thrombosis and pulmonary embolism complicating COVID-19 pneumonia. *Diagnost Intervent Imag*. 2020;101(5):321 May.
13. Kashi M, Jacquin A, Dakhil B, et al. Severe arterial thrombosis associated with Covid-19 infection. *Thromb Res*. 2020;192:75 Aug.
14. Gandotra P, Supariwala A, Selim S, Garra G, Gruberg L. Aortic Arch Thrombus and Pulmonary Embolism in a COVID-19 Patient. *J Emerg Med*. 2020 Aug 4.
15. Azouz E, Yang S, Monnier-Cholley L, Arrivé L. Systemic arterial thrombosis and acute mesenteric ischemia in a patient with COVID-19. *Intensive Care Med*. 2020;46:1464–1465 Jul.
16. Mukherjee A, Ghosh R, Furment MM. Case report: COVID-19 associated renal infarction and ascending aortic thrombosis. *Am J Trop Med Hyg*. 2020;103(5):1989–1992 Nov 4.
17. Gomez-Arbelaiz D, Ibarra-Sanchez G, Garcia-Gutierrez A, Comanges-Yeboles A, Ansuategui-Vicente M, Gonzalez-Fajardo JA. COVID-19-related aortic thrombosis: a report of four cases. *Ann Vasc Surg*. 2020;67:10–13 Aug 1.
18. Vulliamy P, Jacob S, Davenport RA. Acute aorto-iliac and mesenteric arterial thromboses as presenting features of COVID-19. *Br J Haematol*. 2020;189(6):1053–1054 Jun.
19. Singh G, Attique HB, Gadela NV, Mapara K, Manickaratnam S. COVID-19 related arterial coagulopathy. *Cureus*. 2020;12(7) Jul.
20. Masana M, Martinez LI, Gil M, Bueno G, Llagostera S. Thoracic aortic mural thrombus, right ventricular clot and pulmonary embolism in a patient with COVID-19 pneumonia. *Vasc Endovascular Surg*. 2020:1538574420966106 Oct 9.
21. Mui LW, Lau JF, Lee HK. Thromboembolic complications of COVID-19. *Emerg Radiol*. 2020;1–7 Nov 7.
22. Roncati L, Manenti A, Manco G, Farinetti A. Abdominal aortic thrombosis complicating COVID-19 pneumonia. *Ann Vasc Surg*. 2020 Aug 1.

23. de Roquetaillade C, Chousterman BG, Tomasoni D, et al. Unusual arterial thrombotic events in Covid-19 patients. *Int J Cardiol.* 2021;323:281–284 Jan 15.
24. Perini P, Nabulsi B, Massoni CB, Azzarone M, Freyrie A. Acute limb ischaemia in two young, non-atherosclerotic patients with COVID-19. *Lancet North Am Ed.* 2020;395(10236):1546 May 16.
25. Mosbahi S, Heinisch PP, Schoenhoff FS, Berger DC. COVID-19-associated aortic arch thrombus. *Eur J Cardio-thorac Surg.* 2020 Oct 1.
26. Baeza C, González A, Torres P, Pizzamiglio M, Arribas A, Aparicio C. Acute aortic thrombosis in COVID-19. *J Vasc Surg Case Innovat Tech.* 2020;6(3):483–486 Sep 1.
27. Coscas R, Coggia M. Acute Aortic Thrombosis Revealing a COVID-19 Infection. *Eur J Vasc Endovasc Surg.* 2020 Jul 7.
28. de Carranza M, Salazar DE, Troya J, et al. Aortic thrombus in patients with severe COVID-19: review of three cases. *J Thromb Thrombolysis.* 2020;1–6 Jul 9.
29. Mullan C, Powierza C, Miller PE, Geirsson A, Vallabhajosyula P, Assi R. Spontaneous coronavirus disease 2019 (COVID-19)-associated luminal aortic thrombus. *J Thorac Cardiovasc Surg.* 2020;160(2).
30. Nassabein R, Routy B, Blais N, Ayoub JP, Tehfé M. Arterial thrombosis and coronavirus disease 2019 in a patient with cancer. *Eur J Cancer.* 2020;134:1 Jul.
31. Katchanov J, Kalisch J, Havla M, et al. Extensive aortic thrombosis in a patient with Covid-19. *Ann Emerg Med.* 2020 Sep 1.
32. Lari E, Lari A, AlQinai S, et al. Severe ischemic complications in Covid-19—A case series. *Int J Surg Case Rep.* 2020;75:131–135 Jan 1.
33. Silingardi R, Gennai S, Migliari M, Covic T, Leone N. Acute limb ischemia in COVID-19 patients: Could aortic floating thrombus be the source of embolic complications? *J Vasc Surg.* 2020;72(3):1152–1153 Sep 1.
34. Woehl B, Lawson B, Jambert L, Tusch J, Ghassani A, Hamade A. 4 cases of aortic thrombosis in patients with COVID-19. *Case Reports.* 2020;2(9):1397–1401 Jul 15.
35. Patel P, Yu Y, Zia S, Padberg F, Curi M, Huang J. Systemic Thrombolysis as Initial Treatment of COVID-19 Associated Acute Aortoiliac and Lower Extremity Arterial Thrombosis. *Ann Vasc Surg.* 2021;70:297–301 Jan 1.
36. Naudin I, Long A, Michel C, Devigne B, Millon A, Della-Schiava N. Acute aortoiliac occlusion in a patient with novel coronavirus disease-2019. *J Vasc Surg.* 2021;73(1):18–21 Jan 1.
37. Muhammad K, Tantawy TG, Makar RR, Olojugba O. Successful Catheter-directed thrombolysis for acute lower limb ischemia secondary to COVID-19 infection. *Ann Vasc Surg.* 2020 Nov 3.
38. Wengertter SP, Wengertter KR, Masoudpoor H, et al. Acute aortoiliac and infrainguinal arterial thrombotic events in four patients diagnosed with the novel coronavirus 2019. *J Vasc Surg Case Innovat Tech.* 2020;6(4):698–702 Dec 1.
39. Vacirca A, Faggioli G, Pini R, Teutonico P, Pilato A, Gargiulo M. Unheralded lower limb threatening ischemia in a COVID-19 patient. *Int J Infect Dis.* 2020;96:590–592 Jul 1.
40. David K, Clemence P, Ines H, et al. Multiple arterial thrombosis in a 78-year-old patient: Catastrophic thrombotic syndrome in COVID-19. *CJC Open.* 2020 Oct 2.
41. Borulu F, Erkut B. Severe Aortic Thrombosis in the early period after COVID-19: Two cases. *Ann Vasc Surg.* 2021 Jan 22.
42. Ackermann M, Verleden SE, Kuehnel M, Haverich A, Welte T, Laenger F, Vanstapel A, Werlein C, Stark H, Tzankov A, Li WW, Li VW, Mentzer SJ, Jonigk D. Pulmonary Vascular Endothelialitis, Thrombosis, and Angiogenesis in Covid-19. *N Engl J Med.* 2020;383(2):120–128 Jul 9.
43. Panigada M, Bottino N, Tagliabue P, Grasselli G, Novembrino C, Chantarangkul V, Pesenti A, Peyvandi F, Tripodi A. Hypercoagulability of COVID-19 patients in intensive care unit: A report of thromboelastography findings and other parameters of hemostasis. *J Thromb Haemost.* 2020;18(7):1738–1742 JulEpub 2020 Jun 24. doi:10.1111/jth.14850.
44. Helms J, Tacquard C, Severac F, Leonard-Lorant I, Ohana M, Delabranche X, Merdji H, Clere-Jehl R, Schenck M, Fagot Gandet F, Fafi-Kremer S, Castelain V, Schneider F, Grunebaum L, Anglés-Cano E, Sattler L, Mertes PM, Meziani FCIRCS TRIGGERSEP Group (Clinical Research in Intensive Care and Sepsis Trial Group for Global Evaluation and Research in Sepsis). High risk of thrombosis in patients with severe SARS-CoV-2 infection: a multicenter prospective cohort study. *Intensive Care Med.* 2020;46(6):1089–1098 JunEpub 2020 May 4. doi:10.1007/s00134-020-06062-x.
45. Han H, Yang L, Liu R, Liu F, Wu KL, Li J, Liu XH, Zhu CL. Prominent changes in blood coagulation of patients with SARS-CoV-2 infection. *Clin Chem Lab Med.* 2020;58(7):1116–1120 Jun 25.
46. Tabatabai A, Rabin J, Menaker J, Madathil R, Galvagno S, Menne A, Chow JH, Grazioli A, Herr D, Tanaka K, Scalea T, Mazzeffi M. Factor VIII and Functional Protein C Activity in Critically Ill Patients With Coronavirus Disease 2019: A Case Series. *A A Pract.* 2020;14(7):e01236 May.
47. Terpos E, Ntanasis-Stathopoulos I, Elalamy I, Kastritis E, Sergentanis TN, Politou M, Psaltopoulou T, Gerotziakas G, Dimopoulos MA. Hematological findings and complications of COVID-19. *Am J Hematol.* 2020;95(7):834–847 JulEpub 2020 May 23. doi:10.1002/ajh.25829.
48. Mortus JR, Manek SE, Brubaker LS, Loor M, Cruz MA, Trautner BW, Rosengart TK. Thromboelastographic Results and Hypercoagulability Syndrome in Patients With Coronavirus Disease 2019 Who Are Critically Ill. *JAMA Netw Open.* 2020;3(6):e2011192 Jun 1.
49. Xiao M, Zhang Y, Zhang S, Qin X, Xia P, Cao W, Jiang W, Chen H, Ding X, Zhao H, Zhang H, Wang C, Zhao J, Sun X, Tian R, Wu W, Wu D, Ma J, Chen Y, Zhang D, Xie J, Yan X, Zhou X, Liu Z, Wang J, Du B, Qin Y, Gao P, Lu M, Hou X, Wu X, Zhu H, Xu Y, Zhang W, Li T, Zhang F, Zhao Y, Li Y, Zhang S. Antiphospholipid Antibodies in Critically Ill Patients With COVID-19. *Arthritis Rheumatol.* 2020;72(12):1998–2004 DecEpub 2020 Oct 7. doi:10.1002/art.41425.
50. Zhang Y, Xiao M, Zhang S, et al. Coagulopathy and antiphospholipid antibodies in patients with Covid-19. *N Engl J Med.* 2020;382(17):e38 Apr 23.
51. . *Antithrombotic Therapy in Patients With COVID-19.* National Institutes of Health COVID-19 Treatment Guidelines; 2022 Retrieved from <https://www.covid19treatmentguidelines.nih.gov/therapies/antithrombotic-therapy/> Accessed on Jun 24.