


## CASE REPORT

# Endovascular coils mimicking accidental ingestion of a dental-related foreign body in radiographic imaging

Nami Nakayama | Satoshi Nakamura | Miki Yamada | Yosuke Iijima |  
Shunsuke Hino  | Norio Horie | Takahiro Kaneko

Department of Oral and Maxillofacial Surgery, Saitama Medical Center, Saitama Medical University, Saitama, Japan

## Correspondence

Shunsuke Hino, Department of Oral and Maxillofacial Surgery, Saitama Medical Center, Saitama Medical University, 1981 Kamoda, Kawagoe, Saitama 350-8550, Japan.  
Email: [shunhino@saitama-med.ac.jp](mailto:shunhino@saitama-med.ac.jp)

## Key Clinical Message

If a foreign body is seen on chest or abdominal radiographs, accidental aspiration or ingestion of a dental-related foreign body may be suspected. This report describes a case in which vascular embolization coils seen on radiography were suspected to represent a swallowed dental prosthesis. A 72-year-old man with a history of endovascular embolization of portosystemic shunt was admitted for mandibular fracture. On hospital day 2, a foreign body was noted on chest radiographs taken to confirm pleural effusion. No foreign body had been evident on radiographs of the same area the previous day. The foreign body was suspected to be a dental prosthesis, but intraoral examination ruled out this possibility, and the foreign body turned out to be metal coils used to embolize the shunt. Dentists and oral surgeons should be aware that medical devices such as vascular embolization coils can produce images similar to a dental-related foreign body on chest or abdominal radiographs, and dental-related foreign body ingestion or aspiration should be considered in the differential diagnosis.

## KEYWORDS

dental-related foreign body, endovascular coil, radiographic imaging

## 1 | INTRODUCTION

Accidental ingestion or aspiration of dental-related foreign bodies is occasionally observed. The rate of accidental ingestion or aspiration (cases/patients) has been reported as 0.0037%–0.0044%, with the majority of cases representing accidental ingestions.<sup>1,2</sup>

Although almost all aspirated dental-related foreign bodies have been successfully removed by bronchoscopy, lobectomy is sometimes performed.<sup>3,4</sup> In the case of accidentally ingested dental-related foreign bodies, blunt foreign bodies  $\leq 2$  cm in diameter can be expected to be

expelled spontaneously, but sharp foreign bodies may perforate the esophagus or other organs, and may need to be removed by endoscopy or laparotomy.<sup>5</sup> Early detection of dental-related foreign bodies and early treatment planning is therefore important.

If ingestion or aspiration is suspected, general chest and abdominal radiographs are useful to confirm the presence and location of the foreign body, particularly if the foreign body contains metallic components. Computed tomography may be necessary for objects with no metallic components. Similar to dental-related foreign bodies, various medical devices are opaque on radiography.<sup>6,7</sup>

This is an open access article under the terms of the [Creative Commons Attribution-NonCommercial-NoDerivs](https://creativecommons.org/licenses/by-nc-nd/4.0/) License, which permits use and distribution in any medium, provided the original work is properly cited, the use is non-commercial and no modifications or adaptations are made.

© 2023 The Authors. *Clinical Case Reports* published by John Wiley & Sons Ltd.

Most such medical devices are relatively easy to identify by shape. However, some devices appear similar to dental-related foreign bodies and may require differentiation.<sup>8</sup>

In this report, we describe a case of vascular embolization coils used in the treatment of a portosystemic shunt that required differentiation from an accidentally ingested dental prosthesis on radiographs.

## 2 | CASE PRESENTATION

The patient, a 72-year-old man, fell on the street and was admitted to the emergency department and was subsequently admitted to our department for mandibular fracture. The medical history of the patient included congenital portosystemic shunt, surgery for inguinal hernia, heart failure, mitral regurgitation with mitral valve replacement, chronic subdural hematoma, and vascular dementia. The shunt had been embolized due to the appearance of encephalopathy.

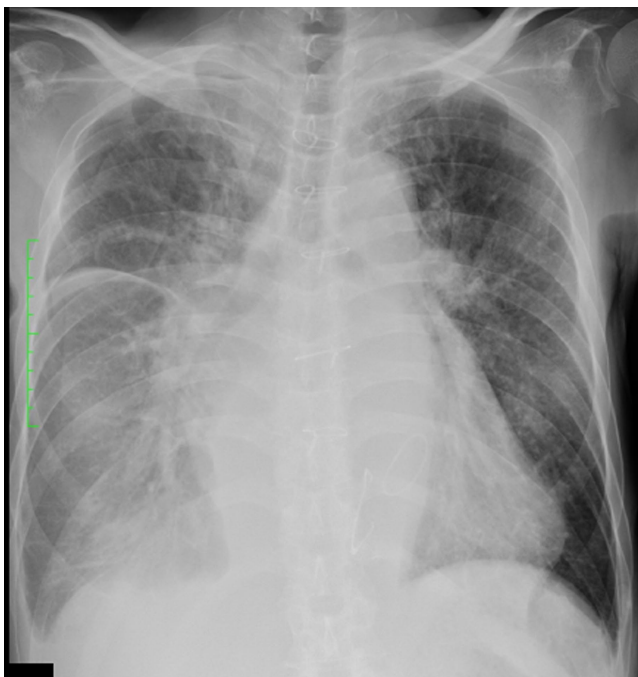The patient underwent chest radiography on admission (hospital day 1). Another chest radiograph was taken to confirm pleural effusion on hospital day 2. No foreign body was seen on the first radiograph (Figures 1 and 2). As about 24 h had elapsed since the first imaging on hospital day 1, accidental ingestion of a dental prosthesis was suspected due to the morphology of the foreign body and its position under the diaphragm. Close examination of the oral cavity revealed no missing teeth, no fixed prostheses,

and no removable dentures. The possibility of accidental ingestion of a dental-related foreign body was thus ruled out. Since the foreign body was found in the abdominal cavity and the patient had a history of shunt embolization, the patient was referred to a gastroenterology and hepatology clinic, where the foreign body was identified as coils used to embolize the portosystemic shunt.

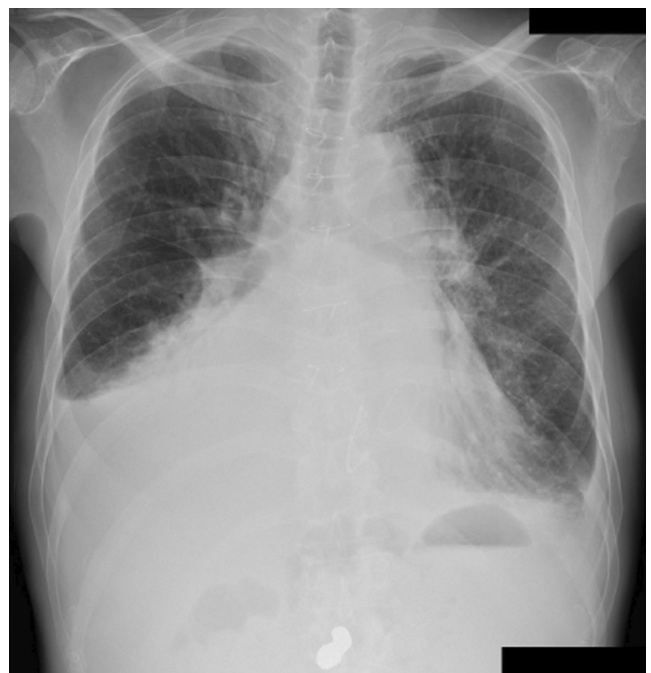
The absence of the foreign object on the initial chest radiograph and its presence on the follow-up radiograph was attributed to a difference in the positioning of the patient and imaging detector during radiography. In other words, if the initial radiograph had shown more of the abdomen as well as the chest, the foreign body would almost certainly have been recognized during the initial examination.

## 3 | DISCUSSION

This report described a case of metallic coils used for the embolization of a portosystemic shunt that was mistaken for an ingested dental prosthesis when seen as opacities on radiographic images. This case was confusing because an opaque foreign body was seen on the radiograph during the follow-up of a pleural effusion, unlike the radiograph taken the previous day. The foreign body was seen under the diaphragm and was thus suspected to have been accidentally ingested, most likely as a dental-related foreign body.



**FIGURE 1** Initial radiograph on hospital day 1. No foreign bodies were seen on radiographs.



**FIGURE 2** Radiograph on the next day (hospital day 2) shows a foreign body.

During dental procedures, sporadic accidental aspiration and ingestion of foreign objects have been observed, with ingestion very much more common than aspiration.<sup>1,2,5</sup> The main subjective symptoms of aspiration or ingestion of a dental-related foreign body include cough and pain, but half of aspiration cases and more than 90% of ingestion cases remain asymptomatic.<sup>5</sup> Determining from subjective symptoms whether a dental-related foreign body has been ingested or aspirated is thus difficult.


In general, distinguishing whether a foreign body is a dental-related foreign body is not very difficult, requiring only examination of the site in the oral cavity from which the foreign body originated. However, determination of the defect site from intraoral findings may be difficult, such as when many teeth are untreated or missing, or when a defect cannot be confirmed due to intubation or other reasons that do not allow sufficient opening of the mouth. In this case, no prosthetic defects were apparent and accidental ingestion of a dental-related foreign body was ruled out. However, the source of the foreign body could not be identified. Dentists and oral surgeons do not usually have detailed knowledge of medical devices from other areas of medicine. The foreign body, in this case, was finally identified as a coil used for embolization of the portosystemic shunt in consultation with gastroenterology and hepatology specialists.

Coils are used for endovascular and aneurysmal embolization. The coil comprises a primary coil, representing a primary stock wire made of platinum wound into a spring-like shape, and a secondary coil made of the same material and wound with further memory of diameter and shape.<sup>9</sup> For embolization of portosystemic shunts, a catheter is inserted, then coils are delivered to the affected area and filled into the target blood vessel to block blood flow (Figure 3).<sup>10</sup> Filled coils may exhibit opacity similar to that of dental prostheses on radiographs and in some cases may also have a size and morphology similar to dental prostheses.

A few reports have described radiographic opacities being mistaken for dental-related foreign bodies. Adachi et al. described a case of appendicitis caused by retention of barium sulfate used for gastrointestinal imaging.<sup>11</sup> In that case, the radiological findings of the barium deposits mimicked those of an accidentally ingested dental metal crown. We experienced another case in which an emergency room physician asked us to differentiate between a foreign body on a radiograph and a dental foreign body. In actual clinical practice, differentiation from dental-related foreign bodies may be needed from time to time.

## 4 | CONCLUSION

In conclusion, when dental-related foreign body ingestion or aspiration is suspected from chest or abdominal



**FIGURE 3** Schematic diagram of endovascular coils (arrowheads) and delivery catheter for coils (arrow).

radiographs, dentists and oral surgeons should keep in mind that medical devices such as vascular embolization coils can produce similar images and form differential diagnoses accordingly.

## AUTHOR CONTRIBUTIONS

**Nami Nakayama:** Conceptualization; data curation; formal analysis; investigation; methodology; project administration; resources; software; supervision; visualization; writing – original draft; writing – review and editing. **Miki Yamada:** Data curation; investigation; resources; software. **Satoshi Nakamura:** Data curation; investigation; resources; software; supervision; writing – review and editing. **Yosuke Iijima:** Data curation; formal analysis; resources. **Shunsuke Hino:** Conceptualization; data curation; writing – original draft; writing – review and editing. **Norio Horie:** Supervision; writing – review and editing. **Takahiro Kaneko:** Conceptualization; project administration; supervision; writing – review and editing.

## FUNDING INFORMATION

None of the authors has any financial disclosures.

## CONFLICT OF INTEREST STATEMENT

The authors declare that they have no conflict of interest.

## DATA AVAILABILITY STATEMENT

Data that support the findings of this study are available from the corresponding author or the first author upon reasonable request.

## CONSENT

Written informed consent was obtained from the patient to publish this report in accordance with the journal's patient consent policy.

## ORCID

Shunsuke Hino  <https://orcid.org/0000-0002-9690-1713>

## REFERENCES

1. Hisanaga R, Hagita K, Nojima K, et al. Survey of accidental ingestion and aspiration at Tokyo Dental College Chiba Hospital. *Bull Tokyo Dent Coll.* 2010;51(2):95-101.
2. Obinata K, Satoh T, Towfik AM, Nakamura M. An investigation of accidental ingestion during dental procedures. *J Oral Sci.* 2011;53(4):495-500.
3. Köse A, Kostak D, Aramagan E, et al. Tracheobronchial foreign body aspiration: dental prosthesis. *Case Rep Pulmonol.* 2014;2014:465856.
4. Sopeña B, García-Caballero L, Diz P, De la Fuente J, Fernández A, Díaz JA. Unsuspected foreign body aspiration. *Quintessence Int.* 2003;34(10):779-781.
5. Hou R, Zhou H, Hu K, et al. Thorough documentation of the accidental aspiration and ingestion of foreign objects during dental procedure is necessary: review and analysis of 617 cases. *Head Face Med.* 2016;12(1):23.
6. Mathew RP, Sam M, Alexander T, Patel V, Low G. Abdominal and pelvic radiographs of medical devices and materials-part 1: gastrointestinal and vascular devices and materials. *Diagn Interv Radiol.* 2020;26(2):101-110.
7. Taljanovic MS, Hunter TB, O'Brien MJ, Schwartz SA. Gallery of medical devices: part 2: devices of the head, neck, spine, chest, and abdomen. *Radiographics.* 2005;25(4):1119-1132.
8. Urade M, Shinbo T. Barium appendicitis 1 month after a barium meal. *Int Surg.* 2012;97(4):296-298.
9. Damiano RJ, Tutino VM, Lamooki SR, et al. Improving accuracy for finite element modeling of endovascular coiling of intracranial aneurysm. *PLoS One.* 2019;14(12):e0226421.
10. Ishikawa T, Imai M, Endo S, et al. Effectiveness of different coils for endovascular coiling for intractable hepatic encephalopathy caused by a portosystemic shunt. *Ann Palliat Med.* 2022;11(6):1954-1960.
11. Adachi M, Takahashi Y, Kume M, Kurenuma A, Motohashi M, Muramatsu Y. Barium-induced appendicitis mimicking accidental ingestion of a dental metal crown in radiological findings. *Clin J Gastroenterol.* 2014;7(2):129-131.

**How to cite this article:** Nakayama N, Nakamura S, Yamada M, et al. Endovascular coils mimicking accidental ingestion of a dental-related foreign body in radiographic imaging. *Clin Case Rep.* 2023;11:e7822. doi:[10.1002/ccr3.7822](https://doi.org/10.1002/ccr3.7822)