



## Cutaneous sporotrichosis in a stray cat from Thailand

Lerpen Duangkaew<sup>a</sup>, Chompoonek Yurayart<sup>b</sup>, Orawan Limsivilai<sup>b</sup>, Charles Chen<sup>c</sup>,  
Chaiyan Kasorndorkbua<sup>d,\*</sup>

<sup>a</sup> Dermatology Unit, Veterinary Teaching Hospital, Faculty of Veterinary Medicine, Kasetsart University, 50 Paholyothin Road, Ladyao, Chatuchak, Bangkok 10900, Thailand

<sup>b</sup> Department of Microbiology and Immunology, Faculty of Veterinary Medicine, Kasetsart University, 50 Paholyothin Road, Ladyao, Chatuchak, Bangkok 10900, Thailand

<sup>c</sup> Asian Veterinary Specialist Referral Center, Taipei, Taiwan

<sup>d</sup> Department of Pathology, Faculty of Veterinary Medicine, Kasetsart University, 50 Paholyothin Road, Ladyao, Chatuchak, Bangkok 10900, Thailand



### ARTICLE INFO

**Keywords:**  
Sporotrichosis  
Cat  
Stray  
Bangkok  
Thailand

### ABSTRACT

This is a case report of feline sporotrichosis in a 3-year-old male intact DSH stray cat in Bangkok, Thailand. Cytology and histopathology revealed *Sporothrix* yeast-like organisms in ulcerative cutaneous lesions. Fungal culture and sequence analysis of ITS region of rDNA confirmed the diagnosis and the causative agent as *Sporothrix schenckii*. This is the first case report of feline sporotrichosis in the country. The case report emphasizes the role of stray cats as this zoonotic disease carrier.

### 1. Introduction

Sporotrichosis is a subcutaneous and systemic mycotic infection in human, and many animal species including dogs, cats, horses, donkeys, caused by thermal dimorphic fungus, *Sporothrix schenckii* [1,2]. *S. schenckii* is classified under the division Ascomycota, class Pyrenomycetes, order Ophiostomatales and family Ophiostomataceae, with no known sexual form [2]. Epidemiological studies revealed high genetic variability within the species complex including six distinctive species that exhibited either globally or geographically distribution [3].

In the environment, *S. schenckii* exists in a mycelial form growing on living and decaying plant material. After inoculation into animal body, the fungus converts itself to a yeast form characterized by round, oval, or cigar shaped, 3–5 µm wide, and 5–9 µm long [4]. In human, sporotrichosis usually caused by transcutaneous traumatic implantation of fungal conidia contaminated thorns, splinters, straw or wood shavings [5]. Classical lesions develop as primary skin papules, nodules or abscesses and infection spreads along the regional lymphatic chain as observing multifocal to generalized skin lesions along with associated lymphadenopathy [3]. In dogs and cats, there are three recognized lesions: the localized or fixed cutaneous form, the cutaneous-lymphatic form and the disseminated or systemic form. Lesions in the nasal cavity and upper respiratory tract are usually observed in most severe cases. In both humans and animals, multifocal or systemic/disseminated sporotrichosis is rare and associated with host immunodeficiency status [5].

Treatments of sporotrichosis in cats are iodides, itraconazole,

ketoconazole, fluconazole local thermotherapy, amphotericin B and terbinafine. Treatment should be continued for at least 1 month after apparent clinical cure to prevent recurrent of clinical sign. Use of glucocorticoids or any immunosuppressive drug is contraindicated both during and after the treatment of the disease, because the disease can worsen or recur. Any concurrent bacterial infection should be simultaneously treated for 4–8 weeks with an appropriate antibacterial to help in the healing of the lesion [1,2,4].

The zoonotic potential of sporotrichosis, especially from cats to humans, are concerned for serious outbreaks in various countries [3]. Transmission of sporotrichosis from animal-to-animal or animal-to-human can occurred via bites, scratches or directly contact of injured skin with an ulcerated wound or exudate from an infected cat [4].

In Thailand, human sporotrichosis was firstly reported in 1999 [6]. Until now, the incidence has been suggested to be very low comparing to other Asian countries [3]. Animal sporotrichosis in Thailand has never been documented before as well. Zoonotic sporotrichosis outbreak in humans and cats in Malaysia, the country with geographically connected with Thailand, has shown the best example of emerging zoonosis that we should aware. Herein, we report the first confirmed case of feline sporotrichosis in a stray cat in Bangkok, Thailand.

### 2. Case

A 3-year-old male intact DSH was found as a stray cat on December 2nd, 2017. Its body condition was emaciation. The cat had multifocal

\* Corresponding author.

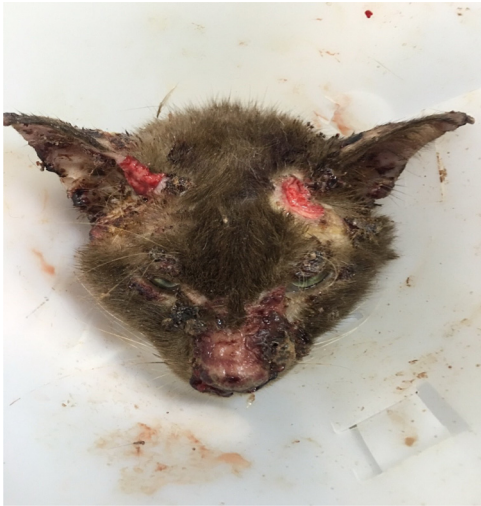E-mail address: [fvetchk@ku.ac.th](mailto:fvetchk@ku.ac.th) (C. Kasorndorkbua).

<https://doi.org/10.1016/j.mmcr.2018.12.003>

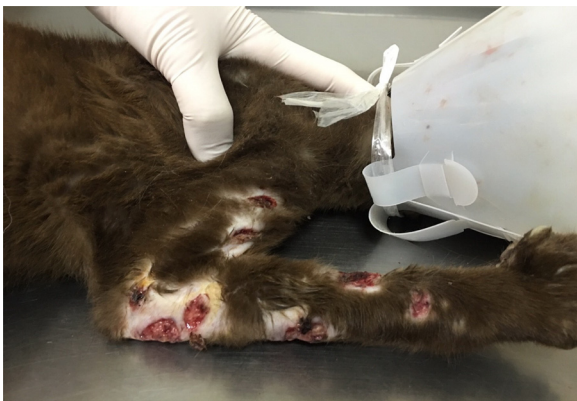Received 28 September 2018; Received in revised form 3 December 2018; Accepted 20 December 2018

Available online 21 December 2018

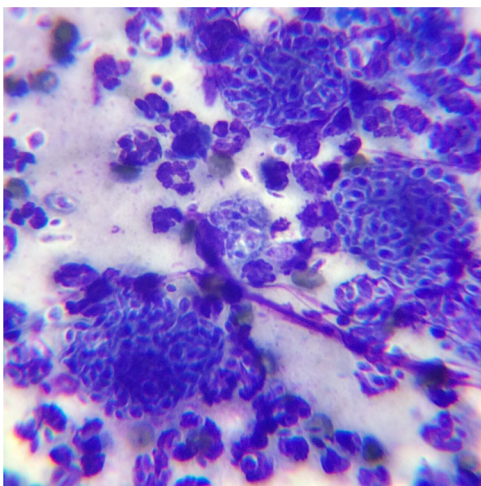
2211-7539/© 2018 The Authors. Published by Elsevier B.V. on behalf of International Society for Human and Animal Mycology. This is an open access article under the CC BY-NC-ND license (<http://creativecommons.org/licenses/by-nc-nd/4.0/>).



**Fig. 1.** Photograph of the cat. Multifocal cutaneous irregular-shaped ulcerations, ranged from 1 to 4 cm, at face, ear pinnae (Fig. 1) and right forelimb (Fig. 2).



**Fig. 2.** Photograph of the cat. Multifocal cutaneous irregular-shaped ulcerations, ranged from 1 to 4 cm, at face, ear pinnae (Fig. 1) and right forelimb (Fig. 2).



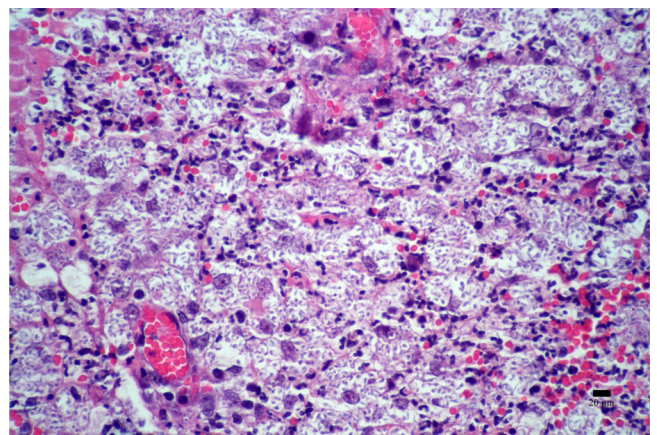
**Fig. 3.** Photomicrograph of a cytologic preparation collected from an ulcerated lesion of the cat's skin showing numerous intramacrophagic and free cigar-shaped yeasts and degenerate neutrophils. Modified Wright's Giemsa stain.

alopecic, abrasive, and ulcerated lesions located at lateral aspects of forelimbs, right hip, and both sides of ear base and the bridge of the nose. It also showed signs of upper respiratory infection including sneezing with bloody mucous discharge. The person who rescued the cat, decided to bring it directly to a private clinic. It was tested for feline immunodeficiency and feline leukemia virus and had positive result for feline leukemia virus (Snap FIV/ FeLV<sup>®</sup> combo test, IDEXX, USA). Complete blood cell count revealed leukocytosis: 32,980 (normal 5.5–19.5  $10^3/\mu\text{l}$ ), anemia (27.7%, normal range 30–45%) whereas creatinine and alanine transferase were within normal ranges. Due to the ulcerated and crusting lesions, the differential diagnosis lists of these lesions were deep pyoderma or deep mycotic infection. Cytology was performed on the ulcerated area and revealed numerous cigar-shaped yeasts, 2–5  $\mu\text{m}$  in diameter with intracellular cocci bacteria and degenerate neutrophils (Fig. 3). The phagocytosis of yeasts cells by macrophages was also noted. Initial diagnosis of cutaneous sporotrichosis was made. The cat was referred to the Kasetsart University Veterinary Teaching Hospital (KUVTH) for further diagnostics and skin biopsy to confirm sporotrichosis.

On day 0, clinical examination was performed and skin biopsy samples were collected from crusted and ulcerated lesions at ear base, lateral hip and forelimbs. The owner was educated about the disease's zoonosis potential and prognosis. On day 0, the cat was received oral itraconazole 10 mg/ml orally once a day together with daily topical solution of hypochlorite (Vetericyn<sup>®</sup>, Innovacyn, USA) at the ulcerated lesions. The cat was also given cefovecin (Convenia<sup>®</sup>, Zoetis, USA) at dose 8 mg/kg subcutaneously in order to control secondary bacterial upper respiratory infection. On day 4, the cat was found dead and the necropsy was performed.

### 3. Necropsy and histopathological findings

Multifocal pyogranulomata were present in the skin, extending from epidermis to deep dermis and caused deep ulceration. The pyogranulomata were characterized by infiltrate of macrophages, neutrophils, and lymphocytes to a lesser extent. Abundant unstained elongate-shaped yeasts were present freely in the lesion and within the macrophages. The yeasts were 4–10  $\mu\text{m}$  in diameter (Fig. 4). Periodic acid-Schiff stain revealed myriads of elongate cigar-shaped yeasts, consistent with *Sporothrix* spp. (Fig. 5). The yeasts were not found in lung, subcutaneous and hilar lymph nodes or liver. Alveolar lumen was filled with eosinophilic proteinaceous fluid associated with severe congestion of alveolar capillaries. Cause of death was acute pulmonary edema. FeLV and FIV viral infection was tested by PCR from bone marrow and heart blood respectively. The cat was positive for FeLV nucleic acid in tested bone marrow but negative for FIV in heart blood.



**Fig. 4.** Photomicrograph of a pyogranuloma characterized by infiltrate of predominant macrophages, neutrophils and lymphocytes with numerous intramacrophagic and free cigar-shaped yeasts. H & E stain.

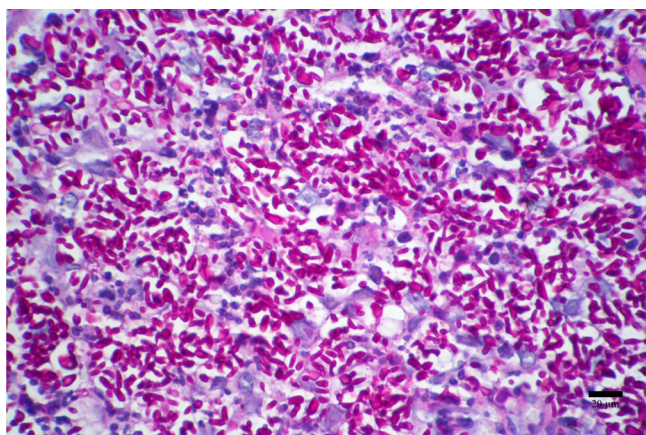


Fig. 5. Photomicrograph of numerous intralésional cigar-shaped yeasts visualized by periodic acid-Schiff stain.

#### 4. Fungal culture and PCR analysis

Samples of cutaneous exudates were collected through sterile swabs from the ulcerative lesions of nose. Prior to the process of fungal culture, high burden of yeast cells with cigar-shaped and budding was directly observed using 10% potassium hydroxide. Fungal isolation was performed by spreading the specimens on following culture media containing chloramphenicol (100 mg/L) and amoxicillin (50 mg/L): Sabouraud dextrose agar, brain heart infusion agar (BHI) and potato dextrose agar; and incubated at 25 °C and 37 °C with daily observation. Positive culture of *Sporothrix schenckii* was identified based on the colony and microscopic morphologies, as well as, its thermal dimorphism (Fig. 6). To confirm the species, fungal DNA barcoding was applied. DNA was extracted by grinding of filamentous fungal culture in liquid nitrogen and followed by the conventional extraction method from Ferrer et al., [7]. The ITS region of the rDNA was amplified using a

set of primers: SR6R (5'-AAGTATAAGTCGTAACAAGG-3') and ITS4 (5'-TCCTCCGCTTATTGATATGC-3') [8]. The amplicons were purified and sequenced in both the forward and reverse directions using ABI BigDye Terminator v. 3. 1 (Macrogen Inc., Seoul, South Korea). The sequences were bidirectional reads assembled and manually corrected for consensus sequences using BioEdit version 7.2.4. The complete sequence of ITS region was deposited to the GenBank database (accession number MG976612) and analyzed by comparing the nucleotide similarity using the BLASTn tool of the National Centre for Biotechnology Information (NCBI) (<https://blast.ncbi.nlm.nih.gov/Blast.cgi>) and the blast tool of the International Society for Human and Animal Mycology (ISHAM) Barcoding database (<http://its.mycologylab.org>). The fungus was successfully confirmed as *S. schenckii* by having 100% genetic identity to the sequences of *S. schenckii* isolated from different hosts and countries, which were available in the GenBank and ISHAM Barcoding databases.

#### 5. Discussion

This is the first confirmed case report of feline cutaneous sporotrichosis in a stray cat in Bangkok, Thailand. The diagnosis was made by skin cytology, biopsy and necropsy. Fungal culture and DNA sequencing confirmed that this cat was infected by *Sporothrix schenckii*. Sequencing of the ITS region of rDNA is currently the most widely applied gene for routine identification of fungi as recommended as the universal DNA barcode for fungal species identification [8]. However, species of the *S. schenckii* complex should be further investigated by using other genes such as calmodulin, translation elongation factor-1 alpha and beta-tubulin which are widely accepted for epidemiological study of sporotrichosis as previous described as six species of *Sporothrix schenckii sensu lato* including *S. schenckii sensu stricto* (the original *S. schenckii*), *S. brasiliensis*, *S. globose*, *S. luriei* (relevant cryptic species under *S. schenckii*), *S. mexican* and *S. albicans* [3]. Based on the literature search, this is the first confirmed case of feline sporotrichosis in Thailand, which definitive diagnosis was reached by necropsy, histopathology, fungal culture and ITS sequencing.

Host immune system is considered as an important factor for the complete cure of sporotrichosis despite the treatment with proper antifungal medication. There was a report of inversion of CD4/CD8 ratio in peripheral circulating lymphocytes, characterized by increased percentage of CD8 + cells, especially CD8<sup>low</sup> cells in severe cases of feline sporotrichosis [9]. In this present report, the cat was a stray animal, and was infected with FeLV. The defective immune system influenced by FeLV infection might be the contributing factor that made the yeast organism disseminated via the lymphatic vessels and developed generalized multifocal cutaneous lesions. According to a published study in Malaysia, evaluating the outcome of ketoconazole treatment in eight cases of feline sporotrichosis, two out of eight cats were FIV positive, but one cat was cured after 12 months [2].

This cat presented with classical sporotrichosis lesions of cutaneous involvement. However, probably due to very poor immune status and body condition, we did not find the enlargement of regional lymph nodes. Severe ulcers of mucocutaneous lesions were prominent over the head, ears and nose; multifocal lesions were also found throughout the body skin of front and hind limbs and paws, trunks and tail. This classical lesions of feline cutaneous sporotrichosis was suggested to be a virulent form in infected cats of endemic regions [10]. Affected areas may initially present with fight wound abscesses, draining tracts, cellulitis or ulcerated and crusted nodules. The risk factors in cats include intact male and roaming outdoors, which acquire the wound through contaminated claws or teeth during fights [1,2, and 4]. Some cats present with a history of lethargy, depression, anorexia, and fever, which suggest the potential for disseminated disease [4].

Due to the concurrent bacterial upper respiratory and skin infections in this presented case, cefovecin (Convenia®, Zoetis, USA) was administered. For antifungal treatment, itraconazole was selected due




Fig. 6. At 25 °C, *Sporothrix schenckii* colonies are moderately growing (5–7 days), dematiaceous fine filaments and to wrinkled and folded surface. Its mycelial form shows thin hyaline septate hyphae, typical flower-like arrangement of conidial clusters at the apex of conidiophores. At 37 °C, on BHI medium, yeast-like colonies of *S. schenckii* are glabrous, yellow to tan color; and microscopically gram-positive ovoid or elongated budding yeast cells. (For interpretation of the references to color in this figure legend, the reader is referred to the web version of this article).

to its efficacy and has less side effect compared to ketoconazole. Topical antifungal solution, hypochlorite (Vetericyn®, Innovacyn, USA) was used to be applied at the lesions around eyes and nose. This solution is not irritating and toxic when it penetrates through the mucosal layer. Retrospective review of successful treatments for feline sporotrichosis, there were 33.8% were treated with itraconazole, 38.2% with sodium iodide, 10.3% with itraconazole and fluconazole, 5.9% with itraconazole and terbinafine, and 4.4% with itraconazole and ketoconazole. The duration of treatment ranged from 16 to 80 weeks [11].

*Sporothrix schenckii* occurs worldwide, but is more common in tropical, subtropical and temperate zones with high humidity (80–95%) and mild temperatures (25–28 °C) [1]. A study of infected cats in Malaysia suggested that a clonal strain of *S. schenckii sensu stricto* is the prevailing causative agent [2]. The study reported 36 of 44 isolates (82%) were thermotolerance, which determined via culture at 37 °C for 7 days. Interestingly, *S. schenckii sensu stricto* in Malaysia showed less susceptibility to antifungal (by microdilution and E-test results) including, fluconazole, amphotericin-B, terbinafine, posaconazole, and itraconazole. Ketoconazole was the antifungal with the lowest MIC and can be considered treatment of choice for this strain [2]. There was a report of two cases of feline sporotrichosis treated with gradual dose increment of itraconazole from 10 mg/kg/day up to 60–80 mg/kg/day and the duration of treatment was up to 7–8 months. The 12-months follow up period revealed no recurrent of infection. Biochemistry profiles in these two cats were normal during the treatment period. The third cat was treated with high dose of itraconazole for 1 month together with topical application of chlorhexidine 3%, climbazole 0.5% and phytosphingosine (Douxo Pyo® Mousse, Ceva, France). This cat had increased liver enzymes, and the high dose itraconazole protocol was discontinued. Despite only being treated with high dose itraconazole for 1 month, the complete cure was achieved, and the cat was in remission at 5-month follow-up [5]. Unfortunately, the cat in this report died prior to the full course of treatment. The in vitro antifungal susceptibility should be improved in future cases.

The traumatic implantation of *S. schenckii sensu lato* spores from a contaminated source has been known as the major route of infection. The first human sporotrichosis in Thailand was reported in 1990 [6]; while the disease in cat in the country may have been overlooked. Higher number of human cases had been described earlier in other Asian countries such as Japan, Korea and India [3]. The burden of sporotrichosis throughout the world are diverse and suggested to be linked with the source of infections and zoonotic interaction [3]. In Asia and many other countries in the world, low to moderate number of sporotrichosis cases is reported annually; leisure and occupational activities such as agriculture, gardening, floriculture and mining, are concerned for major risk of infection [12]. Different situation is occurred when sporotrichosis become zoonotic transmission via bite or scratch of infected animals, especially cats, as reported in Brazil (4669 zoonotic cases), America (62 zoonotic cases) and Malaysia (23 zoonotic cases) [10,12,13]. The route of human infection by transmission from cats is more significant than environmental sources due to large amount of the yeast could be isolated from claws, skin lesions, nasal, oral cavities and feces of the infected cats. Therefore, the human infection could be transmitted by the bite or the scratch from stray cats even there is no contact with the cat's skin lesions [14].

Since we firstly report sporotrichosis in a stray cat in Thailand, an

awareness of zoonotic potential and animal transmission (cat-to-cat or cat-to-dog) should be promoted among the Thai veterinarians and animal-related workers, as well as Thai public health and society. Skin cytology should be performed in order to rule out deep mycotic infections and should be confirmed by skin biopsy. Sporotrichosis should always be suspected in cats with crusted and ulcerated cutaneous lesions, or in the cats with non-healing fight wound abscess, especially stray cats. The owners and veterinarians should be reminded to always wear gloves when handling, examining and collecting clinical samples of exudates or tissues of suspected animals and to prevent from biting and scratching [3,10]. Unfortunately, due to the poor presenting condition, the reported case succumbed, before the authors could monitor the improvement from antifungal treatment. Species within the *S. schenckii sensu lato* and the antifungal susceptibility of Thai cat strain(s) should be further determined in order to compare with feline sporotrichosis of geographically close countries.

#### Conflict of interest

None.

#### Funding source

None.

#### References

- [1] S. Crothers, S. White, P. Ihrke, K. Affolter, Sporotrichosis: a retrospective evaluation of 23 cases seen in northern California (1987–2007), *Vet. Dermatol.* 20 (2009) 249–259.
- [2] H.S. Han, R. Kano, C. Chen, C. Noli, Comparison of two in vitro antifungal sensitivity tests and monitoring during therapy of *Sporothrix schenckii sensu stricto* in Malaysian cats, *Vet. Dermatol.* 28 (2017) (156–e32).
- [3] A. Chakrabarti, A. Bonifaz, M.C. Gutierrez-Galhardo, et al., Global epidemiology of sporotrichosis, *Med. Mycol.* 53 (2015) 3–14.
- [4] W. Miller, C. Griffin, K. Cambell, *Fungal and Algal Skin Disease. Small Animal Dermatology*, 7th ed., Elsevier, St. Louis, MO, 2013, pp. 249–252.
- [5] A. Rodrigues, M. Teixeira, G. Sybren de Hoog, et al., Phylogenetic analysis reveals a high prevalence of *Sporothrix brasiliensis* in feline sporotrichosis outbreak, *PLoS Negl. Trop. Dis.* 7 (2013) e2281.
- [6] C. Kwangsukstith, N. Vanittanakom, P. Khanjanasthiti, C. Uthammachai, Cutaneous sporotrichosis in Thailand: first reported case, *Mycoses* 33 (1990) 513–517.
- [7] C. Ferrer, F. Colom, S. Frases, et al., Detection and identification of fungal pathogens by PCR and by ITS2 and 5.8S ribosomal DNA typing in ocular infections, *J. Clin. Microbiol.* 39 (2001) 2873–2879.
- [8] L. Irinyi, C. Serena, D. Garcia-Hermoso, et al., International society of human and animal mycology (ISHAM)-ITS reference DNA barcoding database—the quality controlled standard tool for routine identification of human and animal pathogenic fungi, *Med. Mycol.* 53 (2015) 313–337.
- [9] L.H.M. Miranda, M.A. Santiago, T.M. Schubach, et al., Severe feline sporotrichosis associated with an increased population of CD8<sup>low</sup> cells and a decrease in CD4<sup>+</sup> cells, *Med. Mycol.* 54 (2016) 29–39.
- [10] I.D. Gremiao, L.H. Miranda, E.G. Reis, et al., Zoonotic epidemic of sporotrichosis: cat to human transmission, *PLoS Pathog.* 13 (1) (2017) e1006077.
- [11] H.S. Han, The current status of feline sporotrichosis in Malaysia, *Med. Mycol. J.* 58 (2017) 107–113.
- [12] T.M.P. Schubach, A.O. Schubach, T. Okamoto, et al., Evaluation of an epidemic of sporotrichosis in cats: 347 cases (1998–2001), *J. Am. Vet. Med. Assoc.* 224 (2002) 1623–1629.
- [13] M.B. Barros, R. de Almeida Paes, A.O. Schubach, *Sporothrix schenckii* and sporotrichosis, *Clin. Microbiol. Rev.* 24 (4) (2011) 633–654.
- [14] A. Lloret, K. Hartman, M.G. Pennisi, et al., Sporotrichosis in cats ABCD guidelines on prevention and management, *J. Feline Med. Surg.* 15 (2013) (619–613).